

# Glenohumeral Microfracture

Michael J. Salata<sup>1</sup>, James S. Kercher<sup>2</sup>, Sarvottam Bajaj<sup>2</sup>,  
Nikhil N. Verma<sup>2</sup>, and Brian J. Cole<sup>2</sup>

Cartilage  
1(2) 121–126  
© The Author(s) 2010  
Reprints and permission:  
sagepub.com/journalsPermissions.nav  
DOI: 10.1177/1947603510366577  
http://cart.sagepub.com



## Abstract

The treatment of symptomatic cartilage lesions in the glenohumeral joint presents a significant challenge due to poor healing characteristics. Diagnosis of glenohumeral chondral defects is not always clear, and while current imaging modalities are good, many lesions require arthroscopy to fully appreciate. Arthroplasty remains an effective treatment in low-demand patients; however, younger, higher demand individuals may be treated with less invasive reparative measures. This paper discusses the diagnosis of glenohumeral chondral pathology and presents the technique, rehabilitation, and available outcomes following microfracture in the shoulder.

## Keywords

glenohumeral, microfracture, cartilage, injury

## Introduction

Full-thickness chondral defects of the glenohumeral joint are relatively uncommon, accounting for only 5% of all chondral lesions seen at the time of shoulder arthroscopy.<sup>1</sup> While the natural history of these lesions is not entirely known, in certain patients, they are symptomatic and debilitating. Total shoulder arthroplasty is becoming a more common treatment for glenohumeral degenerative disease and is currently employed as the treatment of choice for many of these patients. Today, more than 20,000 arthroplasty procedures are performed annually in the United States, but this procedure is not without limitations.<sup>2</sup> Shoulder arthroplasty has been shown to be a reliable treatment modality for pain relief and functional improvement for glenohumeral arthritis in the correctly indicated patient population. However, in younger, more active patients afflicted with these conditions, the results have not been as favorable.<sup>3</sup> This is secondary to the high demands placed on the prosthesis, thus increasing the risk of component loosening, necessitating many of these patients to require revision.

Articular cartilage lesions present a difficult problem due to the inherently poor regenerative capacity of this tissue. The lack of direct vascular supply and pluripotent cells at the articular cartilage surface contribute to ineffective healing.<sup>4,6</sup> Once a chondral defect has been sustained regardless of the etiology, without bleeding, there is a limited influx of vital reparative cells.<sup>3,4</sup> To compound the problem, articular cartilage is almost completely devoid of undifferentiated cells required to adequately heal full-thickness defects.<sup>5</sup> Therefore, the majority of symptomatic, full-thickness

chondral defects frequently require surgical intervention to achieve reduction in pain and improvements in function.

Nonarthroplasty solutions such as microfracture can be effective<sup>6–8</sup> for this patient population. Popularized by Steadman, microfracture has been widely used in the knee with good success and high patient satisfaction.<sup>4,5</sup> This technique is dependent on penetration of the subchondral bone to gain access to multipotent stem cells, which creates a pathway for cell migration into the chondral defect. Here, a marrow clot can form with the capacity to differentiate into a stable fibrocartilage patch.<sup>9</sup> While only recently extrapolated for use in the glenohumeral joint, this technique is attractive because it is simple and minimally invasive. This paper will discuss the indications, technique, and outcomes of glenohumeral microfracture.

## Patient Evaluation

### History

A thorough history should be obtained from all patients presenting with shoulder pain suspected of underlying

<sup>1</sup>Division of Orthopaedic Surgery, Rush University Medical Center, Chicago, IL, USA

<sup>2</sup>Division of Sports Medicine, Rush University Medical Center, Chicago, IL, USA

### Corresponding Author:

Michael J. Salata, Rush University Medical Center, Division of Orthopaedic Surgery, 1611 West Harrison Street, Chicago, IL 60612  
Email: michaeljsalata@gmail.com

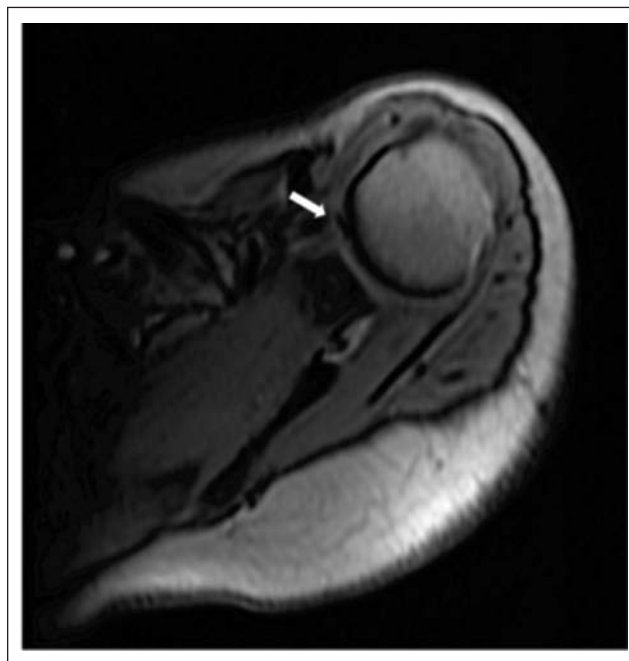
chondral pathology. Trauma to the affected shoulder should be documented including previous dislocations, subluxations, or fractures. Pain is typically deep within the joint and often associated with posterior discomfort. The character of the pain is often described as dull and achy. In addition, pain secondary to a chondral lesion will often be accentuated with increased use and frequently interferes with a patient's sleep. Mechanical symptoms such as locking and catching are also indicative of pathology localized to articular cartilage.<sup>10</sup> A thorough review of all previous operations on the affected shoulder should be standard. When available, operative reports and arthroscopic images from previous surgeries should be obtained and viewed.

A detailed physical examination should follow suit. Range of motion (ROM), both actively and passively, should be observed, recorded, and compared to the contralateral side. Pain with ROM, especially with a compressive load applied to the joint, may be indicative of chondral pathology. Additionally, the presence or absence of crepitus with ROM can be helpful in confirming an irregular chondral surface in the clinical setting. Strength testing of the rotator cuff is a very important part of the physical examination, as chondral pathology has been reported to occur at a much higher rate in the presence of a rotator cuff deficiency. Hsu et al.,<sup>11</sup> in a cadaveric study of 44 shoulders, found that 32% of specimens had glenoid chondral pathology and 36% had lesions in the humeral head when a rotator cuff tear was present. This was compared to 6% in the glenoid and 7% in the humeral head with an intact rotator cuff.<sup>11</sup>

Plain radiographs are the first line in the imaging work-up for chondral pathology of the glenohumeral joint. A true anteroposterior view, axillary view, and lateral view of the shoulder should be obtained as a standard part of the patient's evaluation. The presence and location of osteophytes and subchondral cysts and the degree of joint space narrowing should be evaluated. Computed tomography (CT) and magnetic resonance imaging (MRI) are useful to evaluate complex bony deformity and soft tissue integrity.

Although not perfect, MRI is currently the most useful imaging modality for articular cartilage. Cameron et al. reported that up to 45% of grade IV chondral defects can be missed by MRI.<sup>12</sup> Therefore, an MRI is suitable to determine the integrity of the articular cartilage; however, obtaining a detailed image of the condition of the articular surface is extremely limited (**Fig. 1**). Newer techniques utilizing various sequences of MRI are currently being developed and will allow for higher degrees of sensitivity and specificity in diagnosing chondral pathology at an earlier stage.<sup>13</sup>

Given the limitations of both the physical examination and currently available imaging modalities, arthroscopy remains the gold standard in evaluating these lesions.<sup>14</sup>

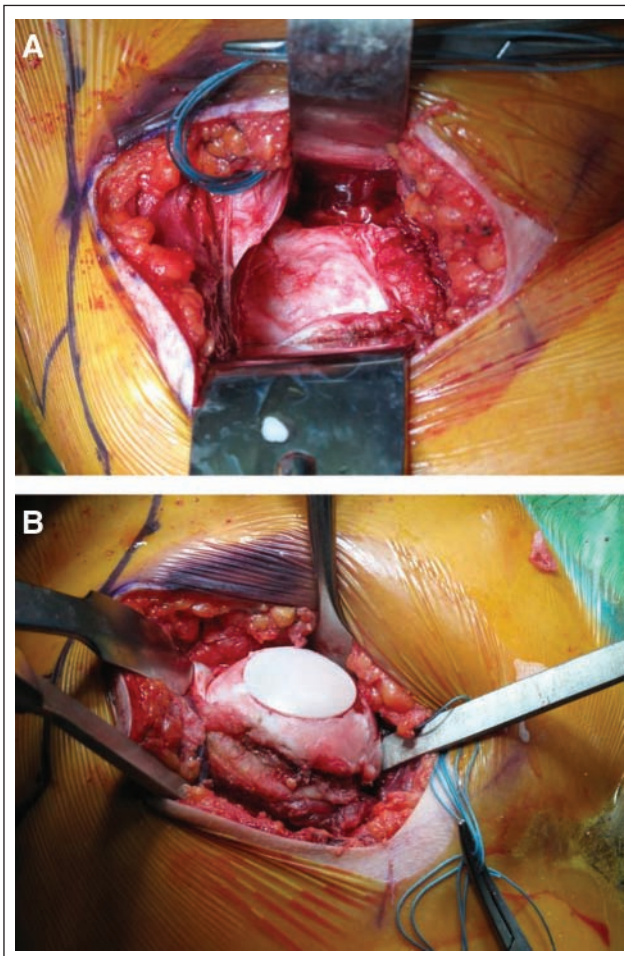


**Figure 1.** Magnetic resonance imaging (MRI) appearance of a focal chondral defect (white arrow) in the glenohumeral joint.

When evaluating for an articular cartilage defect in the glenohumeral joint, the surgeon should always be cognizant to the fact that a normal bare area can be observed at both the central glenoid and on the humeral head. The goals of an initial arthroscopy are to adequately size and stage the lesion. This may also include treatment in the form of debridement and lavage, microfracture, or staging for future interventions.

## Indications

To be considered for microfracture, a patient should have a focal symptomatic chondral defect that has failed conservative management. While the application of microfracture to the glenohumeral joint has not been well studied to date, there are relative indications reported to result in a more favorable outcome. Lesions on the humeral head that are small and unipolar appear to have a higher likelihood of improving with this surgical technique.<sup>6</sup> Additional factors associated with improved outcomes in the knee that might also apply to the shoulder include younger age (<45 years) and lower body mass index (BMI) (<30).<sup>15</sup> It remains to be seen if these issues will translate to the application of microfracture in the glenohumeral joint. In addition, in the setting of bipolar disease with a congruent glenohumeral joint, we will often treat the humeral side with biologic resurfacing (i.e., fresh osteochondral allograft) or arthroplasty and the glenoid side with microfracture in very young patients (**Figs. 2 A and B**).



**Figure 2.** (A) Glenoid defect occupying nearly 50% of the glenoid surface in a patient with postoperative chondrolysis who (B) is also being treated for a 25 × 25-mm chondral lesion of the humeral head with a fresh humeral head osteochondral allograft.

## Contraindications

Microfracture is not a solution for all chondral pathology in the shoulder. It should not be used in patients with global degenerative disease or in the setting of compromised subchondral bony architecture (i.e., glenohumeral articular dissociation due to incongruencies, uncorrected biconcave glenoid). This technique should also not be used in the setting of unaddressed shoulder instability, as repeated instability events can lead to a failure of the fibrocartilage repair tissue. Related to this contraindication is the fact that most chondral defects of the glenohumeral joint are incidental in nature and are very well tolerated clinically. Thus, every effort must be made to correct coexisting pathology that may in totality explain the source of the patient's symptoms. Relative contraindications include untreated bipolar disease and lesions of larger size.

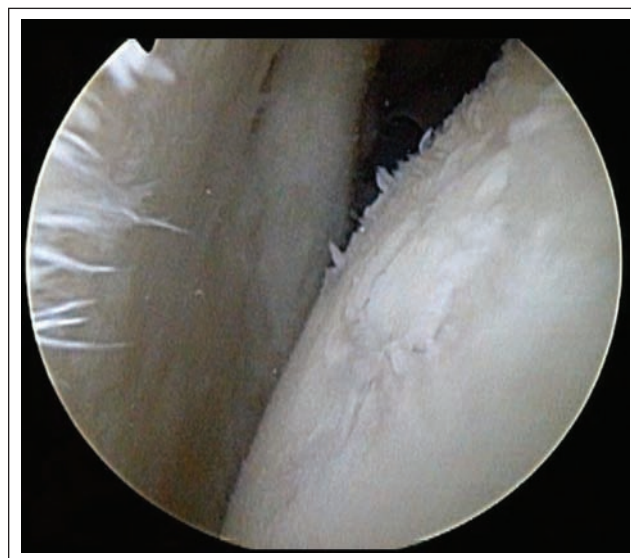
## Surgical Technique

### Anesthesia and Positioning

Depending on surgeon and patient preference, regional anesthesia with intravenous sedation or general anesthesia can be utilized to perform this procedure. Microfracture can be performed in a beach chair or a lateral position. We prefer to use a beach chair position for this procedure and utilize an articulated hydraulic arm-holding device. This facilitates the ability to position the arm to allow perpendicular entry of the microfracture awl. However, the lateral position can be used if that is the preference of the treating surgeon. A standard preparation and draping are then carried out prior to surgical incision.

### Portal Placement

A standard posterior viewing portal is created 1 to 2 cm medial and 2 cm distal to the lateral margin of the posterolateral acromion. The arthroscope is then introduced atraumatically into the glenohumeral joint, and a diagnostic arthroscopy is performed in order to confirm the lesion (Fig. 3). The next portal established is the anterior working portal. Proper placement of this portal is critical. It should be placed to allow perpendicular access to the chondral defect. If the defect is located on the glenoid, portal position will need to be adjusted. This is facilitated by spinal needle localization. For glenoid lesions, it is helpful to slightly lateralize the anterior portal to allow for direct access to the defect and to minimize interference from the



**Figure 3.** Focal chondral defect in the glenohumeral joint that is amenable to the microfracture technique. Note the intact cartilage on the periphery of the lesions that will assist in the creation of a vertically shouldered lesion.

humeral head. Posterior glenoid lesions are more difficult to access from the anterior portal but can usually be accessed by switching the camera to view from anterior and passing instruments from the posterior portal or through a second posterior accessory 7-o'clock portal.

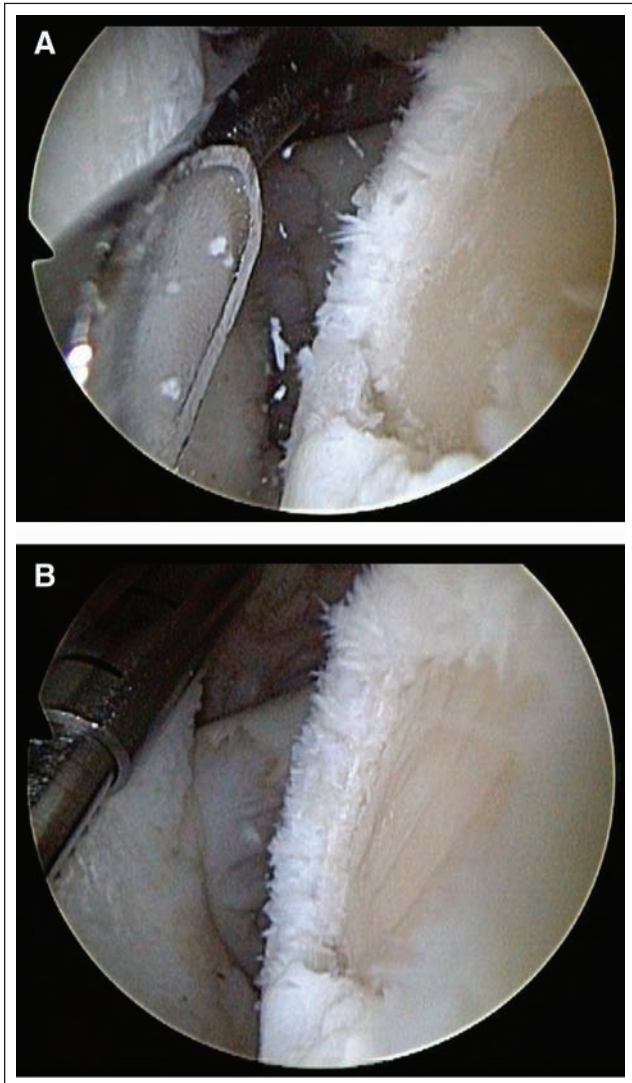
Unlike glenoid lesions, humeral lesions are more easily accessed from a medially placed anterior portal just below the biceps in the rotator interval. Rotation of the humeral head provides access to most lesions from this position, although posterior lesions may be more easily accessed by instruments placed through a posterior portal. It is important to utilize a cannula that is large enough to accommodate multiple awl angles. We have found that a 7-mm cannula is usually sufficient for this purpose. Alternatively, if a more acutely angled awl is required, it may be passed freehand through the rotator interval without the use of a cannula. After establishing proper portal placement, a thorough diagnostic arthroscopy is performed.

### Microfracture

Following lesion identification, the loose edges are debrided to form a stable rim. A combination of standard and ring type curettes is utilized for this purpose (**Fig. 4A**). This is slightly more challenging in the glenohumeral joint, as the thickness of the articular cartilage is less than that encountered in the knee. It is imperative to create vertical walls, as they not only help contain the marrow clot but also may act to distribute load, rendering the chondral defect less relevant.<sup>4,5</sup>

Prior to penetration of the subchondral bone, a meticulous removal of the calcified cartilage layer is mandatory (**Fig. 4B**). The subchondral bone of the humeral head is thin, and care should be taken not to violate the underlying architecture when removing the calcified cartilage layer.

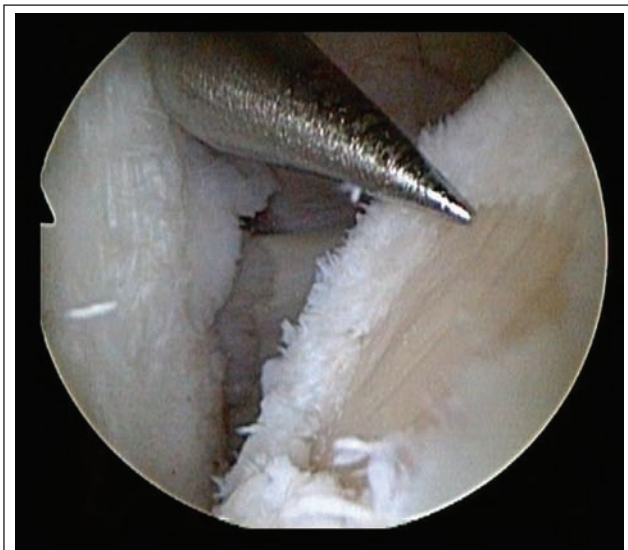Once the lesion has been adequately prepared, a microfracture awl is selected, which will allow perpendicular penetration of the subchondral bone. Begin microfracture on the periphery of the lesion (**Fig. 5**), spacing holes 3 to 4 mm apart, remaining perpendicular to the surface and sinking the awl roughly 2 to 3 mm deep on each pass. Care should be taken not to penetrate too deeply or converge the awl holes, as the subchondral bone of the humeral head and glenoid can often be very soft. This process is continued toward the center of the lesion until the surface has been adequately perforated. Irrigation pump pressure is then decreased to assess for bleeding and release of fat droplets from the microfracture holes (**Fig. 6**). An oscillating shaver is used to debride any fragmentation of the bone around the holes and additional debris that may be present. Once this is verified, the arthroscope is withdrawn from the shoulder, wounds are closed in a standard fashion, and a sterile dressing is applied.



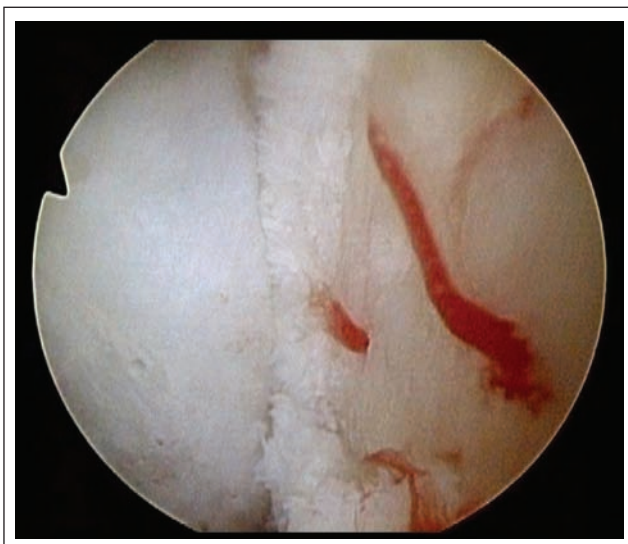**Figure 4.** Preparation of the defect using a curette (**A**). Care must be taken to meticulously remove the calcified cartilage layer as shown here in this prepared lesion (**B**).

### Postoperative Rehabilitation

Much of what we know about rehabilitation following microfracture is derived from early animal research, demonstrating that joint motion following marrow stimulation improves outcomes.<sup>16-18</sup> The postoperative regimen is designed to provide an environment in which newly recruited pluripotent cells can differentiate into the proper cell lines.<sup>16,17</sup> Most important is strict adherence to a program emphasizing joint motion, as this will help maintain lubrication and nutrition and provide mechanical stimuli to the regenerating tissue. However, unlike the knee, we do not employ continuous passive motion (CPM) devices. At our institution, we advise patients to begin pendulum



**Figure 5.** Following preparation of the defect, microfracture holes are created beginning at the periphery of the lesion.



**Figure 6.** Pump pressure has been decreased, and adequate bleeding is noted from the microfracture holes.

exercises at a rate of 600 cycles per day for 6 weeks. Gentle stretching and strengthening exercises are begun as tolerated with restricted, heavy overhead lifting for 3 months. Most patients are expected to return to full activity around 4 months postoperatively with the exception of competitive overhead athletes, who are restricted for 6 months.

## Results

There is a paucity of literature on microfracture outcomes of the glenohumeral joint. In 2003, Siebold et al.<sup>11</sup> reported on a series of 5 patients with grade IV chondral lesions of

the humeral head treated with microfracture in combination with periosteal flap coverage. Postoperatively, all patients reported significant pain relief and increased function at a mean follow-up of 25 months. Two of 3 patients who underwent second-look arthroscopy demonstrated significant size reduction of the cartilage lesions; however, postoperative imaging studies demonstrated progression of osteoarthritis in 2 patients. It should be noted that the microfractures performed in these patients were augmented with periosteal flaps, which is not a standard technique.

Millett et al.<sup>6</sup> reported outcomes for 30 patients who underwent a microfracture for full-thickness articular cartilage injuries of the shoulder. Of the 30 patients enrolled in the study, 24 patients reported significant improvement in American Shoulder and Elbow Surgeons (ASES) scores postoperatively at a mean follow-up of 47 months, while 6 progressed to further surgery. A negative correlation was observed between the size of the lesion and ASES scores, supporting the ideal use of microfracture for small-sized lesions.

Frank et al. reported a series of 16 patients (17 shoulders) who underwent glenohumeral microfracture.<sup>8</sup> The authors reported statistically significant decreases in visual analog scale (VAS) pain scores and significant improvements in the ASES and Simple Shoulder Test (SST) scores with an overall success rate of 80%. There were only 3 reported failures, and only 2 patients required further surgery. Ninety-three percent of patients undergoing this procedure stated that they were satisfied with the result and would choose to undergo the operation again.

Frank, Slabaugh, and Cole<sup>7</sup> reported on a case of glenohumeral microfracture in a 42-year-old male with a 25 × 25-mm grade IV humeral head chondral lesion. Postoperatively, pain level decreased from 3 of 10 to 0 of 10 on the VAS, full active ROM was achieved, the ASES score improved from 62 to 100, and he rated himself as completely satisfied with the procedure.<sup>7</sup> Similarly, Gogus and Ozturk published a case report of a 60-year-old woman followed for 4 years after a microfracture procedure of the glenoid for treatment of a glenoid osteochondritis dissecans. They reported an excellent result with preserved shoulder function and no pain at the 4-year mark.<sup>19</sup>

## Conclusion

Microfracture is an attractive option for chondral defects in the glenohumeral joint due to the minimally invasive nature of the procedure and technical ease. Although a useful tool for the treatment of specific focal lesions, microfracture should not be applied to all shoulders with chondral pathology. Despite early preliminary success with the use of this technique, long-term data are not currently available to determine the durability of the reparative tissue in the shoulder. Postoperative rehabilitation protocols extrapolated

from those used in the knee are currently used, but it is unclear if the biomechanical environment of the shoulder demands the same diligence to rehabilitation.

### Declaration of Conflicting Interests

The authors declared no potential conflicts of interest with respect to the authorship and/or publication of this article.

### Funding

The authors received no financial support for the research and/or authorship of this article.

### References

1. Werner AW, Lichtenberg S, Schmitz H, Nikolic A, Habermeyer P. Arthroscopic findings in atraumatic shoulder instability. *Arthroscopy*. 2004;20:268-72.
2. Sperling JW, Antuna SA, Sanchez-Sotelo J, Schleck C, Cofield RH. Shoulder arthroplasty for arthritis after instability surgery. *J Bone Joint Surg Am*. 2002;84:1775-81.
3. Cohen NP, Foster RJ, Mow VC. Composition and dynamics of articular cartilage: structure, function, and maintaining healthy state. *J Orthop Sports Phys Ther*. 1998;28:203-15.
4. Steadman JR, Rodkey WG, Rodrigo JJ. Microfracture: surgical technique and rehabilitation to treat chondral defects. *Clin Orthop Relat Res*. 2001;391 Suppl:S362-9.
5. Freedman KB, Bush-Joseph C. Microfracture technique in the knee. In: Miller MD, Bush-Joseph C, editors. *Textbook of arthroscopy*. Philadelphia: Elsevier; 2004. p. 575-9.
6. Millett PJ, Huffard BH, Horan MP, Hawkins RJ, Steadman JR. Outcomes of full-thickness articular cartilage injuries of the shoulder treated with microfracture. *Arthroscopy*. 2009;25:856-63.
7. Frank RM, Slabaugh M, Cole BJ. Resurfacing of isolated articular cartilage defects in the glenohumeral joint with microfracture: surgical technique and case report. *Am J Orthop*. 2010.
8. Frank RM, Van Thiel GS, Slabaugh MA, Romeo AA, Cole BJ, Verma NN. Clinical outcomes after microfracture of the glenohumeral joint. *Am J Sports Med*. 2010 Jan 21 [Epub ahead of print].
9. Blevins FT, Steadman JR, Rodrigo JJ, Silliman J. Treatment of articular cartilage defects in athletes: an analysis of functional outcome and lesion appearance. *Orthopedics*. 1998;21:761-7, discussion 767-8.
10. Ellman H, Harris E, Kay SP. Early degenerative joint disease simulating impingement syndrome: arthroscopic findings. *Arthroscopy*. 1992;8:482-7.
11. Hsu HC, Luo ZP, Stone JJ, Huang TH, An KN. Correlation between rotator cuff tear and glenohumeral degeneration. *Acta Orthop Scand*. 2003;74:89-94.
12. Cameron BD, Galatz LM, Ramsey ML, Williams GR, Iannotti JP. Non-prosthetic management of grade IV osteochondral lesions of the glenohumeral joint. *J Shoulder Elbow Surg*. 2002;11:25-32.
13. Gold GE, Reeder SB, Beaulieu CF. Advanced MR imaging of the shoulder: dedicated cartilage techniques. *Magn Reson Imaging Clin N Am*. 2004;12:143-59, vii.
14. Friemert B, Oberlander Y, Schwarz W, Häberle HJ, Bähren W, Gerngross H, et al. Diagnosis of chondral lesions of the knee joint: can MRI replace arthroscopy? A prospective study. *Knee Surg Sports Traumatol Arthrosc*. 2004;12:58-64.
15. Mithoefer K, Williams RJ 3rd, Warren RF, et al. Chondral resurfacing of articular cartilage defects in the knee with the microfracture technique: surgical technique. *J Bone Joint Surg Am*. 2006;88(Suppl 1 Pt 2):294-304.
16. Frisbie DD, Morisset S, Ho CP, Rodkey WG, Steadman JR, McIlwraith CW. Effects of calcified cartilage on healing of chondral defects treated with microfracture in horses. *Am J Sports Med*. 2006;34:1824-31.
17. Frisbie DD, Oxford JT, Southwood L, Trotter GW, Rodkey WG, Steadman JR, et al. Early events in cartilage repair after subchondral bone microfracture. *Clin Orthop Relat Res*. 2003;407:215-27.
18. Frisbie DD, Trotter GW, Powers BE, Rodkey WG, Steadman JR, Howard RD, et al. Arthroscopic subchondral bone plate microfracture technique augments healing of large chondral defects in the radial carpal bone and medial femoral condyle of horses. *Vet Surg*. 1999;28:242-55.
19. Gogus A, Ozturk C. Osteochondritis dissecans of the glenoid cavity: a case report. *Arch Orthop Trauma Surg*. 2008;128:457-60.