

appropriate diagnosis for our case. The patient's complete response to steroid therapy, which usually causes deterioration in COVID-19 cases, supports our diagnosis. It is important to be aware of the similar clinical manifestations between EGPA and COVID-19.

Acknowledgement


This patient in this manuscript has given written informed consent to the publication of his case details.

Conflict of interest

None.

Funding source

None.

H. Hashizume,^{1,*}  Y. Sano,¹ S. Furukawa,¹ S. Imokawa²

¹Department of Dermatology, Iwata City Hospital, Iwata, Japan,

²Department of Pulmonology, Iwata City Hospital, Iwata, Japan

*Correspondence: H. Hashizume. E-mail: hihashiz0001@mac.com

References

- 1 Ng OT, Marimuthu K, Chia PY *et al.* SARS-CoV-2 infection among travelers returning from Wuhan, China. *N Engl J Med* 2020; **382**: 1476–1478.
- 2 Alramthan A, Aldaraji W. A case of COVID-19 presenting in clinical picture resembling chilblains disease. First report from the Middle East. *Clin Exp Dermatol* 2020. <https://doi.org/10.1111/ced.14243>
- 3 Amatore F, Macagno N, Mailhe M *et al.* SARS-CoV-2 infection presenting as a febrile rash. *J Eur Acad Dermatol Venereol* 2020. <https://doi.org/10.1111/jdv.16528>
- 4 Henry D, Ackerman M, Sancelme E, Finon A, Esteve E. Urticarial eruption in COVID-19 infection. *J Eur Acad Dermatol Venereol* 2020. <https://doi.org/10.1111/jdv.16472>
- 5 Magro C, Mulvey JJ, Berlin D *et al.* Complement associated microvascular injury and thrombosis in the pathogenesis of severe COVID-19 infection: a report of five cases. *Transl Res* 2020; **220**: 1–13. <https://doi.org/10.1016/j.trsl.2020.04.007>
- 6 Marzano AV, Genovese G, Fabbrocini G *et al.* Varicella-like exanthem as a specific COVID-19-associated skin manifestation: multicenter case series of 22 patients. *J Am Acad Dermatol* 2020; **83**: 280–285.
- 7 Tammaro A, Adebajo GAR, Parisella FR, Pezzuto A, Rello J. Cutaneous manifestations in COVID-19: the experiences of Barcelona and Rome. *J Eur Acad Dermatol Venereol* 2020. <https://doi.org/10.1111/jdv.16530>
- 8 Fernandez-Nieto D, Jimenez-Cauhe J, Suarez-Valle A *et al.* Characterization of acute acro-ischemic lesions in non-hospitalized patients: a case series of 132 patients during the COVID-19 outbreak. *J Am Acad Dermatol* 2020; **83**: e61–e63. <https://doi.org/10.1016/j.jaad.2020.04.093>
- 9 Su CJ, Lee CH. Viral exanthem in COVID-19, a clinical enigma with biological significance. *J Eur Acad Dermatol Venereol* 2020. <https://doi.org/10.1111/jdv.16469>
- 10 Lindsley AW, Schwartz JT, Rothenberg ME. Eosinophil responses during COVID-19 infections and coronavirus vaccination. *J Allergy Clin Immunol* 2020. <https://doi.org/10.1016/j.jaci.2020.04.021>

DOI: 10.1111/jdv.16705

Histology of skin lesions establishes that the vesicular rash associated with COVID-19 is not 'varicella-like'

Editor

Several articles recently reported a 'varicella-like' rash in patients with COVID-19.^{1,2} We observed similar cases at our institution. However, although we agree that the clinical picture is original, we reject that 'varicella-like' denomination since clinical presentation, as well as some histologic features that we wish to report here for the first time, make it clearly different from varicella.

Three patients with a vesicular rash associated with COVID-19 (RT-PCR test on a nasopharyngeal swab specimen positive for SARS-CoV-2 ARN) were seen at our institution in April, 2020. A biopsy of a vesicle was performed in each. Multiple levels with H&E stain were done; the slides were reviewed independently by two pathologists; only concordant data were validated. A test for SARS-CoV-2 was performed on a vesicle in two patients, and a direct immunofluorescence test on perilesional skin in one.

The main features of the cases are reported in the Table 1. Clinical lesions invariably consisted in small, monomorphic vesicles of 2–3 mm diameter, often excoriated at their top; trunk, especially back, was constantly involved (Fig 1a). Itching was absent or light. Evolution was sometimes irregular, until resolution that occurred without scarring after 10–22 days.

Histology showed a similar pattern in the three cases, with a prominent non-ballooning acantholysis leading to the constitution of an intraepidermal unilocular vesicle, with in two patients a clear suprabasal location (Fig 1b). Eosinophilic dyskeratosis was also constant, with on occasion a striking 'pomegranate-like' aspect (Fig 1c). Features more suggestive of a viral infection were present once (Fig 1d). No vasculitis was seen. The direct immunofluorescence performed in one patient and the two SARS-CoV-2 PCR tests performed on vesicles were negative.

The rash that we observed was similar to that reported by Marzano², and constituted a picture that we agree to be evocative of COVID-19. But, in addition, the histologic pattern of prominent acantholysis and dyskeratosis with constitution of an unilocular intraepidermal vesicle in a suprabasal location, reported here for the first time, contributed to delineate a unique entity. Indeed, this pattern is very different from what is seen in varicella, in which major nuclear atypia, large multinucleated cells, acantholysis secondary to ballooning degeneration, involvement of the epidermis basal layer and vasculitis are regularly seen. Other acantholytic disorder (autoimmune or familial pemphigus, Grover's transient acantholytic dermatosis) do share

Table 1 Clinical and histologic data in three patients with COVID-19-associated vesicular rash

	Case 1	Case 2	Case 3
Age (years)	55	55	50
Sex	Female	Male	Female
General symptoms			
Fever	Yes	Yes	No
Asthenia	No	Yes	No
Respiratory symptoms	No	Cough, dyspnoea, mild desaturation	Light cough
Anosmia	Yes	No	No
Time to resolution	2 days	18 days	2 days
Skin symptoms			
Day of occurrence	Day 6	Day 6	Day 21
Itch	Light, irregular	No	Light, irregular
Involved sites	Trunk	Trunk	Trunk, upper limbs, face
Time to resolution	11 days	22 days	10 days
Any drug intake in the 5 days preceding rash	No	No	No
Histologic data			
Date of biopsy	Day 10 of rash	Day 6 of rash	Day 7 of rash
Intraepidermal vesicle	Yes	Yes	Yes
Acantholysis	Yes	Yes	Yes
Dyskeratosis	Yes	Yes	Yes
Suprabasal clefts	Yes	Yes	No
Balloonization of cells	No	No	No
Nuclear viral inclusions	Yes	No	No
Multinucleated cells	Yes	No	No
Mild dermal inflammatory infiltrates	Yes	Yes	Yes
Dermal eosinophils	Yes	Yes	No

some histologic features with our cases, but with a distinct clinical context. Actually, we are not aware of a viral rash in which such picture is present.

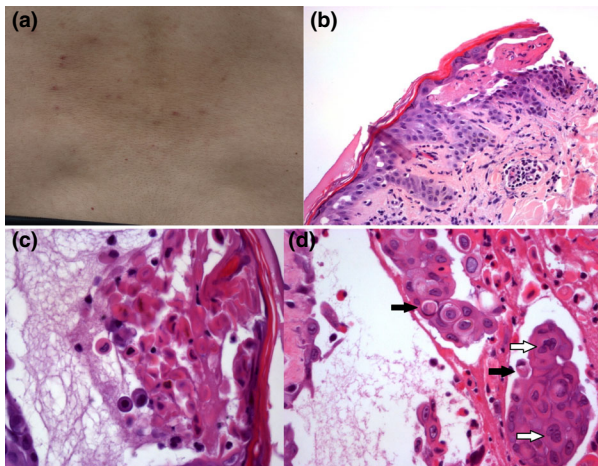


Figure 1 (a) COVID-19-associated vesicular rash involving the back in a patient. (b–d) Histologic features of COVID-19-associated vesicular rash, haematoxylin-eosin staining, (b) Acantholysis, intraepidermal vesicle, suprabasal clefts. (c) Prominent dyskeratosis with ‘pomegranate-like’ aspect. (d) Suspected nuclear viral inclusions (black arrows), multinucleated cells (white arrows).


Considering pathology in COVID-19, data are scarce and rely mainly on autopsies.³ Reports focused on the description of inflammatory and post-inflammatory changes (such as fibrosis) in the lungs. Aspects suggestive of a more direct viral effect (multinucleated cells, viral inclusions) have been rarely reported.^{4,5}

In conclusion, this picture, clinical as well as histologic, has few in common with varicella, as with other known viral rashes. It appears to us that the denomination ‘varicella-like rash’ is poorly indicative, and that such a misnomer should no longer be used. To name this entity, we suggest ‘COVID-19-associated acantholytic rash’, a denomination underlining a feature that we found striking.

Concerning pathogenesis, angiotensin-converting enzyme 2, the receptor for SARS-CoV-2, has been identified on epidermis basal cell layer keratinocytes⁶; that might suggest a direct pathogenic effect of the virus here, leading to acantholysis and dyskeratosis. Finally, despite the SARS-CoV-2 research on vesicles in our patients was negative, the aspects evocative of a direct viral effect that were seen suggested the presence of viral replication; this should probably encourage isolation precautions until such lesions have resolved.

Acknowledgement

The patients in this manuscript have given written informed consent to the publication of their case details.

A. Mahé,*  E. Birkel, C. Merklen, P. Lefèbvre,
C. Hannedouche, M. Jost, L. Droy-Dupré

Hôpital Pasteur, Colmar, France

*Correspondence: A. Mahé. E-mail: antoine.mahe@ch-colmar.fr

References

- 1 Recalcati S. Cutaneous manifestations in COVID-19: a first perspective. *J Eur Acad Dermatol Venereol* 2020; **34**: e212–e213.
- 2 Marzano AV, Genovese G, Fabbrocini G *et al*. Varicella-like exanthem as a specific COVID-19-associated skin manifestation: multicenter case series of 22 patients. *J Am Acad Dermatol* 2020; **83**: 280–285.
- 3 Tian S, Xiong Y, Liu H *et al*. Pathological study of the 2019 novel coronavirus diseases (COVID-19) through postmortem core biopsies. *Mod Pathol* 2020; **73**: 239–242.
- 4 Tian S, Hu W, Niu L, Liu H, Xu H, Xiao SY. Pulmonary pathology of early phases 2019 novel coronavirus (COVID-19) pneumonia in two patients with lung cancer. *J Thorac Oncol* 2020; **15**: e67.
- 5 Varga Z, Flammer AJ, Steiger P *et al*. Endothelial cell infection and endotheliitis in COVID-19. *Lancet* 2020; **395**: 1417–1418.
- 6 Hamming I, Timens W, Bulthuis ML, Lely AT, Navis G, van Goor H. Tissue distribution of ACE2 protein, the functional receptor for SARS coronavirus. *J Pathol* 2004; **203**: 631–637.

DOI: 10.1111/jdv.16706

Exanthema and eosinophilia in COVID-19 patients: has viral infection a role in drug induced exanthemas?

To the Editor

At the present time, the whole world is faced with coronavirus disease 2019 (COVID-19). Cutaneous manifestations in these patients are being increasingly reported, including rash, acrocyanosis or urticaria.¹ Exanthemas in COVID-19 patients are becoming frequent in our daily practice, and they pose a challenge regarding their pathogenesis.

We present a retrospective case series of twelve adult patients (6 male/6 female) with a mean age of 66,3 years (47–79). All patients had pneumonia and nasopharyngeal swab PCR positive for SARS-CoV-2 and had received treatment for COVID-19 per protocol established. Table 1 shows the characteristics of these patients.

All patients developed an itching papular exanthema after an average of 20,4 days (10–28) from their admission. At the exanthema onset, all the drugs had already been discontinued; therefore, topical corticosteroids were prescribed. However, the exanthema showed a cephalocaudal progression and confluence with islands of sparing in all cases. Seven patients developed violaceous-areas and/or target-like (Fig. 1) lesions; of them, three developed fever and facial oedema. In one patient, the

progression of the cutaneous lesions coincided with reintroduction of hydroxychloroquine and lopinavir/ritonavir. Cutaneous biopsy was performed in two of these patients: one of them showed a superficial perivascular inflammation with eosinophils and the other showed a lichenoid pattern with eosinophils. Both two were compatible with drug reaction.

Systemic corticosteroids were prescribed in six patients with violaceous areas, starting at 0.5–1 mg/kg and then tapered over the ensuing 2–4 weeks with progressive improvement. The other cases improved with topical corticosteroids.




It has been suggested that underlying viral infections may increase the risk of adverse drug reactions. The association of viral infections and drug reactions has been described in many clinical situations, such as the ampicillin rash in infectious mononucleosis or the increased risk of drug reactions in AIDS patients.² In DRESS syndrome, viral reactivation (especially HHV-6) is a characteristic feature. Antiviral immune responses may facilitate drug allergy development, and several biological mechanisms have been proposed for this effect, including excessive production of proinflammatory cytokines, which has been observed in COVID-19.^{3,4}

The presence of exanthema and eosinophilia suggests a drug reaction in our patients. DRESS syndrome, although unusual, has been reported related to hydroxychloroquine but it has not been described with lopinavir/ritonavir.⁵ Other drug reactions have also been reported with the treatments used for COVID-19 management. However, the high frequency we are observing these reactions in the COVID-19 pandemic make us think that SARS-CoV-2 infection may have a role in their pathogenesis. We suggest that several exanthemas may result from interaction between antiviral immune response and drugs. Nevertheless, more studies are needed to confirm this hypothesis. We must be cautious until then. It would be therefore strongly recommended that all COVID-19 patients with exanthema and eosinophilia were investigated for drug sensitization.

We suggest that systemic corticosteroids should be considered in those exanthemas that progress to violaceous areas or target-like lesions, since in our experience topical corticosteroids have not been able to achieve an improvement in these cases.

Acknowledgement

The patients in this manuscript have given written informed consent to publication of their case details.

A.M. Rosell-Díaz,^{1,*}  A. Mateos-Mayo,¹ 
L.M. Nieto-Benito,¹  I. Balaguer-Franch,¹
E. Hernández de la Torre-Ruiz,¹ A. Lainez-Nuez,²
R. Suárez-Fernández,¹ M. Bergón-Sendín¹

¹Dermatology Department, Hospital General Universitario Gregorio Marañón, Madrid, Spain, ²Allergology Department, Hospital General Universitario Gregorio Marañón, Madrid, Spain

*Correspondence: A.M. Rosell-Díaz. E-mail: aroselld@gmail.com