


## CLINICAL ARTICLE

# Comparison of Imaging Parameters between a New Cervical Full Lamina Back Shift Spinal Canal Enlargement Technique and Single Open-Door Laminoplasty for Multisegment Cervical Spondylotic Myelopathy

Xiao-nan Wang, MM, Yi-bo Zhao, MD, Xiang-dong Lu, MD, Xiao-feng Zhao, MD, Zhi-feng Fan, MM, De-tai Qi, MM, Run-tian Zhou, MM, Yuan-zhang Jin, MM, Bin Zhao, MD 

*Department of Orthopaedics, the Second Hospital of Shanxi Medical University, Taiyuan, China*

**Purpose:** To provide imaging evidence of the feasibility and clinical efficacy of a new full lamina back shift spinal canal enlargement technique.

**Methods:** A retrospective analysis was conducted on 64 patients with multisegment cervical spondylotic myelopathy caused by cervical stenosis. Of these, 32 patients underwent the new full lamina back shift spinal canal enlargement technique (as observation group) and 32 patients underwent single open-door miniature titanium plate internal fixation (as control group). The computed tomography (CT) data of both groups were imported into Mimics 17.0 software to measure the median sagittal diameter and cross-sectional area of the spinal canal. Photoshop CS5 was employed to measure the drift distance of the spinal cord on MR images to perform a comparative study of the imaging parameters from the two groups.

**Results:** The T2-weighted MR images in both groups showed continuous recovery of the cerebrospinal fluid signal in the C<sub>3</sub>–C<sub>7</sub> range. The enlarged spinal canal cross-sectional area (mm<sup>2</sup>) of each segment after the new full lamina back shift spinal canal enlargement technique was 130.90 ± 20.52 (C<sub>3</sub>), 180.81 ± 18.86 (C<sub>4</sub>), 240.48 ± 35.43 (C<sub>5</sub>), 145.93 ± 36.94 (C<sub>6</sub>), and 153.16 ± 36.28 (C<sub>7</sub>), and the enlarged median sagittal diameter (mm) was 5.31 ± 1.13 (C<sub>3</sub>), 8.8 ± 1.28 (C<sub>4</sub>), 10.28 ± 1.68 (C<sub>5</sub>), 9.46 ± 1.48 (C<sub>6</sub>), and 9.22 ± 1.12 (C<sub>7</sub>). Both parameters were significantly superior to single open-door miniature titanium plate internal fixation ( $P < 0.05$ ). No significant difference was detected in the drift distance of the spinal cord between the two groups ( $P > 0.05$ ).

**Conclusion:** The new full lamina back shift spinal canal enlargement technique achieved a thorough spinal canal decompression effect on imaging while ensuring a reasonable spinal drift distance and few surgical complications. The clinical curative effect of the new technique was precise.

**Key words:** Cervical vertebrae; Full lamina back shift; Imaging parameters; New type; Spinal canal enlargement

**Address for correspondence** Bin Zhao, MD, Department of Orthopaedics, the Second Hospital of Shanxi Medical University, NO.382, Wuyi Road, Taiyuan, Shanxi, China 030001 Tel: +86 138 0340 3737; Fax: 0351-3365103; Email: zzb3737@126.com

**Grant Sources:** There was no direct funding source aligned to this study.

**Disclosure:** We have no conflict of interest.

The manuscript submitted does not contain information about medical device(s)/drug(s).

Received 23 December 2020; accepted 11 April 2021

## Introduction

**M**ultisegment cervical spondylotic myelopathy is a neck condition that arises from degenerative changes in the cervical region of the spine. Cervical spinal stenosis resulting from multisegment disc herniation, ligament hypertrophy, and ossification hyperplasia compresses or stimulates the cervical spinal cord as well as the associated blood vessels, leading to sensory, motor, and reflex dysfunction in the spinal nerves. After onset, the progression of cervical spinal spondylosis is associated with the development of complications. Several investigators<sup>1,2</sup> have chosen posterior cervical surgery for treatment owing to its relative safety, effectiveness, and low rate of spinal cord injury during surgery.

In 1977, Hirabayashi *et al.*<sup>3</sup> invented a single-door spinal canal enlargement laminectomy, which directly relieved posterior spinal cord compression and expanded the sagittal diameter of the cervical spinal canal. Simultaneously, the “bowstring principle” formed by physiological cervical lordosis in the cervical spinal cord was used to make the spinal cord drift backward to achieve an indirect decompression effect on the anterior and flank side of the spinal cord<sup>4</sup>. Subsequently, additional studies on posterior cervical surgery, the development of internal fixation technologies, and various improved posterior cervical surgeries have continued to emerge. The study by O’Brien *et al.*<sup>5</sup> showed that the use of a titanium miniplate to fix the lamina could provide strong support, protecting the dura mater effectively with improved stability. Single open-door miniature titanium plate internal fixation is effective and reliable. However, injury to the posterior cervical muscle ligament complex can be large, and the spinous process can deviate from the midline, which would disrupt the stability of the cervical spine and cause axial symptoms<sup>6</sup>; the incidence of these complications is 45%–80%<sup>7</sup>.

Based on single open-door miniature titanium plate internal fixation, we have developed a new type of spinal canal enlargement that lifts the lamina and preserves the posterior cervical ligament complex. It maintains the stability of the cervical spine, effectively leading to a reduced incidence of axial symptoms. The present study reviewed the imaging data of two groups of patients with multisegment cervical spondylotic myelopathy treated with either the new full lamina back shift spinal canal enlargement technique or single open-door miniature titanium plate internal fixation. The cross-sectional area and the median sagittal diameter of the spinal canal and the distance of the spinal cord drift were measured and compared to evaluate the feasibility and advantages of the new type of spinal canal enlargement. The purpose of this study is: (i) to show the new technique has more advantages in the enlargement of the spinal canal and the expansion distance of the sagittal diameter than the single-door laminoplasty in order to obtain a thorough decompression effect; (ii) to explain the spinal cord drift distance is optimal, and the micro-titanium plate is symmetrically balanced and fixed, reducing the degree of nerve root traction and the incidence of C<sub>5</sub> nerve root palsy; and (iii) to state the integrity of the posterior muscle ligament complex

was maintained and the occurrence of axial symptoms was reduced.

## Materials and Methods

### General Data and Grouping

The current clinical research protocol fulfilled the requirements of the Helsinki Declaration and was approved by the Ethics Review Committee of the Second Hospital of Shanxi Medical University (2018LL039). All participants provided signed informed consent prior to registration.

A total of 64 patients with multisegment cervical spondylotic myelopathy underwent a new full lamina back shift spinal canal enlargement technique in our hospital between February 2017 and September 2018 and comprised the observation group (28 males and 4 females); the mean age was  $57.3 \pm 1.7$  (range, 49–76) years. Another group of 32 patients treated with single open-door miniature titanium plate internal fixation comprised the control group (26 males and 6 females); the mean age was  $56.8 \pm 1.6$  (range, 46–77) years. No significant difference was detected in the baseline data between the two groups. Subsequently, preoperative and postoperative cervical X-ray, cervical computed tomography (CT), and cervical magnetic resonance imaging (MRI) were performed.

### Inclusion and Exclusion Criteria

Inclusion criteria: (i) clinical symptoms and imaging examination leading to a diagnosis of cervical spondylotic myelopathy caused by cervical segmental disc herniation ( $\geq 3$  segments) or cervical stenosis due to continuous posterior longitudinal ligament ossification; (ii) complete and clear preoperative and postoperative imaging data (X-ray, CT, MRI); (iii) complete follow-up data for >3 months; and (iv) completion of the clinical research protocol after provision of consent by the patients.

Exclusion criteria: (i) refusal of the treatment plan; (ii) cervical vertebrae infection, fracture, tumor, and dysplasia; (iii) a combination of basic diseases such as severe diabetes and high blood pressure and an inability to undergo surgery; and (iv) incomplete clinical data.

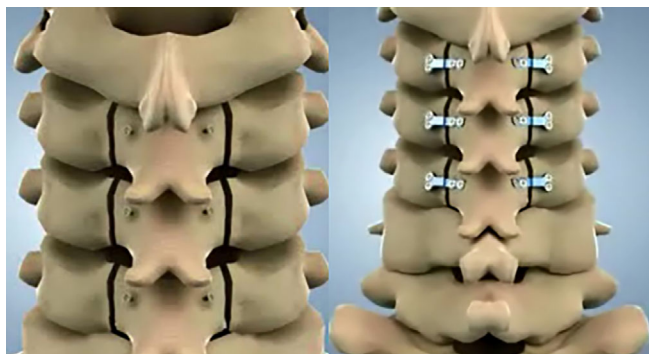
### Surgery

The operations for the two groups were performed by the same doctors. The patients were administered general anesthesia and placed in a prone position. The head and neck were slightly flexed and fixed by a stent. The skin and subcutaneous tissue were cut layer-by-layer until the spinous processes of the C<sub>2</sub>-T<sub>1</sub> vertebrae were exposed.

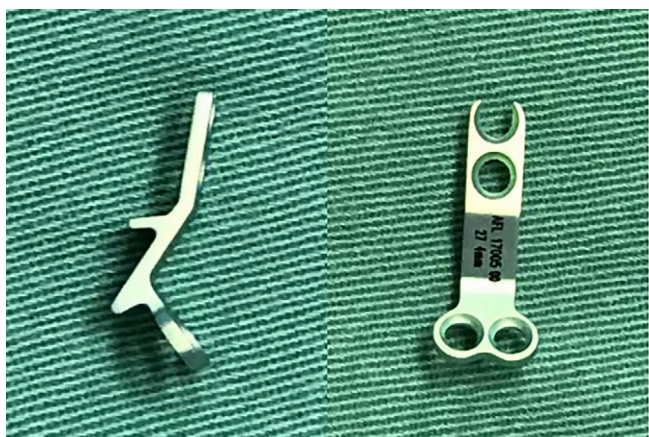Surgical procedure for the observation group: The bilateral paravertebral muscles were removed under the periosteum on both sides of the spinous process, exposing the C<sub>3-7</sub> bilateral lamina and articular processes. Throughout the procedure, the C<sub>3-7</sub> spinous processes, superior ligaments, and interspinous ligaments were preserved. Meanwhile, their

connections with the posterior cervical muscle ligament complexes of  $C_2$  and  $T_1$  were not cut off. Holes were drilled in the bilateral laminae of the  $C_{3-7}$  segments, and screws were preplaced into the holes. The  $C_{3-7}$  bilateral inner and outer bone cortexes of the laminae were gradually removed at the junction of the articular process and lamina. Suitably sized self-developed microsupport titanium plates were selected and fixed to both sides of the  $C_{3-7}$  vertebrae to achieve full lamina back shift expansion (Figs 1, 2). During the operation, the posterior dura mater of the  $C_{3-7}$  was not compressed, and the spinal cord was adequately decompressed. Then, an indwelling drainage catheter was implanted, and the surgical incision was closed layer-by-layer to complete the operation (Figs 3, 4, and 5).

Surgical procedure for the control group: The bilateral paravertebral muscles were removed under the periosteum on both sides of the spinous process, exposing the  $C_{3-7}$  bilateral lamina and articular processes. At the junction of the lamina and facet joint, a high-speed drill was used to make a groove in the bilateral lamina. The left side retained the



**Fig. 1** Schematic diagram of holes drilled into both sides of the lamina, preplacement of the screws, and placement of the miniature titanium plates.



**Fig. 2** Self-developed microsupport titanium plate.

inner panel as the hinge, while further drilling was performed on the right side to create the door in  $C_{3-7}$ . During the operation, the cervical spinal cord achieved sufficient bulging, and a preformed steel plate was placed on the open side of  $C_{3-7}$ . An indwelling drainage catheter was implanted, and the incision was sutured layer-by-layer to complete the operation.

### Data Measurement

#### Cross-Sectional Area and Median Sagittal Diameter of the Spinal Canal

The cervical CT data (64-slice CT 0.625 mm thin-layer scan) of 62 patients were imported into Mimics 17.0 software in DICOM format for evaluation.

##### a. Cross-sectional area

The segmentation function in Mimics 17.0 software was used to select the measurement area. The ability to automatically identify the edge of the spinal canal<sup>8</sup> allowed measurement of the cross-sectional area of the spinal canal for the  $C_{3-7}$  segments at the midpoint plane of the pedicle. The posterior edge of the vertebral body or the posterior margin of the pathological placeholder, such as the intervertebral disc or the posterior longitudinal ligament ossification, was chosen as the anterior border of the spinal canal. The posterior border was defined as the anterior edge of the segmental lamina and both sides of the inner edge of the pedicle. The preoperative cross-sectional area was defined as  $S_1$  and the postoperative area was defined as  $S_2$ . Thus, the enlarged area was calculated as  $S_2 - S_1$  (Fig. 6).

##### b. Median sagittal diameter

The median sagittal diameter of the  $C_{3-7}$  segments was measured on the sagittal images. The distance was estimated from the midpoint of the posterior margin of the vertebral body to the midpoint of the lamina (except for the pathological placeholders such as prominent discs and bone hyperplasias). The preoperative median sagittal diameter was defined as  $d_1$ , and the postoperative diameter was defined as  $d_2$ ; thus, the enlarged distance was calculated as  $d_2 - d_1$  (Fig. 7).

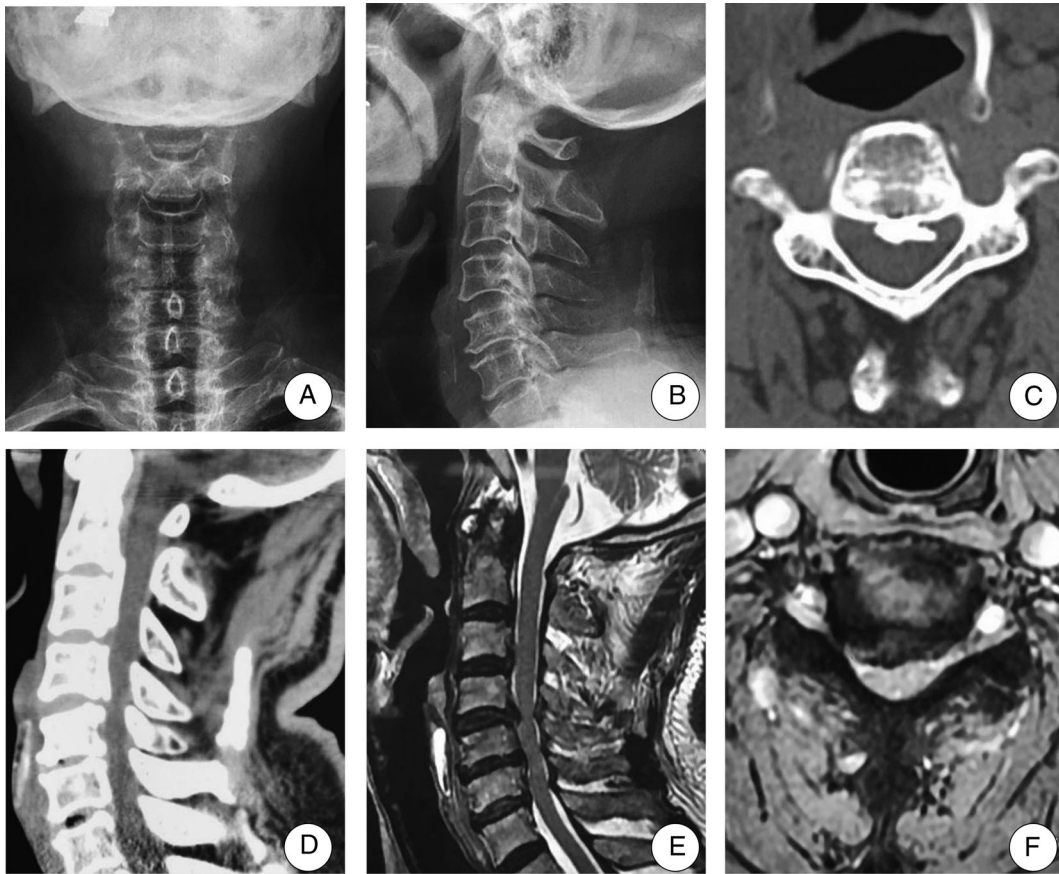
#### Spinal Cord Drift Distance

The preoperative and immediate postoperative central sagittal cervical MRI T2-weighted images were used to measure the distance from the midpoint of the posterior border of the  $C_{3-7}$  segments to the center of the spinal cord with Photoshop CS5 software. The preoperative distance was  $b_1$ , and the postoperative distance was  $b_2$ ; thus, the spinal cord drift was calculated as  $b_2 - b_1$ .

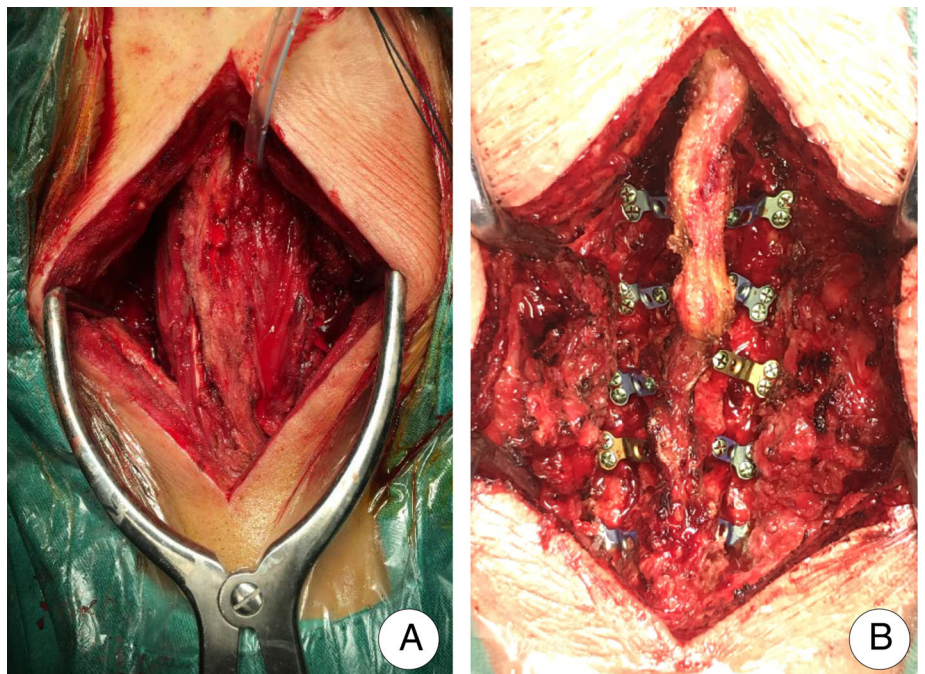
#### Statistical Data Processing

Statistical analysis of the measurement data was performed using SPSS21.0 software and is represented by the mean and standard deviation ( $\bar{x} \pm s$ ). The preoperative and postoperative parameters in one group and the parameters of the

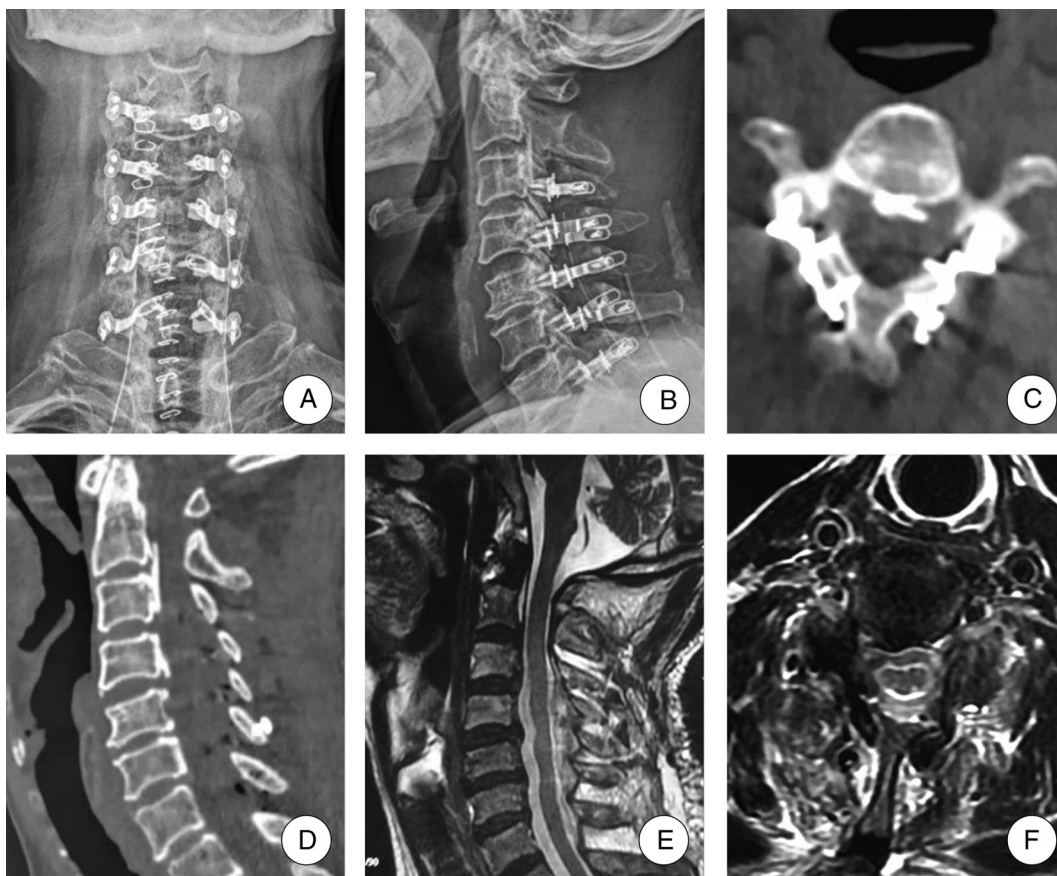




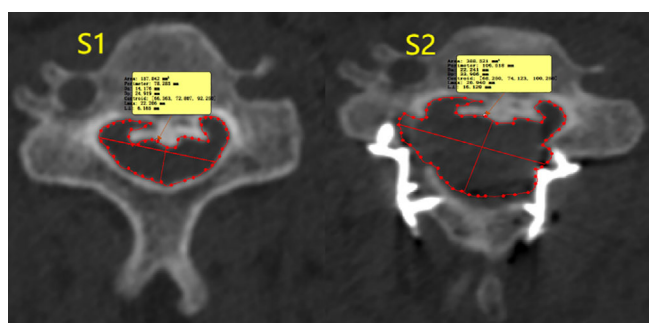
**Fig. 3** A 61-year-old patient with multi-segment cervical spondylotic myelopathy in the observation group. Cervical preoperative X-ray showed cervical spine degeneration (A, B). CT showed bone spinal stenosis, and there was bone space in the spinal canal (C, D). MRI showed multi-segment cervical disc herniation, posterior ligament hypertrophy, and spinal cord compression (E, F).



**Fig. 4** Use micro titanium plates to balance and fix the posterior lamina and suture the muscle fascia *in situ* to restore stability.



**Fig. 5** Imaging data of the same patient as in Fig. 3 after the new cervical full lamina back shift spinal canal enlargement technique. Postoperative X-ray showed that the internal fixation was firm (A,B). CT showed obvious enlargement of the bony spinal canal (C,D). MRI showed unobstructed cerebrospinal fluid and adequate decompression of the spinal canal (E,F).

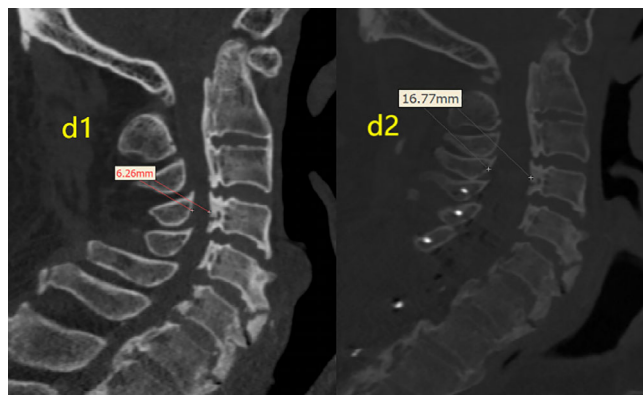

**Fig. 6** Measurement of the cross-sectional area of the C<sub>4</sub> segment before and after surgery in a patient.

patients in the observation and control groups were compared by completely randomized independent samples t-tests at the  $\alpha = 0.05$  level.

### Results

A significant difference was detected between the preoperative and postoperative cross-sectional area of the



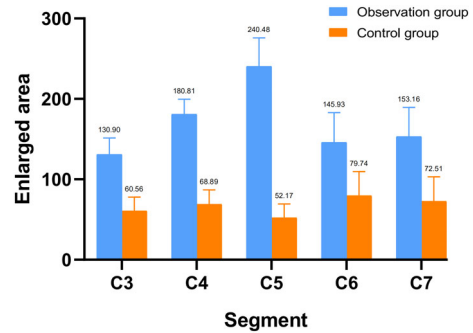
**Fig. 7** Measurement of the median sagittal diameter of the C<sub>4</sub> segment before and after surgery in a patient.

spinal canal for each group ( $P < 0.05$  for both). The enlarged cross-sectional area in each segment after surgery of the observation group was significantly better than that of the control group ( $P < 0.05$  for all) (Table 1, Fig. 8).

**TABLE 1 Comparison of the cross-sectional and enlarged areas between the two groups before and after the operation (mm<sup>2</sup>)**

Segments	Observation group (n = 32)			Control group (n = 32)			t	P
	Preoperation	Postoperation	Enlarged area	Preoperation	Postoperation	Enlarged area		
C <sub>3</sub>	152.19 ± 9.19	283.09 ± 15.67*	130.90 ± 20.52	158.88 ± 11.17	219.43 ± 15.83*	60.56 ± 17.33 <sup>†</sup>	10.476	<0.001
C <sub>4</sub>	168.92 ± 9.54	349.73 ± 18.14*	180.81 ± 18.86	146.60 ± 8.57	215.49 ± 13.38*	68.89 ± 18.03 <sup>†</sup>	17.16	<0.001
C <sub>5</sub>	231.80 ± 19.84	472.28 ± 29.15*	240.48 ± 35.43	201.98 ± 12.57	254.15 ± 14.46*	52.17 ± 17.3 <sup>†</sup>	19.104	<0.001
C <sub>6</sub>	284.09 ± 22.79	430.03 ± 26.95*	145.93 ± 36.94	221.99 ± 20.92	301.73 ± 20.95*	79.74 ± 29.76 <sup>†</sup>	5.582	<0.001
C <sub>7</sub>	286.96 ± 21.97	440.12 ± 26.98*	153.16 ± 36.28	230.41 ± 20.15	302.92 ± 21.08*	72.51 ± 30.54 <sup>†</sup>	6.803	<0.001

\* P < 0.05 vs preoperative area; <sup>†</sup> Significant difference vs. the corresponding enlarged area of the observation group.



**Fig. 8** Measurement of the cross-sectional area of the C<sub>4</sub> segment before and after surgery in a patient who underwent the new full lamina back shift spinal canal enlargement technique.

A significant difference was detected between the pre-operative and postoperative median sagittal diameter of the spinal canal for each group ( $P < 0.05$  for both). The enlarged median sagittal diameter in each segment of the observation group was significantly better than that of the control group ( $P < 0.05$ ) (Table 2, Fig. 9).

Immediately after surgery, the T2-weighted MR images of both groups showed continuous recovery of the cerebrospinal fluid signal for the C<sub>3-7</sub> segments. No significant difference was detected in the overall and per-segment post-operative spinal cord drift distance between the two groups ( $P > 0.05$ ) (Table 3).

**Discussion**

**Feasibility and Curative Effect Analysis of the New Spinal Canal Enlargement Technique**

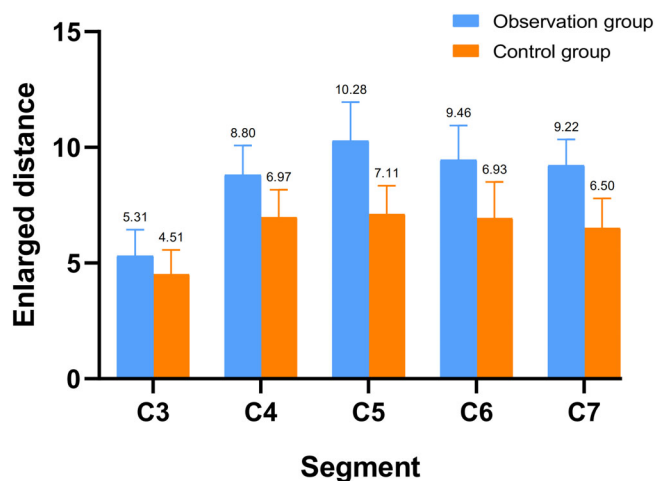
Compared to single open-door miniature titanium plate internal fixation, the new full lamina back shift spinal canal enlargement technique involves cutting the lamina on both sides to move the freed bone posteriorly and elevate it, enlarging the cross-sectional area, and increasing the median sagittal diameter of the spinal canal. The new procedure achieved a thorough decompression effect, providing sufficient space for the drifting and swelling of the spinal cord. Our previous research showed that the visual analog scale (VAS) scores of patients undergoing this new surgical technique decreased from 7.3 to 1.6, and the Japanese Orthopaedic Association (JOA) score improved from 6.9 before the operation to 13.4 at the last follow-up. Furthermore, the percentage of neurological improvement was  $87.23\% \pm 3.81\%$ <sup>9</sup>. Li *et al.* pointed out that<sup>10</sup> for a median spinal canal sagittal diameter of 136.2%, postoperative spinal cord compression was significantly relieved. Kohno *et al.* also found that<sup>11</sup> an adequate surgical effect was achieved when the median sagittal diameter of the spinal canal was enlarged by 5 mm. The degree of median sagittal diameter expansion in each segment following the new full lamina back shift spinal canal enlargement exerted a clinically significant effect. Some



**TABLE 2 Comparison of the median sagittal diameter and enlarged distance between the two groups before and after the operation (mm)**

Segments	Observation group (n = 32)			Control group (n = 32)			t	P
	Preoperation	Postoperation	Enlarged distance	Preoperation	Postoperation	Enlarged distance		
C <sub>3</sub>	7.70 ± 0.49	13.01 ± 1.05*	5.31 ± 1.13	9.16 ± 0.71	13.66 ± 0.84*	4.51 ± 1.06 <sup>†</sup>	2.074	0.047
C <sub>4</sub>	8.00 ± 0.40	16.80 ± 1.39*	8.8 ± 1.28	7.69 ± 0.51	14.66 ± 1.12*	6.97 ± 1.2 <sup>†</sup>	4.163	<0.001
C <sub>5</sub>	8.35 ± 0.39	18.63 ± 1.69*	10.28 ± 1.68	8.51 ± 0.50	15.62 ± 1.34*	7.11 ± 1.23 <sup>†</sup>	6.067	<0.001
C <sub>6</sub>	10.22 ± 0.50	19.68 ± 1.23*	9.46 ± 1.48	10.03 ± 0.50	16.96 ± 1.56*	6.93 ± 1.57 <sup>†</sup>	4.689	<0.001
C <sub>7</sub>	8.91 ± 0.44	18.14 ± 0.90*	9.22 ± 1.12	10.17 ± 0.49	16.67 ± 1.03*	6.5 ± 1.29 <sup>†</sup>	6.37	<0.001

\* P < 0.05 vs preoperative distance; <sup>†</sup> Comparison of the enlarged distance between the two groups.



**Fig. 9** Measurement of the median sagittal diameter of the C<sub>4</sub> segment before and after surgery in a patient who underwent the new full lamina back shift spinal canal enlargement technique.

**TABLE 3 Comparison of the postoperative spinal cord drift distances in each segment for the two groups (mm)**

Segments	Observation group (n = 32)	Control group (n = 32)	t	P
C <sub>3</sub>	2.04 ± 0.10	1.98 ± 0.10	1.855	0.073
C <sub>4</sub>	3.30 ± 0.13	3.25 ± 0.13	0.987	0.331
C <sub>5</sub>	3.50 ± 0.13	3.47 ± 0.18	0.455	0.659
C <sub>6</sub>	3.30 ± 0.17	3.27 ± 0.12	0.660	0.514
C <sub>7</sub>	2.48 ± 0.08	2.44 ± 0.14	1.084	0.289

investigators reported<sup>12,13</sup> that when “reclosure” occurred, the cross-sectional area and the median sagittal diameter of the spinal canal decreased, leading to recurrence of preoperative symptoms and delayed recovery of spinal cord function. This conclusion also indicated that the postoperative spinal canal cross-sectional area and the expansion of the median sagittal diameter are critical parameters for determining the curative effect of posterior cervical decompression surgery.

Single open-door miniature titanium plate internal fixation is currently used for the treatment of cervical spondylotic myelopathy caused by cervical spinal stenosis and has satisfactory clinical effects<sup>14</sup>. The current study found that the new full lamina back shift spinal canal enlargement technique was better than single open-door miniature titanium plate internal fixation in terms of the expansion of the cross-sectional area and the median sagittal diameter of the spinal canal. Therefore, the new full lamina back shift spinal canal enlargement technique had a definite and reliable clinical effect.

#### Effect of the New Full Lamina Back Shift Spinal Canal Enlargement on C<sub>5</sub> Nerve Root Palsy

C<sub>5</sub> nerve root palsy may occur after posterior cervical decompression, mainly manifesting as deltoid muscle and biceps weakness and thereby affecting the immediate quality of life of the patients after surgery and reducing the degree of surgery satisfaction<sup>15</sup>. The incidence after single-door laminoplasty is 5.1%<sup>16</sup>. A majority of investigators have speculated that<sup>17</sup> C<sub>5</sub> nerve root palsy is related to nerve root traction caused by excessive spinal cord drift after decompression. Moreover, the C<sub>5</sub> level is located at the apex of the decompression, and the majority of the postoperative spinal cord drift occurs at this segment. Simultaneously, the C<sub>5</sub> nerve root is short and projects from the spinal cord at an obtuse angle, causing it to be maximally damaged after compression. Imagama *et al.*<sup>18</sup> carried out a retrospective analysis of 1858 patients undergoing posterior cervical laminectomy. Among them, 43 cases had C<sub>5</sub> root palsy symptoms, and their average spinal cord drift distance was 3.9 mm. This study showed that the new full lamina back shift spinal canal enlargement technique achieved effective decompression, while the degree of spinal cord drift was not significantly different from that of the control group (P > 0.05). Thus, we speculated that the new full lamina back shift spinal canal enlargement technique would not increase the incidence of C<sub>5</sub> root palsy. In addition, due to the non-uniform enlargement of the two sides of the spinal canal in single-door laminoplasty surgery, the resulting asymmetric rotational force might cause the spinal cord to drift towards

the open side, thereby increasing the degree of hinge lateral nerve root traction, in turn increasing the incidence of C<sub>5</sub> nerve root palsy<sup>19,20</sup>. In the new type of spinal canal enlargement, a homemade laminar-formed titanium plate was used to perform strong internal fixation on both sides of the lamina simultaneously. This maintained symmetrical balance, effectively avoiding the putative compression of the bony structure on the side of the door shaft during the spinal cord drift and swelling that occurs in single open-door miniature titanium plate internal fixation. Therefore, our improved surgical methods might be beneficial for reducing the occurrence of C<sub>5</sub> nerve root palsy. In our observation group, one patient developed C<sub>5</sub> nerve root palsy symptoms after surgery; his spinal cord drift distance was 3.83 mm. No significant difference was detected in the mean spinal cord drift distance between this patient and the control group ( $P > 0.05$ ). For this patient, the strength of the deltoid and biceps muscles returned to normal after 2 months.

#### **Effect of the New Full Lamina Back Shift Spinal Canal Enlargement on Axial Symptoms**

Kawaguchi *et al.*<sup>21</sup> defined long-term postoperative neck and shoulder pain accompanied by soreness and heavy feelings as axial symptoms. Yoshida *et al.*<sup>22</sup> suggested that the incidence of axial symptoms was reduced by preserving the posterior cervical spinous process ligament complex. Okada *et al.* conducted a prospective study<sup>23</sup> that showed a decrease in the incidence of axial symptoms after the surgery mentioned above. Different from the study by Casha<sup>24</sup>, the lamina and spinous processes of the

decompression segment were completely separated from the other tissues, removed from the body, soaked in hydrogen peroxide, and reimplanted in the corresponding position for fixation. For the new surgical procedure, we preserved the spinous processes, supraspinous ligaments, and interspinous ligaments without removing the connection between the decompression segments and the upper and lower segments, maintaining their midline positions. Additionally, we sutured the muscles and ligaments *in situ* to maintain the integrity of the posterior cervical muscle and ligament complex to reduce the occurrence of axial symptoms. Consecutively, we used a self-developed laminoplasty titanium plate to rigidly fix the raised lamina bilaterally, which significantly enhanced the stability of the cervical spine surgery. Therefore, paravertebral muscle exercises could be performed sooner after surgery, reducing the possibility of axial symptoms. These results were in agreement with the study by Ito *et al.*<sup>25</sup>.

#### **Conclusions**

In summary, the new full lamina back shift spinal canal enlargement technique achieved a thorough spinal canal decompression effect, thereby reducing the occurrence of axial symptoms and controlling the incidence of C<sub>5</sub> nerve root palsy. We concluded that the clinical efficacy was satisfactory. Nevertheless, the correlations between different-sized titanium plates and the expansions of both the cross-sectional area of the spinal canal and the median sagittal diameter will be investigated in the future to further guide the use of this new technique in clinical practice.

### **References**

- Miyata K, Marui T, Miura J, *et al.* Kinetic analysis of the cervical spinal cord in patients after spinous process-splitting laminoplasty using a kinematics magnetic resonance imaging technique. *Spine (Phila Pa 1976)*, 2006, 31: 690–697.
- Tang C, Huang JC, Cheng XG. Explorations to the outcome of different angles of open-door expansive laminoplasty in multi-segmental cervical spondylotic myelopathy. *Chin J Exp Surg*, 2014, 31: 2608–2610.
- Hirabayashi K, Watanabe K, Wakano K, *et al.* Expansive open-door Laminoplasty for cervical spinal Stenotic myelopathy. *Spine (Phila Pa 1976)*, 1983, 8: 693–699.
- Onuma H, Hirai T, Yoshii T, *et al.* Clinical and radiologic outcomes of bone grafted and non-bone grafted double-door laminoplasty, the modified Kirita-Miyazaki method, for treatment of cervical spondylotic myelopathy: five-year follow-up. *J Orthop Sci*, 2018, 23: 923–928.
- O'Brien MY, Peterson D, Casey ATH, *et al.* A novel technique for laminoplasty augmentation of spinal canal area using titanium miniplate stabilization a computerized morphometric analysis. *Spine (Phila Pa 1976)*, 1996, 21: 474–483.
- Sakaura H, Hosono N, Mukai Y, *et al.* Preservation of muscles attached to the C2 and C7 Spinous processes rather than subaxial deep extensors reduces adverse effects after cervical Laminoplasty. *Spine (Phila Pa 1976)*, 2010, 35: 782–786.
- Rhee JM, Register B, Hamasaki T, *et al.* Plate-only open door laminoplasty maintains stable spinal canal expansion with high rates of hinge union and no plate failures. *Spine (Phila Pa 1976)*, 2010, 36: 9–14.
- Honda O, Kawai M, Gyobu T, *et al.* Reproducibility of temporal volume change in CT of lung cancer: comparison of computer software and manual assessment. *Br J Radiol*, 2009, 82: 742–747.
- Zhao B, Zhao YB, Lu XD, *et al.* Research and application of cervical vertebral dome expansion laminoplasty. *Chin J Orthop*, 2019, 39: 604–612.
- Li XK, Liu X, Che L, Ma CJ, Samartzis D, Wang HQ. Cervical open-door laminoplasty technique with simple sutures and bone grafts: a single institutional study with 30 consecutive cases. *J Orthop Surg Res*, 2015, 10: 14.
- Kohno K, Kumon Y, Oka Y, Matsui S, Ohue S, Sakaki S. Evaluation of prognostic factors following expansive laminoplasty for cervical spinal stenotic myelopathy. *Surg Neurol*, 1997, 48: 237–245.
- Chen H, Deng Y, Li T, Gong Q, Song Y, Liu H. Clinical and radiography results of mini-plate fixation compared to suture suspensory fixation in cervical laminoplasty: a five-year follow-up study. *Clin Neurol Neurosurg*, 2015, 138: 188–195.
- Hu W, Shen X, Sun T, Zhang X, Cui Z, Wan J. Laminar reclosure after single open-door laminoplasty using titanium miniplates versus suture anchors. *Orthopedics*, 2014, 37: e71–e78.
- Houten JK, Cooper PR. Laminectomy and posterior cervical plating for multilevel cervical spondylotic myelopathy and ossification of the posterior longitudinal ligament: effects on cervical alignment, spinal cord compression, and neurological outcome. *Neurosurgery*, 2003, 52: 1081–1087.
- Miller JA, Lubelski D, Alvin MD, Benzel EC, Mroz TE. C5 palsy after posterior cervical decompression and fusion: cost and quality-of-life implications. *Spine J*, 2014, 14: 2854–2860.
- Shou F, Li Z, Wang H, *et al.* Prevalence of C5 nerve root palsy after cervical decompressive surgery: a meta-analysis. *Eur Spine J*, 2015, 24: 2724–2734.
- Nassar A, Eck JC, Ponnappan RK, Zanoun RR, Donaldson WF III, Kang JD. The incidence of C5 palsy after multilevel cervical decompression procedures: a review of 750 consecutive cases. *Spine (Phila Pa 1976)*, 2012, 37: 174–178.
- Imagama S, Matsuyama Y, Yukawa Y, *et al.* C5 palsy after cervical laminoplasty: a multicenter study. *J Bone Joint Surg Br*, 2010, 92: 393–400.
- Motohiro O, Akihito M, Toru E, *et al.* A prospective randomized study of clinical outcomes in patients with cervical compressive myelopathy treated with open-door or French-door laminoplasty. *Spine (Phila Pa 1976)*, 2009, 34: 1119–1126.



- 20.** Kaneyama S, Sumi M, Kanatani T, *et al.* Prospective study and multivariate analysis of the incidence of C5 palsy after cervical laminoplasty. *Spine (Phila Pa 1976)*, 2010, 35: E1553–E1558.
- 21.** Kawaguchi Y, Matsui H, Ishihara H, Gejo R, Yoshino O. Axial symptoms after en bloc cervical laminoplasty. *J Spinal Disord*, 1999, 12: 392–395.
- 22.** Yoshida M, Tamaki T, Kawakami M, *et al.* Does reconstruction of posterior ligamentous complex with extensor musculature decrease axial symptoms after cervical laminoplasty?. *Spine (Phila Pa 1976)*, 2002, 27: 1414–1418.
- 23.** Okada M, Minamide A, Endo T, *et al.* A prospective randomized study of clinical outcomes in patients with cervical compressive myelopathy treated with open-door or French-door laminoplasty. *Spine (Phila Pa 1976)*, 2009, 34: 1119–1126.
- 24.** Casha S, Engelbrecht HA, DuPlessis SJ, Hurlbert RJ. Suspended laminoplasty for wide posterior cervical decompression and intradural access: results, advantages, and complications. *J Neurosurg Spine*, 2004, 1: 80–86.
- 25.** Ito M, Nagahama K. Laminoplasty for cervical myelopathy. *Global Spine J*, 2012, 2: 187–194.