




Contents lists available at ScienceDirect

North American Spine Society Journal (NASSJ)

journal homepage: www.elsevier.com/locate/xnsj

Basic Science

Biomechanical evaluation of a novel decompression surgery: Transforaminal full-endoscopic lateral recess decompression (TE-LRD)



Koji Matsumoto^a, Anoli Shah^b, Amey Kelkar^b, Dikshya Parajuli^b, Sushil Sudershan^b, Vijay K. Goel^{b,*}, Koichi Sairyo^c

^a Department of Orthopaedic Surgery, Nihon University Itabashi Hospital, 30-1 Oyaguchikaminami Itabashi-ku, Tokyo, 173-8610, Japan

^b Engineering Center for Orthopaedic Research Excellence (ECORE), Departments of Bioengineering and Orthopaedics surgery, Colleges of Engineering and Medicine, University of Toledo, OH, 43606, USA

^c Department of Orthopedics, Institute of Biomedical Sciences, Tokushima University Graduate School, 3-18-15 Kuramoto, Tokushima, 770-8503, Japan

ARTICLE INFO

ABSTRACT

Background: Transforaminal full endoscopic lateral recess decompression (TE-LRD) can decompress lateral recess stenosis transforaminally under the endoscopy procedure. However, the biomechanical effects of the TE-LRD compared to the conventional decompression techniques are not reported. The purpose of this study is to compare the biomechanical effects of TE-LRD with conventional decompression techniques using finite element method.

Methods: Three finite element models of lumbar functional spinal unit (FSU) of the L4-L5 levels were created: 1) normal disc 2) moderate grade disc degeneration 3) severe grade disc degeneration. For each of these three models, the following decompression techniques were simulated, 1) 50% TE-LRD, 2) 100% TE-LRD, 3) Unilateral laminectomy, 4) Bilateral laminectomy. The lower endplate of the fifth lumbar vertebra was fixed and 10Nm of moment in flexion/extension, left/right bending and axial rotation was applied to the upper endplate of the fourth lumbar vertebra, under a follower load of 400N. The range of motion, intervertebral disc stress, and facet joint stress were compared.

Results: 50% TE-LRD was found to be the most stable decompression technique in all intervertebral disc models. Though the increase in the range of motion of 100% TE-LRD was higher than other decompression techniques in the normal disc model, it was not significantly different from 50% TE-LRD or unilateral laminectomy techniques in the degenerated disc models. The increase in the intervertebral disc stress was lowest for the 50% TE-LRD surgery in all intervertebral disc models. The increase in the facet stresses for 50% TE-LRD was lower than in the conventional decompression techniques for all intervertebral disc models.

Conclusions: 50% TE-LRD was the decompression surgical technique with the least effect on spinal instability. 100% TE-LRD showed to be effective for cases with degenerative discs. 50% TE-LRD may decrease the risk of postoperative intervertebral disc and facet joint degeneration.

Background

Amongst the elderly population, lumbar spinal stenosis (LSS) is a very common ailment with an incidence rate of about 66% in the age range of 60–69 years [1]. LSS can be broadly defined as the narrowing of the spinal canal resulting in neurovascular impingement. LSS can be divided into two categories – central stenosis and lateral stenosis. Lateral stenosis can be further classified into two more subcategories – foraminal stenosis and lateral recess stenosis [1,2].

LSS was traditionally managed using conservative treatments like use of analgesics, spinal injections and physical therapy. In case of failure of mitigating the pathology with conservative means, open spinal decompression surgery with laminectomy and facetectomy has been typically performed with the use of general anesthesia [3,4].

Interlaminar decompression is a traditional approach for LSS. Unilateral laminectomy has been performed for unilateral recess stenosis and bilateral laminectomy has been performed for bilateral recess stenosis and central stenosis.

Abbreviations: TE-LRD, Transforaminal full-endoscopic lateral recess decompression; FSU, Functional spinal unit; LSS, Lumbar spinal stenosis; FED, Full-endoscopic decompression; ROM, Range of motion; HRQoL, Health related quality of life (HRQoL).

* Corresponding author.

E-mail address: Vijay.Goel@utoledo.edu (V.K. Goel).

<https://doi.org/10.1016/j.xnsj.2020.100045>

Received 9 November 2020; Received in revised form 9 December 2020; Accepted 11 December 2020

Available online 16 December 2020

2666-5484/© 2020 The Authors. Published by Elsevier Ltd on behalf of North American Spine Society. This is an open access article under the CC BY-NC-ND license (<http://creativecommons.org/licenses/by-nc-nd/4.0/>)

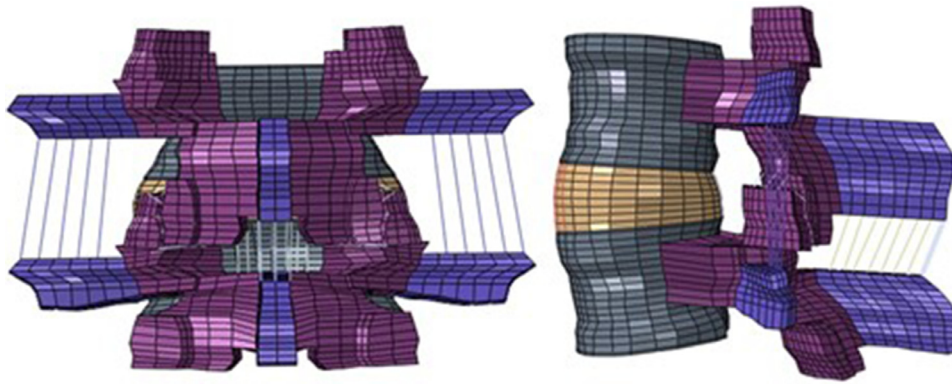


Fig. 1. Posterior and lateral views on a non-linear ligamentous validated finite element model of functional spinal unit of L4-L5.

Due to the development of high-speed drills, full-endoscopic decompression (FED) surgery has been recently established for LSS [5]. FED has enabled transforaminal approach as well as the conventional interlaminar approach for LSS. With this technique, under the guidance of the full-endoscopic view through the cannula, the herniated disc fragment was removed. Following this, a technique was developed to decompress the foraminal stenosis percutaneously with the full-endoscopic systems [6].

The transforaminal full-endoscopic lateral recess decompression (TE-LRD) was subsequently developed in 2017 [7,8]. This technique had the advantage of allowing the removal of the superior articular process transforaminally while enabling simultaneous decompression of foraminal and lateral recess stenosis. The major advantage of TE-LRD procedures is that the entire procedure was performed under local anesthesia [7–10].

With the above procedure, the patient can be awake during surgery and the surgical technique can help avoid serious nerve root damage. Since many of the elderly patients suffering from LSS have comorbidities, such as lung, heart and kidney dysfunctions, which limit the safety and effectiveness of an open surgical procedure performed under general anesthesia [11,12]. A minimally invasive decompression procedure may lead to lower medical complication rates in this vulnerable patient population.

TE-LRD has a different approach from the conventional decompression techniques as the lamina and ligamentum flavum were preserved in this procedure. This difference makes the postoperative spinal structure different compared to unilateral and bilateral decompression techniques. However, the biomechanical effects of the TE-LRD compared to the conventional decompression techniques have not been studied. The purpose of this study is to compare the performance of TE-LRD with conventional decompression techniques (unilateral and bilateral laminectomy) using finite element method with respect to annular stresses, facet stresses and range of motion. We hypothesize that since TE-LRD removes a smaller proportion of the posterior column, spinal instability and subsequent intervertebral disc stresses will be lower compared to conventional decompression techniques.

Methods

A nonlinear ligamentous finite element model of the L4-L5 functional spinal unit (FSU) was used in this study, Fig. 1. This normal spine model of L4-L5 was created in ABAQUS software (Dassault Systems, Johnston RI, USA). The geometric data was obtained from transverse CT scan images of a cadaveric spine and a three-dimensional model was created from this data. This model was then meshed using hexahedral shaped elements in ABAQUS.

The L4-L5 vertebral bodies were modelled as a cancellous bone core surrounded by a 0.5 mm thick cortical bone shell. A nine-degree lordotic angle was maintained between the L4-L5 vertebrae based on published

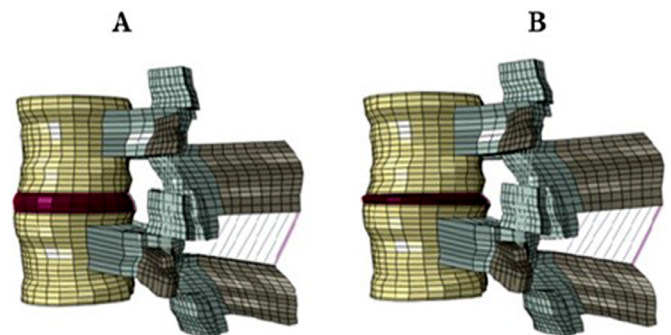


Fig. 2. A: Moderate grade disc degeneration model of non-linear ligamentous validated finite element model of L4-L5, B: Severe grade disc degeneration model of non-linear ligamentous validated finite element model of L4-L5.

anthropometric data [32]. The intervertebral disc was modelled as a combination of annulus and nucleus. The annulus was simulated as a composite solid with alternating $\pm 30^\circ$ collagen fibers modelled using REBAR elements with “no compression” allowed. Nucleus was simulated as a linearly elastic material. The facet joints were simulated using three-dimensional gap elements with an initial defined clearance of 0.5 mm. All ligamentous structures were simulated as hypoelastic materials. The material properties used in the model were obtained from published literature and are listed in Table 1 [13,14].

A majority of elderly patients with LSS have an associated lumbar disc degeneration of varying degrees. Therefore, models with moderate grade disc degeneration and severe grade disc degeneration were also created in this study.

The normal spine model was used as a template to produce the moderate grade and severe grade disc degeneration models, Fig. 2. The disc degeneration was performed by incrementally reducing the compressibility of the nucleus pulposus and the stiffness of annulus grounds as per studies conducted by Rohlmann et al and Schmidt et al [16,17]. The disc height was reduced for the disc degeneration models as described by the degenerated disc grading system established by Wilke et al [18]. The disc height was reduced by 50% and 80% for the moderate grade and severe grade disc degeneration models respectively. The disc elements were not remeshed but the height of the elements was uniformly reduced to reflect the change in height.

The decrease in disc heights lead to the buckling of ligaments and this change in length was compensated by simulating the offset of the nonlinear force-deflection curve as per Rohlmann et al and Schmidt et al [16,17]. The facet gap was also correspondingly reduced to account for the facet joint degeneration observed concurrent to the degenerative changes in the intervertebral disc. Similarly, the posterior ligament material properties (for posterior longitudinal ligament, interspinous ligament and supraspinous ligament) were altered to account for the de-

Table 1
Material Properties and element types used in the L4-L5 finite element model.

Bony Structure	Material model / element type	Young's modulus	Poisson's ratio
Cortical Bone	Isotropic, elastic / hexahedral elements	12000	0.3
Cancellous Bone	Isotropic, elastic / hexahedral elements	100	0.2
Intervertebral disc			
Annulus Ground Substance	Isotropic, Elastic / hexahedral elements	4.2	0.45
Annulus (fibers)	Rebar	357-550	0.3
Nucleus Pulposus	Incompressible, Isotropic, Elastic / hexahedral elements	9	0.4999
Ligaments			
Anterior Longitudinal	Tension-only, Truss elements	7.8(<12%), 20.0(>12%)	0.3
Posterior Longitudinal	Tension-only, Truss elements	10.0(<11%), 20.0(>11%)	0.3
Ligamentum Flavum	Tension-only, Truss elements	15.0(<6.2%), 19.5(>6.2%)	0.3
Intertransverse	Tension-only, Truss elements	10.0(<18%), 58.7(>18%)	0.3
Interspinous	Tension-only, Truss elements	10.0(<14%), 11.6(>14%)	0.3
Supraspinous	Tension-only, Truss elements	8.0(<20%), 15.0(>20%)	0.3
Capsular	Tension-only, Truss elements	7.5(<25%), 32.9(>25%)	0.3
Joint			
Apophyseal Joints	Non-linear Soft contact, GAPPUNI elements	—	—

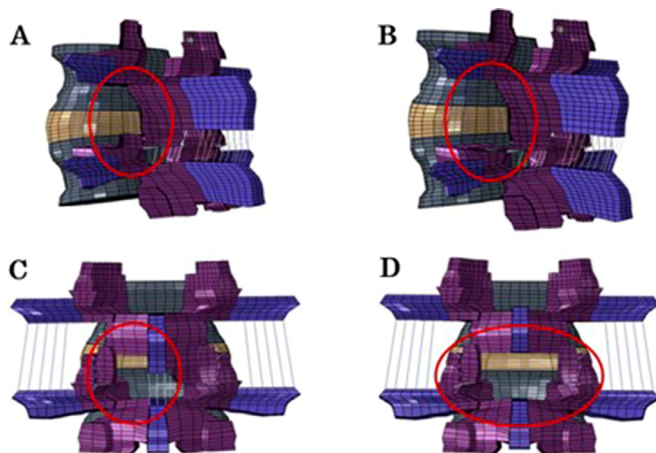


Fig. 3. A: 50% Transforaminal full endoscopic lateral recess decompression (TE-LRD), B: 100% Transforaminal full endoscopic lateral recess decompression (TE-LRD), C: Unilateral laminectomy, D: Bilateral laminectomy.

generative changes in posterior ligament complex. The material property of the annulus fibers was not altered for the disc degeneration models as per observations by Rohlmann et al and Schmidt et al [16,17].

For each of three models of the L4-L5 FSU, four types of decompression surgery were simulated as described below, Fig. 3. In total 12 models of decompression surgery cases were created for the evaluations.

50%. Transforaminal full endoscopic lateral recess decompression (TE-LRD) -

The ventral side of the facet joint was removed. 50% of superior articular process and the half of capsular ligaments were removed on the procedure side. The procedure side was left, Fig. 3A.

100% Transforaminal full endoscopic lateral recess decompression (TE-LRD)

The ventral side of the facet joint was removed. 100% of superior articular process and the capsular ligaments were removed on the procedure side. The procedure side was left, Fig. 3B.

Unilateral laminectomy

The medial parts of the facets and the adjacent lamina and the ligamentum flavum were removed on the procedure side. The procedure side is left, Fig. 3C.

Bilateral laminectomy

The medial parts of the facets and the adjacent lamina and the ligamentum flavum were removed on both sides. Supra- and interspinous ligaments and the half of spinous process were removed, Fig. 3D.

Model validation studies were undertaken to validate the normal disc, moderate grade disc degeneration and severe grade disc degeneration L4-L5 FSU models. The 10Nm of pure moment was applied to superior endplate of L4 vertebra and the inferior endplate of the L5 vertebra was fixed by constraining in all directions. The range of motion of the L4-L5 normal disc model in flexion/extension, left/right lateral bending and left/right axial rotation was computed and compared with the published data in literature by Panjabi et al [15]. The range of motion of the L4-L5 with moderate and severe grade disc degeneration for flexion/extension, left/right lateral bending and left/right axial rotation was computed and compared with the published data in literature by Mimura et al [19].

For each of the four decompression models with varying disc types, 10 Nm of pure moment along with 400 N preload (in flexion/extension, left/right lateral bending and left/right axial rotation) was applied to the superior endplate of the L4 vertebra and the inferior endplate of the L5 vertebra was fixed by constraining all directions.

Data analyses

The range of motion (ROM), peak von-mises stresses in the intervertebral disc (annulus) and facets were computed and compared between decompression techniques with different disc degenerations. The percentage change of stresses and range of motion for different decompression models were calculated with respect to the intact model with no decompression as a reference to study the comparison between the decompression techniques.

To study the overall effect of all the motions, the average of the motion data was used to compare between all the decompression techniques. To study the effects on overall facet stresses for the left and right side stresses were averaged for the comparison between different techniques.

Results

Finite element model validation for the L4-L5 FSU model

The normal L4-L5 FSU FE model exhibited a range of motion in flexion/extension, lateral bendings and axial rotations that was in the range of in-vitro data published by Panjabi et al [15], Fig. 4.

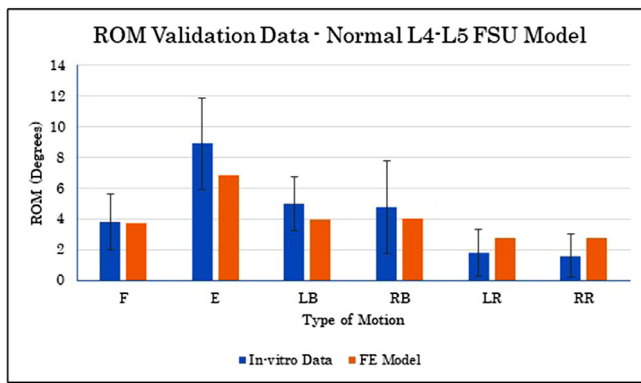


Fig. 4. Degenerated disc L4-L5 model ROM validation data: comparison of finite element results with in-vitro data.

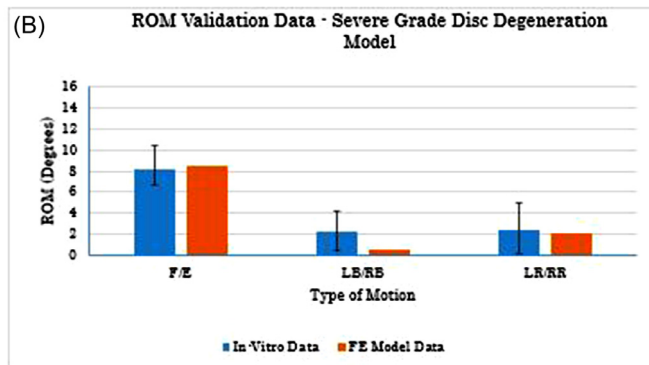
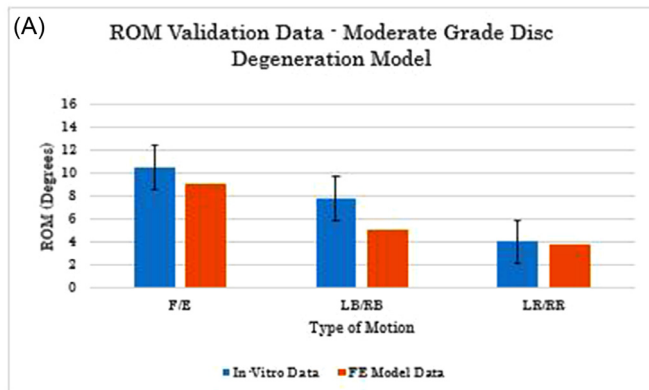


Fig. 5. Degenerated disc L4-L5 model ROM validation data: comparison of finite element results with in-vitro data – A: Moderate grade disc degeneration L4-L5 model, B: Severe grade disc degeneration L4-L5 model.

Finite element model validation for the degenerated disc models

The moderate disc degeneration models exhibited a reduced range of motion in flexion/extension and lateral bendings compared to the normal model. The range of motion reduced further when the degree of disc degeneration went from moderate to severe. For axial rotations, the range of motion increased for the moderate disc degeneration model when compared to the normal disc model. However, the range of motion decreased for the axial rotations when the degree of disc degeneration went from moderate to severe.

This trend agreed with the in-vitro data collected by Mimura et al who observed that the ROM decreased as the disc degeneration progressively worsened, Fig. 5A & 5B [19]. The only point where the data did not correlate was for moderate disc degeneration models for lateral bending ROM.

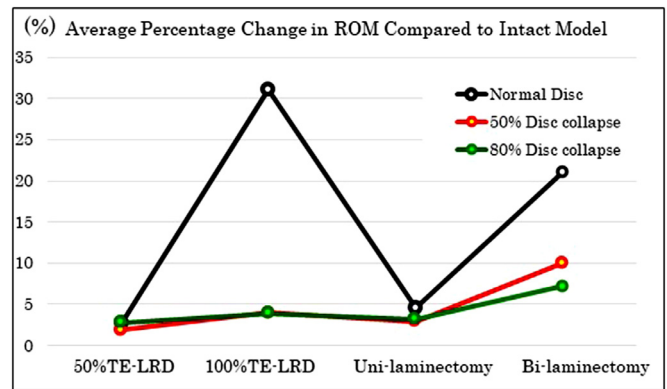


Fig. 6. Average percentage change in ROM for all decompression techniques compared to the ROM in intact L4-L5 model.

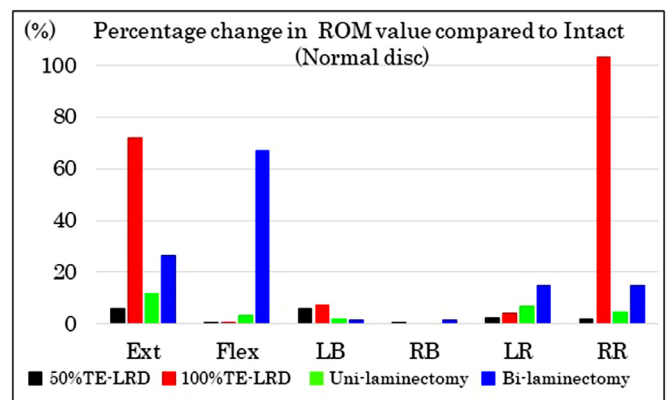


Fig. 7. Percentage change in ROM for all decompression techniques compared to intact in normal disc L4-L5 model, data normalized.

ROM data

Normal disc model

In the normal disc model, 50% transforaminal full endoscopic lateral recess decompression (TE-LRD) was the technique that least impaired the spinal stability, Fig. 6. The increase in the ROM for 50% TE-LRD was the smallest at flexion/extension and left/right axial rotations. However, the increase in the ROM for left/right lateral bending was greater for 50% TE-LRD than in the conventional decompression techniques, Fig. 7. In this case, the bending ROM on the decompression side was higher than on the contralateral side.

In the normal disc model, the average ROM in six directions for 100% TE-LRD increased by 31.1% compared to intact. It was the decompression technique that impaired the spinal stability most, Fig. 6. The increase in ROM for 100% TE-LRD was highest in extension, left lateral bending and right axial rotation, Fig. 7.

Moderate grade disc degeneration model

In the moderate grade disc degeneration model, the average ROM in six directions for the 50% TE-LRD case increased by 1.7% compared to intact. This decompression technique impaired the spinal stability by the least value, Fig. 6. 50% TE-LRD was more stable in flexion/extension and the axial rotations compared to other techniques. Like the normal disc models, 50% TE-LRD showed more instability than the other decompression techniques in lateral bending with a higher ROM on the decompression side than on the contralateral side, Fig. 8.

In the moderate grade disc degeneration model, the average ROM in six directions for the 100% TE-LRD case increased by 4% compared to intact. 100% TE-LRD was the decompression technique that impaired

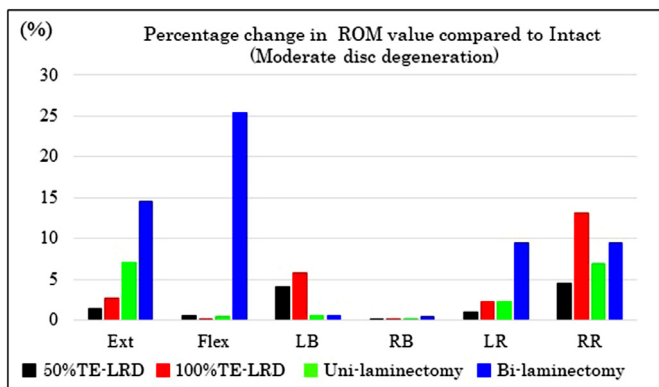


Fig. 8. Percentage change in ROM for all decompression techniques compared to intact in moderate grade disc degeneration L4-L5 model.

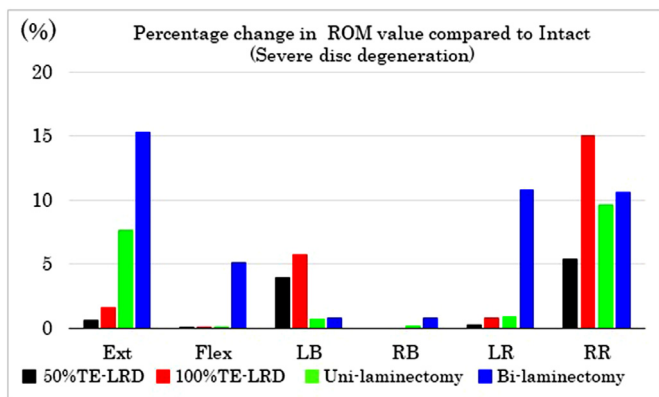


Figure 9. Percentage change in ROM for all decompression techniques compared to intact in severe grade disc degeneration L4-L5 model

the spinal stability the most along with bilateral laminectomy, Fig. 6. The increase in the ROM for the 100% TE-LRD case was the highest at left lateral bending and right axial rotation, Fig. 8.

Severe grade disc degeneration model

In the severe grade disc degeneration model, the average ROM in six directions for the 50% TE-LRD case increased by 2.8% compared to intact. This decompression technique impaired the spinal stability by the least value, Fig. 6. 50% TE-LRD was more stable in flexion/extension and the axial rotations compared to other techniques. Similar to the normal disc models, 50% TE-LRD showed more instability than the other decompression techniques in lateral bending with a higher ROM on the decompression side than on the contralateral side, Fig. 9.

The average ROM in six directions for the 100% TE-LRD increased by 3.9% compared to intact. 100% TE-LRD was the decompression technique that impaired the spinal stability the most along with bilateral laminectomy, Fig. 6. The increase in the ROM for the 100% TE-LRD case was the highest at left lateral bending and right axial rotation, Fig. 9.

The 50% TE-LRD was the decompression technique which least impaired the spinal stability in all decompression technique models. Lateral bending on the decompression side, the stability was impaired irrespective of the decompression technique. Though 100% TE-LRD was the decompression technique which impaired spinal stability most in all models, the increase in the ROM was not that different from either 50% TE-LRD or unilateral laminectomy and it was smaller than bilateral laminectomy in both the degenerative disc models. In the Normal disc models, the difference in the increase in ROM between the surgical procedures was large, but as the disc degeneration progressed, the

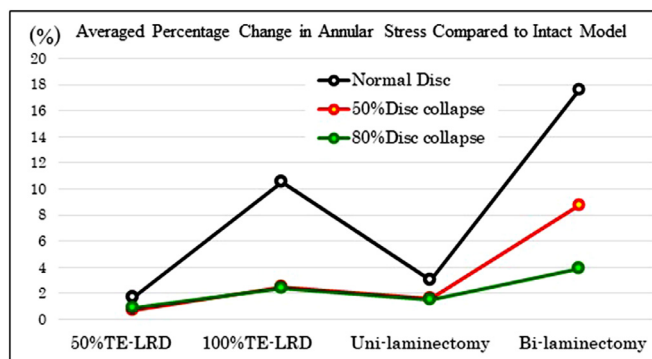


Fig. 10. Average percentage change in annular stresses for all decompression techniques compared to intact L4-L5 model.

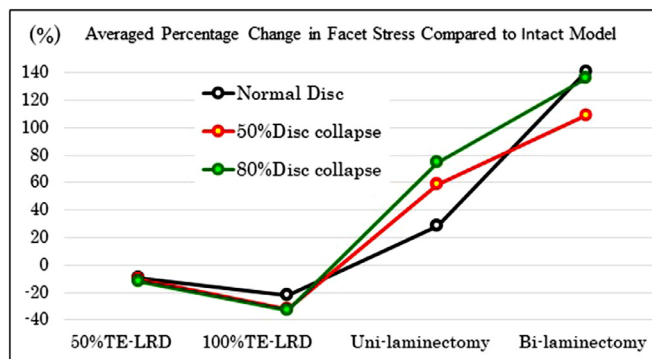


Fig. 11. Average percentage change in facet stresses for all decompression techniques compared to intact L4-L5 model.

difference in the increase in the ROM among the surgical procedures reduced, Fig. 6.

Intervertebral disc (Annular) stresses

50% TE-LRD was the decompression technique which increased the intervertebral disc (Annular) stresses by the least amount in all intervertebral disc models. 100% TE-LRD was the decompression technique that had the largest increase in the intervertebral disc stress along with bilateral laminectomy.

Though 100% TE-LRD was the decompression technique increased the intervertebral disc stresses, the increase in the disc stresses was not much different when compared to 50% TE-LRD or unilateral laminectomy for the normal disc models and it was smaller than bilateral laminectomy in both the degenerative disc models, Fig. 10.

Facet joint stresses

The peak von Mises facet stresses for both the left and right facets were computed and the average was calculated. 50% TE-LRD increased facet stresses compared to intact in all intervertebral disc models.

The increase in the facet stress for 50% TE-LRD models were smaller than the conventional decompression techniques, Fig. 11.

Discussion

Transforaminal full-endoscopic lateral recess decompression (TE-LRD) is a newly established decompression technique first devised in 2017. Initial clinical results have indicated that TE-LRD have similar effectiveness when compared to contemporary open decompression techniques.

Shuo et al performed a retrospective clinical analysis on a group of patients who were treated for lateral recess stenosis using percutaneous partial decompression surgery and found improvement comparable to

the conventional decompression techniques in terms of pain improvement scores and health related quality of life (HRQoL) over a period of 12 months post-surgery [20]. Kapetanakis et al also saw very good clinical outcomes in terms of pain scores and HRQoL scores in elderly patient group who were treated for lateral recess stenosis for a period of up to 24 months after the initial surgery [21,22]. Zhang et al observed that percutaneous transforaminal surgery for lateral recess stenosis for the elderly was very effective in terms of clinical effects when the Oswestry disability index (OD) and visual analogue scale (VAS) scores were analyzed over a period of up to 38 months post-surgery [23].

However, since TE-LRD is a recently reported new decompression technique, there is no documented research on the biomechanics of this technique.

The biomechanical effects for conventional decompression techniques such as facetectomy and laminectomy that have been used for lumbosacral stenosis are well documented in literature [24–26]. The use of finite element analyses to study the effect of resections of posterior bony or ligamentous structures as done in facetectomy and laminectomy procedures also have a history in literature [27–29]. The finite element model simulations help in providing a theoretical reference for a clinical practice [30]. Therefore, finite element analyses tool was utilized to assess the biomechanics of the TE-LRD technique.

The current study showed that 50% TE-LRD was the decompression technique which least impaired the spinal stability in all intervertebral disc models. This can be attributed to complete preservation of the inferior articular process and can be considered to be the most reasonable operation technique that can selectively decompress bone tissue involved in stenosis. This result holds the possibility of 50% TE-LRD being able to cope with cases that have been considered to require fixation until now. Even with 50% resection of the superior articular process, less instability was observed compared to conventional decompression techniques.

Taking into consideration that the difference in the ROM between the different decompression surgical techniques, 50% TE-LRD can be recommended as a more effective technique in normal and degenerated disc cases. In addition, 50% TE-LRD was the technique with the smallest increase in disc stresses across all decompression techniques and thus it could be considered to minimize post-surgical disc degeneration. Increase in facet stresses for 50% TE-LRD was also smaller than the conventional decompression techniques. Thus, it could be inferred that 50% TE-LRD could delay the postoperative facet joint degeneration than the conventional decompression techniques.

Though 100% TE-LRD was the decompression technique which impaired spinal stability most in normal disc, it was observed to be as stable as 50% TE-LRD or unilateral laminectomy and more stable than bilateral laminectomy in degenerative disc models. These results demonstrate that 100% TE-LRD could be an effective technique for LSS decompression in patients with degenerate discs.

However, in lateral bending and axial rotation, the stability was lost on the decompression side with both 50% and 100% TE-LRD when compared with the conventional decompression techniques, which indicated that the superior articular process is an important stabilizer in bending on the decompression side. The literature suggests that the laminectomy might cause potential spinal instability and the adequate preservation of the partial lamina, spinous process, and supraspinous and interspinous ligaments during laminectomy may be critical to alleviate the stress concentration of the disc in flexion [27,28]. On the other hand, both TE-LRD surgeries did not appear to destabilize in flexion. This indicates that the superior articular process does not function as a stabilizer in flexion.

It is considered that the inclination of the facet joint of the lumbar vertebrae is greatly related to the difference in the range of motion [31]. As the inclination of the facet joint differs in the upper lumbar vertebrae when compared to the lower lumbar vertebrae, whether the result of this study can be translated to other motion segments is yet unknown. Therefore, it can be considered as a limitation of this study and the results may be different in the upper lumbar vertebrae with different

inclinations of facet joint. The model used of a single FSU with one anatomy, so it did not take the whole thoracolumbar spine alignment into an account. Therefore, the biomechanical effects of multi-level TE-LRD were not analyzed for this comparison. The use of a single FSU finite element model also limited us from studying the effects of TE-LRD on the adjacent segment biomechanics.

Various studies have shown that using the inter-body fusion have shown to create a fusion and lead adjacent segment diseases. And the decompression techniques like facetectomy and laminectomy tend to alleviate the adjacent segment disease pain but may lead to the instability. This study explains the biomechanics of the novel TE-LRD decompression technique that will help the surgeons to choose a suitable decompression technique for the patients and to avoid these complications.

Conclusion

The 50% Transforaminal full endoscopic lateral recess decompression (TE-LRD) was the decompression surgery that impaired the spinal stability the least. Even 100% TE-LRD may be effective for cases with degenerative disc. This makes TE-LRD not only a minimally invasive operation that can be performed using local anesthesia, but also a procedure with biomechanical advantages. The results of this study provide useful information to the surgeons that may help determining an optimal decompression surgical method based on the patient profile.

Declaration of Competing Interest

The authors declare that they have no known competing financial interests or personal relationships that could have appeared to influence the work reported in this paper.

Funding disclosure statement

Work supported in part by the NSF Industry/University Cooperative Research Center, University of California at San Francisco, University of Toledo and Ohio State University.

References

- [1] Kalichman L, Cole R, Kim DH, et al. Spinal stenosis prevalence and association with symptoms: the Framingham Study. *Spine J* 2009;9(7):545–50.
- [2] Lurie J, Tomkins-Lane C. Management of lumbar spinal stenosis. *BMJ* 2016;352:h6234.
- [3] Atlas SJ, Keller RB, Robson D, Deyo RA, Singer DE. Surgical and nonsurgical management of lumbar spinal stenosis: four-year outcomes from the maine lumbar spine study. *Spine (Phila Pa 1976)* 2000;25(5):556–62.
- [4] Postacchini F. Surgical management of lumbar spinal stenosis. *Spine (Phila Pa 1976)* 1999;24(10):1043–7.
- [5] Yeung AT. The evolution of percutaneous spinal endoscopy and discectomy: state of the art. *Mt Sinai J Med* 2000;67(4):327–32.
- [6] Ahn Y, Oh HK, Kim H, Lee SH, Lee HN. Percutaneous endoscopic lumbar foraminotomy: an advanced surgical technique and clinical outcomes. *Neurosurgery* 2014;75(2):124–33 discussion 32–3.
- [7] Sairyo K, Higashino K, Yamashita K, et al. A new concept of transforaminal ventral facetectomy including simultaneous decompression of foraminal and lateral recess stenosis: Technical considerations in a fresh cadaver model and a literature review. *J Med Invest* 2017;64(1.2):1–6.
- [8] Sairyo K, Yamashita K, Manabe H, et al. A novel surgical concept of transforaminal full-endoscopic lumbar undercutting laminectomy (TE-LUL) for central canal stenosis of the lumbar spine with local anesthesia: a case report and literature review. *J Med Invest* 2019;66(3.4):224–9.
- [9] Sairyo K, Egawa H, Matsuura T, et al. State of the art: transforaminal approach for percutaneous endoscopic lumbar discectomy under local anesthesia. *J Med Invest* 2014;61(3-4):217–25.
- [10] Li Y, Wang B, Wang S, Li P, Jiang B. Full-endoscopic decompression for lumbar lateral recess stenosis via an interlaminar approach versus a transforaminal approach. *World Neurosurg* 2019;128:e632 e8.
- [11] Neufeld KJ, Leoutsakos JS, Sieber FE, et al. Evaluation of two delirium screening tools for detecting post-operative delirium in the elderly. *Br J Anaesth* 2013;111(4):612–18.
- [12] Seymour DG, Vaz FG. A prospective study of elderly general surgical patients: II. Post-operative complications. *Age Ageing* 1989;18(5):316–26.
- [13] Goel VK, Kiapour A, Faizan A, Krishna M, Friesem T. Finite element study of matched paired posterior disc implant and dynamic stabilizer (360° motion preservation system). *SAS J* 2007;1(1):55–61.

- [14] Ivanov A, Faizan A, Sairyo K, Ebraheim N, Biyani A, Goel VK. Minimally invasive decompression for lumbar spinal canal stenosis in younger age patients could lead to higher stresses in the remaining neural arch – a finite element investigation. *Minim Invasive Neurosurg* 2007;50(1):18–22.
- [15] Panjabi MM, Oxland TR, Yamamoto I, Crisco JJ. Mechanical behavior of the human lumbar and lumbosacral spine as shown by three-dimensional load-displacement curves. *J Bone Joint Surg Am* 1994;76(3):413–24.
- [16] Rohlmann A, Zander T, Schmidt H, Wilke HJ, Bergmann G. Analysis of the influence of disc degeneration on the mechanical behaviour of a lumbar motion segment using the finite element method. *J Biomech* 2006;39(13):2484–90.
- [17] Schmidt H, Kettler A, Rohlmann A, Claes L, Wilke HJ. The risk of disc prolapses with complex loading in different degrees of disc degeneration - a finite element analysis. *Clin Biomech (Bristol, Avon)* 2007;22(9):988–98.
- [18] Wilke HJ, Rohlmann F, Neidlinger-Wilke C, Werner K, Claes L, Kettler A. Validity and interobserver agreement of a new radiographic grading system for intervertebral disc degeneration: Part I. Lumbar spine. *Eur Spine J* 2006;15(6):720–30.
- [19] Mimura M, Panjabi MM, Oxland TR, Crisco JJ, Yamamoto I, Vasavada A. Disc degeneration affects the multidirectional flexibility of the lumbar spine. *Spine (Phila Pa 1976)* 1994;19(12):1371–80.
- [20] Tang S, Jin S, Liao X, Huang K, Luo J, Zhu T. Transforaminal percutaneous endoscopic lumbar decompression by using rigid bendable burr for lumbar lateral recess stenosis: technique and clinical outcome. *Biomed Res Int* 2018;2018:2601232.
- [21] Kapetanakis S, Gkantsinikoudis N, Papathanasiou JV, Charitoudis G, Thomaidis T. Percutaneous endoscopic ventral facetectomy: an innovative substitute of open decompression surgery for lateral recess stenosis surgical treatment? *J Craniovertebr Junction Spine* 2018;9(3):188–95.
- [22] Kapetanakis S, Gkantsinikoudis N, Thomaidis T, Charitoudis G, Theodosiadis P. The role of percutaneous transforaminal endoscopic surgery in lateral recess stenosis in elderly patients. *Asian Spine J* 2019;13(4):638–47.
- [23] Zhang SM, Wu GN, Jin J, et al. Application of broad easy immediate surgery in percutaneous transforaminal endoscopic technology for lumbar lateral recess stenosis in the elderly. *Zhongguo Gu Shang* 2018;31(4):317–21.
- [24] Yeung AT. The Evolution and advancement of endoscopic foraminal surgery: one surgeon's experience incorporating adjunctive technologies. *SAS J* 2007;1(3):108–17.
- [25] Zander T, Rohlmann A, Klockner C, Bergmann G. Influence of graded facetectomy and laminectomy on spinal biomechanics. *Eur Spine J* 2003;12(4):427–34.
- [26] Zeng ZL, Zhu R, Wu YC, et al. Effect of graded facetectomy on lumbar biomechanics. *J Healthc Eng* 2017;2017:7981513.
- [27] Chen CS, Feng CK, Cheng CK, Tzeng MJ, Liu CL, Chen WJ. Biomechanical analysis of the disc adjacent to posterolateral fusion with laminectomy in lumbar spine. *J Spinal Disord Tech* 2005;18(1):58–65.
- [28] Lee KK, Teo EC. Effects of laminectomy and facetectomy on the stability of the lumbar motion segment. *Med Eng Phys* 2004;26(3):183–92.
- [29] Bresnahan L, Ogden AT, Natarajan RN, Fessler RG. A biomechanical evaluation of graded posterior element removal for treatment of lumbar stenosis: comparison of a minimally invasive approach with two standard laminectomy techniques. *Spine (Phila Pa 1976)* 2009;34(1):17–23.
- [30] Song M, Zhang Z, Lu M, et al. Four lateral mass screw fixation techniques in lower cervical spine following laminectomy: a finite element analysis study of stress distribution. *Biomed Eng Online* 2014;13:115.
- [31] Kozanek M, Wang S, Passias PG, et al. Range of motion and orientation of the lumbar facet joints in vivo. *Spine (Phila Pa 1976)* 2009;34(19):E689–96.
- [32] Panjabi MM, White AA. *Clinical biomechanics of the spine*; 1990.