



Case report

Pleural loculated empyema masking a CPAM 3 in a newborn infant: A case report with brief literature review

G. Dilorenzo^{a,*}, E. Salinaro^b, V. Favia^a, S. Pavone^b, P. Drimaco^c, N. Laforgia^c, G. Angelelli^a, A.A. Stabile Ianora^a^a DIM, Interdisciplinary Department of Medicine, Section of Diagnostic Imaging, Aldo Moro University of Bari Medical School, Piazza Giulio Cesare 11, 70124, Bari (BA), Italy^b Department of Radiology, Di Venere Hospital, Via Ospedale di Venere 1, 70012, Bari (BA), Italy^c Neonatology and Neonatal Intensive Care Unit, Department of Biomedical Sciences and Human Oncology, University of Bari, Piazza Giulio Cesare 11, 70124, Bari (BA), Italy

A B S T R A C T

Congenital pulmonary airway malformations (CPAMs) are a heterogeneous group of hamartomatous cystic and noncystic lung lesions that result from early airway maldevelopment. Usually they are distinguished according to Stocker's classification in type 0, 1, 2, 3 and 4.

We present the case of a 2 weeks old baby who was admitted to hospital with RDS symptoms and left pleural effusion: X rays and CT were suggestive for a pulmonary cystic lesion with pleural complications. Because of the persistence of pleural empyema and the development of a pneumothorax the baby underwent surgery. The histological examination revealed a type 3 CPAM associated with pleural loculated empyema.

According to this case, in newborns with RDS loculated pleural empyema may mimic pulmonary cystic lesions; a treatment-resistant pleural empyema or pyopneumothorax in a newborn can recognize a CPAM 3 as a probable underlying condition, even in the absence of lung suppurative changes; CPAM 3 involving only two lung segments can have an excellent prognosis after surgical excision.

1. Introduction

Congenital pulmonary airway malformations (CPAMs) are a heterogeneous group of cystic and noncystic lung lesions that largely result from early airway maldevelopment. They are considered hamartomatous lung lesions containing tissue from different pulmonary origins and represent a rare entity, with a reported incidence ranging from 1:10,000 to 1:35,000 newborns [1,2]. They were first described as Congenital Cystic Adenomatous Malformations (CCAMs) in 1949 by Chin and Tang [3], while the microscopic criteria for the diagnosis were first summarized by Kwittken and Reiner in 1962 [4]. Only in 1977 this malformations were classified by Stocker et al. [5] into three main types (type 1, type 2, type 3) according to cystic size and pathological features, namely the histologic resemblance of the hamartomatous components of the lesions to the normal tissues of the developing tracheobronchial tree and airspaces; they also suggested prognosis [5,6]. In 2002 Stocker himself revised this classification by adding two more types (type 0, type 4) and changing the name from CCAM to CPAM. The term congenital pulmonary airway malformation has been recommended as preferable to the term congenital cystic adenomatoid malformation, since the lesions are cystic in only type 1,2 and 4, and adenomatoid in only one type, i.e. type 3 lesion [1,7,8].

Other classifications have been proposed, but Stocker's revised one remains the most accepted in the literature.

It consists of the following categories:

- Type 0 represents 1–3% of total CPAMs and originates from trachea and main bronchi. Its gross appearance is solid: lungs are small and firm throughout. Microscopy shows tracheo-bronchial airways with cartilage, smooth muscle and glands separated by abundant mesenchymal tissue. This form is often associated with other complex malformations and is almost incompatible with life.
- Type 1 is the commonest one, being 60–70% of total CPAMs. It originates from distal bronchi and proximal bronchioles, and has a macrocystic gross appearance, with one or more large cysts > 2 cm in diameter (up to 10 cm and more in some cases). The cysts are lined by pseudostratified ciliated cells often interspersed with rows of mucous cells. Clinical manifestations is in 70–80% of cases occurs as respiratory distress in neonates, but in 10% of cases can be late in infants during first year of life due to complicated cysts (infection, pneumothorax, mass effect); the remnant cases remain asymptomatic and are often occasionally diagnosed in adult. In its neonatal manifestation, this type has a good prognosis after surgical resection.

* Corresponding author.

E-mail address: giuseppedlr@live.it (G. Dilorenzo).

- Type 2 represents 10–15% of total CPAMs, has a distal bronchiolar origin and a sponge-like macroscopic appearance due to multiple, small (0.5–2-cm in diameter) cysts. On histological examination cysts resemble dilated bronchioles lined by cuboid/columnar epithelium with a thin fibromuscular wall. Its prognosis is very poor because of frequent association with renal, cardiovascular and gastrointestinal malformations.
- Type 3 is the rarest form among CPAMs (5% of all CPAMs), originating from respiratory bronchioles and alveolar ducts and characterized by multiple microcysts (< 0.2 cm). It usually appears at gross pathology as one/multiple large bulky solid lesions; histology shows microcystic airspaces lined by cuboidal epithelium (“fetal lung”) separating excess of normal bronchiolar structures. Typical it becomes symptomatic early in neonatal age and has poor prognosis, even if it depends on the grade of secondary pulmonary hypoplasia of non affected lung and mediastinal dislocation/deformation.
- Type 4 accounts for 10–15% of CPAMs, has a distal acinar origin, appearing as a large macrocystic lesion, with large cysts (> 10 cm) lined by flattened epithelium resting on loose mesenchymal tissue. The diagnosis is usually made in neonates and infants, and resembles type I lesion prognosis after surgical resection.

Prenatal diagnosis is generally achieved during the second trimester of pregnancy using high resolution ultrasound (US) [9], but prenatal US becomes less sensitive in diagnosing lung cysts with advancing pregnancy due to the loss of the fluid-tissue interfaces. Imaging evaluation (chest X-ray and computed tomography (CT)) and clinical follow-up after birth is required in all cases to confirm the diagnosis and to initiate adequate treatment [10].

The natural history of these fetal lung masses is variable and the overall prognosis depends on the size of the lesions and on the grade of the secondary physiologic derangement caused by compression from the masses on surrounding structures [11].

At birth the 80% of the affected is asymptomatic. When no prenatal diagnosis is made, children may remain asymptomatic or may present, later in their lives, respiratory distress symptoms, complications of recurrent pneumonias or spontaneous pneumothorax [12].

Only three types of CPAMs are distinguished at imaging: large cyst CPAM (type 1) and small cyst CPAM (type 2), which constitute macrocystic CPAMs; and microcystic or solid type (type 3) lesions, which have cysts that are smaller than 5 mm in diameter, with no discernible cystic spaces. Type 4 (Stocker classification) [8] usually appears as the large cyst type at imaging and is indistinguishable from a predominantly cystic pleuropulmonary blastoma. A CPAM may communicate with the proximal airways, although this communication is abnormal. Most CPAMs derive their blood supply from the pulmonary artery and drain via the pulmonary veins, with the exception of hybrid lesions, which can have a systemic blood supply. Postnatal radiography shows variable density in the region of the mass depending on the fluid contents of the cysts and, possibly, mediastinal shift, depending on the size of the CPAM. In the neonatal period, a large cyst CPAM may be seen as a round soft-tissue mass that gradually becomes filled with air, since there is delayed clearance of fetal lung fluid from the cysts through the abnormal airway. It may be seen as a solitary well-defined air-filled cyst with thin walls or as multiple cysts of varying size. Air-fluid levels may be identified. Postnatally, cross-sectional imaging usually takes the form of CT, which is optimal for detailed depiction of the lung parenchyma and airway and these lesions will be readily detectable as well-defined air-filled spaces [1].

Surgical resection is required for symptomatic lesions, while the treatment of asymptomatic malformations remains controversial. Early surgical intervention avoids infection that might lead to a difficult dissection or prolonged hospital course; pulmonary resections in infants have been shown to be well tolerated and carry a relatively low morbidity [13].

According to this case, a treatment-resistant pleural empyema or

pyopneumothorax in a newborn can recognize a CPAM 3 as a probable underlying condition, even in the absence of lung suppurative changes; CPAM 3 involving only two lung segments can have an excellent prognosis after surgical excision.

2. Presentation of case

A full-term male, 2 weeks old, born by spontaneous delivery, was taken to hospital because of sudden onset of fever and was admitted to neonatal intensive care unit (NICU). At this time clinical and laboratory tests (C-reactive protein [CRP] = 9.39mg/l, procalcitonin [PCT] = 4,66 mg/l WBC 31.700/mm³, neutrophiles 79%) evidenced a sepsis so the baby started antibiotic therapy with Ampicillin and Netilmicin.

In a few hours general conditions got worst (C-reactive protein [CRP] = 33,7 mg/l, procalcitonin [PCT] = 50,6 mg/l, WBC 47.500/mm³, neutrophiles 81%) as the child developed the symptoms of respiratory distress syndrome (RDS), so he was intubated and started mechanical ventilation. X-rays of the chest and lung US examination were performed. They revealed the presence of a left pleural effusion together with a multicystic air-filled lesion at left pulmonary lower lobe with mediastinal shift to the right and hypoexpansion of the ipsilateral lung; bilateral radiological signs of RDS were also present (Fig. 1).

Left thoracentesis (70 cc) was then performed, but pleural fluid culture and physical/chemical examination resulted negative.

A second chest radiograph was performed because of further increasing of respiratory symptoms: it showed a left hypertensive pneumothorax (PTX) (Fig. 2) that was treated and partially solved by inserting a gravity chest drainage (Fig. 3).

As the patient was undergoing mechanical ventilation, the cause of hypertensive PTX was supposed to be a communication between peripheral airways, the cystic lesion and the pleural space (inner PTX), powered by the positive pressure of the mechanical ventilation itself.

At this time neonatologists decided to modify again the antibiotic therapy by shifting to Teicoplanin-Amikacin and performed a lumbar puncture, but cerebrospinal fluid (CSF) culture and chemical-physical examination resulted negative too.

A CT scan of the chest was then performed in emergency and without contrast medium administration due to the patient's poor clinical conditions, in order to map more precisely the pathological pattern. The exam confirmed the presence of a coarse (4 cm) air-filled lesion with thick irregular walls at the apical segment (VI) of the left lower lobe, that determined contralateral shift of the mediastinum;

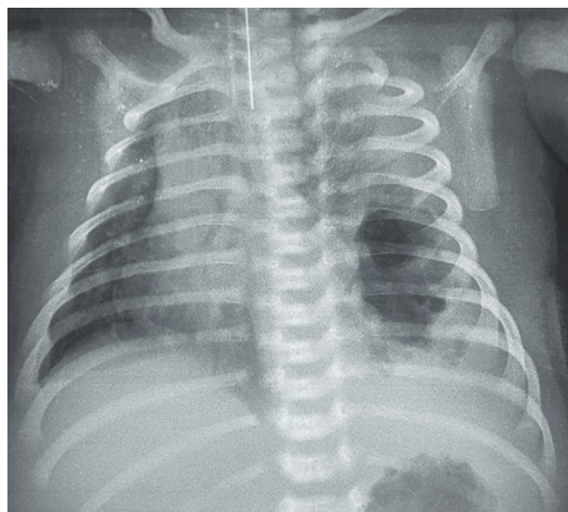


Fig. 1. Plain film of the chest. Left pleural effusion and multicystic air-filled lesion at left pulmonary lower lobe with mediastinal shift to the right and hypoexpansion of the lung; bilateral radiological signs of RDS.

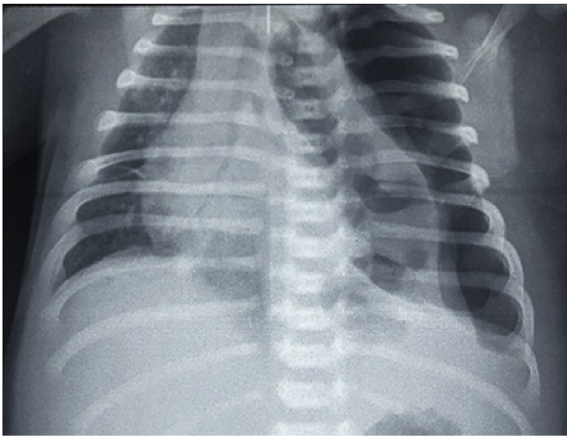


Fig. 2. Plain film of the chest. Left hypertensive pneumothorax.

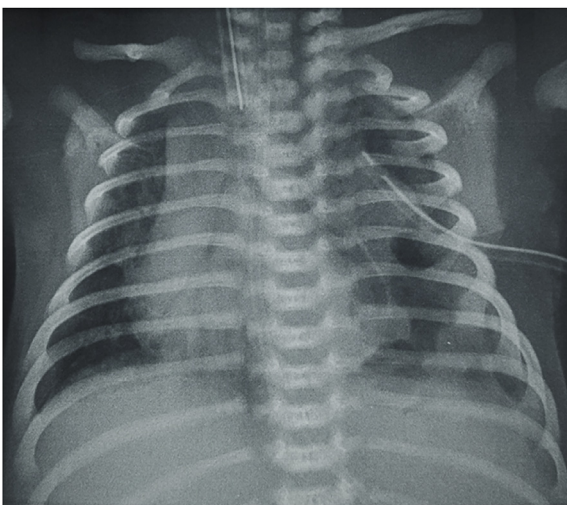


Fig. 3. Plain film of the chest. Partial resolution of the hypertensive pneumothorax after left pleural tube insertion.

moreover it evidenced the persistence of the left PTX. A suspected communication between the lesion and the left pleural space was observed, but it wasn't certain. Pulmonary consolidations with air bronchograms surrounding the lesion and widespread among ipsi and contralateral lung were also demonstrated, compatible with RDS clinical setting (Fig. 4).

The child was then transferred to our University Center NICU with endotracheal tube and left pleural drainage and started intravenous therapy with Meropenem, Vancomycin and Perfalgan. After a few days the endotracheal tube was removed and the baby started high flow oxygen therapy. Given the observation of a minimal clinical improvement and in order to supply the thoracic surgeons with a clear pre-operative lung mapping, an imaging completion with CT scan after endovenous contrast medium administration was performed at 19 days from the first one. It evidenced the persistence of the cystic lesion that now showed thin walls and mixed air-fluid levels; the lesion was broader, extended from VI segment to basal an lateral regions of the same lobe, compressing segments IX and X. The angle formed by the lesion and the pleura was acute (45°), mimicking a lung origin, but the split pleura sign was also present with an acute folding of visceral pleura on both sides, suggesting the hypothesis of a loculated pleural empyema; no aberrant arterial supply from the descending aorta was demonstrated. At this time bilateral consolidations were almost completely solved, but hydro-PTX persisted in the antero-basal zone, with no clear cleavage plan from the lesion, that lied superiorly (Fig. 5).

Ten days later, because of the persistence of bad clinical conditions, a multi-disciplinary team composed by neonatologists, radiologists and pediatric surgeons, unanimously proposed to proceed to left lung surgery. The baby underwent thoracotomy at the 5th left intercostal space with exeresis of segment IX and X and of a cystic lesion of segment VI (Fig. 6). Gross surgical sample revealed a cystic lesion measuring 6×2.5 cm and pleuro-pulmonary fragments measuring from 0.5 to 3.5 cm in length. Microscopic examination of the fragments showed signs of chronic-aspecific pleuritis, atelectasis of the adjacent lung with hypoaerectasis and flogistic infiltration, bronchiectasis and small alveolar spaces lined by cuboidal epithelium (bronchiar-like). The cystic lesion was interpreted as a loculated pleural empyema. Overall symptoms, in correlation with clinical and radiological findings, were consistent with type 3 CPAM (Stocker's classification) associated with pleural loculated empyema.

In the two weeks following surgery the baby showed quick and progressive clinical improvement: inflammation markers and leukocytosis got normal, endotracheal, nasogastric and drainage tubes were removed. On the second post-operative day the patient regained spontaneous breathing and from the seventh to the fourteenth day he underwent full enteral feeding by increasing volumes of milk; then he was discharged in healthy condition.

Neonatologists and thoracic surgeons asked for a chest-CT control exactly one year after surgery, that was performed without the e. v. injection of contrast medium, and showed a complete resolution: in fact re-expansion of the residual segments of the left lower lobe was observed, and there was no more evidence of parenchymal consolidations, cavitating lesions, PTX or pleural effusions. The only evidence of par-enchymal and pleural scarring was represented by a little number of dense fibrotic bands and traction bronchiectasis (Fig. 7).

3. Discussion

Among CPAMs, type 3 lesions are the rarest ones (frequency 5–10%). They occur almost exclusively in males and correspond to the 'original' congenital adenomatoid malformation described by Chin and Tang in 1949 [14]. The lesion generally appears as a large bulky mass that produces mediastinal shift and compression of adjacent lung, which is hypoplastic. The infants with this lesion may be stillborn or develop severe respiratory distress shortly after birth [8].

In the reported case the symptoms of RDS suddenly appeared about 15 days after birth. X rays and first CT scan (acquired without contrast medium administration because of bad general conditions of the patient) evidenced a broad air-filled lesion in the left lower lobe without the typical features of cysts, because of thick and lobulated margins, and not clearly distinguishable from the surrounding consolidated lung.

Differential diagnosis of cystic lesions in neonates and young children include congenital cystic bronchopulmonary malformations, neoplastic conditions, infections, collagen or soft tissue abnormalities, but also mimics [15].

We excluded diaphragmatic hernia (left diaphragm was intact) and bronchogenic cysts because they are smaller in size, isolated and have a homogeneous fluid content: moreover, even if complicated, they do not justify a lung involvement as widespread as the one we observed.

Lobar atresia and congenital lobar emphysema were not taken into consideration because they do not induce such an extensive pulmonary disruption.

In our opinion, the first and more consistent diagnosis, considering the age of onset, the septic clinical setting and the RDS symptoms, seemed to be that of CPAM. We hypothesized a type 1 or 4 (macrocystic variants, compatible with the broad air-filled lesion): it should have been the moving cause, complicated with an infection and the opening into the pleural space that could have explained the associated pleural effusion and the PTX. The presence of a subtle communication with the pleural space seemed a significant detail in order to justify the development of a hypertensive PTX (barotrauma) at the beginning of

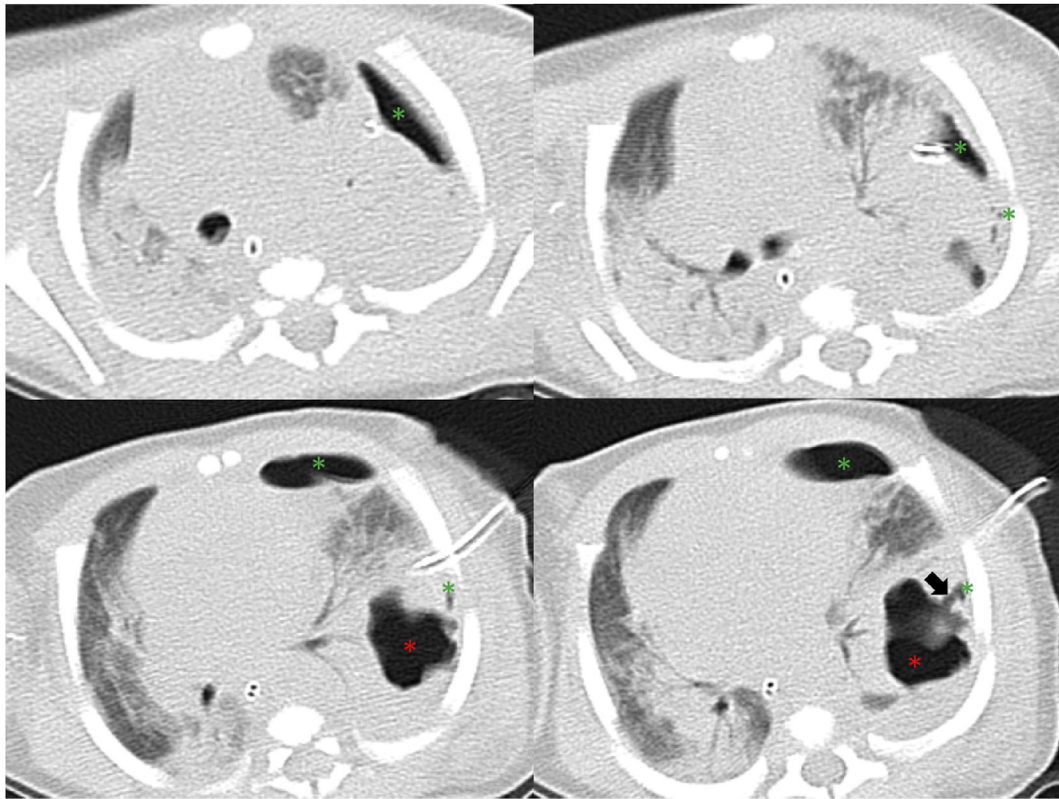


Fig. 4. MDCT of the thorax without contrast medium, lung window. Coarse air-filled lesion with thick irregular walls at the apical segment (VI) of the left lower lobe (red asterisks), determining contralateral shift of the mediastinum. Left PTX (green asterisks). Suspected communication between the lesion and the left pleural space (black arrow). Pulmonary consolidations with air bronchograms surrounding the lesion and widespread among omo and contralateral lung (RDS). (For interpretation of the references to colour in this figure legend, the reader is referred to the Web version of this article.)

mechanical ventilation. The air mechanically supplied entered into the pleural cavity and, probably with a valve mechanism through the communication itself, remained entrapped.

At this time as other possible differential diagnosis we considered: infected extralobar sequestration (more probable than the intralobar one in newborns, needed contrast administration to underline any systemic arterial supply and a better delineation of pleural sheets, that were impossible to rule out because of the coexistence of severe RDS, atelectasis and PTX), pulmonary abscess (needed contrast injection to evaluate the presence of rim enhancement) and, very rare, pleuro-pulmonary blastoma type 1 (cystic aspect, from prenatal to 10 months of age, impossible to distinguish from CPAMs 1 and 4).

With regard to this, the literature underlines that intravenous contrast enhancement can be particularly helpful in young children who have poor natural tissue contrast, frequently enabling differentiation of pneumonia from atelectasis, effusion, empyema and adenopathy [15].

For all these different reasons, the administration of contrast medium at second CT examination was fundamental to understand that the cystic component could depend to the pleural space, showing the split pleura sign, suggestive for pleural empyema.

The absence of systemic arterial supply to the lesion led us to abandon the hypothesis of an extralobar sequestration; the lack of a complete rim enhancement made the diagnosis of pulmonary abscess less probable; these considerations endorsed the suspect of a Type 1 or 4 CPAM with superimposed infection, PTX and pleural empyema or of a pulmonary pneumatocele: this latter hypothesis was in line with the finding of a thin walled cystic lesion and with infection or barotrauma as the leading causes.

In literature has been reported that a proportion of patients with CPAM develops complications but these are generally related to superadded infection that potentially may lead to the development of

empyema, lung abscess and recurrences; peripheral cysts' rupture can cause recurrent air leak and pneumothorax [16].

Chilkar et al. describe the case of a pyopneumothorax in a 5-month-old infant with type 3 CPAM but they specify that the signs of pleuritis were associated to a suppurative inflammation of the lung indicative of abscess [17].

Our histological report evidenced a pleural empyema alone, without a primitive underlying lung infection and, to the best of our knowledge, this is the first study to report such a case.

The true chronological and causal sequence of pathological events in this case remains unclear, because of the absence of suppurative changes in the lung adjacent to the loculated empyema. In our opinion, even if the diagnosis of CPAM 3 seems to be a collateral and incidental finding, its presence could have facilitated the development of a loculated PTX, later complicated by a superimposed infection. The mechanical ventilation at high pressures, instead, could have determined hypertensive PTX and the following pleural empyema.

4. Conclusions

According to this case, in a newborn with RDS loculated pleural empyema may mimic pulmonary cystic lesions and should be taken into account for differential diagnosis, despite acute angles between it and the parietal pleural sheets. CPAM 3 may be a subtle lesion, masked on CT scans by other more evident conditions, such as widespread bilateral pulmonary consolidations, pleural effusion or PTX. A treatment resistant pleural empyema or pyopneumothorax in a newborn can recognize a CPAM 3 as a probable underlying condition, even in the absence of lung suppurative changes.

In our experience in young children, who have poor natural tissue contrast, intravenous contrast material administration during CT

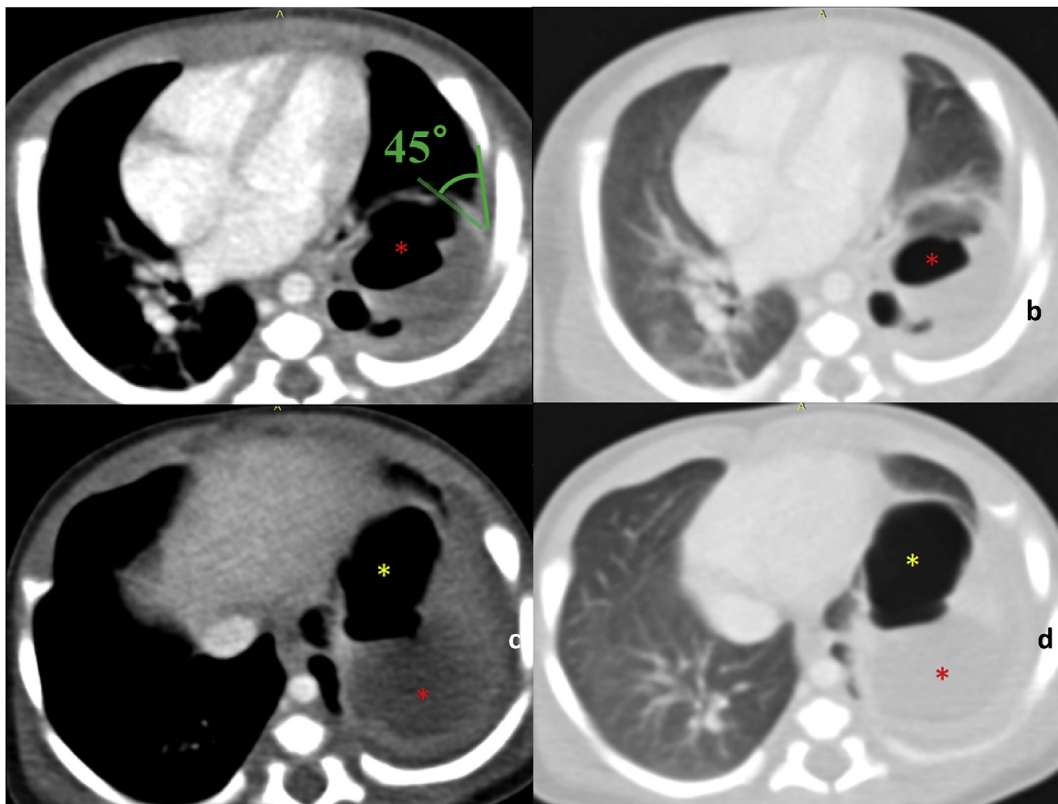


Fig. 5. MDCT of the thorax with contrast medium injection (a, c, e Mediastinum window. b, d, f Lung window) Persistence of the cystic lesion (c, e. red asterisks), showing thin walls, mixed air-fluid levels. The lesion extends from VI to IX e X segments and pleural joining angle is acute (45°), suggesting lung origin than pleural. Split pleura sign and acute folding of visceral pleura (a), significant for loculated pleural empyema. Absence of vascular anomalies from the descending aorta (red X). Relevant reduction of bilateral consolidations. Persistence of pneumothorax in the antero-basal zone (e. yellow asterisks). (For interpretation of the references to colour in this figure legend, the reader is referred to the Web version of this article.)

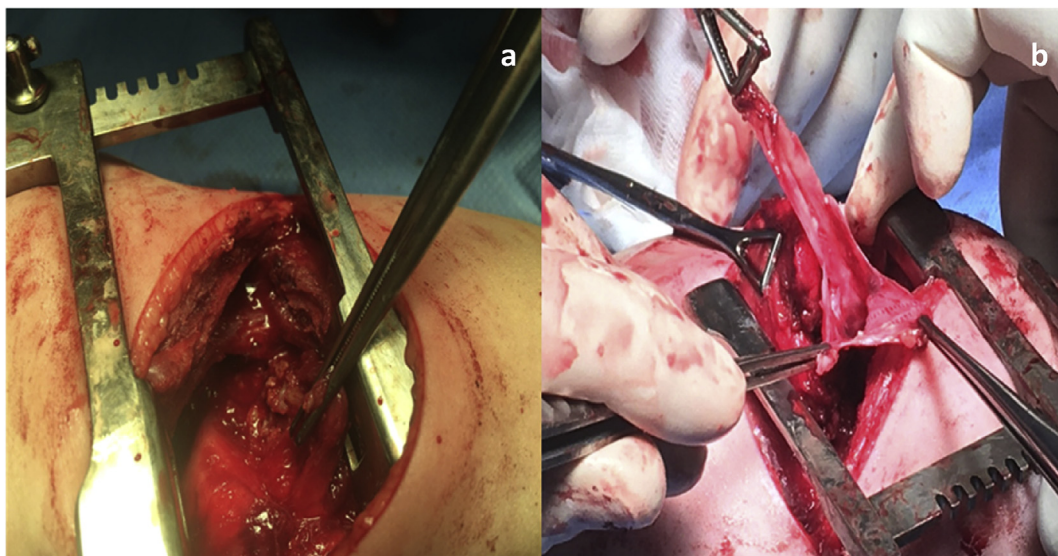


Fig. 6. Fifth left intercostal space thoracotomy (a). IV segment cystic lesion opened before removal (b) showing thin walls.

examination had been fundamental to better characterize the broad air filled lung lesion, allowing to specify the precise anatomical site, the preoperative map and the differential diagnosis.

Finally, according to this case CPAM 3 involving only two lung segments can have an excellent prognosis after surgical excision.

Conflicts of interest statement

The authors of this case report certify that they have NO affiliations with or involvement in any organization or entity with any financial interest (such as honoraria; educational grants; participation in speakers' bureaus; membership, employment, consultancies, stock ownership, or other equity interest; and expert testimony or patent-

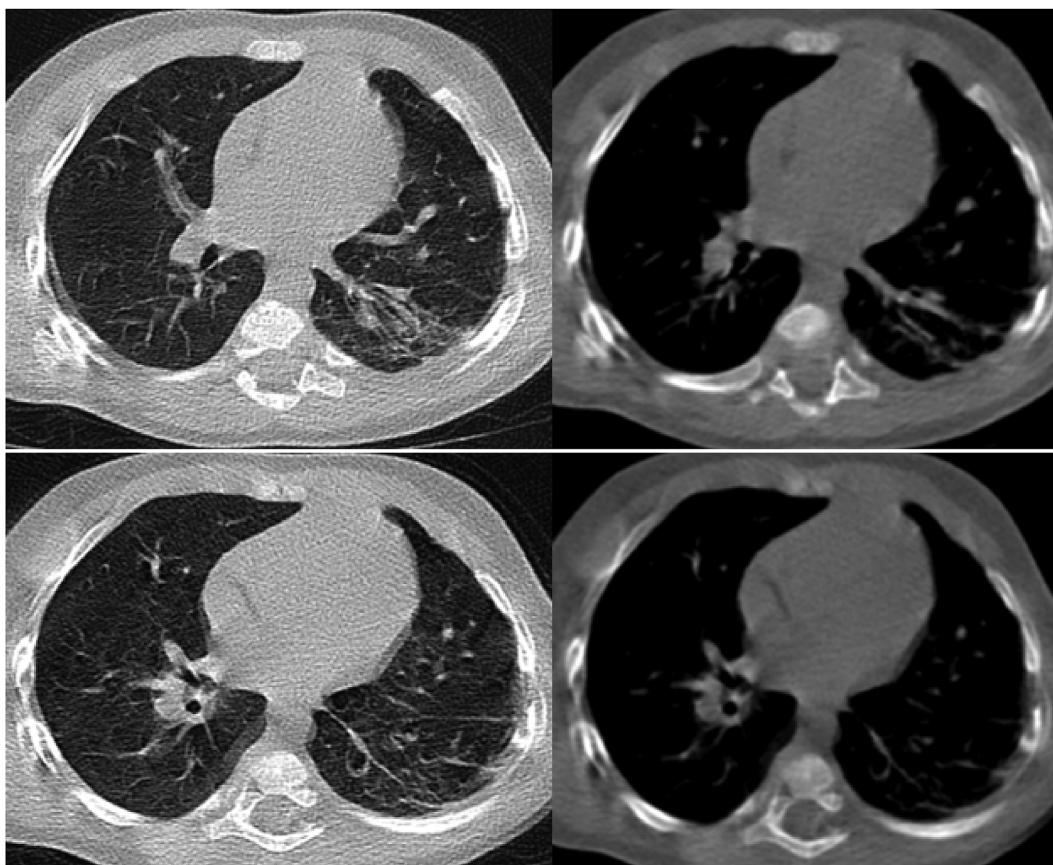


Fig. 7. Chest-CT 1 year post-surgery: complete resolution. Re-expansion of the residual segments of the left lower lobe, showing only some fibrotic bands and traction bronchiectasis, due to parenchymal and pleural scarring.

licensing arrangements), or non-financial interest (such as personal or professional relationships, affiliations, knowledge or beliefs) in the subject matter or materials discussed in this manuscript.

References

- [1] D.R. Biyyam, T. Chapman, M.R. Ferguson, et al., Congenital lung abnormalities: embryologic features, prenatal diagnosis, and postnatal radiologic-pathologic correlation *RadioGraphics*, 30 (Oct 2010) 1721–1738, <https://doi.org/10.1148/rg.306105508>.
- [2] J. Durell, K. Lakhoo, Congenital cystic lesions of the lung, *Early Hum. Dev.* 90 (12) (2014) 935–939 <https://doi.org/10.1016/j.earlhumdev.2014.09.014> PMID:25448785.
- [3] K.Y. Chin, M.Y. Tang, Congenital adenomatoid malformation of one lobe of a lung with general anasarca, *Arch. Pathol. (Chic)* 48 (3) (1949) 221–229 PMID:18137795.7.
- [4] J. Kwittken, L. Reiner, Congenital cystic adenomatoid malformation of the lung, *Pediatrics* 30 (1962) 759.
- [5] J.T. Stocker, J.E. Madewell, R.M. Drake, Congenital cystic adenomatoid malformation of the lung. Classification and morphologic spectrum, *Hum. Pathol.* 8 (2) (1977) 155–171 [https://doi.org/10.1016/S0046-8177\(77\)80078-6](https://doi.org/10.1016/S0046-8177(77)80078-6) PMID:856714.
- [6] F.A.F. Di Prima, A. Bellia, G. Inclimona, et al., Antenatally diagnosed congenital cystic adenomatoid malformations (CCAM) Research Review, *J. Prenat. Med.* 6 (2) (2012) 22–30.
- [7] A.R.M.B. Reis, F.B. Ribeiro, R. Schultz, Congenital cystic adenomatoid malformation type I, *Autopsy Case Rep. [Internet]* 5 (3) (2015) 21–26 <https://doi.org/10.4322/acr.2015.019>.
- [8] J.T. Stocker, Congenital pulmonary airway malformation - a new name for and an expanded classification of congenital cystic adenomatoid malformation of the lung. Symposium 24: non-neoplastic lung disease, *Histopathology* 41 (Suppl. 2) (2002) 424–430.
- [9] A. Hellmund, C. Berg, A. Geipel, et al., Prenatal diagnosis and evaluation of sonographic predictors for intervention and adverse outcome in congenital pulmonary airway malformation, *PLoS One* 11 (3) (2016) e0150474, <https://doi.org/10.1371/journal.pone.0150474>.
- [10] M. David, R. Lamas-Pinheiro, T. Henriques-Coelho, Prenatal and postnatal management of congenital pulmonary airway malformation, *Neonatology* 110 (2) (2016) 101–115, <https://doi.org/10.1159/000440894>. Epub 2016 Apr 13.
- [11] S. Costanzo, C. Filisetti, C. Vella, et al., Pulmonary malformations: predictors of neonatal respiratory distress and early surgery, *J. Neonatal Surg.* 5 (3) (2016) 27, <https://doi.org/10.21699/jns.v5i3.375>.
- [12] F. Gobbo, G. Pelizzo, J.M.&B. Schleeff, Dalla diagnosi prenatale al management post natale delle malformazioni polmonari. Suggestimenti per i pediatri, *Pagine elettroniche* Feb 13 (2) (2010), http://www.medicoebambino.com/?id=IPS1002_10.html.
- [13] N. Bagrodia, S. Cassel, J. Liao, et al., Segmental resection for the treatment of congenital pulmonary malformations, *J. Pediatr. Surg.* 49 (6) (2014 Jun) 905–909, <https://doi.org/10.1016/j.jpedsurg.2014.01.021>.
- [14] <https://pathology.uchicago.edu/sites/pathology.uchicago.edu/files/uploads/Stocker%20CPAM%20for%20Aspen%202014.pdf>.
- [15] B. Newman, J. Caplan, Cystic lung lesions in newborns and young children: differential considerations and imaging, *Seminars Ultrasound, CT MRI* 35 (6) (Dec 2014) 571–587.
- [16] R. Singh, M. Davenport, The argument for operative approach to asymptomatic lung lesions, *Semin. Pediatr. Surg.* 24 (4) (2015) 187–195 <https://doi.org/10.1053/j.sempedsurg.2015.02.003>.
- [17] S.M. Chilkar, V. Leelakumar, C.P. Ranjani, et al., Pyopneumothorax with Stocker type III congenital cystic adenomatoid malformation in a 5-month-old infant. *Lung India, Offic. Organ Indian Chest Soc.* 33 (2) (2016) 208–211, <https://doi.org/10.4103/0970-2113.177435>.