



Review

Retraction pocket excision with cartilage grafting as a preventive surgery for cholesteatoma

Francesco Comacchio^a, Marta Mion^{a,*}, Barbara Pedruzzi^b

^a Institute of Otolaryngology, Department of Neurosciences, Padova University, Via Giustiniani 2, 35121 Padova, Italy

^b Institute of Otolaryngology, Ospedali Riuniti Padova Sud, Via Albere 30, 35043 Monselice, Italy

Received 4 February 2017; revised 6 April 2017; accepted 18 April 2017

Abstract

Aims: The goal of the present study is to summarize our experience on surgical management of retraction pockets (RP) as a preventive tool against cholesteatomas.

Methods: Twenty-five ears have been followed up for a mean period of 6.16 ± 4.35 years (from 1 to 17 years). The sample presented a mean age of 47.56 ± 19.11 years (from 16 to 73 years). All patients underwent cartilage graft surgery. Furthermore 10 (40%) underwent tympanoplasty (TPL) type I, 14 (56%) TPL type II and 1 (4%) TPL type V.

Results: Eleven ears (44%) showed cholesteatoma: all these cases were stage III according to Charachon staging, and stage IV or V according to Gersdorff classification. Twelve patients (48%) showed erosion of the ossicular chain. Of these, five were associated with cholesteatoma and seven only with retraction. The recurrence rate of cholesteatoma was 12%. None of the patients with a stage II or III RP (according to Gersdorff classification) developed cholesteatoma. The recurrence of RP was 0%.

In regards to literature review, seven references were selected. These studies showed a success rate ranging from 79.1% to 88%, while recurrences of RP varied from 6.4% to 13%. Only one study specified a recurrence rate of cholesteatoma of 28%.

Conclusions: Surgical treatment of stages II and III RP is an effective tool to prevent cholesteatoma formation. The presence of keratin accumulation and cholesteatoma at the RP (stages IV and V, according to Gersdorff) are the real predictors of poor prognosis.

Copyright © 2017, PLA General Hospital Department of Otolaryngology Head and Neck Surgery. Production and hosting by Elsevier (Singapore) Pte Ltd. This is an open access article under the CC BY-NC-ND license (<http://creativecommons.org/licenses/by-nc-nd/4.0/>).

Keywords: Cartilage; Cholesteatoma; Graft; Pockets; Retraction

Contents

1. Introduction	113
2. Methods	113
2.1. Strategy	113
2.2. Statistical analyses	113
3. Results	113
4. Discussion	113
5. Conclusions	116
Conflicts of interest	116
Acknowledgement	116
References	116

* Corresponding author. Fax: +39 049 8213113.

E-mail addresses: comacchio.francesco@alice.it (F. Comacchio), med.mion@gmail.com (M. Mion), barbarengy@hotmail.com (B. Pedruzzi).

Peer review under responsibility of PLA General Hospital Department of Otolaryngology Head and Neck Surgery.

1. Introduction

A localized retraction of the tympanic membrane (TM) is called a “retraction pocket” (RP), which is an inward displacement of the TM from its normal position caused by the presence of a fragile portion of the pars tensa or pars flaccida (Alzahrani and Saliba, 2014).

RPs are implicated in the pathophysiology of cholesteatoma formation, and therefore their correct diagnosis is the base for prevention of this important middle ear pathology. There are many staging systems for RPs, that are useful to assess the follow up and consequent evolution of RP. The first staging system was proposed by Sadè and Berco (1976), after which several classifications were then approved (Bours et al., 1998; Charachon, 1988; Tos et al., 1987).

A dysfunctional Eustachian tube may be the cause of the RP (Alzahrani and Saliba, 2014), which may present as a paucisymptomatic entity. On the other hand, the middle ear ventilation, and particularly the epitympanic aeration, depends on the state of the tympanic isthmus (the narrow passage between the tubotympanic cavity and the atticomastoid air space): when there is a blockage in this area, gas exchanges only occur in the mastoid cells (Palva and Ramsay, 1996).

Otoscopic, otomicroscopic or otoendoscopic examination, audiometric exam, impedenzometry and radiological investigations become mandatory for an accurate diagnosis. In particular, temporal bone HRCT (high resolution computed tomography) is an important tool for surgical planning, for evaluation of the state of ossicular chain and to rule out the presence of cholesteatoma. A video rhinopharyngoscopy is equally important for the evaluation of the Eustachian tube orifices.

Treatment decisions may be guided by the grade of retraction and by the presence or absence of cholesteatoma. Various therapeutic approaches are available, with conservative and surgical options: the latter are represented by more or less invasive techniques, as transtympanic drainage, excision of the RP with cartilage grafting or, in the presence of cholesteatoma, canal wall up or canal wall down tympanomastoidectomy.

The aim of this study is to evaluate the efficacy of RP excision with cartilage grafting as a preventive surgery for the formation of cholesteatoma, by presenting our experience and by systematically reviewing extant literature on this topic.

2. Methods

2.1. Strategy

The present is a retrospective study of all patients (regardless of age or sex) with RPs who underwent cartilage graft surgery over a period ranging from 2003 to 2016. Patients were consecutively selected and all the operations were carried out by a single surgeon (the senior author, C.F.). Endoscopic photos (768 × 576 pixels, 33 × 26 dpi) were obtained in many cases, with a consequent description of the grading of the RP according to Charachon and Gersdorff classifications. Rates of RP recurrence and of cholesteatoma appearance were recorded.

2.2. Statistical analyses

Descriptive baseline and follow-up data were presented for each patient. Also, statistical analyses were conducted with the aim to identify potential predictors of recurrence prevention.

Numerical continuous variables were expressed as means ± standard deviation and nominal variables were described by the absolute and relative (%) frequency.

For all statistical analyses, the level of significance was set at $p < 0.05$.

3. Results

In the period 2003–2016, a total of 24 patients (25 ears, 14 left ears, and 11 right ears; 17 males and 7 females) were identified. The age range of the sample went from 16 to 73 (mean 47.56 ± 19.11 years).

Fourteen ears presented only a RP, while 10 patients also presented cholesteatoma at the time of diagnosis.

According to Charachon classification, all twenty-five RPs corresponded to a stage II (fixed RP, visible fundus) or III (fixed RP, not visible fundus), while according to Gersdorff classification, eleven of these (44%) coincided with a stage IV (fixed RP, not visible fundus, accumulation of keratin debris) or V (cholesteatoma with purulent otorrhea).

In our study, every patient underwent cartilage graft surgery. Overall, 10 (40%) patients underwent tympanoplasty (TPL) type I, 14 (56%) TPL type II and 1 (4%) TPL type V.

Post-surgical follow up had a mean duration of 6.16 ± 4.35 years (1–17 years; median = 6 years).

Fourteen ears (56%) did not present cholesteatoma in the RP or in the middle-ear, and none of these developed cholesteatoma during the follow up. On the other hand, eleven ears (44%) were found to be positive for cholesteatoma intra-operatively, result that was coherent with pre-operative findings. Furthermore, 12 patients (48%) showed erosion of the ossicular chain: five of these were associated with cholesteatoma and seven only with retraction. The recurrence rate of cholesteatoma was 12%. In all cases, the primitive cholesteatoma occupied the middle ear and not the RP. The mean disease-free period was 4.92 ± 3.91 years.

None of Gersdorff stage II or III RPs developed cholesteatoma.

Recurrence of RPs was 0% (Figs. 1 and 2).

All the data are summarized in Table 1a and b.

4. Discussion

RPs are a dynamic pathology. The persistence of otitis media or of negative pressure in the middle ear is the basis of the development of complications, such as cholesteatoma (Charachon et al., 1992). Negative middle ear pressure can be created by a selective dysventilation of the epitympanum, which is typically smaller in patients with RPs (Monsanto et al., 2016); Besides, a large mastoid antrum can contribute to a fall of pressure behind the TM (Grewal et al., 2003). Marchioni et al. (2010) hypothesized the existence of a

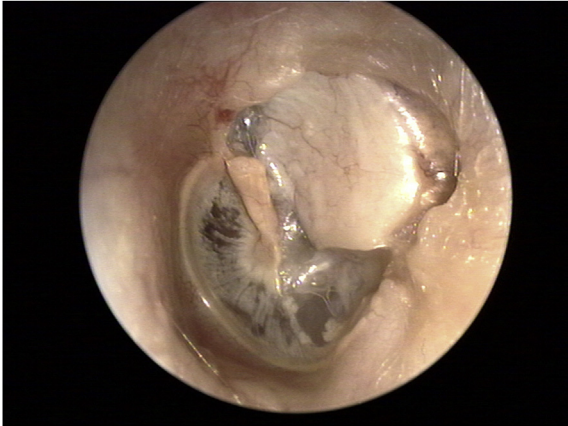

Fig. 1. Post-surgery otomicroscopy of previous RP with attic erosion.

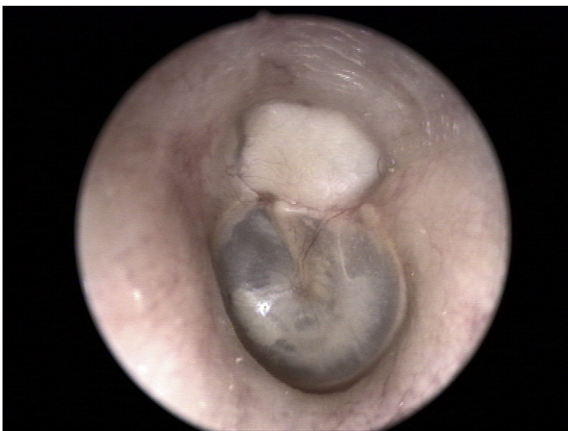

Fig. 2. Post-surgery otomicroscopy of previous RP.

selective epitympanic dysventilation syndrome, consisting of the presence of an attic RP or cholesteatoma, with a normal tubal function, a complete epitympanic diaphragm and a blockage of the isthmus.

Table 1

Baseline data.

	Age (y)	FU free from recurrence (y)	FU duration (y)
Mean	47.56	4.92	6.16
SD	19.11	3.91	4.35
Range	16–17	1–17	1–17
			All (range)
No. of patients			24
No. of ears			25
Sex			17 (M)/7 (F)
Ear side			14 (L)/11 (R)
TPL I			10 (40%)
TPL II			14 (56%)
TPL V			1 (4%)
Chole intra-operatively			11 (44%)
Ossicular chain erosion			12 (48%)
Chole recurrence rate			12%
Recurrence of RP			0%

y: years; FU: follow up; SD: standard deviation; M: male; F: female; L: left; R: right; TPL: tympanoplasty; chole: cholesteatoma.

There are many treatment options for RPs, and the therapeutic challenge consists in the evaluation of the correct timing for surgical intervention, which generally depends on the progression of pathology and on the consequent worsening of symptoms.

Bours et al. (1998) added stages IV and V to Charachon's classification of RPs to include keratin accumulation and cholesteatoma formation, respectively. According to Alzahrani and Saliba (2014), the patients who present keratin accumulation and otorrhea at direct otomicroscopy are candidates for surgical repair while, in the absence of these findings, the management should be guided by audiometric results: an ABG of more than 20 dB could be an indication for surgery. Kasbekar et al. (2014) recommend surgical treatment in case of retractions with no visible full extent, persistent or intermittent otorrhea and keratin accumulation. According to the same authors, operating on Charachon stage III RPs and symptomatic stage II RPs could prevent further damages to the middle ear structures.

Considering the material used for reconstruction of the TM, many studies demonstrate that there is no statistical difference in the outcome by using as a graft the temporalis fascia or a cartilage graft (Dornhoffer, 2006; Khalilullah et al., 2016; Mansour et al., 2006). Traditionally though, the latter is preferred for its intrinsic strength, which is greater than the one of the temporalis fascia (Kasbekar et al., 2014) and for its higher mechanical stability under negative pressure changes, which are frequent in the middle ear, especially in cases of tubal dysfunction, adhesive processes, tympanic fibrosis and general defects of the TM (Shin et al., 2007).

However, the reconstruction of the TM affects the quality of sound transmission, so the shape and the location of the transplant should be accurately chosen, tailoring the surgical technique depending on the characteristics of each patient.

The second goal of the present study is to review extant literature on this topic. Seven articles have been found (Barbara, 2008; Cassano and Cassano, 2010; Elsheikh et al., 2006; Kasbekar et al., 2014; Levinson, 1987; Mierzwiński et al., 2014; Shin et al., 2007), all of which extensively studied the management of RPs. The mean age of analyzed patients was 24.86 years, with an average follow up period of 30.33 months. Three studies (Barbara, 2008; Kasbekar et al., 2014; Mierzwiński et al., 2014) used Charachon classification to classify RPs (precisely, Mierzwiński et al. (2014) used a modification form of Charachon classification), while Cassano and Cassano (2010) and Elsheikh et al. (2006) preferred the Sadè scale. Shin et al. (2007) and Levinson (1987) did not use any classification but described their otoscopic findings.

The rate of cholesteatoma found intraoperatively was of 31% for Kasbekar et al. (2014) and 19% for Levinson (1987), while the rate of ossicular erosion was respectively 83% and 30%, respectively.

The success rate was 88% for Mierzwiński et al. (2014), and 79.1% for Cassano and Cassano (2010). Post-surgical recurrence rate of RP was of 6.4% in the series of patients described by Shin et al. (2007); for Levinson (1987) this rate

Table 2
Summary of reviewed studies.

Author	n.	Age (y): range	Age (y): mean	Charchon	Sadè	FU (mo): range	FU (mo): mean	Chole	Ossicular erosion	Success rate	Recurrence
Kasbekar et al., 2014	42 ears	8–66	38	62% II 38% III		12–104	38	31%	83%		
Mierzwiński et al., 2014	25 ears	5–36	10.6	III modified			36			88%	
Cassano and Cassano, 2010	24 ears	5–12			III		24			79.1%	
Cochrane, 2010: Barbara, 2008	15 pt			II			12				0 RP 0 chole
Elsheikh et al., 2006	23 pt				X						
Shin et al., 2007	47 pt	7–71					50				6.4% RP
Levinson, 1987	85 ears	2–83	26			12–24	22	19%	30%		13% RP 5/18 II look: chole

FU: follow up; y: years; mo: months; chole: cholesteatoma.
Bold type: Cochrane studies.

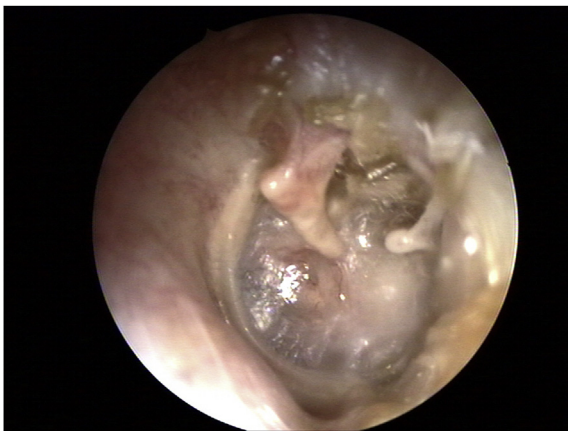

Fig. 3. A.P., pre-surgery otomicroscopy, Gersdorff's stage IV.

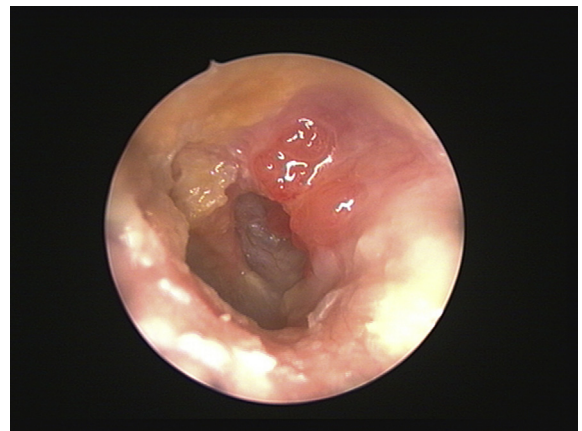


Fig. 5. B.A., pre-surgery otomicroscopy, Gersdorff's stage V.

was 13%, with five cholesteatomas found in 18 patients (28%) who underwent second look surgery.

All data are summarized in [Table 2](#).

According to data from our series, the introduction of Gersdorff stage IV and V raises the prognostic level of Charchon classification: the probability of recurrence depends on

the presence of keratin infiltration or already formed cholesteatoma, more than the presence of a mobile or fixed RP ([Figs. 3–8](#)).

In our experience, patients who underwent preventive cartilage grafting of the RP, did not develop cholesteatoma. Thus, surgical treatment in these cases resulted as an effective tool to prevent cholesteatoma formation.

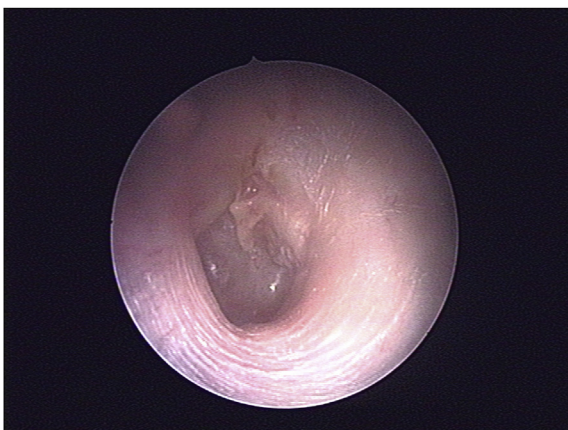

Fig. 4. A.P., post-surgery otomicroscopy.

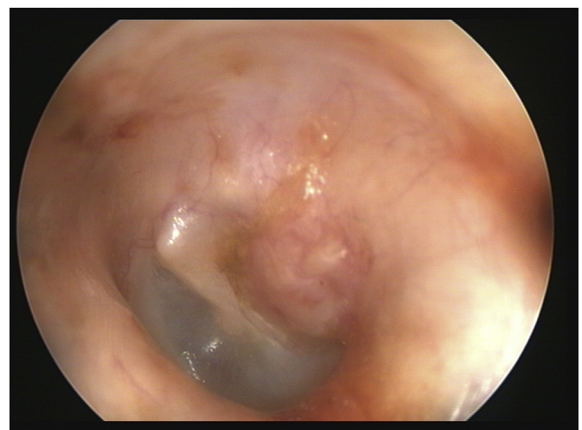


Fig. 6. B.A., post-surgery otomicroscopy.

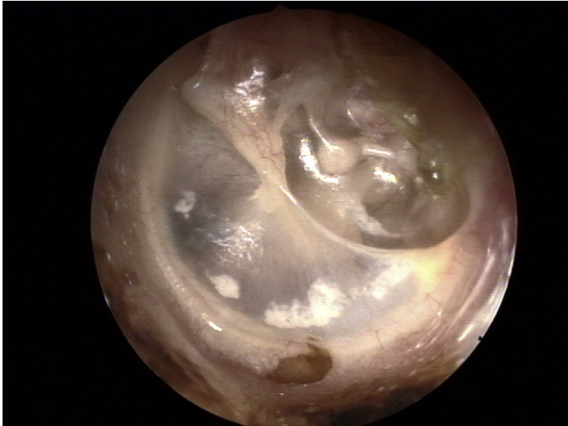


Fig. 7. G.E., pre-surgery otomicroscopy, Gersdorff's stage IV.

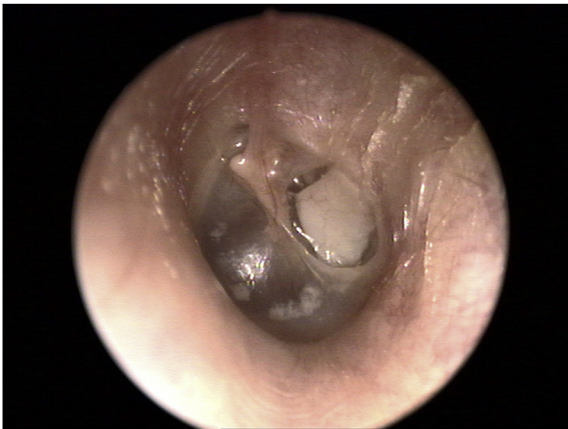

Fig. 8. G.E., post-surgery otomicroscopy.

The research has been conducted in full accordance with ethical principles.

This research was carried out without funding.

References

- Alzahrani, M., Saliba, I., 2014. Tympanic membrane retraction pocket staging: is it worthwhile? *Eur. Arch. Otorhinolaryngol.* 271, 1361–1368.
- Barbara, M., 2008. Lateral attic reconstruction technique: preventive surgery for epitympanic retraction pockets. *Otol. Neurotol.* 29 (4), 522–525.
- Bours, A.F., Decat, M., Gersdorff, M., 1998. Our classification of tympanic retraction pockets. *Acta Otorhinolaryngol. Belg.* 52 (1), 25–28.
- Cassano, M., Cassano, P., 2010. Retraction pockets of pars tensa in pediatric patients: clinical evolution and treatment. *Int. J. Pediatr. Otorhinolaryngol.* 74 (2), 178–182.
- Charachon, R., 1988. Classification of retraction pockets. *Rev. Laryngol. Otol. Rhinol. Bord.* 109 (3), 205–207.
- Charachon, R., Barthez, M., Lejeune, J.M., 1992. Spontaneous retraction pockets in chronic otitis media medical and surgical therapy. *Ear Nose Throat J.* 71, 578–583.
- Dornhoffer, J.L., 2006. Cartilage tympanoplasty. *Otolaryngol. Clin. North Am.* 39, 1161–1176.
- Elsheikh, M.N., Elsherief, H.S., Elsherief, S.G., 2006. Cartilage tympanoplasty for management of tympanic membrane atelectasis: is ventilatory tube necessary? *Otol. Neurotol.* 27 (6), 859–864.
- Grewal, D.S., Hathiram, B.T., Moliorkar, A.V., Davis, S., Rajeevan, T., 2003. Retraction pockets in chronic suppurative otitis media – our experience. *Indian J. Otolaryngol. Head Neck Surg.* 55 (2), 107–112.
- Kasbekar, A.V., Patel, V., Rubasinghe, M., Srinivasan, V., 2014. The surgical management of tympanic membrane retraction pockets using cartilage tympanoplasty. *Indian J. Otolaryngol. Head Neck Surg.* 66 (4), 449–454.
- Khalilullah, S., Shah, S.P., Yadav, D., Shrivastav, R.P., Bhattarai, H., 2016. Comparison of results of graft uptake using tragal cartilage perichondrium composite graft versus temporalis fascia in patients undergoing surgery for chronic otitis media – squamous type. *Head Face Med.* 12 (1), 26.
- Levinson, R.M., 1987. Cartilage–perichondrial composite graft tympanoplasty in the treatment of posterior marginal and attic retraction pockets. *Laryngoscope* 97 (9), 1069–1074.
- Mansour, M.H., Askar, M.H., Albirmamy, O.A., 2006. Repair of tympanic membrane perforation using a modified cartilage–perichondrium composite ring graft. *J. Laryngol. Otol.* 120, 952–954.
- Marchioni, D., Alicandri-Ciuffelli, M., Molteni, G., Artioli, F.L., Genovese, E., Presutti, L., 2010. Selective epitympanic dysventilation syndrome. *Laryngoscope* 120 (5), 1028–1033.
- Mierzwiński, J., Andrew, J., Fishman, 2014. Retraction pockets of tympanic membrane: protocol of management and results of treatment. *Otorhinolaryngologia* 13 (2), 114–121.
- Monsanto, R.D., Pauna, H.F., Kaya, S., Hizli, Ö., Kwon, G., Paparella, M.M., Cureoglu, S., 2016. Epitympanum volume and tympanic isthmus area in temporal bones with retraction pockets. *Laryngoscope* 126 (11), E369–E374.
- Palva, T., Ramsay, H., 1996. Incudal folds and epitympanic aeration. *Am. J. Otol.* 17, 700–708.
- Sadè, J., Berco, E., 1976. Atelectasis and secretory otitis media. *Ann. Otol. Rhinol. Laryngol.* 85 (2 Suppl 25 Pt 2), 66–72.
- Shin, S.H., Lee, W.S., Kim, H.N., Lee, H.K., 2007. Wheel-shaped cartilage–perichondrium composite graft for the prevention of retraction pocket development. *Acta Otolaryngol.* 127 (1), 25–28.
- Tos, M., Stangerup, S.E., Larsen, P., 1987. Dynamics of eardrum changes following secretory otitis. A prospective study. *Arch. Otolaryngol. Head Neck Surg.* 113 (4), 380–385.

5. Conclusions

Surgical treatment of stages II and III RP could be an effective tool to prevent cholesteatoma formation: in our experience, none of stage II or III RP developed cholesteatoma. Furthermore, as suggested by the present study and confirmed by extant literature, the presence of RPs with keratin accumulation and cholesteatoma formation is the real predictors of poor prognosis in RP surgical treatment. In this sense, Gersdorff classification results more predictive than the one proposed by Charachon.

Conflicts of interest

No conflicts of interest declared.

Acknowledgement

Thanks to Doctor Alexandre Enrico for language editing and proofreading the article.