


Clinical and Radiographic Aspects of Patients with Femoroacetabular Impingement Syndrome: Is There Difference between Symptomatic and Asymptomatic Hip?*

Aspectos clínicos e radiográficos de pacientes com síndrome do impacto femoroacetabular: Há diferença entre quadril sintomático e assintomático?

Andreza Maroneze Silva¹  Flávia Marques Nakatake¹ Maria Cristina Arruda Neves¹
Vera Lúcia Santos Alves¹ Giancarlo Cavalli Polesello¹

¹ Irmandade da Santa Casa de Misericórdia de São Paulo, Faculdade de Ciências Médicas, São Paulo, SP, Brazil

Rev Bras Ortop 2020;55(2):247–253.

Address for correspondence Vera Lúcia dos Santos Alves, PhD, Irmandade da Santa Casa de Misericórdia de São Paulo, Faculdade de Ciências Médicas, Rua Dr. Cesário Mota Júnior, 112, Vila Buarque - São Paulo, SP 01221-020, Brazil
(e-mail: fisioterapiasc@uol.com.br; andreza.fisio.orto@gmail.com).

Abstract

Objective This paper aims to compare clinical and radiographic features of symptomatic and asymptomatic hips in patients with unilateral femoroacetabular impingement syndrome (FAIS) and to establish a correlation between these findings.

Methods This is a retrospective study, based on medical records of patients diagnosed with FAIS between January 2014 and April 2017. The patients were assessed clinically as per the International Hip Outcome Tool 33 (iHOT33) questionnaire, visual analogue pain scale, hip rotation, and hip and knee muscular strength. The radiographic evaluation consisted of measurements of the alpha angle, crossover signal, acetabular retroversion index, ischial spine signal, and posterior wall sign.

Results A total of 45 patients were included in the study, with mean time from symptom onset to diagnosis of 28.6 months and mean iHOT33 score was 39.9. The mean medial rotation was 20.5° in symptomatic hip and 27.2° in asymptomatic hip ($p < 0.001$). The crossover signal was positive on 68.9% of the symptomatic hips and 55.6% of the asymptomatic hips ($p = 0.03$). The mean retroversion index was 0.15 in symptomatic hips and 0.11 in asymptomatic hips ($p = 0.02$). There was a positive correlation between the total time of symptoms and medial hip rotation reduction ($p = 0.04$) and between body mass index (BMI) and medial hip rotation reduction ($p = 0.02$).

Keywords

- ▶ femoroacetabular impingement
- ▶ hip
- ▶ range of motion

* Study performed at the Musculoskeletal Physical Therapy Department, Irmandade da Santa Casa de Misericórdia de São Paulo, São Paulo, SP, Brazil.

Resumo

Conclusion When comparing clinical and radiographic features, we observed reduction of medial rotation and increase of acetabular retroversion index in the symptomatic hip, as well as association between the long symptom time and the high BMI with loss of medial rotation of the hips..

Objetivos Comparar características clínicas e radiográficas entre quadril sintomático e assintomático em pacientes com síndrome do impacto femoroacetabular unilateral e estabelecer correlações entre os achados.

Métodos Estudo retrospectivo, que consultou prontuários de pacientes com síndrome do impacto femoroacetabular, entre janeiro de 2014 e abril de 2017. Os pacientes foram avaliados clinicamente pelo questionário *International Hip Outcome Tool 33* (iHOT33), escala visual analógica de dor, amplitude de rotação de quadril e força muscular de quadril e joelho. A avaliação radiográfica foi composta por mensurações do ângulo alfa, sinal do cruzamento, índice de retroversão acetabular, sinal da espinha isquiática e sinal da parede posterior do acetábulo.

Resultados Foram incluídos no estudo 45 prontuários de pacientes, com tempo médio de sintomas até o diagnóstico de 28,6 meses e pontuação média no iHOT33 de 39,9. O valor médio de rotação medial do quadril sintomático foi de 20,5° e do assintomático 27,2°, com ($p < 0,001$). A positividade do sinal do cruzamento para quadril sintomático foi de 68,9% e do assintomático 55,6% ($p = 0,03$). Para índice de retroversão, o valor médio do quadril sintomático foi de 0,15 e do quadril assintomático foi 0,11 ($p = 0,02$). Encontramos correlação positiva entre o tempo de sintomas e a redução de amplitude de rotação medial de quadril ($p = 0,04$) e entre o índice de massa corpórea (IMC) e a redução amplitude de rotação medial de quadril ($p = 0,02$).

Conclusão Ao comparar características clínicas e radiográficas, observamos redução de rotação medial e aumento do índice de retroversão acetabular no quadril sintomático, bem como associação entre o longo tempo de sintoma e o IMC elevado com perda de rotação medial dos quadris.

Palavras-chave

- ▶ impacto femoroacetabular
- ▶ quadril
- ▶ amplitude de movimento

Introduction

Femoroacetabular impingement syndrome (FAIS) is defined as a clinical disorder related to hip movement and composed of a triad, that is, symptoms, clinical signs, and imaging findings. It is divided into three clinical subtypes: cam (femoral morphological change), pincer (acetabular morphological change), and mixed (a combination of both previous subtypes).¹

In the pathophysiology of FAIS, there is an abnormal contact between the proximal end of the femur and the acetabulum during extremes of hip range of motion (ROM); due to frequent repetition, this contact can result in progressive lesions of the lip and acetabular cartilage. The condition is known as a common cause for hip pain and has gained recognition for its correlation with osteoarthritis.²

The main symptom of FAIS is anterior/inguinal hip pain; the mechanical overload resulting from impingement may cause functional changes in the whole lower limb, such as reduced ROM and alterations in strength production, neuromuscular control, gait and more intense sportive activities. A systematic review concludes that this population performs compensations in the frontal, sagittal, and transverse planes during dynamic activities compared to asymptomatic controls.³

The literature reports studies comparing clinical and radiographic parameters from patients with FAIS and asymptomatic controls; in addition, there are studies confronting features from dominant and non-dominant limbs.⁴ However, few papers compare symptomatic and asymptomatic limbs from patients with unilateral FAIS in order to broaden the understanding of characteristics leading to hip pain.

This study aimed to compare the clinical and radiographic features of symptomatic and asymptomatic hips from patients with unilateral FAIS and to establish a correlation between such findings.

Method

This was a retrospective, observational, clinical, self-controlled study based on medical records from a single center. These medical records belonged to patients from a single-surgeon case series (Giancarlo Cavalli Polesello - GCP) who were followed between January 2014 and April 2017. The study was approved by the Research Ethics Committee under CAAE number 63881917.8.0000.5479; this manuscript was prepared using the Strengthening the Reporting of Observational studies in Epidemiology (Strobe) checklist.⁵

Inclusion criteria were the following: complete medical records with information on both male and female patients diagnosed with unilateral FAIS, aged between 18 and 55 years and who signed the informed consent form. Medical records from patients previously submitted to orthopedic surgeries of the spine and/or lower limbs or reporting degenerative hip osteoarthritis, villonodular synovitis, synovial chondromatosis, malignant tumors of the hip and continuous use of opioid analgesics at the time of functional tests were excluded.

Medical records of 95 patients were initially examined, and the final sample consisted of 45 patients. Data from both hips were assessed, constituting a sample of 90 hips.

The diagnosis of FAIS was confirmed by personal history, physical examination and imaging findings. Clinical tests included flexion, adduction and internal rotation (FADIR) and flexion, abduction and external rotation (FABER),⁶ whereas imaging included an anteroposterior (AP) radiograph of the pelvis with the patient standing up, a lateral radiography of the femoral neck (Dunn or Ducroquet) and magnetic resonance imaging in patients with surgical indication for better lip and acetabular cartilage evaluation. In case of diagnostic doubt after all routine tests, signs and symptoms were reassessed after an intra-articular anesthetic injection. All patients were evaluated by a senior hip surgeon (> 20 years of experience) and a hip rehabilitation staff with more than 5 years of practice.

Clinical and Functional Evaluation

A standardized form was used for data extraction and clinical characterization of the sample, including gender, age (years), weight (kg), height (cm), body mass index (BMI, kg/m²), dominant limb, symptomatic limb, duration of symptoms (months), associated diseases, medications in use, and level of physical activity (► **Table 1**).

Clinical data, including visual analogue scale (VAS) for pain, hip medial rotation (RM) and lateral rotation (RL) ROM, hip and knee muscle strength scores, quality of life questionnaire International Hip Outcome Tool 33 (iHOT33) and pelvic AP radiographic measurements (alpha angle, cross-over signal, acetabular retroversion index, posterior wall signal, and ischial spine signal), were also collected. Evaluations were performed by two physical therapists with 5 years of experience in hip rehabilitation.

Measurements of hip rotation amplitudes were performed using a universal goniometer (Carci, São Paulo, SP, Brazil) with the patient in supine position and the stabilized pelvis on the stretcher with a belt to avoid compensations. The evaluated limb was positioned in 90° hip flexion and the contralateral limb was put in extension. The goniometer axis was positioned over the center of the knee on the side to be measured, with the fixed arm parallel to the ground and the movable arm following the tibial axis during medial and lateral femoral rotation (► **Figure 1**).⁷ The evaluators had class correlation index (CCI) above 0.80 for hip rotation ROM assessment.

Hip and knee muscular strength were measured with a manual dynamometer MicroFet2 (Hoggan Health Industries Inc., West Jordan, UT, USA).⁸ A stabilization belt was used to avoid compensations (► **Figure 2**).⁹ Three isometric contrac-

Table 1 Anthropometric and analytical variables from the 45 patients included in the study sample.

Gender		
Female	28 (62.2%)	
Male	17 (37.8%)	
Age (years)	39.02 ± 8.03	
Weight (kg)	69.63 ± 14.52	
Height (cm)	168.89 ± 9.86	
BMI (kg/m ²)	24.16 ± 3.21	
Symptoms duration (months)	28.64 ± 31.91	
VAS (0-10)	5.67 ± 2.55	
iHOT-33 (0-100)	39.93 ± 21.20	
Pain site		
C-sign	22 (48.9%)	
Inguinal	17 (37.8%)	
Trochanter	6 (13.3%)	
Dominant limb		
Right	43 (95.6%)	
Left	2 (4.4%)	
Symptomatic limb		
Right	29 (64.4%)	
Left	16 (35.6%)	
FAI subtype	Symptomatic	Asymptomatic
Cam	13 (28.9%)	15 (33.3%)
Pincer	12 (26.6%)	09 (20%)
Mixed	20 (44.5%)	18 (40%)
Physical activity		
Sedentary	16 (35.6%)	
Active	29 (64.4%)	

Abbreviations: SD, standard deviation; VAS, visual analog scale; FAI, femoroacetabular impingement; iHOT-33, The International Hip Outcome Tool 33; BMI, body mass index.

tions of five seconds each were performed and averaged. The following muscle groups were evaluated: flexors, extensors, adductors, abductors, hip medial and lateral rotators, knee flexors and extensors muscles.¹⁰ Strength was measured in kilograms (kg) and normalized according to body mass (kg) with the formula: (strength [kg]/body mass [kg]) x 100.¹¹ The evaluators had CCI above 0.80 for hip and knee muscle groups strength measurement using a manual dynamometer.

The iHOT33 score assessed FAIS-related limitations in the quality of life of our patients.¹² This questionnaire, used in young adults with non-arthritic hips, was adapted and translated into Portuguese in 2012.¹³ Patients were allowed to fill in the form, which had 33 questions divided into four domains: symptoms and functional limitations, sports and recreational activities, job-related concerns, and social, emotional, and lifestyle concerns. These questions are evaluated by a scale with a 100 mm-long line. The patients were

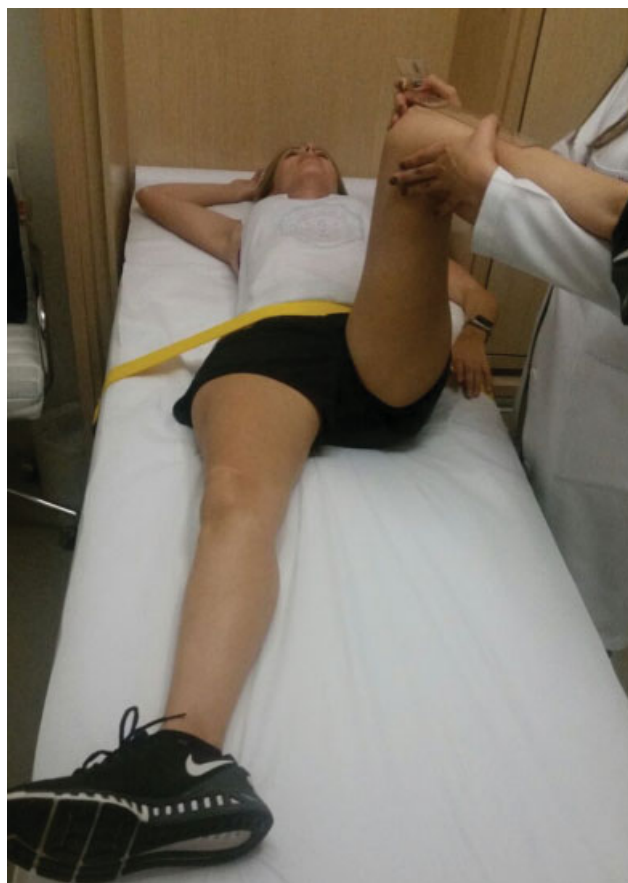

Fig. 1 Patient positioning and measurement of hip medial rotation range of motion under stabilization.

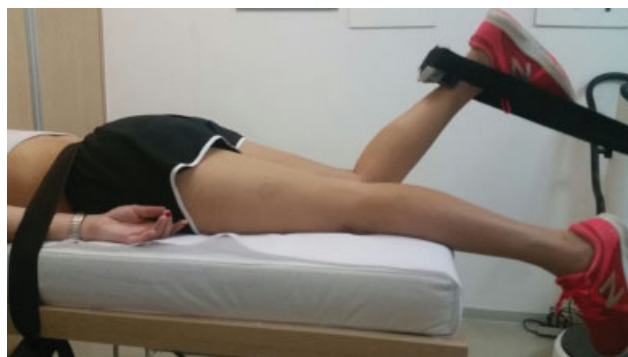

Fig. 2 Illustrative image for muscle strength measurement of knee flexors with a manual isometric dynamometer and belt stabilization.

instructed to answer the question by drawing a bar at the line. The final score was the sum of answers, divided by the total number of questions.

Radiological Evaluation

All patients underwent an orthostatic digital AP hip radiography with 15° internal rotation of the lower limbs, a radius centered 1 cm above the pubic symphysis, ampoule 120 cm from the chassis and a 100% magnification to evaluate the alpha angle, acetabular retroversion index, ischial spine signal, crossover signal, and posterior wall signal.¹⁴

The alpha angle is a quantitative expression of femoral deformity. It was evaluated according the method described by Gosvig et al,¹⁵ using as reference points the center of the femoral neck, the center of the femoral head and the beginning of the femoral deformity (► **Figure 3A**). The authors categorized alpha angle values in orthostatic AP hip radiographies as normal, borderline and pathological. In the present study, diagnostic criteria for cam morphology were defined as pathological alpha angle values ($\geq 83^\circ$ for men and $\geq 57^\circ$ for women).

The acetabular retroversion index (ARI) quantitatively expresses the cross-over signal, representing a radiographic sign of anterior acetabular overlay and was measured according to Diaz-Ledezma et al,¹⁶ 2013. The ARI is the quotient between the anterior border overlap length and the lateral distance of the acetabular cavity. Values above 0.20 are related to chondral injury (► **Figure 3B**). The ischial spine signal, posterior wall signal and cross-over signal were described as present or absent.

The free HOROS 64-bit image viewer software for OS X was used. This software is based on OsiriX and other open source medical image libraries and is available under GNU General Public License, version 3 (GPL-3.0).

Images were evaluated by an orthopedist working in the hip surgery area for more than five years and who was blind to the patient's name and symptomatic limb; CCI was performed in a previous study, with good correlation in all analyzed parameters.¹⁷

Statistical Analysis

Excel Office 2017 (Microsoft Corp., Redmond, WA, USA) and SPSS 13.0 (SPSS Inc., Chicago, IL, USA) were used. Descriptive data were expressed as mean and standard deviation. Comparison between variables was made using Wilcoxon, paired Student t, McNemar, and Pearson tests. The *p*-value adopted as significant was 0.05.

Results

Mean medial rotation ROM was $20.56^\circ \pm 12.39^\circ$ in symptomatic hips and $27.22 \pm 12.59^\circ$ in asymptomatic hips ($p < 0.001$). Mean values for lateral rotation were, respectively, $40.89 \pm 8.2^\circ$ and $44.67^\circ \pm 5.7^\circ$ ($p = 0.003$).

In the muscle strength analysis, when comparing mean values from hip and knee muscle groups, symptomatic and asymptomatic limbs, there was a significant difference in hip adductors ($p = 0.040$) and knee flexors ($p = 0.007$). The remaining groups, including hip flexors ($p = 0.915$), hip extensors ($p = 0.082$), hip abductors ($p = 0.090$), medial hip rotators ($p = 0.378$), hip lateral rotators ($p = 0.345$) and knee extensors ($p = 0.942$), showed no differences (► **Figure 4**).

Regarding the radiographic analysis, mean alpha angle was $74.06^\circ \pm 7.57$ in symptomatic limbs and $71.76^\circ \pm 7.07$ in asymptomatic limbs ($p = 0.080$). For the retroversion index, values were 0.15 ± 0.11 and 0.11 ± 0.11 , respectively ($p = 0.009$). Cross-over signal was positive in 68.9% (31 hips) symptomatic limbs and 55.6% (25 hips) asymptomatic limbs ($p = 0.030$). Ischial spine signal was positive in 37.8% (17 hips) both symptomatic and asymptomatic limbs ($p = 1.000$). The

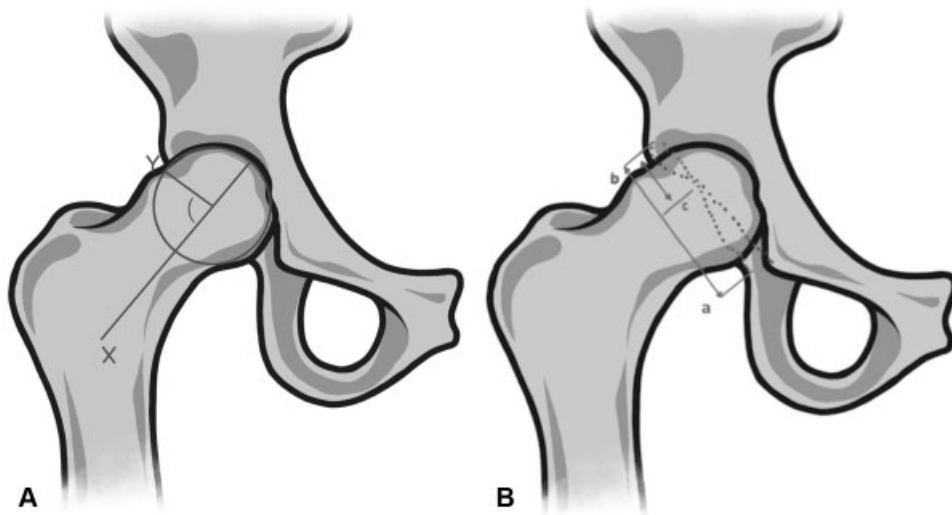


Fig. 3 Tracings for radiographic measurements. (A) alpha angle; (B) retroversion index.

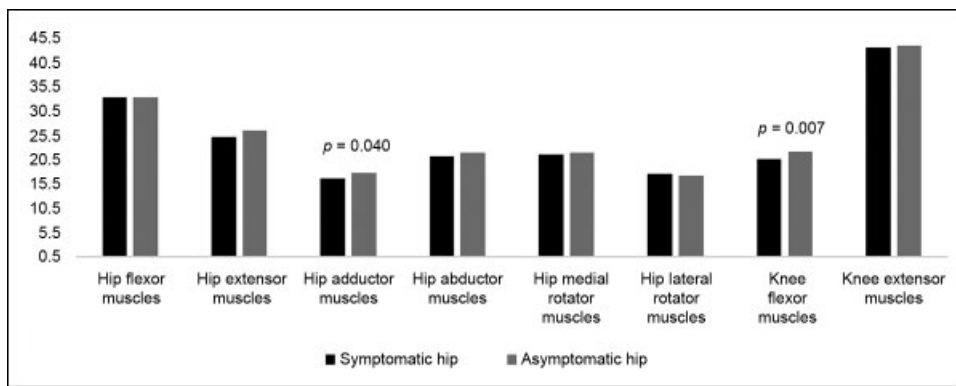


Fig. 4 Hip and knee dynamometry values normalized per body weight—comparison between symptomatic and asymptomatic hips (n = 90 hips).

posterior wall signal was positive in 42.2% (19 hips) symptomatic limbs and 40% (18 hips) asymptomatic limbs ($p = 1.000$).

In the correlation between all parameters evaluated, a statistical significance was found between time of symptoms onset and loss of medial rotation ROM in symptomatic hips ($p = 0.040$); $r = 0.279$ and between BMI and loss of medial rotation ROM in symptomatic hips ($p = 0.020$); $r = 0.495$.

Discussion

Comparing symptomatic and asymptomatic hips, the main findings were the reduced hip medial and lateral rotation ROM, reduced hip adductor and knee flexor muscle strength, cross-over signal positivity and increased acetabular retroversion index in symptomatic hips. Regarding correlations between evaluated aspects, we found out that the time of symptoms was weakly correlated with the reduced hip RM, whereas BMI was moderately correlated with the reduced hip RM.

Measurement of hip ROM is an important element of functional assessment. There is strong evidence that loss of hip medial rotation ROM is a risk factor for intra-articular

injury. A systematic review¹⁸ indicates that a difference in medial or lateral hip rotation higher than 7° between limbs may be a marker for future injury risk. Audenaert et al¹⁹ found a significant reduction in RM ROM when comparing controls to individuals with FAIS in cam and pincer morphology. This change influences the quality of life and sports practice, especially in activities with increased hip flexion.

The Warwick agreement, established in 2016, guides requests for simple hip AP and femoral neck lateral radiographies to investigate morphological changes and rule out other causes of hip pain.¹ This study used the hip AP radiographies which allow the evaluation of femoral sphericity and signs of acetabular retroversion. Since markers for pincer signals assessment are not well established in the literature, the acetabular retroversion index, which provides quantitative information on the severity of focal overlay and may be a prognostic predictor in symptomatic patients,¹⁶ was added to the three most used signals.²⁰

A 2015 systematic review evaluating radiographic variables associated with FAIS progression concluded that there is moderate evidence that the increased alpha angle is associated with disease progression and that additional markers would

not be an influence.²¹ In this study, we found high alpha angles in both hips, with no significant difference between limbs, suggesting that factors other than femoral alteration influence symptoms development. In addition, the difference in retroversion index between limbs was clinical (26% higher in symptomatic limbs) and statistically significant and certainly a determining factor for symptoms development.

Neuromuscular inhibition of the hip is common in patients with FAIS. Deep stabilizers may be more affected due to their proximity to the injured tissue, resulting in joint and lower limb overload.²² A study assessing isometric muscle strength in 22 FAIS patients compared to 22 matching controls found a significant difference in hip adductor, abductor, flexor, and external rotator muscles strength in symptomatic individuals.²³ Other researchers investigated the isometric and isokinetic strength of FAIS patients compared to controls. Based on the ratio between agonist and antagonist muscles in each group, it was concluded that individuals with FAIS have 20% of hip abductor isometric weakness and also an imbalance between lateral and medial hip rotators when compared to controls.⁴ We observed a reduction in hip adductor and knee flexor muscles strength when comparing limbs, but such difference was clinically small.

Kockara et al²⁴ concluded that BMI values $\geq 25/m^2$ may be predictors of unfavorable clinical outcomes after surgical treatment for FAIS. In our study, the increased BMI was positively correlated with the loss of RM, which may indicate a higher severity of FAIS in overweight patients. However, this change may also result from the difficulty in assessing hip medial rotation due to the accumulation of inguinal and abdominal fat/muscle mass in such patients.

The long time until diagnosis was observed in our case series and also by Kahlenberg et al,²⁵ who, after evaluating 78 patients with FAIS and applying a standardized questionnaire, noted that the mean time between symptom onset and diagnosis was 32 months. This finding demonstrates the importance of appropriate assessment and timely diagnosis, since, in an attempt to relieve pain, many patients may be exposed to long-term drug treatments and incorrect interventions, leading to health risk and injury progression.

This study had some limitations, such as small sample size compared to large-center studies, hip radiological assessment only in AP views (which may not identify some cases of cam deformity that are only visible in lateral view), the non-stratification of the level of physical activity in evaluated patients and the lack of a dynamic evaluation of muscular strength. The main contribution of this study was the identification of possible factors related to pain and hip medial rotation limitation in FAIS patients. Further assessments may create new opportunities for treatment and follow-up of these patients.

Conclusion

The comparison of clinical and radiographic features revealed a reduction in medial rotation and an increase in

the acetabular retroversion index in symptomatic hips, as well as an association between long duration of symptom and high BMI with loss of medial rotation of the hips.

Conflict of Interests

The authors have no conflict of interests to declare.

Acknowledgments

We are thankful to Dr. Guilherme Guadagnini Falótico for performing the radiological measurements presented in this paper.

References

- 1 Griffin DR, Dickenson EJ, O'Donnell J, et al. The Warwick Agreement on femoroacetabular impingement syndrome (FAI syndrome): an international consensus statement. *Br J Sports Med* 2016;50(19):1169–1176
- 2 Ganz R, Parvizi J, Beck M, Leunig M, Nötzli H, Siebenrock KA. Femoroacetabular impingement: a cause for osteoarthritis of the hip. *Clin Orthop Relat Res* 2003;(417):112–120
- 3 Diamond LE, Dobson FL, Bennell KL, Wrigley TV, Hodges PW, Hinman RS. Physical impairments and activity limitations in people with femoroacetabular impingement: a systematic review. *Br J Sports Med* 2015;49(04):230–242
- 4 Diamond LE, Wrigley TV, Hinman RS, et al. Isometric and isokinetic hip strength and agonist/antagonist ratios in symptomatic femoroacetabular impingement. *J Sci Med Sport* 2016;19(09):696–701
- 5 Malta M, Cardoso LO, Bastos FI, Magnanini MM, Silva CM. Iniciativa STROBE: subsídios para a comunicação de estudos observacionais. *Rev Saude Publica* 2010;44(03):559–565
- 6 Pacheco-Carrillo A, Medina-Porqueres I. Physical examination tests for the diagnosis of femoroacetabular impingement. A systematic review. *Phys Ther Sport* 2016;21:87–93
- 7 Gradoz MC, Bauer LE, Grindstaff TL, Bagwell JJ. Reliability of Hip Rotation Range of Motion in Supine and Seated Positions. *J Sport Rehabil* 2018;27(4):1–4. Doi: 10.1123/jsr.2017-0243
- 8 Sisto SA, Dyson-Hudson T. Dynamometry testing in spinal cord injury. *J Rehabil Res Dev* 2007;44(01):123–136
- 9 Bohannon RW, Kindig J, Sabo G, Duni AE, Cram P. Isometric knee extension force measured using a handheld dynamometer with and without belt-stabilization. *Physiother Theory Pract* 2012;28(07):562–568
- 10 Magalhães E, Fukuda TY, Sacramento SN, Forgas A, Cohen M, Abdalla RJ. A comparison of hip strength between sedentary females with and without patellofemoral pain syndrome. *J Orthop Sports Phys Ther* 2010;40(10):641–647
- 11 Robinson RL, Nee RJ. Analysis of hip strength in females seeking physical therapy treatment for unilateral patellofemoral pain syndrome. *J Orthop Sports Phys Ther* 2007;37(05):232–238
- 12 Mohtadi NG, Griffin DR, Pedersen ME, et al; Multicenter Arthroscopy of the Hip Outcomes Research Network. The Development and validation of a self-administered quality-of-life outcome measure for young, active patients with symptomatic hip disease: the International Hip Outcome Tool (iHOT-33). *Arthroscopy* 2012;28(05):595–605, quiz 606–10.e1
- 13 Polesello GC, Godoy GF, Trindade CA, Queiroz MC, Honda E, Ono NK. Tradução e adaptação transcultural do instrumento de avaliação do quadril iHOT. *Acta Ortop Bras* 2012;20(02):88–92
- 14 Tannast M, Siebenrock KA, Anderson SE. Femoroacetabular impingement: radiographic diagnosis—what the radiologist should know. *AJR Am J Roentgenol* 2007;188(06):1540–1552
- 15 Gosvig KK, Jacobsen S, Palm H, Sonne-Holm S, Magnusson E. A new radiological index for assessing asphericity of the femoral

- head in cam impingement. *J Bone Joint Surg Br* 2007;89(10):1309–1316
- 16 Diaz-Ledezma C, Novack T, Marin-Peña O, Parvizi J. The relevance of the radiological signs of acetabular retroversion among patients with femoroacetabular impingement. *Bone Joint J* 2013;95-B(07):893–899
- 17 Garcia AS, Gobetti M, Tatei AY, Falótico GG, Arliane GG, Puertas EB. Prevalência de sinais radiográficos de impacto femoroacetabular em indivíduos assintomáticos e não atletas. *Rev Bras Ortop* 2019;54(01):60–63
- 18 Tak I, Engelaar L, Gouttebarga V, et al. Is lower hip range of motion a risk factor for groin pain in athletes? A systematic review with clinical applications. *Br J Sports Med* 2017;51(22):1611–1621. Doi: 10.1136/bjsports-2016-096619
- 19 Audenaert EA, Peeters I, Vigneron L, Baelde N, Pattyn C. Hip morphological characteristics and range of internal rotation in femoroacetabular impingement. *Am J Sports Med* 2012;40(06):1329–1336
- 20 Rhee C, Le Francois T, Byrd JWT, Glazebrook M, Wong I. Radiographic Diagnosis of Pincer-Type Femoroacetabular Impingement: A Systematic Review. *Orthop J Sports Med* 2017;5(05):2325967117708307
- 21 Wright AA, Naze GS, Kavchak AE, Paul D, Kenison B, Hegedus EJ. Radiological variables associated with progression of femoroacetabular impingement of the hip: a systematic review. *J Sci Med Sport* 2015;18(02):122–127
- 22 Retchford TH, Crossley KM, Grimaldi A, Kemp JL, Cowan SM. Can local muscles augment stability in the hip? A narrative literature review. *J Musculoskelet Neuronal Interact* 2013;13(01):1–12
- 23 Casartelli NC, Maffiuletti NA, Item-Glatthorn JF, et al. Hip muscle weakness in patients with symptomatic femoroacetabular impingement. *Osteoarthritis Cartilage* 2011;19(07):816–821
- 24 Kockara N, Sofu H, Issin A, Çamurcu Y, Bursali A. Predictors of the clinical outcome and survival without degenerative arthritis after surgical treatment of femoroacetabular impingement. *J Orthop Sci* 2018;23(01):117–121
- 25 Kahlenberg CA, Han B, Patel RM, Deshmane PP, Terry MA. Time and Cost of Diagnosis for Symptomatic Femoroacetabular Impingement. *Orthop J Sports Med* 2014;2(03):2325967114523916