

APPLICATION OF SILVER DIAMINE FLUORIDE AS PART OF THE ATRAUMATIC RESTORATIVE TECHNIQUE

By **Dharmit Modasia**, University of Bristol, and **Reema Modasia**, QMUL

Introduction

Dentistry is an evolving profession that has been significantly impacted by the COVID-19 pandemic. Greater consideration must be taken with treatment planning to minimise aerosol generating procedures (AGPs) as well as working in the patient's best interest to provide the best quality of dental care. Silver diamine fluoride (SDF) is an effective non-invasive treatment option and is applied as a topical medicament on tooth cavities to arrest dental caries. Currently there is limited use of this substance across dental practices in the UK, however the prospect of SDF being introduced is becoming increasingly likely due to the COVID-19 pandemic.

Silver diamine fluoride (SDF)

The only available preparation within the UK is Riva Star with a formulation of 38% SDF which has been proven to be the optimum concentration to arrest carious lesions. SDF consists of silver, ammonium and fluoride ions. Following SDF application, literature supports the use of potassium iodide to help eliminate stain formation.¹ The Riva Star preparation is only registered as a desensitising agent and therefore the use of SDF for caries prevention is not officially condoned.

Indication of SDF use

SDF can be used on dentinal lesions in anxious children but can also be used to treat root caries in both the primary and permanent dentition. It is effective for root exposed surfaces and can help to reduce sensitivity as well as promote remineralisation. High caries risk patients

who are medically compromised or require additional support and cannot tolerate invasive treatment can also be indications for SDF use.

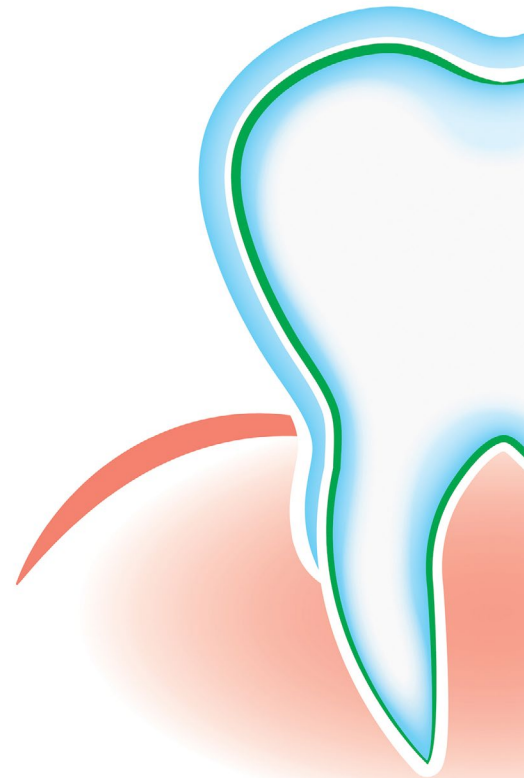
Contra-indications of its use are if the patient presents with clinical signs of pulpitis, dental abscess, infection or ongoing active lesions.² Summaries in Table 1 shows the advantages and disadvantages of SDF. It is important to consider that although SDF is used as a coping strategy to avoid restorations or extractions, some extent of cleansability by the patient is required to maintain good oral hygiene and to control the progression of caries.

‘High caries risk patients who are medically compromised or require additional support and cannot tolerate invasive treatment’

Mechanism of action

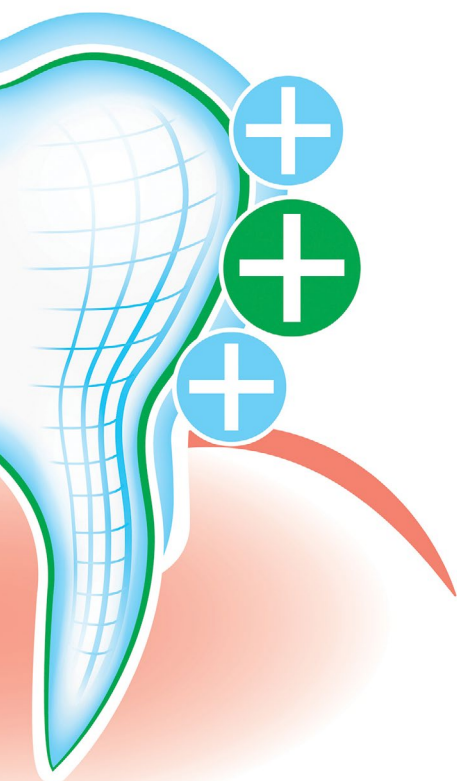
Although the mechanism remains unclear, there are numerous studies that propose the possible different methods of how the SDF interacts within the oral environment to arrest carious lesions.

1. 38% SDF contains 44,800ppm of fluoride.² The hydroxyl group of hydroxyapatite crystals, which makes up enamel, can be substituted by fluoride to form



fluorhydroxyapatite. This molecule is more thermodynamically stable and is more resistant to dissolution in acidic solutions and therefore inhibits demineralisation.

2. SDF effects the organic content of dentine by inhibiting matrix metalloproteinases and cysteine cathepsins which are responsible for degrading demineralised collagen.⁴
3. The silver ions within SDF affect cariogenic bacteria formation on carious lesions and act as an antimicrobial agent. It can break through the cell wall, disrupt cellular respiration and interfere with cell replication. Studies have demonstrated that dentinal caries lesions treated by SDF application have a lower bacterial count compared to those not treated with SDF.⁵
4. Chemical reactions between tooth tissue and components of SDF can help to reduce tooth sensitivity by depositing silver precipitates and calcium fluoride on exposed dentinal tubules.²

Table 1 Summarising the advantages and disadvantages of SDF^{2,3}

Advantages	Disadvantages
Helps maintain space in primary dentition	Difficult to monitor
Inexpensive	Black staining is not aesthetic
Better cooperation in anxious patients	Transient gingival irritation
Minimally invasive treatment	High fluoride concentration and potential toxicity
Remineralisation of the tooth	
Reduces sensitivity	

Table 2 ICDAS-II classification of visual and tactile features of an enamel or dentine lesion⁸

	Enamel		Dentine	
	Active lesion	Arrested lesion	Active lesion	Arrested lesion
Visual appearance	Dull and Matt	Shiny	Often lighter (may be covered in plaque)	Often lighter (may be free of dental plaque)
Tactile sensation	Rough	Smooth	Soft	Hard

Silver Modified Atraumatic Restorative Technique (SMART)

SDF can be used in conjunction with the Atraumatic Restorative Technique (ART) whereby hand instruments are used to prepare cavities with or without the use of local aesthetic because sound dentine is not removed.⁶ SDF can be placed immediately before placement of conventional glass ionomer cement as part of the Silver Modified Atraumatic Restorative Technique (SMART). The SMART procedure helps to eradicate cariogenic bacteria by sealing the restoration whilst enhancing pulp vitality and promoting remineralisation of the carious lesion.⁷

The use of rubber dam isolation is recommended to achieve good moisture control, safety and improve visual field. Petroleum jelly can also be applied to the lips and gingiva to reduce staining from SDF prior to application. The carious lesion should be dried beforehand and SDF should be applied onto the lesion via capillary action for 1 minute using a microbrush.²

After application, patients are encouraged to rinse their mouth using water because it helps to increase bond strength between GIC and sound dentine hence increasing the longevity of the restoration.¹ The

liquid SDF will turn active lesions black and harden tooth tissues softened due to dental decay. The discolouration only takes place on carious lesions and not healthy tooth structure. After a 2-4 week follow up appointment, if the lesion is still active then SDF may need to be reapplied.²

SDF can also be used in the management of symptomatic molar incisor hypomineralisation as the silver ions are able to form precipitates which occlude the exposed dentinal tubules, and this helps manage dentine hypersensitivity. The success of this procedure can be tested through simply blowing air from the 3-in-1 syringe onto the tooth to test for sensitivity.

Assessing the success of SDF

According to the ADA, it is unacceptable to use colour as the sole factor to assess the arrest and progression of a carious lesion.⁸ As shown in Table 2 and based on the ICDAS-II classifications, tactile sensation can help to provide a better diagnosis of whether the lesion is active or inactive. This can be done by gently running a BPE probe along the surface of the tooth to check for smoothness and hardness which may indicated an arrested lesion.

References

1. Knight G M and McIntyre J M. The effect of silver fluoride and potassium iodide on the bond strength of auto cure glass ionomer cement to dentine. *Aust Dent J* 2006; **51**: 42-45.
2. Seifo N, Robertson M, MacLean J, *et al.* The use of silver diamine fluoride (SDF) in dental practice. *Br Dent J* 2020; **228**: 75-81.
3. Patel J, Anthonappa R P and King N M. Silver Diamine Fluoride: a critical review and treatment recommendations. *Dent Update* 2019; **46**: 626-632.
4. Mei M L, Ito L, Cao Y, Li Q L, Lo E C and Chu C H. Inhibitory effect of silver diamine fluoride on dentine demineralisation and collagen degradation. *J Dent* 2013; **41**: 809-817.
5. Chu C H, Mei L E I, Seneviratne C J and Lo E C M. Effects of silver diamine fluoride on dentine carious lesions induced by *Streptococcus mutans* and *Actinomyces naeslundii* biofilms. *Int J Paediatr Dent* 2012; **22**: 2-10.
6. Scottish Dental Clinical Effectiveness Programme (SDCEP). Prevention and Management of Dental Caries in Children [Internet]. *NHS Education for Scotland Dental Clinical Guidance* 2018. Available from: www.sdcep.org.uk/wp-content/uploads/2018/05/SDCEP-Prevention-and-Management-of-Dental-Caries-in-Children-2nd-Edition.pdf (Accessed March 2021).
7. Alvear Fa B, Jew J A, Wong A and Young D. Silver Modified Atraumatic Restorative Technique (SMART): an alternative caries prevention tool. *Stoma Edu J* 2016; **3**: 18-24.
8. Slayton R L, Urquhart O, Araujo M W *et al.* Evidence-based clinical practice guideline on nonrestorative treatments for carious lesions: a report from the American Dental Association. *J Am Dent Assoc* 2018; **149**: 837-849.

Dharmit Modasia and Reema Modasia ■
<https://doi.org/10.1038/s41406-021-0199-1>