



Endovascular Aneurysm Repair in Patients with Conical Neck Anatomy

Jae Hoon Lee and Ki Hyuk Park

Division of Vascular and Endovascular Surgery, Department of Surgery, Catholic University of Daegu School of Medicine, Daegu, Korea

Purpose: Cone shape neck is regarded as non-instruction for use (IFU) in most commercial stent graft. However, in real practice, liberal application of endovascular aneurysm repair (EVAR) for outside of IFU happens. We investigate non-adherence to conical neck anatomy in terms of early aneurysmal exclusion results.

Materials and Methods: From January 2010 to December 2013, 105 patients with abdominal aortic aneurysm (AAA) underwent EVAR in Daegu Catholic University Medical Center. Among them, 38 patients (36.2%) had AAA with conical neck. We investigated the clinical characteristics of patients and the details of conical neck. We also analyzed the clinical results, such as endoleak, migration, procedure failure, perioperative mortality, and admission duration between conical neck and non-conical neck.

Results: The maximum diameter of AAA was larger (60.95 mm vs. 52.68 mm, $P=0.016$) and the infrarenal neck length was shorter (25.07 mm vs. 38.13 mm, $P=0.000$) in conical neck group. During the procedure, type Ia endoleak occurred more in conical neck group (23.7% vs. 6.0%, $P=0.013$) and it could be successfully solved with additional adjunctive treatments, such as balloon or Palmaz stent. Although there was no statistical significance, mortality was higher and admission duration was longer in the conical neck (15.8% vs. 6.0%, 16.62 ± 13.12 days vs. 13.03 ± 13.13 days). Mean follow-up duration was 319.2 ± 366.45 days. Successful aneurysmal exclusion was achieved.

Conclusion: The presence of conical neck may not be a contraindication for EVAR. However, conical neck requires careful observation for additional adjunctive treatments because it increases the risk of type Ia endoleak.

Key Words: Aortic aneurysm, abdominal, Endovascular procedures, Stents, Endoleak

Received March 8, 2017

Revised April 25, 2017

Accepted April 28, 2017

Corresponding author: Ki Hyuk Park

Division of Vascular and Endovascular Surgery, Department of Surgery, Catholic University of Daegu School of Medicine, 33 Duryugongwon-ro 17-gil, Nam-gu, Daegu 42472, Korea

Tel: 82-53-650-4053

Fax: 82-53-624-7185

E-mail: khpark@cu.ac.kr

Conflict of interest: None.

Copyright © 2017, The Korean Society for Vascular Surgery

This is an Open Access article distributed under the terms of the Creative Commons Attribution Non-Commercial License (<http://creativecommons.org/licenses/by-nc/4.0>) which permits unrestricted non-commercial use, distribution, and reproduction in any medium, provided the original work is properly cited.

Vasc Spec Int 2017;33(2):59-64 • <https://doi.org/10.5758/vsi.2017.33.2.59>

INTRODUCTION

Endovascular aneurysm repair (EVAR) has been highlighted as the current standard procedure for the treatment of abdominal aortic aneurysm (AAA), because the early mortality and morbidity were lower than open aneurysm

repair (OAR) [1]. In order to perform EVAR, suitable aneurysmal neck anatomy, such as length, angle and shape is needed. Specific anatomic requirements of the proximal aneurysm neck have been defined by aortic stent graft manufacturers as instructions for use (IFU). Many reports demonstrated difficulties performing EVAR in patients with

non-IFU neck anatomy. EVAR with non-IFU has been related with increased technical failure [2], type Ia endoleak [3,4] and secondary intervention [2,5]. As one of the hostile neck anatomy, conical neck is difficult to be sealed by the stent graft from aneurysmal sac and it is considered as a contraindication to EVAR in some reports [6-9]. Conical neck increased the risk of postprocedural complications such as proximal endoleak and stent graft migration [6,7,9,10]. Conical neck is variously defined for each articles (Table 1) [6,7,10-13]. Because most articles defined conical neck only by simple shape and diameter without considering the neck length, it were insufficient in view of the impact on the neck fixation in the EVAR. In this study, we classify neck anatomy according to the definition by Albertini et al. [11] considering the length and diameter of the AAA neck and evaluate the complications and mortality after EVAR.

MATERIALS AND METHODS

1) Study population

A retrospective data were collected for patients who underwent EVAR from January 2010 to December 2013

Table 1. The definitions of conical neck

Study	Definition
Stanley et al. [6]	Diameter progressively increases between the renal arteries and the sac with a proximal neck contour change >3 mm
Chuter [7]	Change in proximal neck diameter of >5 mm from proximal to distal
Dias et al. [10]	Increase in proximal neck diameter >2 mm for each cm of length
Albertini et al. [11]	'Neck coefficient' calculated using the following formula (diameter, D): $\text{Arctangent} ([D3-D1]/[\text{neck length}]) \times 180/\pi$ If the absolute value of the neck coefficient was >10, it was defined as conical or inverted conical; aortic neck configurations were defined as straight, conical, inverted conical, hourglass, or barrel types.
Jordan et al. [12]	The percentage increase in aortic neck diameter between the renal artery and a specified length distally. Conicity was defined through four levels: 5, 10, and 15 mm beyond to the renal artery and at the distal margin of the visual neck.
Farley et al. [13]	A greater than 3 mm increase in diameter within the first 10 mm of the aorta caudal to the renal artery.

in Daegu Catholic University Medical Center. The collection and analysis included demographic and outcome data. Among them, 38 patients had conical neck according to the definition [11]. We compared conical neck with non-conical neck in AAA patients who underwent EVAR.

2) Surgical procedure

All patients underwent EVAR of AAA under general anesthesia or epidural anesthesia in an operating room equipped with a portable fluoroscopy unit (GE-OEC 9900; GE Healthcare, Salt Lake City, UT, USA). Bilateral cut-down of the common or superficial femoral artery was performed in all cases. We used the Zenith device (Cook Medical, Bloomington, IN, USA) in most cases. In 10 cases, we used Endurant aorto uni iliac devices (Medtronic Endovascular, Santa Rosa, CA, USA) because the diameter of aortic bifurcation was less than 17 mm.

If we noticed the immediate type Ia endoleak after stent graft deployment, we priorly repeated balloon dilation of the proximal seal zone with Coda balloon (Cook Medical). If type Ia endoleak persisted, Palmaz balloon expandable stent (Cordis, Miami Lakes, FL, USA) was performed to seal the proximal neck of AAA. All Palmaz stents were placed just below the level of the lowest renal artery, with minimal to no overlap onto the native aorta.

3) Patient assessment

Three-dimensional computed tomographic angiography (3D CTA) was examined to plan EVAR and to check the aortoiliac anatomy. Measurements were performed on a TeraRecon workstation using Aquarius, iNtuition Ed ver 4.4.6 (TeraRecon Inc., Foster City, CA, USA) reformatting centerline and segmentating CTA data sets. The proximal and distal neck diameter, infrarenal neck length, infrarenal angulation, and the maximal diameter of AAA were obtained. Primarily, conical neck was determined by examining at the visual outward appearance of the neck and then we measured diameters using reconstructed images perpendicular to the longitudinal axis of the neck, at the level of the renal arteries (D1) and at the distal end of the neck (D2). Neck length (L) was measured along the longitudinal axis. Conical neck was defined according to Albertini et al. [11] introducing 'neck coefficient' to provide an objective and standardized definition of conical neck. The neck coefficient was calculated using the formula (Fig. 1). Conical neck was classified if the absolute value of the neck coefficient was 10 or more. Follow-up 3D CTA was performed within the postoperative 1 week and then at 6 months and every following year to determine the endoleak, fracture, kinking,

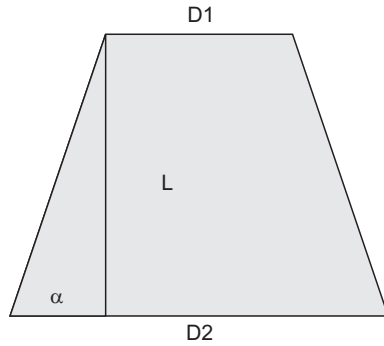


Fig. 1. Calculation of the neck coefficient (α). Conical neck ($\alpha \geq 10$), inverted conical neck ($\alpha \leq -10$), straight neck ($-10 < \alpha < 10$). α , arctangent $[(D2-D1)/L] \times 180/\pi$; D1, diameter at the level of the renal arteries; D2, diameter at the distal end of the neck; L, neck length.

migration, and patency of the stent graft.

4) Statistical analysis

Statistical analysis was performed using PASW Statistics ver. 18.0 software (IBM Co., Armonk, NY, USA). Continuous data are presented as mean and standard deviation. Categorical data are reported as the counts (percentage). The chi-square test or Fisher's exact test was used for comparison of qualitative variables and a Student t-test was used for comparison of continuous variables. P-value < 0.05 was considered to be statistically significant.

RESULTS

Analysis of patient demographics and past medical history (Table 2) did not differ significantly between the two groups. Mean age of the patients was 73.97 ± 7.70 years in conical neck group and 72.70 ± 7.75 years in non-conical neck group (P=0.419). The percentage of male was 78.9% in conical neck group and 85.1% in non-conical neck group (P=0.423). 24 patients (63.2%) in conical neck and 33 patients (49.3%) in non-conical neck had hypertension as comorbidity (P= 0.169).

Patients with conical neck differed significantly from non-conical neck in the maximum diameter of AAA and neck length. The maximum diameter of AAA was larger (60.95 mm vs. 52.68 mm, P=0.016) and the infrarenal neck length was shorter (25.07 mm vs. 38.13 mm, P=0.000) in conical neck group. Neck angulation was similar in both groups (48.25 vs. 46.49, P=0.785) (Table 3).

Investigating the conical neck group in detail (Table 4), average diameter ratio was 141.92% when diameter ratio was defined as the ratio of distal neck diameter (D2) divided

Table 2. Patients' clinical characteristics

Variable	Non-conical neck (n=67)	Conical neck (n=38)	P-value
Age (y)	72.70±7.75	73.97±7.70	0.419
Male	57 (85.1)	30 (78.9)	0.423
Hypertension	33 (49.3)	24 (63.2)	0.169
Ischemic heart disease	14 (20.9)	12 (31.6)	0.223
Cerebrovascular accident	11 (16.4)	10 (26.3)	0.223
Diabetes mellitus	10 (14.9)	4 (10.5)	0.766
Chronic obstructive pulmonary disease	7 (10.4)	5 (13.2)	0.675
Chronic renal failure	2 (3.0)	3 (7.9)	0.350
Smoking	21 (31.3)	16 (42.1)	0.267

Values are presented as mean±standard deviation or number (%).

Table 3. The details of abdominal aortic aneurysm figure

Variable	Non-conical neck (n=67)	Conical neck (n=38)	P-value
AAA maximal diameter (mm)	52.68±17.64	60.95±14.59	0.016 ^a
Neck angulation (°)	46.49±33.01	48.25±29.20	0.785
Neck length (mm)	38.13±17.06	25.07±12.66	0.000 ^a

Values are presented as mean±standard deviation.

AAA, abdominal aortic aneurysm.

^aP<0.05 (Student's t-test).

Table 4. The details of conical neck

Hostile condition	Conical neck (n=38)
Diameter ratio >160%	7 (18.4)
Neck angulation >60°	12 (31.6)
Neck length <15 mm	7 (18.4)

Values are presented as number (%).

Diameter ratio (%)=distal neck diameter/proximal neck diameter.

by proximal neck diameter (D1) (diameter ratio [%]=D2/D1×100). In 38 patients with conical neck, 7 patients had severe conic shape with 160% or more diameter ratio. Severe neck angulation (>60°) and severe shorter neck (<15 mm) were accompanied by conical neck in 12 patients (31.6%) and 7 patients (18.4%).

The immediate type Ia endoleak after stent-graft deployment was frequent in the conical neck (23.7% vs. 6.0%, P=0.013), but it was successfully solved with additional adjunctive treatments using balloon or Palmaz stent. Although there was no statistical significance, overall mortality during follow-up was higher (15.8% vs. 6.0%, P=0.163) and admission duration was longer in the conical neck (16.62

days vs. 13.03 days, P=0.187). Twelve patients (11.4%) with ruptured AAA were included in this study. Among these patients, 4 patients with conical neck and 2 patients with non-conical neck expired after EVAR during perioperative period. No stent graft migration was detected in our series (Table 5).

According to the analysis of type Ia endoleak by neck anatomy (Table 6), conical neck and short neck were the risk factors of type Ia endoleak in both univariate and multivariate analysis.

DISCUSSION

EVAR has substituted OAR as the more common treatment of choice for patients with AAA after the first introduction of EVAR in 1988 [14]. However there are several limitations to execute EVAR. Since earnest research about EVAR in the early 1990s, it has been considered that post-procedural complications (proximal endoleak and stent graft migration) are related with aortic neck anatomy difficult to stent graft proximal seal [15]. The term ‘hostile neck’ with unfavorable aortic neck anatomy was introduced for the first time in 2003 [16]. In many studies including meta-analysis and review articles, adverse clinical events and imaging findings occurred in hostile neck [17-19]. The incidence of conical neck, one of the hostile neck anatomy in AAA patients which underwent EVAR had been reported from 18% to 24% [6,10,11]. The effectiveness and safety of EVAR has been debatable in AAA patients with conical neck, because making a reliable seal was difficult to achieve. Conical neck had the risk of postprocedural complications due to the difficulty of proximal stent graft fixation and seal in some papers [6,7,9,10]. On the contrary, the length, angle and size rather than the shape of the neck had been introduced as risk factors for type Ia endoleak in other

papers [11,12]. The European Collaborators on Stent Graft Techniques for Aortic Aneurysm Repair database demonstrates a significantly increased risk of type Ia endoleaks at short-term and medium-term follow-up with short (<15 mm) proximal neck and higher incidences of proximal neck dilation, type Ia endoleak, and need for secondary interventions with severe (>60°) infrarenal aortic neck angulation [5]. In our study, the proportion of conical neck occupied 36.2% in AAA patients who received EVAR by the definition of conical neck considering the length of the neck. Type Ia endoleak occurred more frequently in conical neck and short (<15 mm) proximal neck in both univariate and multivariate analysis. Because endoleak after EVAR is important to the risk of sac expansion and rupture if left untreated, secondary intervention is required to prevent endoleak [20]. AAA patients with conical neck shape had the larger maximum diameter of AAA (P=0.016), the smaller length of infrarenal neck (P=0.000) and severe angled neck (>60°, 31.6%). Such hostile neck anatomies accompanied with conical neck seem to increase the frequency of type Ia endoleak. Precise and delicate planning on morphologic evaluations of the proximal neck before EVAR is vital to prevent endoleak.

Oversizing has also made a significant decrease in proximal endoleak to provide suitable seal in the proximal landing zone. Stent graft oversizing within the range of 10% to 20% larger than AAA neck diameter has been recommended [21-23]. Oversizing by the most distal and largest aortic neck diameter in a conical neck may happen to an excessive oversizing for the proximal neck diameter. Excessive oversizing (>20%) of stent graft may aggravate this late aortic neck dilation. Late aortic neck dilation was significantly related to migration [24]. Excessive oversizing (>30%) with the Zenith AAA Endovascular Graft increased the risk of device migration and AAA expansion [25]. On the contrary, Mwipatayi et al. [26] suggested that excessive oversizing (>30%) was appropriate and they had no evidence of type Ia endoleak and distal migration although the proximal neck oversizing was significantly larger in the conical neck (42.9%±17.5%). We chose the stent graft size within the range of 10% to 20% greater than the most

Table 5. Follow-up results

Variable	Non-conical neck (n=67)	Conical neck (n=38)	P-value
Post deploy immediate type Ia endoleak	4 (6.0)	9 (23.7)	0.013 ^a
Additive procedure for type Ia endoleak	Palmaz stent: 2 cases Reballoon: 2 cases	Palmaz stent: 5 cases Reballoon: 4 cases	
Stent graft migration	0	0	
Admission duration (d)	13.03±13.13	16.62±13.12	0.187
Overall mortality	4 (6.0)	6 (15.8)	0.163

Values are presented as number (%) or mean±standard deviation. ^aP<0.05 (Student’s t-test, chi-square test).

Table 6. Analysis of type Ia endoleak by neck anatomy

Variable	Univariate (P-value)	Multivariate	
		OR (95% CI)	P-value
Conical neck	0.013 ^a	7.133 (1.419-35.851)	0.017 ^a
Short neck (<15 mm)	0.019 ^a	17.127 (2.389-122.804)	0.005 ^a
Angled neck (>60°)	0.336	2.826 (0.695-11.490)	0.147

OR, odds ratio; CI, confidence interval.

^aP<0.05 (Chi-square test, logistic regression).

distal and largest neck diameter. The incidence of endoleak was higher in the conical neck but it overcame with a simple adjuvant treatment. Excessive proximal oversizing could reinforce wall contact and proximal seal by radial forces. Excessive proximal oversizing does not make the in folding or wrinkling of graft fabric based on the experiments using in vitro glass model. The stretching and narrowing of stent graft unlike the original size in proximal neck may be considered reasonable.

Our hospital policy has been considering EVAR as a priority and had many EVAR (105 cases). When the standard EVAR was not available for the aneurysm structure, modified EVAR (3 cases) and open repair (23 cases) were performed. The more stent graft materials, technologies, intraoperative adjuncts, and surgical experiences developed, the more outcomes following EVAR in patients with hostile neck improved. To overcome hostile neck including conical neck, the flexible and conformable stent grafts with proximal anchoring pins were suggested [27,28]. Custom-made fenestrated endograft systems and the chimney graft technique have been invented to solve anatomic limitations [29,30]. Our data showed higher frequency of type Ia endoleak after EVAR with conical neck anatomy and we overcame endoleak by intraoperative adjuncts, such as ballooning and balloon-expandable bare stent.

The limitation of this study relates to the length of follow-up. The mean follow-up duration of this study was less than 1 year. Many see conical necks as an early stage in the process of aneurysmal dilatation and therefore do not consider this to be normal aorta. This can lead to neck failure from disease progression, which can lead to delayed type I endoleak or stent migration. This study's follow-up duration is too short to truly evaluate these complications. The retrospective study and single center experience could be also the limitations of this study.

In conclusion, conical neck was associated with in the high frequency of type Ia endoleak and we successfully overcame the endoleak with additional adjuvant treatment. Conical neck might not be the contraindication of EVAR in AAA patients, but may require additional procedure. Preoperative accurate planning and postoperative frequent surveillance program is necessary for early detection and rapid response to treat the postprocedural complications in conical neck with AAA patients following EVAR. Furthermore long-term follow-up should be mandatory.

ACKNOWLEDGEMENTS

This work was supported by research grants from the Catholic University of Daegu in 2014.

REFERENCES

- 1) Schermerhorn ML, O'Malley AJ, Jhaveri A, Cotterill P, Pomposelli F, Landon BE. Endovascular vs. open repair of abdominal aortic aneurysms in the Medicare population. *N Engl J Med* 2008;358:464-474.
- 2) Sternbergh WC 3rd, Carter G, York JW, Yoselevitz M, Money SR. Aortic neck angulation predicts adverse outcome with endovascular abdominal aortic aneurysm repair. *J Vasc Surg* 2002; 35:482-486.
- 3) Abbruzzese TA, Kwolek CJ, Brewster DC, Chung TK, Kang J, Conrad MF, et al. Outcomes following endovascular abdominal aortic aneurysm repair (EVAR): an anatomic and device-specific analysis. *J Vasc Surg* 2008;48:19-28.
- 4) Aburahma AF, Campbell JE, Mousa AY, Hass SM, Stone PA, Jain A, et al. Clinical outcomes for hostile versus favorable aortic neck anatomy in endovascular aortic aneurysm repair using modular devices. *J Vasc Surg* 2011; 54:13-21.
- 5) Hobo R, Kievit J, Leurs LJ, Buth J; Eurostar Collaborators. Influence of severe infrarenal aortic neck angulation on complications at the proximal neck following endovascular AAA repair: a EUROSTAR study. *J Endovasc Ther* 2007;14:1-11.
- 6) Stanley BM, Semmens JB, Mai Q, Goodman MA, Hartley DE, Wilkinson C, et al. Evaluation of patient selection guidelines for endoluminal AAA repair with the Zenith Stent-Graft: the Australasian experience. *J Endovasc Ther* 2001;8:457-464.
- 7) Chuter TA. Stent-graft design: the good, the bad and the ugly. *Cardio-vasc Surg* 2002;10:7-13.
- 8) Andrews SM, Cuming R, Macsweeney ST, Barrett NK, Greenhalgh RM, Nott DM. Assessment of feasibility for endovascular prosthetic tube correction of aortic aneurysm. *Br J Surg* 1995;82: 917-919.
- 9) Lobato AC, Quick RC, Vaughn PL, Rodriguez-Lopez J, Douglas M, Diethrich EB. Transrenal fixation of aortic endografts: intermediate follow-up of a single-center experience. *J Endovasc Ther* 2000;7:273-278.
- 10) Dias NV, Resch T, Malina M, Lindblad B, Ivancev K. Intraoperative proximal endoleaks during AAA stent-graft repair: evaluation of risk factors and treatment with Palmaz stents. *J Endovasc Ther* 2001;8:268-273.
- 11) Albertini J, Kalliafas S, Travis S, Yusuf SW, Macierewicz JA, Whitaker SC, et

- al. Anatomical risk factors for proximal perigraft endoleak and graft migration following endovascular repair of abdominal aortic aneurysms. *Eur J Vasc Endovasc Surg* 2000;19:308-312.
- 12) Jordan WD Jr, Ouriel K, Mehta M, Varnagy D, Moore WM Jr, Arko FR, et al. Outcome-based anatomic criteria for defining the hostile aortic neck. *J Vasc Surg* 2015;61:1383-1390.e1.
- 13) Farley SM, Rigberg D, Jimenez JC, Moore W, Quinones-Baldrich W. A retrospective review of Palmaz stenting of the aortic neck for endovascular aneurysm repair. *Ann Vasc Surg* 2011;25:735-739.
- 14) Schwarze ML, Shen Y, Hemmerich J, Dale W. Age-related trends in utilization and outcome of open and endovascular repair for abdominal aortic aneurysm in the United States, 2001-2006. *J Vasc Surg* 2009;50:722-729. e2.
- 15) Fox AD, Whiteley MS, Murphy P, Budd JS, Horrocks M. Comparison of magnetic resonance imaging measurements of abdominal aortic aneurysms with measurements obtained by other imaging techniques and intraoperative measurements: possible implications for endovascular grafting. *J Vasc Surg* 1996;24:632-638.
- 16) Dillavou ED, Muluk SC, Rhee RY, Tzeng E, Woody JD, Gupta N, et al. Does hostile neck anatomy preclude successful endovascular aortic aneurysm repair? *J Vasc Surg* 2003;38:657-663.
- 17) Antoniou GA, Georgiadis GS, Antoniou SA, Kuhan G, Murray D. A meta-analysis of outcomes of endovascular abdominal aortic aneurysm repair in patients with hostile and friendly neck anatomy. *J Vasc Surg* 2013;57:527-538.
- 18) Stather PW, Wild JB, Sayers RD, Bown MJ, Choke E. Endovascular aortic aneurysm repair in patients with hostile neck anatomy. *J Endovasc Ther* 2013;20:623-637.
- 19) Rockman CB, Lamparello PJ, Adelman MA, Jacobowitz GR, Therff S, Gagne PJ, et al. Aneurysm morphology as a predictor of endoleak following endovascular aortic aneurysm repair: do smaller aneurysms have better outcomes? *Ann Vasc Surg* 2002;16:644-651.
- 20) Fransen GA, Vallabhaneni SR Sr, van Marrewijk CJ, Laheij RJ, Harris PL, Buth J, et al. Rupture of infra-renal aortic aneurysm after endovascular repair: a series from EUROSTAR registry. *Eur J Vasc Endovasc Surg* 2003;26:487-493.
- 21) van Prehn J, Schlösser FJ, Muhs BE, Verhagen HJ, Moll FL, van Herwaarden JA. Oversizing of aortic stent grafts for abdominal aneurysm repair: a systematic review of the benefits and risks. *Eur J Vasc Endovasc Surg* 2009;38:42-53.
- 22) Mohan IV, Laheij RJ, Harris PL; Eurostar Collaborators. Risk factors for endoleak and the evidence for stent-graft oversizing in patients undergoing endovascular aneurysm repair. *Eur J Vasc Endovasc Surg* 2001;21:344-349.
- 23) Lin KK, Kratzberg JA, Raghavan ML. Role of aortic stent graft oversizing and barb characteristics on folding. *J Vasc Surg* 2012;55:1401-1409.
- 24) Connors MS 3rd, Sternbergh WC 3rd, Carter G, Tonnessen BH, Yoselevitz M, Money SR. Endograft migration one to four years after endovascular abdominal aortic aneurysm repair with the AneuRx device: a cautionary note. *J Vasc Surg* 2002;36:476-484.
- 25) Sternbergh WC 3rd, Money SR, Greenberg RK, Chuter TA; Zenith Investigators. Influence of endograft oversizing on device migration, endoleak, aneurysm shrinkage, and aortic neck dilation: results from the Zenith multicenter trial. *J Vasc Surg* 2004;39:20-26.
- 26) Mwiapatayi BP, Picardo A, Wong J, Thomas SD, Vijayan V. Endovascular repair of abdominal aortic aneurysms with reverse taper neck anatomy using the Endurant stent-graft: analysis of stent-graft oversizing. *J Endovasc Ther* 2013;20:514-522.
- 27) Albertini JN, Perdikides T, Soong CV, Hinchliffe RJ, Trojanowska M, Yusuf SW. Endovascular repair of abdominal aortic aneurysms in patients with severe angulation of the proximal neck using a flexible stent-graft: European multicenter experience. *J Cardiovasc Surg (Torino)* 2006;47:245-250.
- 28) Setacci F, Sirignano P, de Donato G, Chisci E, Iacoponi F, Galzerano G, et al. AAA with a challenging neck: early outcomes using the Endurant stent-graft system. *Eur J Vasc Endovasc Surg* 2012;44:274-279.
- 29) British Society for Endovascular Therapy and the Global Collaborators on Advanced Stent-Graft Techniques for Aneurysm Repair (GLOBALSTAR) Registry. Early results of fenestrated endovascular repair of juxtarenal aortic aneurysms in the United Kingdom. *Circulation* 2012;125:2707-2715.
- 30) Antoniou GA, Schiro A, Antoniou SA, Farquharson F, Murray D, Smyth JV, et al. Chimney technique in the endovascular management of complex aortic disease. *Vascular* 2012;20:251-261.