



RESEARCH

Open Access

# Influence of lip closure on alveolar cleft width in patients with cleft lip and palate

Wolfgang Eichhorn<sup>1</sup>, Marco Blessmann<sup>2</sup>, Oliver Vorwig<sup>2</sup>, Gerd Gehrke<sup>3</sup>, Rainer Schmelzle<sup>2</sup>, Max Heiland<sup>2\*</sup>

## Abstract

**Background:** The influence of surgery on growth and stability after treatment in patients with cleft lip and palate are topics still under discussion. The aim of the present study was to investigate the influence of early lip closure on the width of the alveolar cleft using dental casts.

**Methods:** A total of 44 clefts were investigated using plaster casts, 30 unilateral and 7 bilateral clefts. All infants received a passive molding plate a few days after birth. The age at the time of closure of the lip was 2.1 month in average (range 1-6 months). Plaster casts were obtained at the following stages: shortly after birth, prior to lip closure, prior to soft palate closure. We determined the width of the alveolar cleft before lip closure and prior to soft palate closure measuring the alveolar cleft width from the most lateral point of the premaxilla/anterior segment to the most medial point of the smaller segment.

**Results:** After lip closure 15 clefts presented with a width of 0 mm, meaning that the mucosa of the segments was almost touching one another. 19 clefts showed a width of up to 2 mm and 10 clefts were still over 2 mm wide. This means a reduction of 0% in 5 clefts, of 1-50% in 6 clefts, of 51-99% in 19 clefts, and of 100% in 14 clefts.

**Conclusions:** Early lip closure reduces alveolar cleft width. In most cases our aim of a remaining cleft width of 2 mm or less can be achieved. These are promising conditions for primary alveolar bone grafting to restore the dental bony arch.

## Background

The treatment of children with a cleft lip and palate remains a challenge. Beginning at birth, it is necessary to balance several aspects of treatment such as growth, esthetics, function, and psychosocial development. Especially in children with a complete bilateral cleft lip and palate, many problems remain unsolved. Apart from intrinsic tissue deficiency and anatomic aberrations, there is difficulty in restoring the orbicularis oris muscle, in creating a philtrum, and in lengthening the columella. Furthermore, benefit of early orthopedic treatment is still questioned. Unrestricted premaxillary growth also gives rise to many problems. Surgeons have not reached consensus regarding best type and timing of lip- and palatal closure. Similarly, orthodontists have not reached agreement on early management of the alveolar segment position before lip closure. Some promoted the use of

active or passive intra-oral appliances in order to normalize alveolar segment position before lip closure. This would enable the surgeon to operate with less tension on the soft tissues. Others have advocated the use of extra-oral strapping placed. Finally, the influence of surgery on further growth and stability after treatment are topics still under discussion [1-10]. According to the Muenster treatment protocol an early lip closure is performed at the age of 4-6 months [7], while Anastassov and Joos prefer an age of 3 months [5]. According to the Hamburg treatment protocol lip closure is performed even earlier at the age of 8 weeks in the mean and can be classified as a very early lip closure.

The aim of the present study was to investigate the influence of early lip closure on the width of the alveolar cleft using dental casts.

## Methods

37 patients (21 male, 16 female) were evaluated in this study. A total of 44 clefts were investigated using plaster casts, 30 unilateral and 7 bilateral clefts. All infants

\* Correspondence: [m.heiland@uke.de](mailto:m.heiland@uke.de)

<sup>2</sup>Department of Oral and Maxillofacial Surgery, University Medical Center Hamburg-Eppendorf, Martinistr. 52, 20246 Hamburg, Germany  
Full list of author information is available at the end of the article

received a passive molding plate a few days after birth. The age at the time of closure of the lip was 2.1 month in average (range 1-6 months). The one patient with the age of 6 months suffered from a hydrocephalus, whereby an earlier operation could not be realized. The surgical procedure was performed according to Tension or Millard. The closure of the soft palate was performed at the age of 8.5 months in average (range 4-17 months).

Orthodontic plaster casts were obtained at the following stages: shortly after birth, prior to lip closure, and prior to soft palate closure. We determined the width of the alveolar cleft before lip closure and prior to soft palate closure measuring the alveolar cleft width from the most lateral point of the premaxilla/anterior segment to the most medial point of the smaller segment according to Sillmann and Robertson et al. [1,11].

Due to the small number of cases, a descriptive analysis was performed. The reduction of alveolar cleft width after lip closure in mm and in percent to the original alveolar cleft width were calculated.

### Results

After lip closure 15 clefts presented with a width of 0 mm, meaning that the mucosa of the segments of both sides were in direct contact. 19 clefts showed a width of up to 2 mm and 10 clefts were still over 2 mm wide. The relative reduction compared to the original cleft width revealed a reduction of 0 percent in 5 five clefts. In one case an original cleft width of 0 mm before lip closure did not enhance and stayed small. Small clefts stayed small. 6 clefts showed a reduction of 1-50%, 19 a reduction of 51-99% and 14 a reduction of 100%. A 100% reduction means that the cleft segments were in direct contact (table 1).

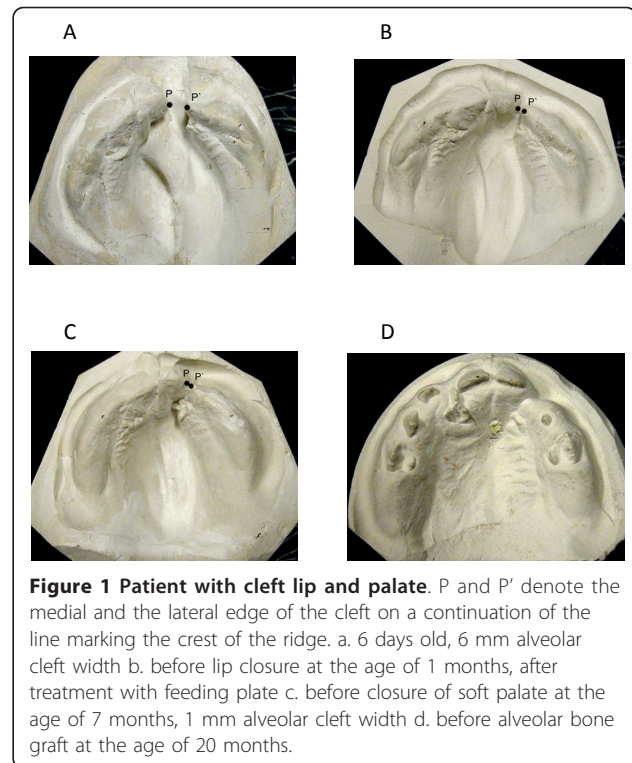
Additional dental casts obtained in single cases at later surgical procedures prove a rapid initial reduction of alveolar cleft width followed by a reduced velocity of movement (Figure 1, 2).

### Discussion

Active maxillary appliances are constructed to move alveolar segments in a predetermined manner with

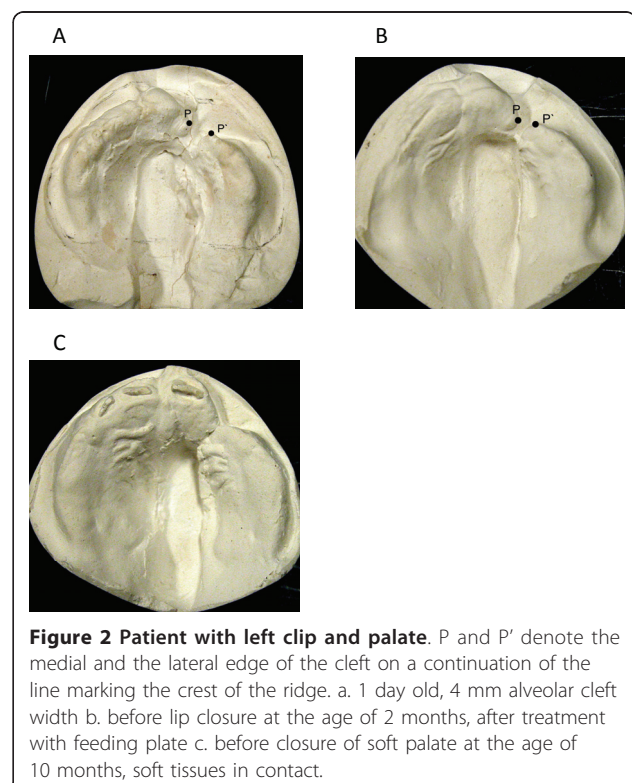
**Table 1 Alveolar cleft width and reduction of cleft width at time of soft palate closure**

Alveolar cleft width (mm)	Number of patients
0	15
up to 2	19
more than 2	10
<b>Reduction of cleft width (%)</b>	
0	5
1-50	6
51-99	19
100	14



**Figure 1 Patient with cleft lip and palate.** P and P' denote the medial and the lateral edge of the cleft on a continuation of the line marking the crest of the ridge. a. 6 days old, 6 mm alveolar cleft width b. before lip closure at the age of 1 months, after treatment with feeding plate c. before closure of soft palate at the age of 7 months, 1 mm alveolar cleft width d. before alveolar bone graft at the age of 20 months.

controlled force. The use of pin-retained appliances to expand collapsed alveolar segments while retracting the premaxilla in the case of a bilateral cleft and in unilateral cleft cases has been repeatedly advised [12-16].



**Figure 2 Patient with left cleft lip and palate.** P and P' denote the medial and the lateral edge of the cleft on a continuation of the line marking the crest of the ridge. a. 1 day old, 4 mm alveolar cleft width b. before lip closure at the age of 2 months, after treatment with feeding plate c. before closure of soft palate at the age of 10 months, soft tissues in contact.

In contrast, passive maxillary appliances do not provide any force. They act as a fulcrum for the forces created by the surgical lip closure, to contour and mold the alveolar segments in a predictable fashion [6,17]. Also a nasoalveolar molding as soon as possible after birth and nonsurgical lip adhesion by placing a tape across the upper lip have been proposed. The tape aids in the closure of the cleft, decreases the width of the base of the nose and helps to approximate the lip [6,17-20]. In our study a passive feeding plate in combination with an early lip closure with a restored orbicularis oris muscle was used for molding with 34 clefts being less than 2 mm wide at the time of soft palate closure. Therefore, an active appliance and two-staged lip repair as advocated seemed not to be necessary [21]. This achieved approximation would facilitate primary bone grafting of the alveolar cleft, if desired. The use of calvarian bone instead of bone from the iliac crest or mandible seems to be a promising alternative in bridging narrow alveolar defects [22].

In the 7<sup>th</sup> week of pregnancy a cleft lip and palate inhibit the closure of the muscle rings of the mimic musculature and on the pharynx. The facial midsagittal axis is deviated to the non-cleft side because the muscles of the midface and lip are not attached to the septo-vomerine growth center. These insufficient muscular stimuli lead to skeletal changes we observe in cases of a cleft lip. Via reconstruction of the musculature the bones, for the most part, are able to develop normally. Keeping this in mind corrective surgery should be carried out as early as possible at the age of 3-4 months without using preoperative orthodontic appliances [5,7,23-27]. In our study, lip closure was performed even a little bit earlier (average 2.1 months) and passive feeding plates to facilitate breast feeding and to prevent tongue displacement in the palatal gap were used.

After lip closure the intercanine width, the growth of the arch depth and the intercanine width were significantly reduced showing an immediate effect of lip closure on maxillary arch shape. In the period between lip closure and palatal closure growth of the palatal arches changed into direction of the non-cleft controls while growth velocity of the intercanine width and the anterior arch remained less than the non-cleft controls [4,15,28].

As a modern alternative for analyzing orthodontic plaster cast models a 3D digital stereophotogrammetry can be used. This may also help to facilitate the documentation [29].

Attempts to close the lip cleft in-utero in a lamb model proved to have the advantage of scarless wound healing in the fetus and would also have positive effects on the alveolar cleft width. There was no inhibition of maxillary growth in the animals that underwent in-utero

cleft lip repair in contrast to the neonatal group showing significant maxillary retrusion. However both lip repairs, the in-utero and neonatal group, produced significant shorter lips than the contralateral noncleft sides requiring a secondary lip revision. Thereby, the purpose of an intrauterine repair is defeated today [30-32].

## Conclusions

Early lip closure reduces alveolar cleft width. In most cases our aim of a remaining cleft width of 2 mm or less can be achieved. These are good conditions for primary alveolar bone grafting to restore the dental bony arch.

## Author details

<sup>1</sup>Department of Oral and Maxillofacial Surgery, General Hospital Balingen, Tübinger Str. 30, 72336 Balingen, Germany. <sup>2</sup>Department of Oral and Maxillofacial Surgery, University Medical Center Hamburg-Eppendorf, Martinistr. 52, 20246 Hamburg, Germany. <sup>3</sup>Department of Oral and Maxillofacial Surgery, Henriettenstiftung Hannover, Marienstr. 72-90, 30171 Hannover, Germany.

## Authors' contributions

WE and MH conceptualized the paper. WE, MH, MB, OV drafted and edited the manuscript. GG and RS were responsible for the treatment algorithm and performed the surgical procedures. All authors have read and approved the final manuscript.

## Competing interests

The authors declare that they have no competing interests.

Received: 18 October 2010 Accepted: 26 January 2011

Published: 26 January 2011

## References

1. Robertson N, Shaw W, Volp C: The changes produced by presurgical orthopedic treatment of bilateral cleft lip and palate. *Plast Reconstr Surg* 1977, **59**:86-93.
2. Bardach J: The influence of cleft lip repair on facial growth. *Cleft Palate J* 1990, **27**:76-78.
3. Heidbuchel KLWM, Kuijpers-Jagtman AM: Maxillary and mandibular dental-arch dimensions and occlusion in bilateral cleft lip and palate patients from 3 to 17 years of age. *Cleft Palate-Craniofac J* 1997, **34**:21-26.
4. Heidbuchel KLWM, Kuijpers-Jagtman AM, Van'tHof MA, Kramer GJC, Prah Andersen B: Effects of early treatment on maxillary arch development in BCLP. A study on dental casts between 0 and 4 years of age. *J Cranio-Maxillofac Surg* 1998, **26**:140-147.
5. Anastassov GE, Joos U: Comprehensive management of cleft lip and palate deformities. *J Oral Maxillofac J* 2001, **59**:1062-1075.
6. Cho BC: Unilateral complete cleft lip and palate repair using lip adhesion combined with a passive intraoral molding appliance: surgical results and the effect on the maxillary alveolar arch. *Plast Reconstr Surg* 2006, **15**:1510-1529.
7. Joos U, Wermker K, Kruse-Loessler B, Kleinheinz J: Influence of treatment concept, velopharyngoplasty, gender and age on hypernasality in patients with cleft lip, alveolus and palate. *J Cranio-Maxillofac Surg* 2006, **34**:472-477.
8. Al-Gunaid T, Asahito T, Yamaki M, Hanada K, Takagi R, Ono K, Saito I: Relapse tendency in maxillary arch width in unilateral cleft lip and palate patients with different maxillary arch forms. *Cleft Palate-Craniofac J* 2008, **45**:278-283.
9. Le Pendeven R, Mayrnot-Duquennoy V, Pellerin P: Long-term morphologic results of a 32 successive patients series presenting unilateral complete cleft lip and palate with surgery at early age. *Ann Chir Plast Esthet* 2009, **54**:7-15.

10. Ruotolo RA, Fearon JA: **Cleft lip repair: a unique sutureless skin closure technique.** *Plast Reconstr Surg* 2009, **123**:109-111.
11. Sillmann JH: **Dimensional changes of the dental arches: Longitudinal study from birth to 25 years.** *Am J Orthodont* 1964, **50**:824-842.
12. Georgiade NG, Latham RA: **Maxillary arch alignment in the bilateral cleft lip and palate infant using the pinned coaxial screw appliance.** *Plast Reconstr Surg* 1975, **56**:52-60.
13. Latham RA, Kusy RP, Georgiade NG: **An intraorally activated expansion appliance for cleft palate infants.** *Cleft palate J* 1976, **13**:253-261.
14. Latham RA: **Orthopedic advancement of the cleft maxillary segment: A preliminary report.** *Cleft Palate J* 1980, **17**:227-233.
15. Hotz M, Gnoinsky W: **Comprehensive care of cleft lip and palate children at Zurich University: a preliminary report.** *Am J Orthod Dentofac Orthop* 1976, **70**:481-504.
16. Hotz M, Perko M, Gnoinski W: **Early orthopaedic stabilization of the praemaxilla in complete bilateral cleft lip and palate in combination with the celesnik repair.** *Scand J Reconstr Surg* 1987, **21**:45-51.
17. Suri S, Tompson BD: **A modified muscle-activated maxillary orthopedic appliance for presurgical nasoalveolar molding in infants with unilateral cleft lip and palate.** *Cleft Palate-Craniofacial J* 2004, **41**:225-229.
18. Moss ML, Salentijn L: **The primary role of functional matrices in facial growth.** *Am J Orthodont* 1969, **55**:566-577.
19. Grayson BH, Cutting CB: **Presurgical nasoalveolar orthopedic molding in primary correction of the nose, lip, and alveolus of infants born with unilateral and bilateral clefts.** *Cleft Palate-Craniofacial J* 2001, **38**:193-198.
20. Liou EJ, Subramanian M, Chen PKT, Huang CS: **The progressive changes of nasal symmetry and growth after nasoalveolar molding: a three-year follow up study.** *Plast Reconstr Surg* 2004, **114**:858-864.
21. Millard DR, Latham R, Huifen X, Spiro S, Morovic C: **Cleft lip and palate treated by presurgical orthopedics, gingivoperiosteoplasty, and lip adhesion (popla) compared with previous lip adhesion method: a preliminary study of serial dental casts.** *Plast Reconstr Surg* 1999, **103**:1630-1644.
22. Eichhorn W, Blessmann M, Pohlenz P, Blake FAS, Gehrke G, Schmelzle R, Heiland M: **Primary osteoplasty using calvarian bone in patients with cleft lip, alveolus and palate.** *J Cranio-Maxillofac Surg* 2009, **37**:429-433.
23. Delaire J, Fève JR, Chateau JP, Courtay D, Tulasne JF: **Anatomie et physiologie des muscles et du frein median de la lèvre supérieure: Premiers resultats de l'électromyographie selective.** *Rev Stomatol* 1977, **78**:93-103.
24. Joos U, Friedburg H: **Darstellung und Verlauf der mimischen Muskulatur in der Kernspintomographie.** *Fortschr Kiefer Gesichtschir* 1987, **32**:125-127.
25. Joos U: **Skeletal growth after muscular reconstruction for cleft lip, alveolus, and palate.** *Br J Oral Maxillofac Surg* 1995, **33**:139-144.
26. Joos U: **Muscle reconstruction in primary cleft lip surgery.** *J Cranio-Maxfac Surg* 1989, **17**:8-10.
27. Joos U: **The importance of muscular reconstruction in the treatment of cleft lip and palate.** *Scand J Plast Reconstr Surg* 1987, **21**:109-113.
28. Kramer GJC, Hoeksma JB, Prah-Andersen B: **Palatal changes after lip surgery in different types of cleft lip and palate.** *Cleft Palate-Craniofacial J* 1994, **31**:376-384.
29. Heike CL, Upson K, Stuhaug E, Weinberg SM: **A practical guide to facial image acquisition.** *Head and Face Medicine* 2010, **6**:6-18.
30. Stelnicki EJ, Lee S, Hoffmann W, Lopoo J, Foster R, Harrison M, Longaker M: **A long-term, controlled-outcome analysis of in utero versus neonatal cleft lip repair using an ovine model.** *Plast Reconstr Surg* 1999, **104**:607-615.
31. Oberg K, Robles A, Ducsay C, Childers B, Rasi C, Gates D, Kirsch WM, Hardesty R: **Endoscopic excision and repair of simulated bilateral cleft lips in fetal lambs.** *Plast Reconstr Surg* 1998, **102**:1-9.
32. Wenghoefer MHO, Deprest J, Goetz W, Kuijpers-Jagtman AM, Bergé S: **Prenatal cleft lip and maxillary alveolar defect repair in a 2-step fetal lamb model.** *J Oral Maxillofac Surg* 2007, **65**:2479-2486.

doi:10.1186/1746-160X-7-3

**Cite this article as:** Eichhorn et al.: Influence of lip closure on alveolar cleft width in patients with cleft lip and palate. *Head & Face Medicine* 2011 **7**:3.

**Submit your next manuscript to BioMed Central and take full advantage of:**

- Convenient online submission
- Thorough peer review
- No space constraints or color figure charges
- Immediate publication on acceptance
- Inclusion in PubMed, CAS, Scopus and Google Scholar
- Research which is freely available for redistribution

Submit your manuscript at  
[www.biomedcentral.com/submit](http://www.biomedcentral.com/submit)

