

CASE REPORT



## Streptococcal toxic shock syndrome with primary group A streptococcus peritonitis in a healthy female

Ahsan Wahab  and Bilal Nasir

Internal Medicine Department, McLaren-Flint/Michigan State University, Flint, MI, USA

### ABSTRACT

A 47-year-old female with a history of chronic alcoholism presented with nausea, vomiting and mild epigastric tenderness. She reported subjective fever, abdominal fullness and loose, watery stools and had stable vitals on arrival. Examination was positive for mild epigastric tenderness with hepatic enlargement. Computed tomography of the abdomen showed circumferential thickening of the stomach wall, lower esophagus and the first part of the duodenum in addition to peritoneal ascites. She was admitted for alcohol-related gastritis, acute alcoholic hepatitis, and acute kidney injury. She was started on fluid resuscitation and supportive management. After 8-hours, the patient became hemodynamically unstable with subsequent intubation and fluid resuscitation. She was started on empiric antibiotics. Blood and ascitic fluid cultures were obtained showing group A beta-hemolytic streptococci (GAS). The patient was diagnosed with primary GAS peritonitis along with diffuse gastritis and streptococcal toxic shock syndrome. No cutaneous source of *Streptococcus pyogenes* was identified, and there was no personal or family history of streptococcal pharyngitis. Antibiotics were switched to IV ampicillin and clindamycin. However, the patient continued to deteriorate and succumbed to death within 2-days.

### ARTICLE HISTORY

Received 16 July 2018  
Accepted 11 September 2018

### KEYWORDS

Shock; peritonitis; gastritis;  
*Streptococcus pyogenes*;  
Female; healthy



## 1. Introduction

Group A beta-hemolytic streptococci (GAS) causes various cutaneous (cellulitis, impetigo, erysipelas, necrotizing fasciitis) and non-cutaneous infections (scarlet fever, myositis, myonecrosis, pharyngitis, pneumonia, post-partum endometritis). GAS can invade sterile tissue and lead to GAS bacteremia with or without streptococcal toxic shock syndrome (STSS) [1]. STSS is a critical illness in which GAS is isolated from sterile tissue in the presence of septic shock and multiorgan failure. Centres for Disease Control and Prevention (CDC) defines STSS as a streptococcal illness associated with hypotension and multiorgan failure characterized by at least two of the following 1) renal dysfunction 2) hepatic dysfunction 3) acute respiratory distress syndrome 4) coagulopathy 5) generalized erythematous macular rash and 6) soft tissue necrosis [2]. Though the STSS occurs mainly with GAS soft tissue infections, it has been rarely reported in association with primary GAS peritonitis as well [3]. Primary peritonitis has a diverse bacterial etiology and *Streptococcus pyogenes* is one of the rare pathogens responsible for this disease [3], commonest being *Escherichia coli*, *Klebsiella pneumoniae*, and *Streptococcus pneumoniae* [4]. The diagnosis of primary peritonitis is made in retrospect when secondary causes of peritonitis such as gastrointestinal perforation or anastomotic leakage are excluded. Among reported

cases of primary GAS peritonitis, the portal of entry into the peritoneum has rarely been identified [3]. We report a female of childbearing age who presented with GAS peritonitis and STSS. She was hemodynamically stable on initial presentation and had diffuse circumferential thickening of the stomach and adjacent parts of the esophagus and duodenum in addition to ascites on CT. Esophagogastroduodenoscopy (EGD) showed diffuse ulceration of the stomach, likely an ischemic or infiltrative process. She was admitted because of alcohol-induced gastritis and alcoholic hepatitis. Though she had a subtle presentation in the beginning, she had a fulminant course. Her blood cultures and peritoneal fluid cultures were positive for GAS. She deteriorated and succumbed to death within 48-hours. Her only risk factor was chronic alcoholism that might have caused impaired immunity leading to fulminant infection.

## 2. Case Report

A 47-year-old Caucasian female presented to the emergency department because of a 2-day history of nausea, vomiting and moderate to severe progressive epigastric pain. She reported subjective fever with rigors and chills, loose, watery stools and abdominal fullness. Her past medical history was significant for chronic alcoholism; she drank 6–8 beers each day. She had no reported history of cirrhosis.

**CONTACT** Ahsan Wahab  [aanish00@yahoo.com](mailto:aanish00@yahoo.com)  Internal Medicine Department, McLaren-Flint/Michigan State University, 401 S Ballenger Highway, Flint, MI 48532, USA

© 2018 The Author(s). Published by Informa UK Limited, trading as Taylor & Francis Group on behalf of Greater Baltimore Medical Center. This is an Open Access article distributed under the terms of the Creative Commons Attribution-NonCommercial License (<http://creativecommons.org/licenses/by-nc/4.0/>), which permits unrestricted non-commercial use, distribution, and reproduction in any medium, provided the original work is properly cited.

On arrival, her vitals included blood pressure: 120/88 mmHg, pulse:80/minute, respiratory rate:18/minute, temperature:98.6 °F and oxygen saturation: 97% on ambient air. She appeared in mild distress; sclera was slightly jaundiced. Cardiovascular examination was unremarkable. The abdomen was mildly tender in the epigastric area without guarding and rigidity. Hepatomegaly was also noted. Central nervous system examination was non-focal. Skin showed no erythematous lesions. Laboratory data included haemoglobin 14.2 (12.0–15.7 g/dl), leucocyte count  $9 (4.5\text{--}11 \times 10^3/\text{uL})$ , platelets count 143 ( $4.5\text{--}11.0 \times 10^3/\text{uL}$ ), glucose 83(70–105 mg/dL), blood urea nitrogen 48(7–22 mg/dL), creatinine 2.52(0.50–1.50 mg/dL), sodium 129(134–145 mM/L), potassium 2.9(3.5–5.1 mM/L), chloride 94(98–112 mM/L), bicarbonate 18(24–30 mM/L), anion gap 17(6.0–14.0 mM/L), albumin 2.5(3.5–5.0 g/dL), total bilirubin 6.3(0.2–1.3 mg/dL), AST 71(8–40 U/L), ALP 66 (39–117 U/L), ALT 128 (7–56 U/L), activated PTT 38.1 (23.0–31.0 sec) and PT 12.9 (9.5–12.0 sec) and lactic acid 2.8 (0.5–2.0 mM/L). Contrast-enhanced CT of the abdomen and pelvis showed severe, circumferential thickening of the gastric wall with the involvement of distal esophagus and the first portion of the duodenum in addition to perigastric stranding; findings were reported to be consistent with severe gastritis (Figure 1). There was also mild mucosal thickening of the transverse and descending colon. The liver was enlarged with fatty infiltration. A small amount of ascites with small left-sided pleural effusion was seen throughout the peritoneum. No obstruction, perforation or intrabdominal abscess was seen. Based on her subtle presentation, physical exam and hemodynamic stability, primary peritonitis was deemed less likely upon initial assessment. Therefore, she was admitted to a medical floor with the provisional diagnoses of alcohol-related gastritis,

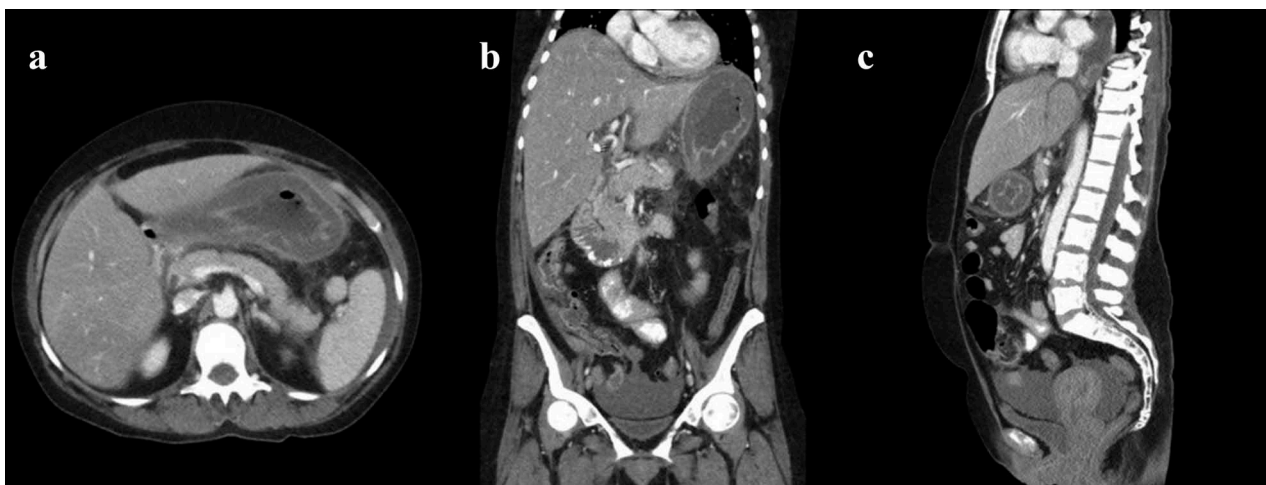
alcoholic hepatitis, and acute kidney injury. She received a 2-litre bolus of intravenous (IV) normal saline and was started on maintenance fluid, IV antiemetics, and IV pantoprazole.

Within 8-hours of admission, the patient became hemodynamically unstable with subsequent intubation and fluid resuscitation. She was transferred to the intensive care unit. Because of bright red blood on nasogastric decompression, she was started on IV octreotide given her history of chronic alcoholism and possible variceal bleed. Because of hypotension and SIRS with peritoneal ascites, blood cultures were drawn, and the patient was started on broad-spectrum empiric antibiotics (vancomycin, piperacillin-tazobactam, and levofloxacin). A diagnostic paracentesis was performed obtaining 1.2 liters of thick serosanguinous peritoneal fluid. Ascitic fluid analysis was suggestive of monomicrobial primary peritonitis, showing abundant Gram-positive cocci and 51,500 leucocytes/mm<sup>3</sup> with 67% neutrophils. Ascitic fluid was exudative in nature with total protein 3.8 g/dl, albumin 1.6 g/dl, lactate dehydrogenase 5189/UL and glucose 56 mg/dl. Serum-albumin ascitic-albumin gradient was 0.9 g/dl.

No surgical intervention was considered as the possibility of secondary peritonitis was less likely based on her CT and ascitic fluid findings. Blood cultures and ascitic fluid cultures were positive for GAS, and therefore, the patient was started on IV ampicillin and clindamycin for primary GAS peritonitis.

Because of hematemesis, the patient underwent EGD that showed diffuse gastric ulcerations, but no esophageal varices or active bleeding. Given diffuse ulceration of stomach with circumferential wall thickening, gastritis was thought to be caused by an underlying ischemic or infiltrative process.

Although the patient's hemoglobin was stable, and she had required no blood transfusions, her



**Figure 1.** CT scan of the abdomen and pelvis showing circumferential diffuse thickening of the stomach, distal part of the esophagus and first part of the duodenum with intraperitoneal free fluid and fat stranding (a) axial view. (b) coronal view. (c) sagittal view.

hemodynamic status started to deteriorate requiring multiple pressor support and IV high-dose hydrocortisone. Given the context of isolation of GAS from blood and ascitic fluid, septic shock and multiorgan failure (renal failure and liver failure), a diagnosis of STSS was made. Her lactic acid level worsened from 2.8 at baseline to 42 mM/L. The patient was deemed a non-surgical candidate by the surgical team. However, an ultrasound-guided intraperitoneal drain was placed for therapeutic reasons. The patient received few doses of antibiotics; however, she continued to deteriorate and succumbed to death within 48-hours of admission due to cardiopulmonary arrest and multiorgan failure.

### 3. Discussion

GAS peritonitis data is limited and involves sporadic case reports, case series and review articles [3,5–8]. According to a literature review of Malota *et al.*, there is a female preponderance among 35 cases of GAS peritonitis, with a female to male ratio of 4: 1 and the median age of 38 [3]. Contrary to this, Iwata *et al.* collected data on female patients only and summarized 75 patients; fifty-five of them (73%) were below 50 [6]. This much higher incidence in women of childbearing age was attributed to the ascent of GAS from genital tract; this standpoint is based on the isolation of GAS from female organs, especially vagina [6]. Though most of the females were asymptomatic genital carriers of GAS, cases are outlined with concomitant vaginitis, cervicitis, endometritis/parametritis, salpingitis, oophoritis, ovarian abscess and pelvic abscess [5,6,9]. Apart from genital isolation, GAS has been isolated from the oropharynx of children and family members of the affected patients. In some instances, recent personal or family history of GAS pharyngitis has been reported [3]. Therefore, GAS pharyngitis has been implicated as a possible portal of entry in these cases. Besides these routes, Jonathan *et al.* proposed an orogenital route based on their case of GAS peritonitis in a female patient; an intrauterine device (IUD) was thought to be the portal of entry in her case [9]. The patient's husband was an asymptomatic carrier of GAS in his oropharynx, and the couple was involved in oral sex. Similar GAS serotypes were isolated from IUD, the patient, and the oropharynx of her husband; circumstantially, that was the only possible route in this case [9].

Primary GAS peritonitis exhibits nonspecific symptoms and mimics infectious enterocolitis. Most patients present with nausea, vomiting, diarrhea, fever, flu-like symptoms and abdominal pain [3]. Signs of peritonitis are variable, and therefore, not always present [9]. Involvement of intraperitoneal organs, on the other hand, can cause localized features and imitate secondary peritonitis. Other less common features include a maculopapular rash with

desquamation, myositis, rhabdomyolysis, cutaneous necrotizing fasciitis and peritoneal necrotizing fasciitis [3,9,10]. STSS, a systemic failure caused by streptococcal exotoxins and inflammatory cytokines, has been reported to occur in only 37% of cases with primary GAS peritonitis [3].

Although the initial presentation in these cases is very subtle at times, STSS depicts a fulminant course, and patients deteriorate within hours.

Our case is unique as the patient presented with severe gastritis, primary GAS and STSS and died within 48 hours. In view of diffuse gastritis with the involvement of the esophagus and duodenum, we reviewed the literature; GAS can cause phlegmonous inflammation of stomach as well [11]. However, cases with concomitant phlegmonous gastritis and primary GAS peritonitis rarely occur. The literature search reveals a case in which phlegmonous inflammation of uterus occurred in the presence of primary GAS peritonitis [5]. This example means that extensive peritonitis could involve intraperitoneal organs and lead to phlegmonous inflammation of organs because of GAS infiltration. In our case, GAS was not isolated from biopsy specimens. However, conventional mucosal biopsies are often non-diagnostic due to the invasive nature of the disease with the involvement of submucosa and muscular layers more often [11]. Though we are not certain if extensive gastritis in our case is a spectrum of phlegmonous gastritis, this could be one possibility; this is in view of our patient's aggregate clinical picture, the presence of primary GAS peritonitis, CT and EGD findings.

The diagnosis of primary GAS peritonitis needs a high clinical suspicion and requires consideration in females of childbearing age. Such cases need a thorough history and physical examination including a pelvic exam. The purpose of the workup is to 1) exclude secondary causes of peritonitis 2) to obtain microbiological evidence of GAS and 3) to detect sepsis and multiorgan failure. Streptococcal throat swabs and vaginal cultures for GAS should be obtained. IUD devices should be removed and sent for examination [9]. Blood tests include complete blood counts, comprehensive metabolic panel, coagulation tests, lactic acid and creatine kinase. Blood cultures are positive in more than 80% of cases and should be obtained [3]. Ascitic fluid should be sent for gram stain, culture and sensitivity. Rapid antigen detection test might be helpful.

The role of CT of the abdomen and pelvis involves detection of GAS peritonitis, to rule out secondary causes of peritonitis and to reveal peritoneal fluid or ascites. CT findings are miscellaneous on the extent of peritonitis and involvement of visceral organs. These include intraperitoneal/retroperitoneal/perivisceral fluid collections, peritoneal fat thickening, infiltration and edema of soft tissues, thickening of

intestines/colon/psoas muscle, distension and edema of the small intestines [3,7,9,10,12,13].

Contrary to the fact that primary GAS peritonitis is a medical diagnosis, most patients require surgical exploration because of hemodynamic instability. Though these procedures (laparoscopy or laparotomy) seem to be invasive, many benefits derived from previous literature include 1) to rule out secondary causes of peritonitis 2) to confirm anatomic extent of the disease and visceral involvement such as necrotizing fasciitis of peritoneum and involvement of intestines, colon, ovaries, fallopian tubes, and uterus 3) isolation of GAS from intraperitoneal fluid or tissue 4) placement of peritoneal drains or peritoneal wash-outs for therapeutic reasons 5) hastened clinical recovery after removal of GAS-infected tissue such as debridement of necrotizing fasciitis 6) resection of dead and necrotic organs such as hysterectomy, salpingectomy, oophorectomy, etc. and 7) improved mortality outcomes in patients with surgery [3,7,10,13]. Though surgery could be avoided in a few cases with a good clinical outcome, mortality in females of childbearing age is 4.8% versus 15.8% with surgery and without surgery, respectively [3].

The mainstay of treatment of GAS peritonitis is IV antibiotics at least for two-weeks. Treatment of GAS peritonitis involves empiric IV antibiotics containing clindamycin and beta-lactam antibiotics such as piperacillin-tazobactam, benzylpenicillin, amoxicillin-clavulanic acid. The patients treated with these antibiotics had an excellent clinical response. Though clindamycin has a role against the virulence factors of GAS, i.e., M proteins and exotoxins, it should not be used alone due to the possibility of resistant strains. Therefore, the role of clindamycin is essential in STSS as it also targets the pathogenesis responsible for STSS. Hospitalization varies, extending up to more than three months occasionally [7]. In the literature, some cases were treated with antibiotics alone and had a good clinical response [7]. However, the patients who do not respond to antibiotics and deteriorate should be considered for surgery. As the disease is fulminant, the decision for surgery should be made early. Early surgery might be beneficial in patients with no antibiotic response. Our patient declined from stable hemodynamics to unstable, and then, shock, with no surgical intervention and subsequent death within 48 hours.

#### 4. Conclusion

Primary GAS peritonitis should be suspected in females of childbearing age with or without septic shock. Diagnosis of this condition requires high clinical suspicion. Patients may have a subtle presentation initially but will deteriorate within hours if not appropriately treated. Antibiotics are the mainstay of treatment, but

surgery could be lifesaving when there is no response to antibiotics. The decision for surgery should be made early in the absence of clinical response.

#### Disclosure statement

No potential conflict of interest was reported by the authors.

#### ORCID

Ahsan Wahab  <http://orcid.org/0000-0003-3597-1838>

#### References

- [1] Stevens DL. Streptococcal toxic-shock syndrome: spectrum of disease, pathogenesis, and new concepts in treatment. *Emerg Infect Dis.* 1995 Jul;1(3):69–78.
- [2] Streptococcal Toxic Shock Syndrome (STSS) (Streptococcus pyogenes) 2010 Case Definition [Internet]. Centers for disease control and prevention. Centers for Disease Control and Prevention; [cited 2018 Jul 14]. Available from: <https://www.cdc.gov/ndss/conditions/streptococcal-toxic-shock-syndrome/case-definition/2010/>
- [3] Malota M, Felbinger TW, Ruppert R, et al. Group A Streptococci: a rare and often misdiagnosed cause of spontaneous bacterial peritonitis in adults. *Int J Surg Case Rep.* 2015 Jan 1;6:251–255.
- [4] Laroche M, Harding G. Primary and secondary peritonitis: an update. *Eur J Clin Microbiol Infect Dis.* 1998 Aug 1;17(8):542–550.
- [5] Fox KL, Born MW, Cohen MA. Fulminant infection and toxic shock syndrome caused by Streptococcus pyogenes. *J Emerg Med.* 2002 May 1;22(4):357–366.
- [6] Monneuse O, Tissot E, Gruner L, et al. Diagnosis and treatment of spontaneous group A streptococcal peritonitis. *Br J Surg.* 2010 Jan;97(1):104–108.
- [7] Iwata Y, Iwase S. Group A streptococcal peritonitis and toxic shock syndrome in a postmenopausal woman. *Intern Med.* 2017 Sep 15;56(18):2523–2527.
- [8] Gisser JM, Fields MC, Pick N, et al. Invasive group A streptococcus associated with an intrauterine device and oral sex. *Sex Transm Dis.* 2002 Aug 1;29(8):483–485.
- [9] Kanetake K, Hayashi M, Hino A, et al. Primary peritonitis associated with streptococcal toxic shock-like syndrome: report of a case. *Surg Today.* 2004 Dec 1;34(12):1053–1056.
- [10] Kim GY, Ward J, Hennessey B, et al. Phlegmonous gastritis: case report and review. *Gastrointest Endosc.* 2005 Jan 1;61(1):168–174.
- [11] Iitaka D, Ochi F, Nakashima S, et al. Treatment with antibodies against primary group A streptococcal peritonitis: a case report and a review of the literature. *Medicine.* 2017 Dec 1;96(52):e9498.
- [12] Tilanus AM, de Geus HR, Rijnders BJ, et al. Severe group A streptococcal toxic shock syndrome presenting as primary peritonitis: A case report and brief review of the literature. *Int J Infect Dis.* 2010 Sep;14(14):e208–e212.
- [13] Abellán IM, González A, Selva PC, et al. Primary peritonitis by Streptococcus pyogenes. A condition as rare as it is aggressive. *Revista española de enfermedades digestivas.* 2016 Apr;108(4):231–232.