



Case report

Retinal detachment repair with perfluoro-N-octane endotamponade in an infant with juvenile X-linked retinoschisis

Homer Chiang^a, Emmanuel Chang^b, C. Armitage Harper III^{c,*}^a UT Health San Antonio, Department of Ophthalmology, 7703 Floyd Curl Dr. MSC 6230, San Antonio, TX, 78229, USA^b Retina and Vitreous of Texas, Houston, 2727, Gramercy Suite 200, Houston, TX, 77025, USA^c Austin Retina Associates, 801 W, 38th Street, Suite 200, Austin, TX, 78705, USA

ARTICLE INFO

Keywords:

X-linked retinoschisis
Retinal detachment
Vitreotomy
Perfluoro-N-Octane

ABSTRACT

Purpose: We present a case of successful surgical management of an infant with X-linked retinoschisis with a giant retinal tear and retinal detachment of the right eye.**Observations:** A 10-month-old male presented with retinoschisis of both eyes and a retinal detachment of the right eye. The patient underwent two-stage pars plana vitrectomy utilizing perfluoro-N-octane to stabilize the detached retina and facilitate posterior hyaloid separation. Retained perfluoro-N-octane tamponade was later exchanged with silicone oil. The retina remained attached at last follow up.**Conclusions and Importance:** Retinal detachment repair in infants presents unique challenges. This is a safe and effective strategy for complex retinal detachment repair in the infant population.

1. Introduction

Juvenile X-linked retinoschisis (XLRS) is a common inherited macular degeneration in young males with an estimated global prevalence of 1:5000 to 1:20000,¹ associated with a mutation in the RS1 gene on chromosome Xp22. While diagnosis is most often made at school age, cases presenting within the first year of life have been reported,^{2,3} which is postulated to represent a more progressive form of disease.³ Concomitant retinal detachments are estimated to occur in 20%.¹

2. Case report

A 10-month-old male was referred to a retina specialist for retinoschisis of the right eye. The patient's mother tested positive for the RS1 mutation in a prenatal genetic screen. The patient also tested positive for the RS1 mutation, and negative for inherited retinal diseases including familial exudative vitreoretinopathy, congenital stationary night blindness, Leber's congenital amaurosis, and early-onset retinal dystrophy. The patient was heterozygous for MYO7A and USH2A but demonstrated no clinical evidence of retinitis pigmentosa, usher syndrome, or hearing loss. Exam showed a normal anterior segment in both eyes. Fundus exam of the right eye showed a large schisis cavity

combined with a chronic retinal detachment inferiorly (Fig. 1A). Fundus exam of the left eye showed retinoschisis without retinal detachment. Further examination under anesthesia (EUA) showed a large schisis cavity inferiorly with a giant outer retinal tear with a pigmented demarcation line, extending from the central macula to the nasal periphery. The left eye showed schisis in the inferior periphery (Fig. 1B). Fluorescein angiogram (Fig. 2A and B) demonstrated shadowing in the periphery consistent with a schisis cavity. After discussion with the child's parents, they elected to proceed with surgical retinal detachment repair of the right eye.

A primary pars plana lensectomy and pars plana vitrectomy (PPV) were performed. The vitreous was stained with preservative-free triamcinolone to aid in visualization of the vitreous body and posterior hyaloid face. During vitreous detachment, the posterior hyaloid face was tightly adherent to the billowing retina. Perfluoro-N-Octane (PFO) was injected over the optic nerve to unfold and flatten the retina. The PFO bubble was then used as a "third hand" to tamponade the billowing retina and facilitate complete separation of the posterior hyaloid. 360° of peripheral laser retinopexy was performed. No inner retinal breaks were found.

The PFO was retained in the eye postoperatively as a vitreous replacement tamponade. 10 days after the initial surgery, a second stage

Abbreviations: XLRS, X-linked retinoschisis; EUA, Exam under anesthesia; PPV, pars plana vitrectomy; PFO, Perfluoro-N-octane; PVR, proliferative vitreoretinopathy.

* Corresponding author.

E-mail addresses: Homerhchiang@gmail.com (H. Chiang), Emanmdphd@gmail.com (E. Chang), armieharper3@gmail.com (C.A. Harper).

<https://doi.org/10.1016/j.ajoc.2020.100975>

Received 27 August 2020; Received in revised form 7 October 2020; Accepted 18 October 2020

Available online 24 October 2020

2451-9936/© 2020 Published by Elsevier Inc. This is an open access article under the CC BY-NC-ND license (<http://creativecommons.org/licenses/by-nc-nd/4.0/>).

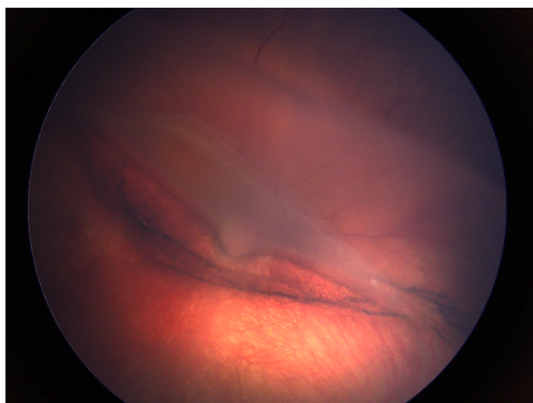


Fig. 1A. Color fundus photo of the right eye showing retinoschisis folded over the optic nerve with giant tear and pigmented demarcation line. (For interpretation of the references to colour in this figure legend, the reader is referred to the Web version of this article.)

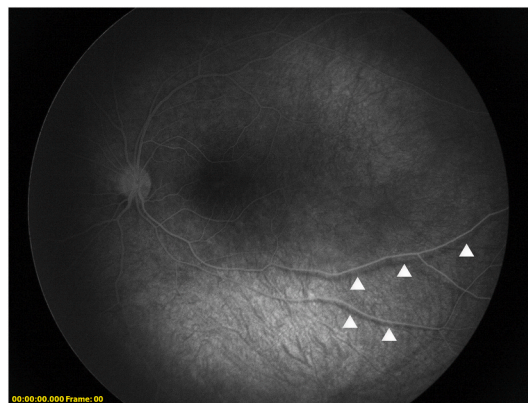


Fig. 2B. Fluorescein angiography of the left eye demonstrates shadowing (arrowheads) indicating retinoschisis.

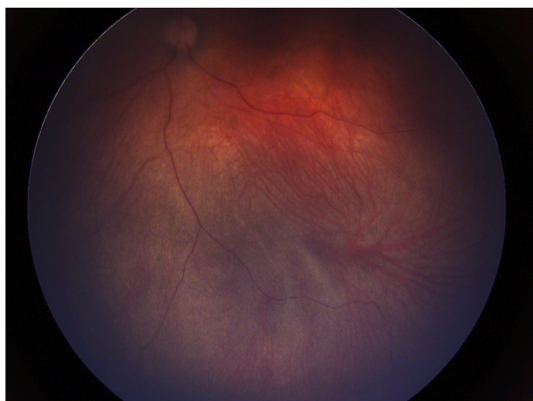

Fig. 1B. Color fundus photo of the left eye with shallow schisis inferiorly.

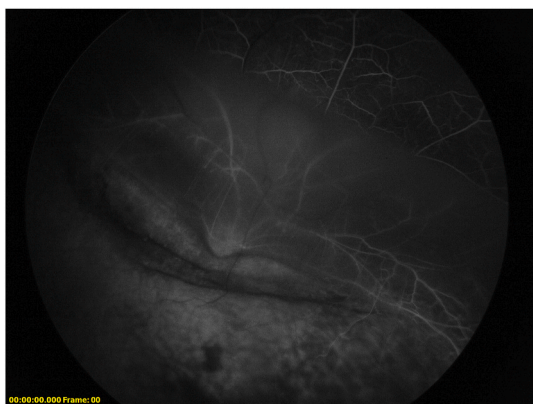

Fig. 2A. Fluorescein angiography of the right eye.

pars plana vitrectomy was performed. The PFO was exchanged for silicone oil and additional laser retinopexy was added. No emulsified PFO was noted in the eye at the time of removal. The retina remained attached with good silicone oil fill at post-operative week 2 (Fig. 3) and remained attached at his latest post-operative week 18 visit. Silicone oil removal is planned for next post-operative month 5.

3. Discussion

Compared with adults, retinal detachments in children are often more complex and difficult to treat satisfactorily. This is thought to be due to delay in diagnosis and differences in etiology including trauma and congenital or developmental abnormalities. Estimates of anatomical success ranges from 10 to 88% depending on etiology and surgical approach, with most failures caused by proliferative vitreoretinopathy (PVR).⁴

In a large case series, of 178 eyes in the pediatric population that underwent retinal detachment repair, 9 (4.3%) were secondary to XLRS.⁴ These eyes were repaired by PPV/oil or gas, or scleral buckle/PPV/oil or gas. Although 100% final attachment rate was reported, 5 eyes (56%) had re-detachment and 7 eyes (78%) required more than 1 surgery. All 9 eyes XLRS in the series had PVR.

Intraoperatively, PFO can be used to stabilize the retina and facilitate posterior vitreous separation in pediatric eyes with tightly adherent vitreous. Owing to its higher specific gravity, PFO tamponade may also be an effective choice for infant patients (who cannot reliably maintain positioning) or for inferior detachments compared to substances with lower relative specific gravity such as gas or silicone oil.

Case reports have demonstrated good efficacy safety profile when used in short or intermediate duration.^{5,6} Ling and colleagues demonstrated lasting attachment (more than 2 years follow-up) in 1 eye with PFO tamponade followed by silicone oil exchange after 1 week.⁵ The eye had previously undergone 3 vitrectomies and scleral buckling but suffered repeated re-detachments secondary to PVR. In a case series of 9 eyes, Imaizumi and colleagues showed anatomic reattachment in 7 eyes (78%) after temporary PFO tamponade.⁶ Prior to utilization of PFO, 7 eyes (78%) had undergone at least 1 vitrectomy surgery. To our knowledge, only 1 case has described this technique for retinal detachment in a patient with XLRS. Sisk and colleagues described extended (25 days) PFO tamponade in an infant with XLRS and recurrent traction retinal detachments from PVR⁷ after multiple vitrectomies with silicone oil exchange. Emulsified PFO was noted in the anterior chamber at the time of removal but without significant inflammation, and the retina remained attached 11 month follow up.

The safety profile of retained PFO is not well understood. In rabbit studies, eyes injected with PFO showed histological thinning of the outer plexiform layer after 1 week and distortions in the photoreceptor outer segments after 2 weeks.⁸ Given that these changes occurred in the inferior retina, and similar histological changes occurred in the superior retina of rabbit eyes injected with silicone oil, it was postulated that these effects may be mechanical rather than toxic. In their series, Imaizumi and colleagues noted no adverse effects in eyes receiving PFO tamponade for periods between 1 and 5 weeks.⁶ The appropriate duration for retained PFO, therefore, seems to be 1–2 weeks. In our patient,

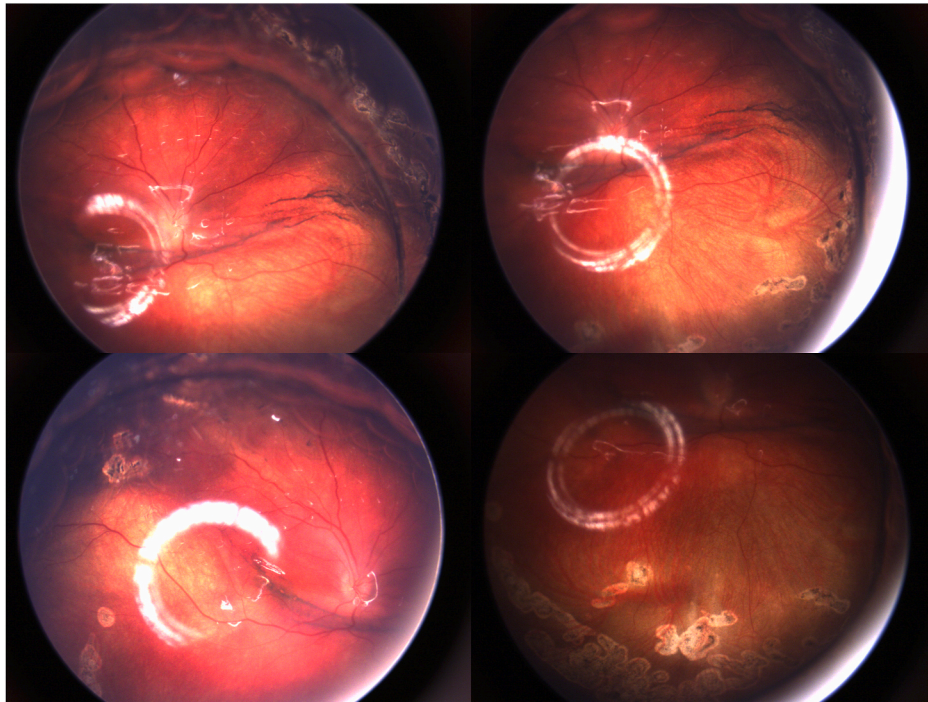


Fig. 3. Postoperatively, after silicone oil exchange, the retina remained attached in all quadrants. There is 95% silicone oil fill with reflection of the oil bubble at the attached retinal surface.

the decision to remove the PFO at 10 days was based on this safety window and surgical scheduling with the family.

4. Conclusion

XLRS can be associated with retinal detachment. Vitrectomy for retinal detachment repair can be challenging in infants with a tightly adherent posterior hyaloid face. Temporary, short-term retained PFO tamponade may be a safe and effective option in infants who cannot reliably maintain positioning.

5. Patient consent

Consent to publish the case report was not obtained. This report does not contain any personal information that could lead to the identification of the patient.

Acknowledgements and Disclosures

The authors acknowledge Jessica Goldstein for her assistance. The authors report no financial disclosures. No funding was received for the preparation of this report.

Appendix A. Supplementary data

Supplementary data to this article can be found online at <https://doi.org/10.1016/j.ajoc.2020.100975>.

[org/10.1016/j.ajoc.2020.100975](https://doi.org/10.1016/j.ajoc.2020.100975).

Authorship

All authors attest that they meet the current ICMJE criteria for Authorship.

References

- George ND, Yates JR, Moore AT. X linked retinoschisis. *Br J Ophthalmol.* 1995;79(7): 697–702.
- Lee JJ, Kim JH, Kim SY, Park SS, Yu YS. Infantile vitreous hemorrhage as the initial presentation of X-linked juvenile retinoschisis. *Kor J Ophthalmol.* 2009;23(2): 118–120.
- Murro V, Caputo R, Bacci GM, et al. Case report of an atypical early onset X-linked retinoschisis in monozygotic twins. *BMC Ophthalmol.* 2017;17(1):19.
- Read SP, Aziz HA, Kuriyan A, et al. Retinal detachment surgery in a pediatric population: visual and Anatomic Outcomes. *Retina.* 2018;38(7):1393–1402.
- Ling KP, Wu AL, Lai CC, Wu WC. Short-term postoperative perfluoro-n-octane tamponade for pediatric recurrent retinal detachment. *Taiwan J Ophthalmol.* 2018;8 (4):249–252.
- Imaizumi A, Kusaka S, Noguchi H, Shimomura Y, Sawaguchi S. Efficacy of short-term postoperative perfluoro-n-octane tamponade for pediatric complex retinal detachment. *Am J Ophthalmol.* 2014;157(2):384–389. e2.
- Sisk RA, Berrocal AM, Murray TG, Mavrofrides EC. Extended endotamponade with perfluoro-n-octane in pediatric retinal detachment. *Ophthalmic Surg Laser Imag.* 2010: 1–3.
- Chang S, Sparrow JR, Iwamoto T, Gershbein A, Ross R, Ortiz R. Experimental studies of tolerance to intravitreal perfluoro-n-octane liquid. *Retina.* 1991;11(4):367–374.