

Ectopic third molar in the maxillary sinus

K. D. Dental College and Hospital,
NH 2 Chatikara, Mathura,
Uttar Pradesh, India

Shishir Mohan, Hasti Kankariya, Bhupendra Harjani, Harendra Sharma

Address for correspondence:
Dr. Shishir Mohan,
K. D. Dental College and Hospital,
NH 2 Chatikara, Mathura –
281 006, Uttar Pradesh, India.
E-mail: drshishirdent@yahoo.
co.in

ABSTRACT

Ectopic eruption of teeth into a region other than the oral cavity is rare although there have been reports of teeth in the nasal septum, mandibular condyle, coronoid process, palate, chin and maxillary sinus. Occasionally, a tooth may erupt in the maxillary sinus and present with local sinonasal symptoms attributed to chronic sinusitis. We present a case of an ectopic maxillary third molar tooth that caused chronic purulent sinusitis in relation to the right maxillary sinus.

Key words: Ectopic eruption, maxillary antrum, third molar

INTRODUCTION

Tooth development results from a complicated multi-step interaction between the oral epithelium and the underlying mesenchymal tissue. A series of complex tissue interactions result in the formation of mature teeth. Abnormal tissue interactions during tooth development may potentially result in ectopic tooth development and eruption.^[1]

Ectopic eruption of a tooth into the dental environment is common, whereas ectopic eruption of a tooth in other sites is rare.^[2] One such site for ectopic tooth eruption in a nondental location is the maxillary sinus.^[3] Due to its rarity, there is a dearth of literature discussing this entity.^[4] Ectopic eruption may result due to one of the three processes: developmental disturbance, pathological process and iatrogenic activity.^[4] Tooth eruption into the maxillary sinus may cause sinusitis,^[4] the treatment of which (if infected) is surgical removal.^[1] We present a case of an ectopic maxillary third molar, which presented in the right maxillary sinus with purulent rhinorrhea and was removed via a Caldwell-Luc procedure.

CASE REPORT

A 28-year-old female reported with a complaint of recurrent purulent rhinorrhea on the right side with associated pain and swelling of 6 months duration [Figure 1]. The problem did not resolve in spite of taking several courses of antibiotics prescribed by medical practitioners. On examination, swelling was noted extending from ala of nose to zygomatic prominence, obliterating nasolabial fold of the right side. Swelling was tender. Intraoral examination revealed swelling from right lateral incisor to second molar region, obliterating the vestibule. No carious tooth was noted in the involved quadrant. All teeth were found vital as confirmed by vitality test in the right upper quadrant. Right upper third molar was missing and there was no history of any previous extraction. Swelling was tender and fluctuant. Aspiration revealed seropurulent fluid. Orthopantomogram (OPG) [Figure 2] confirmed the presence of an ectopic molar tooth in the superomedial aspect of the right maxillary antrum.

The patient subsequently underwent removal of the ectopic tooth under sedation and local anesthesia via a Caldwell-Luc procedure. A vestibular incision was made from lateral incisor up to the first molar tooth. A bony window was created [Figure 3] and a cystic lining was noticed. Enucleation of the cyst was done; the lining was attached with medial wall of maxillary sinus which was thinned out and came out along with the lining [Figure 4]. Hemostasis was achieved by placing a pack,

| Access this article online | |
|--|--|
| Quick Response Code:  | Website: www.njms.in |
| | DOI: 10.4103/0975-5950.94488 |

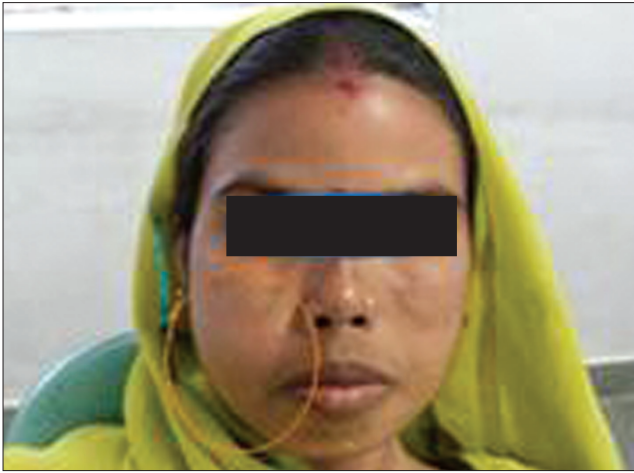

Figure 1: Swelling on right side of the face

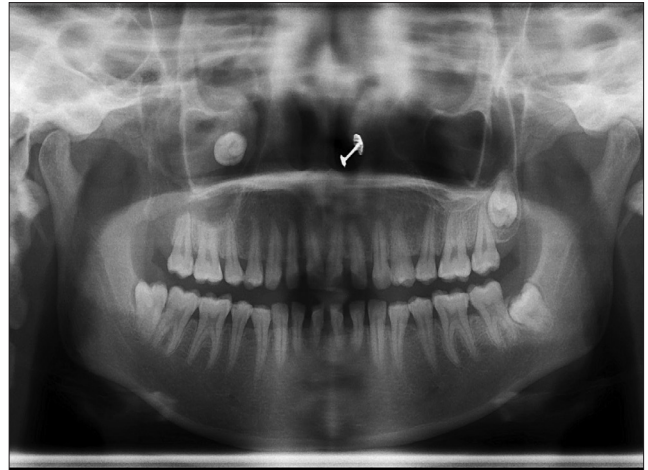


Figure 2: OPG shows tooth in sinus

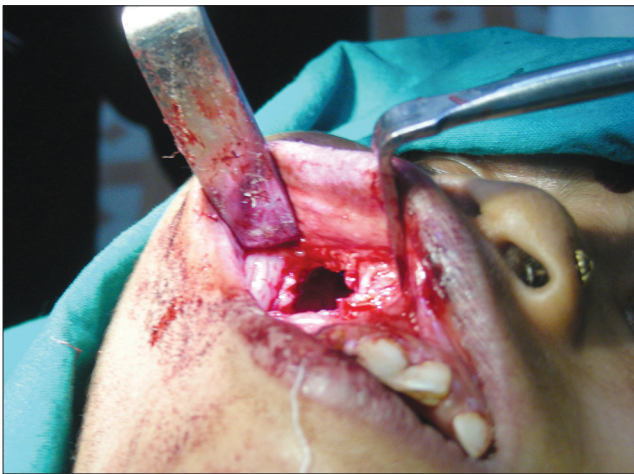


Figure 3: Bony window made in anterior wall of sinus

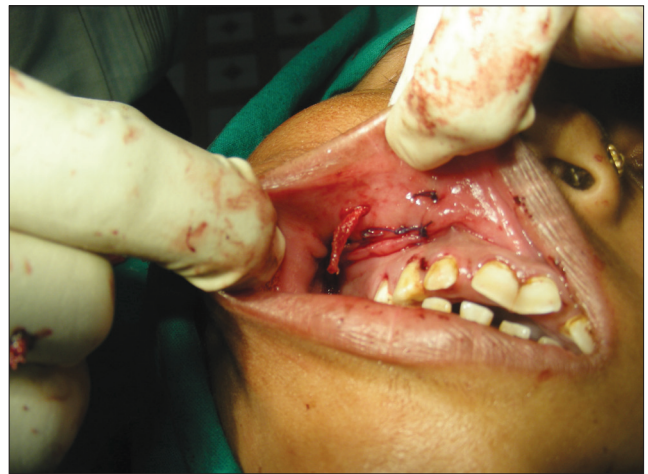

Figure 4: Incision closed pack removed through separate stab incision

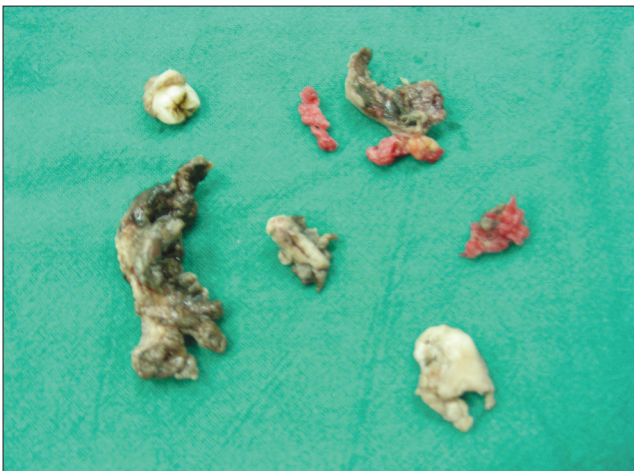

Figure 5: Pathological specimen with removed tooth

and the wound closed with 3.0 silk suture [Figure 5]. The pack was removed on 3rd postoperative day and primary closure was done. On the 10th day, swelling completely subsided. Histopathology of the soft tissue revealed a dentigerous cyst with no evidence of

malignancy. There was no discharge from the nose. The patient has been asymptomatic over a year's follow-up.

DISCUSSION

Tooth development results from an interaction between the oral epithelium and the underlying mesenchymal tissue. This process begins in the 6th week *in utero* with the formation of maxillary and mandibular dental lamina in the region of the future alveolar process. This ectodermal derivative undergoes proliferation to form the permanent dentition between the 5th and 10th months, with each mature tooth consisting of a crown and a root.^[5] Abnormal tissue interactions during development may potentially result in ectopic tooth development and eruption. Ectopic eruption of a tooth into a region other than the oral cavity is rare although there have been reports of tooth in the nasal septum,^[6] mandibular condyle,^[7] coronoid process^[8] and the palate.^[9] Occasionally, the tooth may erupt into the maxillary antrum and present with local

sinonasal symptoms attributed to recurrent or chronic sinusitis. The diagnosis of this condition can be made radiographically with plain sinus X-rays and computed tomography (CT) scans taken in axial and coronal sections.

Dentigerous cyst is the most common of all follicular cysts, more common in males, occurring in the second or third decade of life. About 70% of dentigerous cysts occur in the mandible and 30% in the maxilla.^[10] If infected, the treatment of choice is complete enucleation of the lesion intraorally with removal of the associated tooth. It is also important to completely remove all diseased antral tissues and thoroughly assess all resected soft tissue histologically.^[11] Only a few cases of "ectopic" molars which have been displaced by progressively growing dentigerous cysts have been reported in medical literature.^[12] It is believed that the displacement of tooth buds by the expansion of these dental cysts results in the displacement of the tooth to other areas, which is attributed to the ectopic appearance of the third molar in this patient. Recurrence and malignant or ameloblastic transformation following a dentigerous cyst is rare when compared to odontogenic keratocyst.^[13,14] Close observation and follow-up with periodic radiographs is required.

The treatment of an ectopic tooth in the maxillary sinus is usually removal because if left untreated, it has the tendency to form a cyst or tumor and/or the lesion may cause perforation of the orbital floor and obliteration of the nasal cavity. Caldwell-Luc procedure was followed in this case as the ectopic tooth was the cause of recurrent sinusitis and purulent rhinorrhea in spite of administering antibiotics repeatedly. The importance

of ruling out related dental conditions in any patient presenting with such signs and symptoms of the head and neck region cannot be overemphasized.

REFERENCES

1. Goh YH. Ectopic eruption of maxillary molar tooth: An unusual cause of recurrent sinusitis. *Singapore Med J* 2001;42:80-1.
2. Elango S, Palaniappan SP. Ectopic tooth in the roof of the maxillary sinus. *Ear Nose Throat J* 1991;70:365-6.
3. Goh YH. Ectopic eruption of maxillary molar tooth: An unusual cause of recurrent sinusitis. *Singapore Med J* 2001;42:80-1.
4. Bodner L, Tovi F, Bar-Ziv J. Teeth in the maxillary sinus: Imaging and management. *J Laryngol Otol* 1997;111:820-4.
5. Avery JK. *Oral Development and histology*. 2nd ed. New York: Theime Medical Publisher Inc; 1994. p. 70-92.
6. el-Sayed Y. Sinonasal teeth. *J Otolaryngol* 1995;24:180-3.
7. Yusuf H, Quayle AA. Intracondylar tooth. *Int J Oral Maxillofac Surg* 1989;18:323.
8. Toranzo Fernandez M, Terrones Meraz MA. Infected cyst in the coronoid process. *Oral Surg Oral Med Oral Pathol* 1992;73:768.
9. Pracy JP, Williams HO, Montgomery PQ. Nasal teeth. *J Laryngol Otol* 1992;106:366-7.
10. Bhaskar SN. *Synopsis of oral pathology*. 7th ed. United States: CBS Publisher; 1986. p. 228-37.
11. Laskin DM. *Oral surgery*. 1st ed. Missouri: Cr. Mosby; 1996. p. 459.
12. Szerlip L. Displaced third molar with dentigerous cyst: An unusual case. *J Oral Surg* 1978;36:551-2.
13. Kramer IR. Ameloblastoma: Clinicopathological appraisal. *Br J Oral Surg* 1963;1:13-28.
14. Toller PA. Origin and growth of cyst of the jaws. *Ann R Coll Surg Engl* 1967;40:306-36.

How to cite this article: Mohan S, Kankariya H, Harjani B, Sharma H. Ectopic third molar in the maxillary sinus. *Natl J Maxillofac Surg* 2011;2:222-4.

Source of Support: Nil. **Conflict of Interest:** None declared.