

Myelomatous pleural effusion in a cat diagnosed with multiple myeloma

Tancrède Amalbert¹ , Aude Morgane Canonne² 
 and Jérémy Béguin² 

Journal of Feline Medicine and Surgery Open Reports
 1–6

© The Author(s) 2023

Article reuse guidelines:

sagepub.com/journals-permissions

DOI: 10.1177/20551169221134094

journals.sagepub.com/home/jfmsopenreports

This paper was handled and processed by the European Editorial Office (ISFM) for publication in *JFMS Open Reports*



Abstract

Case summary A 10-year-old male castrated domestic shorthair cat was presented with a 3-day history of dyspnoea, chronic lethargy and inappetence. A bilateral pleural effusion was identified by thoracic ultrasound, and cytological examination revealed numerous atypical plasma cells. Biochemistry and serum protein electrophoresis revealed a severe hyperglobulinaemia associated with a monoclonal gammopathy. A moderate non-regenerative anaemia was also noted. Multiple bone lytic lesions were detected, and marked plasmacytosis was observed on bone marrow aspirates. Chemotherapy with cyclophosphamide and prednisolone was initiated but did not result in any clinical or biological response, and pleural effusion recurred. Lack of therapeutic response led to euthanasia 2 months after diagnosis.

Relevance and novel information This is the first description of a myelomatous pleural effusion in a cat diagnosed with multiple myeloma and should be considered as one of the possible differential diagnoses for cats presented with pleural effusion and hyperglobulinaemia. The diagnostic, therapeutic and prognostic aspects of this manifestation are discussed.

Keywords: Malignant pleural effusion; hyperglobulinaemia; malignant plasma cells; myeloma-related disorders; monoclonal gammopathy

Accepted: 3 October 2022

Introduction

Myeloma-related disorders (MRDs) in cats are a group of several neoplasias involving malignant plasma cells or malignant immunoglobulin-secreting B lymphocytes. Feline MRDs include multiple myeloma (MM), cutaneous extramedullary plasmacytoma, non-cutaneous extramedullary plasmacytoma, solitary plasmacytoma of bone, IgM macroglobulinaemia, immunoglobulin-secreting lymphoma, immunoglobulin-secreting leukaemia and plasma cell leukemia.¹ In cats, extramedullary involvement, especially of the liver and the spleen, is common in MRD.² However, until now, the presence of a myelomatous pleural effusion (MPE) has not yet been described in dogs and cats diagnosed with MM and MRD.

Case description

A 10-year-old castrated male domestic shorthair cat was presented with a 3-day history of anorexia and worsening dyspnoea and a 6-month history of inappetence, weight loss and lethargy. Vaccinations and deworming

were not up to date. Two months prior to first presentation, a severe hyperglobulinaemia (>100 g/l; reference interval [RI] 26–51) and hypoalbuminaemia (17 g/l; RI 22–41) were identified. Corticosteroid therapy was initiated (prednisolone 0.6 mg/kg q24h for 15 days), leading to partial clinical improvement. One month later, severe hyperglobulinaemia persisted (>100 g/l; RI 26–51) and a moderate normocytic normochromic anaemia was identified (red blood cells [RBCs] $4.10 \times 10^{12}/l$ [RI 5–10];

¹National Veterinary School of Alfort, Paris-Est University, Maisons-Alfort, France

²Department of Internal Medicine, National Veterinary School of Alfort, Paris-Est University, Maisons-Alfort, France

Corresponding author:

Aude Morgane Canonne DVM, DipECVIM-CA, Department of Internal Medicine, National Veterinary School of Alfort, 7 Av. du Général de Gaulle, Maisons-Alfort 94700, France
 Email: morgane.canonne@vet-alfort.fr



Creative Commons Non Commercial CC BY-NC: This article is distributed under the terms of the Creative Commons

Attribution-NonCommercial 4.0 License (<https://creativecommons.org/licenses/by-nc/4.0/>) which permits non-commercial use, reproduction and distribution of the work without further permission provided the original work is attributed as specified on the SAGE and Open Access pages (<https://us.sagepub.com/en-us/nam/open-access-at-sage>).

haematocrit 20.1% [RI 27–47%]; haemoglobin 6.7 g/dl [RI 8–17]).

On physical examination, a poor body condition (weight 3.4 kg; body condition score 2/9), 5% dehydration and tachypnoea (60 beats/min) with increased inspiratory efforts were observed. Heart sounds were muffled bilaterally. Oxygen therapy was initiated, and thoracic point-of-care ultrasound revealed a bilateral pleural effusion. Serohaemorrhagic fluid (160 ml) was drained by thoracocentesis.

Biochemistry confirmed a severe hyperglobulinaemia (105 g/l; RI 26–51). Serum protein electrophoresis (SPE) revealed a monoclonal gammopathy with a gammaglobulinaemia of 64.1 g/l (RI 5.8–23.0) (Figure 1). Serum electrolytes were within normal limits. Complete blood count confirmed a moderate normocytic normochromic non-regenerative anaemia (RBCs: $3.55 \times 10^{12}/l$ [RI 6.54–12.2]; haematocrit 15.9% [RI 30.3–52.3%]; haemoglobin 5.2 g/dl [RI 9.8–16.2]; reticulocytes 22.4 K/ μ l [RI 3.0–50.0]; mean cell volume (MCV) 44.8 fl [RI 35.9–53.1]; mean cell haemoglobin (MCH) 32.7 g/dl [RI 28.1–35.8]). Urinalysis showed a trace of proteins with a specific gravity of 1.014.

Pleural effusion was characterised as an exudate (RBCs: 30,000/ mm^3 ; nucleated cells: 3800/ mm^3 ; total protein: 56 g/dl). Cytological examination showed plasma cells, representing up to 40% of nucleated cells, with marked atypia, binucleations, anisocytosis, anisokaryosis, macrokaryosis and mitotic figures (Figure 2). These findings were consistent with a myelomatous pleural effusion.

Biochemistry, SPE and cytology of pleural effusion suggested an atypical presentation of MRD. Bone marrow aspiration revealed a polymorphic population of plasma cells, representing up to 100% of nucleated cells in most bone marrow spicules. Binucleation, anisocytosis, anisokaryosis and macrokaryosis were prominent among these plasma cells (Figure 3). The myeloid lineage was normal; however, the erythroid lineage was significantly reduced.

Thoracic radiographs performed after thoracocentesis showed pathological rib fractures, persistent pleural effusion and lung atelectasis, with no evidence of mass lesion (Figure 4a,b). Spine and pelvis radiographs revealed multiple lytic bone lesions consistent with bone geodes (Figure 4c,d).

An MM complicated with multifocal osteolytic lesions and an MPE was diagnosed.

Chemotherapy was initiated with cyclophosphamide (240 mg/ m^2 PO q10days [Endoxan; Baxter]) combined with prednisolone (1.6 mg/kg PO q24h [Dermipred; Ceva Santé Animale]). Alendronic acid was prescribed (3.2 mg/kg PO once a week [Alendronate; Teva Pharmaceutical Industries]) for the management of lytic bone lesions and associated pain. Gabapentin (10 mg/kg PO q8h [Neurontin; Pfizer]) was dispensed for pain management. Finally, darbepoetin alpha supplementation was

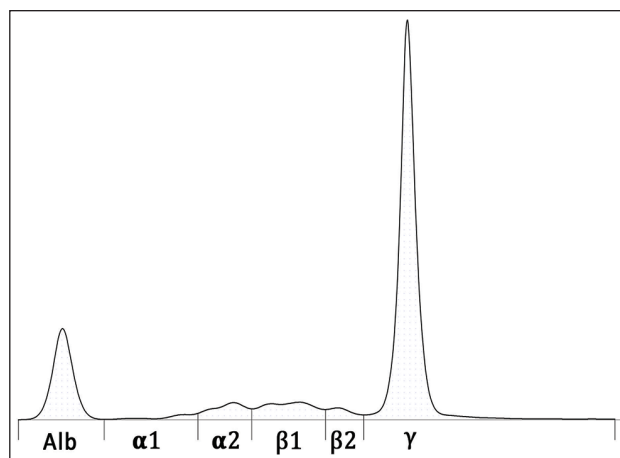


Figure 1 Serum protein electrophoresis at the time of diagnosis showing a narrow monoclonal spike in the gammaglobulin region. Albumin (Alb) 17.5 g/l (reference interval [RI] 44.5–62.3), 21.4% (RI 25.0–39.0%); alpha 1 globulins (α 1) 1.7 g/l (RI 2.2–7.6), 2.1% (RI 2.0–5.0%); alpha 2 globulins (α 2) 5.4 g/l (RI 5.7–19.9), 6.6% (RI 8.0–11.0%); beta 1 globulins (β 1) 8.6 g/l (RI 2.8–11.3), 10.5% (RI 3.0–5.0%); beta 2 globulins (β 2) 2.7 g/l (RI 3.1–11.7), 3.3% (RI 3.0–6.0%); gamma globulins (γ) 64.1 g/l (RI 5.8–23.0), 78.2% (RI 12.0–32.0%). Agarose gel electrophoresis Hydrasys 2 Scan (Sebia)

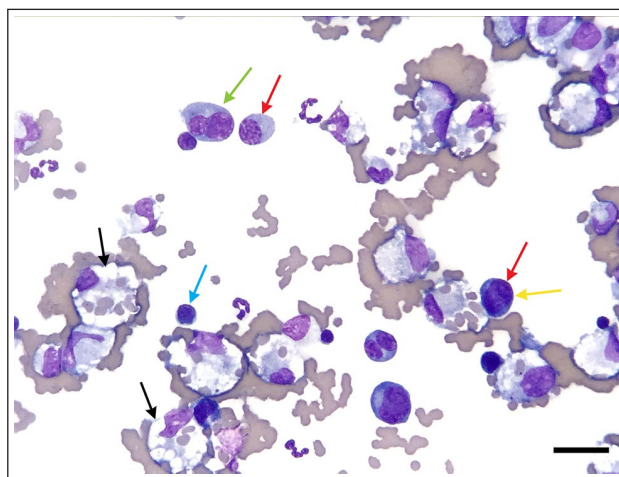


Figure 2 Photomicrograph of pleural effusion. Plasma cells show the following atypia: anisocytosis, anisokaryosis (red arrows), binucleation (green arrow) and macrokaryosis (yellow arrow). Some plasma cells are immature (blue arrow). Erythrophagocytosis was seen in many macrophages (black arrows). May–Grünwald–Giemsa stain. Scale bar 20 μ m

started (1 μ g/kg SC once a week [ND Aranesp; Amgen]) in an attempt to promote erythropoiesis.

After 2 weeks, a clinical improvement was reported. However, complete blood count revealed persistent non-regenerative anaemia (RBCs $3.03 \times 10^{12}/l$ [RI 6.54–12.20]; haematocrit 14.4% [RI 30.3–52.3]; haemoglobin 4.5 g/dl [RI 9.8–16.2]; reticulocytes 55.1 K/ μ l [RI 3.0–50.0]; MCV

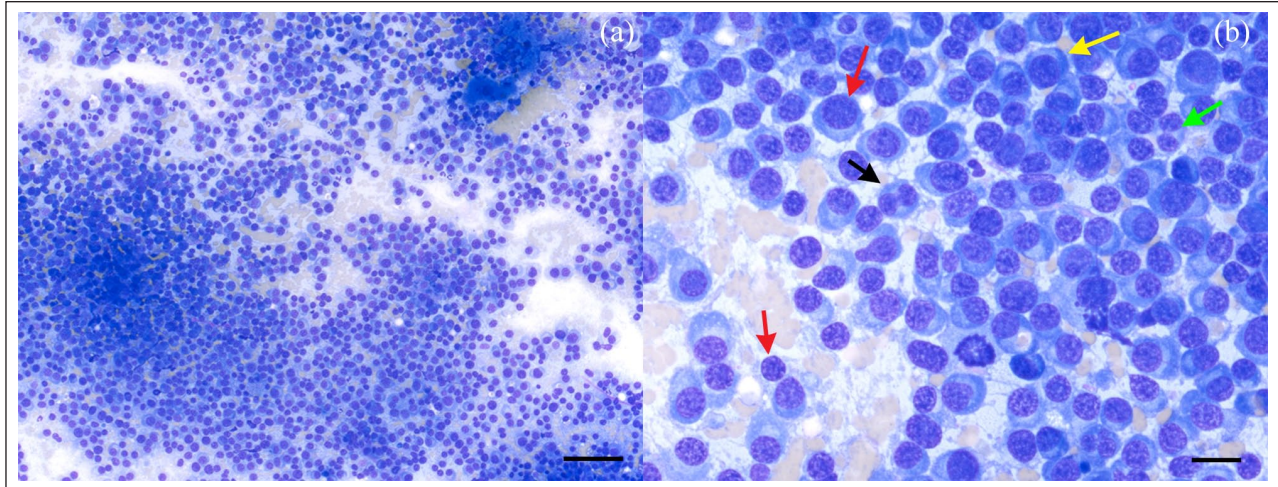


Figure 3 Cytological analysis of bone marrow aspiration. (a) Photomicrograph. Note the marked hypercellular bone marrow due to plasma cells invasion and the reduced erythroid lineage. (b) Photomicrograph. Plasma cells with anisocytosis, anisokaryosis (red arrows), binucleation (green arrow), macrokaryosis (yellow arrow) and mitotic figures (black arrow) are observed. May–Grünwald–Giemsa stain. Scale bars: (a) 100 μ m and (b) 20 μ m

47.5 fl [RI 35.9–53.1]; MCH 31.3 g/dl [RI 28.1–35.8]) and the persistence of pleural effusion was confirmed on thoracic ultrasound. Thoracocentesis was repeated and oral chemotherapy with cyclophosphamide was pursued. One month after the diagnosis, inspiratory efforts recurred. A large quantity of pleural effusion was identified. Hyperglobulinaemia (119 g/l; RI 26–51) and monoclonal gammopathy (88.5 g/l; RI 5.8–23.0) worsened. Based on the unfavourable clinical evolution, euthanasia was requested by the owners and necropsy was declined.

Discussion

MRDs in cats are rare and represent <1% of malignant tumours.² Up to 2021, about 50 cases were reported – mainly case reports or small case series. The mean age of cases varies from 12.5 to 14 years,³ and the youngest reported cases were 7 years old.^{2,4} To date, there is no established breed or sex predisposition.

MM is considered to be the most common and severe MRD in dogs and cats.¹ In dogs, a diagnosis of MM is based on at least two of the following four criteria:² (1) monoclonal gammopathy; (2) Bence Jones proteinuria; (3) aggressive osteolytic lesion(s); (4) and bone marrow plasma cells representing >20% of marrow nucleated cells. For cats, a cut-off of 10% has been suggested because bone marrow infiltration may be milder in this species.⁵ In addition, some cats with MRD showed visceral infiltration (such as liver, spleen^{2,6} or, more rarely, kidney and digestive tract)⁶ without detectable bone marrow plasmacytosis,^{3,7} making the diagnosis harder to establish. Therefore, consideration of plasma cell morphology and visceral organ infiltration have also been suggested as diagnostic criteria in feline MM.^{2,8} In our case, the monoclonal gammopathy, the marked medullar

plasmacytosis (up to 100% of nucleated cells) and the presence of osteolytic lesions were consistent with a diagnosis of MM. In addition, an MPE was identified; this has never been previously described in dogs and cats, but was a key element for the diagnosis of MM in this case.

MPE is an extremely uncommon but well-described manifestation in human patients with MM, and occurs in <1% of cases.⁹ The pathophysiology is poorly understood: MPE is thought to arise from a thoracic plasma cell infiltration (dissemination of pleura, lung parenchyma or mediastinal lymph nodes).¹⁰ Only case series and case reports of MPE are available in humans, limiting consistency in diagnostic techniques and treatment. MPE is commonly considered as a late manifestation of MM;¹¹ however, few reports have also described MPE as an early clinical finding.^{12–15} As in our case, respiratory clinical signs secondary to MPE may be the only clinical sign leading to the diagnosis of MM.^{12,13,16}

Pleural effusion secondary to congestive heart failure due to hyperviscosity, renal failure, pulmonary embolism, chylothorax, haemorrhage and infection are also common in patients diagnosed with MM and are reported in 6–14% of cases.^{10,15,17} Therefore, clinicians must be advised of these causes as some are treatable and carry a better prognosis than MPE.

Effusion cytology is the most common and inexpensive method to diagnose MPE.¹⁵ Wright's stain may help in identifying malignant plasma cells.¹⁸ However, owing to paucicellular samples and a highly varied appearance of plasma cells, cytology is often insufficient to achieve a final diagnosis.¹¹ Moreover, distinguishing reactive plasma cells secondary to tuberculosis infection, viral infection or certain types of lymphoma from malignant

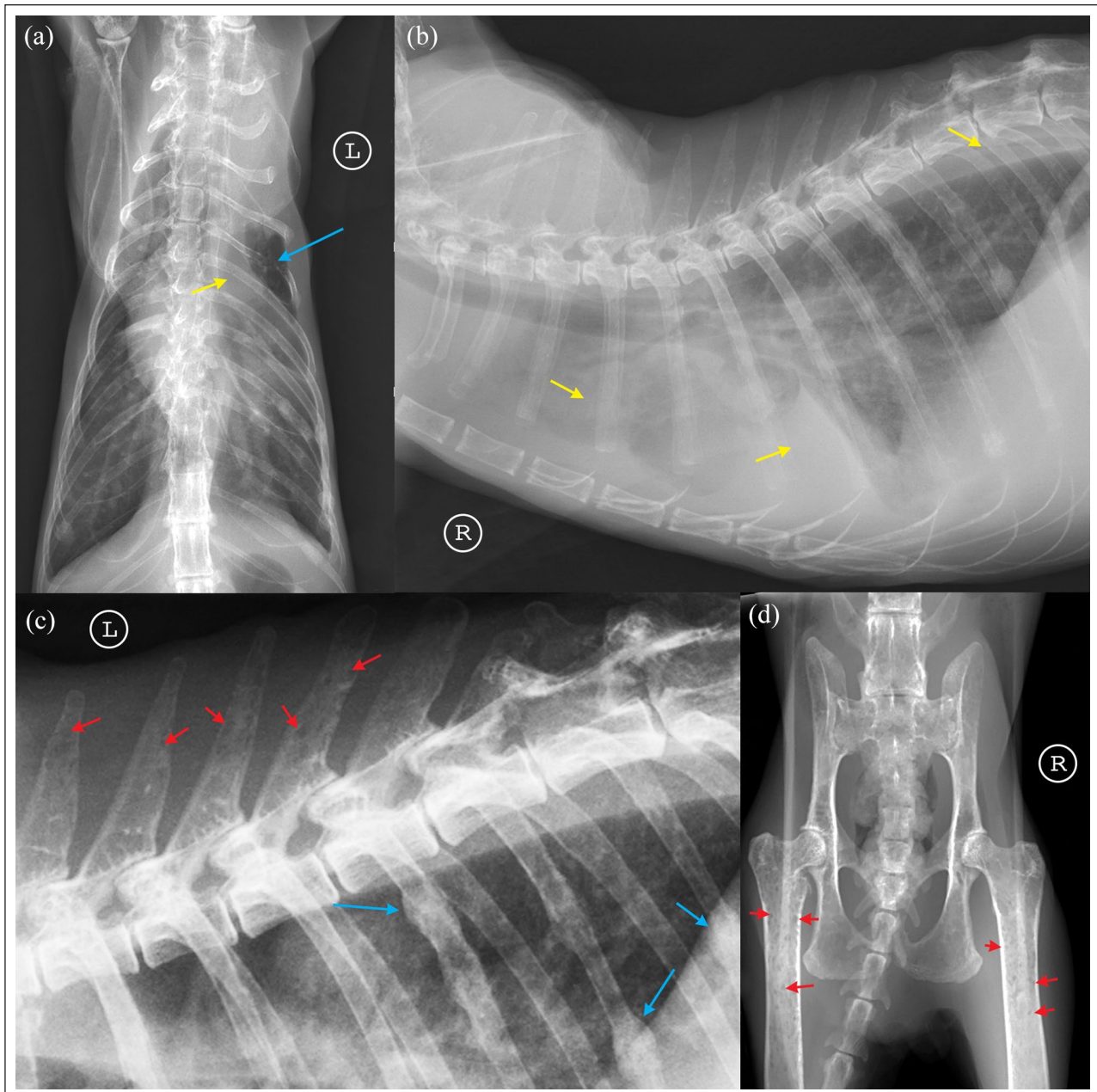


Figure 4 (a) Thoracic ventrodorsal projection radiograph. A pathological fracture of the fifth rib (blue arrow) and pleural effusion are seen (yellow arrow). (b) Right thoracic lateral projection radiograph. Pleural effusion is present (yellow arrows). (c) Left lateral projection radiograph of thoracic spine: numerous circular bone lytic lesions are observed on spinous processes (red arrows) and probably healed rib fractures (blue arrows). (d) Ventrodorsal projection radiograph of the pelvis: osteolytic lesions are observed, involving proximal extremities of both femurs (red arrows)

ones on cytology can be challenging.¹⁹ Therefore, further investigations such as imaging or histological analysis may be warranted.

Thoracic CT may provide information on the intrathoracic infiltration. In dogs and cats with pleural effusion, findings such as costal pleural mass, diaphragmatic pleural thickening and pulmonary mass are suggestive of malignant pleural effusion.²⁰ Pleural biopsies could

also be considered, but its sensitivity is unknown. However, for humans with MPE, some authors claim that pleural biopsies are associated with a higher diagnostic yield than cytology.¹²

SPE on pleural effusion is considered to be irrelevant. Even if there are immunoglobulins identical to those identified in serum,¹⁵ a diagnosis of MPE should not be made because of the lack of specificity of this technique.¹⁷

Analysis of the pleural effusion using flow cytometry (FC) may identify malignant plasma cells and differentiate them from reactive plasma cells. In human medicine, normal and reactive plasma cells have similar antigens expression (eg, CD19, CD27, CD45 and CD81), whereas neoplastic plasma cells show overexpression of CD20, CD28, CD33 and CD56, and decreased expression of CD27, CD38, CD45 and CD81.²¹ Assessment of a combination of the mentioned antigens by FC has a better sensitivity and specificity than cytology.¹⁶ Indeed, some authors suggest that a significant proportion of MPE is underdiagnosed when FC is not performed.^{10,22} FC combined with immunocytochemistry has been reported for the diagnosis of a plasma cell leukaemia for one dog.²³ For this case, immunocytochemistry demonstrated that circulating cells were strongly positive for multiple myeloma oncogene 1/interferon regulatory factor 4 (MUM-1) and weakly to moderately positive for Pax5. In cats, immunocytochemistry and immunohistochemistry may be useful to discriminate MRD from other round cell tumours and to categorise feline MRD (between poorly, intermediate or well differentiated).²⁴ Therefore, when cytological examination is inconclusive, FC, immunocytochemistry or immunohistochemistry on effusion cell block²⁵ would be a reliable alternative to pleural biopsies. Only a few immunoglobulin reagents are readily available for the feline species, but these techniques will probably be more accessible in the future.

In people, MPE is commonly associated with a poor prognosis, with a median overall survival of <4 months, despite the initiation of treatment.¹² Management of MPE should include treatment of MM, as well as draining the effusion. Relapsing effusion is common, and chemotherapy combined with a pleural access port or pleurodesis is an acceptable palliative option for most patients.¹¹ The use of more aggressive chemotherapy or radiotherapy did not appear to provide additional benefit.¹⁴

In veterinary medicine, MPE has not previously been described in dogs and cats diagnosed with MM. In cats, only three cases of MRD have been reported with pleural effusion. Among these three cases,^{2,7,26} one had a suspected septic effusion,² and the other a confirmed cardiogenic effusion based on echocardiographic changes.²⁶ The last one, from 1986,⁷ had a confirmed septic pleural effusion with *Salmonella typhimurium*, and effusion cytology reported some pleiomorphic plasma cells.

In our case, neither biochemical nor haematological improvement was noted despite the initiation of chemotherapy. Response to therapy is usually assessed with clinical evolution, weekly complete blood count and monthly assessment of serum globulin and SPE.^{1,3,4} A recent study²⁷ in dogs with MM showed that serum

M-protein concentration during treatment was significantly correlated to overall survival time, whereas serum globulinaemia was not. Thus, the authors highly advised against the use of serum globulinaemia to assess response to treatment in dogs and recommended performing SPE instead. The same recommendations may be followed in cats with MRD, but no data supporting this assumption are currently available.

Despite cyclophosphamide and prednisolone administration, and repeated thoracocentesis, progressive disease was noticed. The expected response rate to chemotherapy in cats diagnosed with MM ranges between 50% and 83%, and most recent studies report median survival times ranging from 8 to 13 months with chemotherapy.⁴⁻⁶ For our case, a rescue protocol with chlorambucil or COP was discussed with the owners, but they declined this considering the decrease in quality of life.

Conclusions

To our knowledge, this is the first described case of MPE as a manifestation of MM in a cat. MPE is an extremely rare manifestation of MM in human oncology. Confirming an MPE can be challenging but has an essential clinical, diagnostic and prognostic significance. In case of an inconclusive pleural effusion cytology, clinicians should investigate other causes of pleural effusion (ie, pyothorax, cardiogenic effusion, chylothorax and haemorrhage) as the prognosis may be significantly worse in the case of confirmed MPE. If a suspicion of MPE remains despite an equivocal cytological examination, thoracic CT, FC, immunocytochemistry or immunohistochemistry on an effusion cell block and pleural biopsies should be considered. Considering that MPE is a negative prognostic factor in people and the poor clinical evolution in this case report, MPE might also have a negative prognostic impact in cats with MM. Palliative pleurodesis or pleural access port placement could be discussed, but the medium-term benefits of this procedure might be limited.

Conflict of interest The authors declared no potential conflicts of interest with respect to the research, authorship, and/or publication of this article.

Funding The authors received no financial support for the research, authorship, and/or publication of this article.

Ethical approval The work described in this manuscript involved the use of non-experimental (owned or unowned) animals. Established internationally recognised high standards ('best practice') of veterinary clinical care for the individual patient were always followed and/or this work involved the use of cadavers. Ethical approval from a committee was therefore not specifically required for publication in *JFMS Open*

Reports. Although not required, where ethical approval was still obtained, it is stated in the manuscript.

Informed consent Informed consent (verbal or written) was obtained from the owner or legal custodian of all animal(s) described in this work (experimental or non-experimental animals, including cadavers) for all procedures undertaken (prospective or retrospective studies). No animals or people are identifiable within this publication, and therefore additional informed consent for publication was not required.

ORCID iD Tancrede Amalbert  <https://orcid.org/0000-0001-9463-8838>

Aude Morgane Canonne  <https://orcid.org/0000-0002-9263-1744>

Jérémy Béguin  <https://orcid.org/0000-0003-2400-8309>

References

- Vail DM. **Myeloma-related disorders**. In: Vail D, Thamm D and Liptak J (eds). *Withrow and MacEwen's small animal clinical oncology*. 6th ed. St Louis, MO: Elsevier, 2020, pp 739–772.
- Patel RT, Caceres A, French AF, et al. **Multiple myeloma in 16 cats: a retrospective study**. *Vet Clin Pathol* 2005; 34: 341–352.
- Hajek R, Munoz A, Riber C, et al. **Multiple myeloma in horses, dogs and cats: a comparative review focused on clinical signs and pathogenesis**. In: Roman H (ed). *Multiple myeloma – a quick reflection on the fast progress*. InTech. London: United Kingdom, 2013, pp 289–326.
- Hanna F. **Multiple myelomas in cats**. *J Feline Med Surg* 2005; 7: 275–287.
- Mellor PJ, Haugland S, Smith KC, et al. **Histopathologic, immunohistochemical, and cytologic analysis of feline myeloma-related disorders: further evidence for primary extramedullary development in the cat**. *Vet Pathol* 2008; 45: 159–173.
- Cannon CM, Knudson C and Borgatti A. **Clinical signs, treatment, and outcome in cats with myeloma-related disorder receiving systemic therapy**. *J Am Anim Hosp Assoc* 2015; 51: 239–248.
- Hawkins EC, Feldman BF and Blanchard PC. **Immunoglobulin A myeloma in a cat with pleural effusion and serum hyperviscosity**. *J Am Vet Med Assoc* 1986; 188: 876–878.
- Mellor PJ, Haugland S, Murphy S, et al. **Myeloma-related disorders in cats commonly present as extramedullary neoplasms in contrast to myeloma in human patients: 24 cases with clinical follow-up**. *J Vet Intern Med* 2006; 20: 1376–1383.
- Kintzer JS, Rosenow EC and Kyle RA. **Thoracic and pulmonary abnormalities in multiple myeloma. A review of 958 cases**. *Arch Intern Med* 1978 138: 727–730.
- Byun JM, Kim KH, Choi IS, et al. **Pleural effusion in multiple myeloma: characteristics and practice patterns**. *Acta Haematol* 2017; 138: 69–76.
- Kamble R, Wilson C, Fassas A, et al. **Malignant pleural effusion of multiple myeloma: prognostic factors and outcome**. *Leuk Lymphoma* 2005; 46: 1137–1142.
- Jiang AG, Yang YT, Gao XY, et al. **Bilateral pleural effusion as an initial manifestation of multiple myeloma: a case report and literature review**. *Exp Ther Med* 2015; 9: 1040–1042.
- Coppola A, Ghinassi G, Ciarleglio G, et al. **Pleural effusion as first extra-medullary clinical presentation of an occult multiple myeloma: the role of medical thoracoscopy**. *Respir Med Case Rep* 2020; 29. DOI: 10.1016/j.rmcr.2020.101013.
- Rodelo A and Joshi J. **Myelomatous pleural effusion as a presenting symptom: a case report**. *Cureus* 2019; 11: e5153. DOI: 10.7759/cureus.5153.
- Riveiro V, Ferreiro L, Toubes ME, et al. **Characteristics of patients with myelomatous pleural effusion. A systematic review**. *Rev Clin Esp (Barc)* 2018; 218: 89–97.
- Zhang LL, Li YY, Hu CP, et al. **Myelomatous pleural effusion as an initial sign of multiple myeloma – a case report and review of literature**. *J Thorac Dis* 2014; 6: E152–E159. DOI: 10.3978/j.issn.2072-1439.2014.06.48.
- Imed BG, Feki NB, Lamoum M, et al. **Pleural myelomatous involvement in multiple myeloma: five cases**. *Ann Saudi Med* 2015; 35: 327–330. DOI: 10.5144/0256-4947.2015.327.
- Kapadia SB. **Cytological diagnosis of malignant pleural effusion in myeloma**. *Arch Pathol Lab Med* 1977; 101: 534–535.
- Bredrossian CW. **Diagnostic problems in serous effusions**. *Diagn Cytopathol* 1998; 19: 131–137.
- Reetz JA, Suran JN, Zwingenberger AL, et al. **Nodules and masses are associated with malignant pleural effusion in dogs and cats but many other intrathoracic CT features are poor predictors of the effusion type**. *Vet Radiol Ultrasound* 2019; 60: 289–299.
- Wang H and Lin P. **Flow cytometric immunophenotypic analysis in the diagnosis and prognostication of plasma cell neoplasms**. *Cytometry B Clin Cytom* 2019; 96: 338–350.
- Arora P, Gupta SK, Mallik N, et al. **Flow cytometry in diagnosis of myelomatous pleural effusion: a case report**. *Indian J Hematol Blood Transfus* 2016; 32 Suppl 1: 138–142.
- Rout ED, Shank AM, Waite AH, et al. **Progression of cutaneous plasmacytoma to plasma cell leukemia in a dog**. *Vet Clin Pathol* 2017; 46: 77–84.
- Mellor PJ, Haugland S, Smith KC, et al. **Histopathologic, immunohistochemical, and cytologic analysis of feline myeloma-related disorders: further evidence for primary extramedullary development in the cat**. *Vet Pathol* 2008; 45: 159–173.
- Chen H, Li P, Xie Y, et al. **Cytology and clinical features of myelomatous pleural effusion: three case reports and a review of the literature**. *Diagn Cytopathol* 2018; 46: 604–609.
- Takeuchi Y, Iizuka H, Kanemitsu H, et al. **Myeloma-related disorder with leukaemic progression in a cat**. *J Feline Med Surg* 2010; 12: 982–987.
- Moore AR, Harris A, Jeffries C, et al. **Retrospective evaluation of the use of the International Myeloma Working Group response criteria in dogs with secretory multiple myeloma**. *J Vet Intern Med* 2021; 35: 442–450.