

A Right Intercosto-Bronchial Artery Derived from the Thyrocervical Trunk: An Unusual Cause of Type II Endoleak Post Thoracic Aortic Stenting

Andrew MTL Choong, M.D.^{1,2,3}, Ken Mitchell, M.D.⁴, Jason Jenkins, M.D.¹

The aetiology, incidence and management of type II endoleaks in standard infrarenal endovascular aortic aneurysm repair is well described. Far less data is available for thoracic stent grafting. We present a rare and interesting case of a type II endoleak post thoracic aortic stenting and highlight the aberrant anatomy that can cause this phenomenon in such cases.

Key words: 1. Intercostal artery
2. Stents
3. Aneurysm
4. Endoleak

CASE REPORT

A 79-year-old woman presented to our tertiary referral vascular surgical centre with an incidental finding of a thoracic aortic aneurysm on routine chest radiography. Upon further investigation, she was found to have an isolated descending thoracic aortic aneurysm secondary to a previous open aortic coarctation repair that she had undergone at the age of 38. She underwent a left carotid-subclavian bypass graft with left vertebral reimplantation prior to the completion of thoracic aortic stent grafting nine days later. An angiogram taken after thoracic aortic stent grafting and a post-implantation computed tomography angiogram performed the following day demonstrated no endoleak, and she was discharged eight days later.

Four months later, a small type II endoleak was subsequently demonstrated with minimal expansion of the aneur-

ysm sac. Over the course of the following five years, she underwent regular observation until sac expansion required further investigation and intervention. Catheter-directed angiography demonstrated that the right intercostal bronchial artery was communicating with the aneurysm sac, corresponding to the type II endoleak seen on computed tomography angiography (Fig. 1). Onyx (Covidien, Irvine, CA, USA) was used to perform standard coil embolization, and no flow into the aneurysm sac was found after the procedure (Fig. 2).

DISCUSSION

Whilst the phenomenon of type II endoleaks and their management is well described for the endovascular repair of infra-renal aneurysms, there is less data available about type II endoleaks following thoracic aortic stent grafting. The in-

¹Department of Vascular Surgery, Royal Brisbane and Women's Hospital, ²Department of Surgery, University of Queensland, Brisbane,

³Department of Surgery, Griffith University, ⁴Department of Interventional Radiology, Royal Brisbane and Women's Hospital

Received: July 17, 2014, Revised: September 18, 2014, Accepted: September 23, 2014, Published online: April 5, 2015

Corresponding author: Andrew Choong, Associate Lecturer in Surgery, University of Queensland, Flat 7, College Court, Sussex Place, Hammersmith, London, UK [W6 9DY]

(Fax) 44-7780604020 (E-mail) mail@andrewchoong.com

© The Korean Society for Thoracic and Cardiovascular Surgery. 2015. All rights reserved.

© This is an open access article distributed under the terms of the Creative Commons Attribution Non-Commercial License (<http://creativecommons.org/licenses/by-nc/3.0>) which permits unrestricted non-commercial use, distribution, and reproduction in any medium, provided the original work is properly cited.

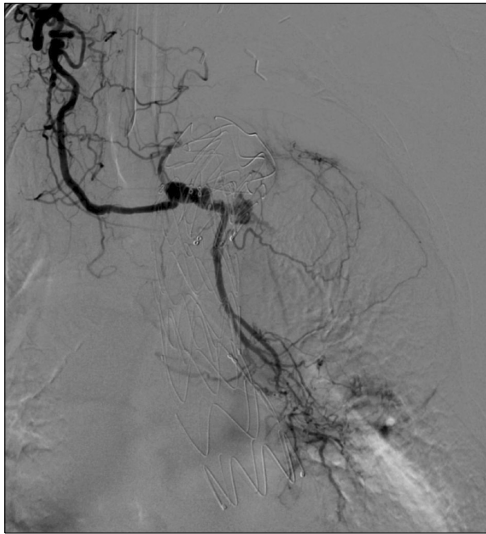

Fig. 1. Right Intercosto-bronchial Artery Derived from the Thyrocervical Trunk Post Thoracic Aortic Stenting Causing a Type II Endoleak.

idence of type II endoleaks following thoracic aortic stenting can be as high as 10.6% [1]. To our knowledge, only one similar report of a thyrocervical derived collateral causing a type II endoleak exists, described by Rivera-Sanfeliz et al. [2]. They describe a right thyrocervical trunk bronchial collateral, which is very similar to our description of an endoleak occurring in the intercostal bronchial artery. We strongly agree with their statement that the “examination of potential anomalous or collateral thoracic pathways is mandatory when considering treatment of a type II endoleak following endovascular TAA repair.”

“Onyx is a non-adhesive liquid embolic agent used for the pre-surgical embolization of brain arteriovenous malformations and aneurysms. Onyx is comprised of an ethylene vinyl alcohol copolymer dissolved in dimethyl sulfoxide, with suspended micronized tantalum powder to provide contrast for visualization under fluoroscopy [3].” The use of Onyx to treat type II endoleaks in endovascular abdominal aortic aneurysm repair was first reported in 2001 [4]. It is now a well-described and frequently used technique in the management of type II endoleaks following the endovascular repair of both abdominal and thoracic aneurysms [5-8]. However, its use for this purpose remains unlicensed and off-label. Our case further demonstrates the usefulness of Onyx for type II endoleak

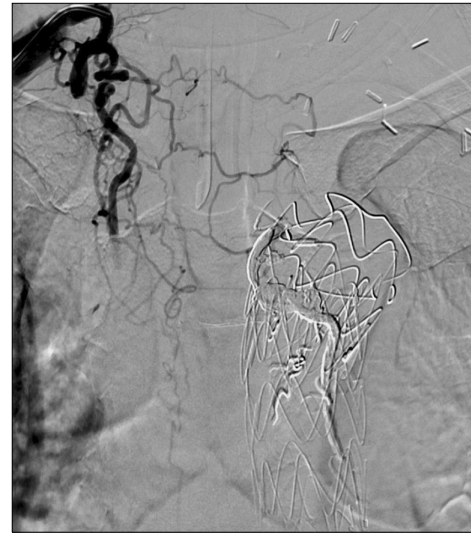


Fig. 2. Endoleak Resolution Following Onyx and Coil Embolisation.

embolization following endovascular aneurysm repair, even in unusual cases involving aberrant anatomy.

CONFLICT OF INTEREST

No potential conflict of interest relevant to this article was reported.

REFERENCES

1. Heijmen RH, Thompson MM, Fattori R, Goktay Y, Teebken OE, Orend KH. *Valiant thoracic stent-graft deployed with the new captivia delivery system: procedural and 30-day results of the Valiant Captivia registry.* J Endovasc Ther 2012;19:213-25.
2. Rivera-Sanfeliz G, Kansal N. *Right thyrocervical trunk bronchial artery collateral: source of type II Endoleak after endovascular repair of thoracic aortic aneurysm.* J Vasc Interv Radiol 2007;18:655-8.
3. Covidien. *Onyx liquid embolic system* [Internet]. Irvine: Covidien; c2015 [cited]. Available from: <http://www.ev3.net/neuro/us/liquid-embolics/onyx-liquid-embolic-system.htm>.
4. Martin ML, Dolmatch BL, Fry PD, Machan LS. *Treatment of type II endoleaks with Onyx.* J Vasc Interv Radiol 2001; 12:629-32.
5. Massis K, Carson WG 3rd, Rozas A, Patel V, Zwiebel B. *Treatment of type II endoleaks with ethylene-vinyl-alcohol copolymer (Onyx).* Vasc Endovascular Surg 2012;46:251-7.
6. Bosiers MJ, Schwindt A, Donas KP, Torsello G. *Midterm*

- results of the transarterial use of Onyx in the treatment of persisting type II endoleaks after EVAR.* J Cardiovasc Surg (Torino) 2013 Apr 5 [Epub].
7. Muller-Wille R, Wohlgemuth WA, Heiss P, et al. *Transarterial embolization of type II endoleaks after EVAR: the role of ethylene vinyl alcohol copolymer (Onyx).* Cardiovasc Intervent Radiol 2013;36:1288-95.
 8. Khaja MS, Park AW, Swee W, et al. *Treatment of type II endoleak using Onyx with long-term imaging follow-up.* Cardiovasc Intervent Radiol 2014;37:613-22.