

Which Clip? A Prospective Comparative Study of Retention Rates of Endoscopic Clips on Normal Mucosa and Ulcers in a Porcine Model

Payal Saxena, Eun Ji-Shin, Yamile Haito-Chavez, Ali K. Valeshabad, Venkata Akshintala, Gerard Aguila, Vivek Kumbhari, Dawn S. Ruben¹, Anne-Marie Lennon, Vikesh Singh, Marcia Canto, Anthony Kalloo, Mouen A. Khashab

Department of Medicine and Division of Gastroenterology and Hepatology, ¹Department of Molecular and Comparative Pathobiology, The Johns Hopkins Medical Institutions, Baltimore, MD, USA

Address for correspondence:
Asst. Prof. Mouen A. Khashab, Director of Therapeutic Endoscopy, Johns Hopkins Hospital, 1800 Orleans St, Suite 7125B, Baltimore, MD 21287, USA.
E-mail: mkhasha1@jhmi.edu

ABSTRACT

Background/Aim: There are currently no data on the relative retention rates of the Instinct clip, Resolution clip, and QuickClip2Long. Also, it is unknown whether retention rate differs when clips are applied to ulcerated rather than normal mucosa. The aim of this study is to compare the retention rates of three commonly used endoscopic clips. **Materials and Methods:** Six pigs underwent upper endoscopy with placement of one of each of the three types of clips on normal mucosa in the gastric body. Three mucosal resections were also performed to create "ulcers." Each ulcer was closed with placement of one of the three different clips. Repeat endoscopy was performed weekly for up to 4 weeks. **Results:** Only the Instinct and Resolution clips remained attached for the duration of the study (4 weeks). At each time point, a greater proportion of Instinct clips were retained on normal mucosa, followed by Resolution clips. QuickClip2Long had the lowest retention rate on normal mucosa. Similar retention rates of Instinct clips and Resolution clips were seen on simulated ulcers, although both were superior to QuickClip2Long. However, the difference did not reach statistical significance. All QuickClip2Long clips were dislodged at 4 weeks in both the groups. **Conclusions:** The Resolution and Instinct clips have comparable retention rates and both appeared to be better than the QuickClip2Long on normal mucosa-simulated ulcers; however this did not reach statistical significance. Both the Resolution clip and the Instinct clip may be preferred in clinical situations when long-term clip attachment is required, including marking of tumors for radiotherapy and anchoring feeding tubes or stents. Either of the currently available clips may be suitable for closure of iatrogenic mucosal defects without features of chronicity.

Key Words: Anchor, bleeding, endoclip, hemoclip, ulcer, upper endoscopy

Received: 15.04.2014, Accepted: 12.07.2014

How to cite this article: Saxena P, Ji-Shin E, Haito-Chavez Y, Valeshabad AK, Akshintala V, Aguila G, *et al.* Which clip? A prospective comparative study of retention rates of endoscopic clips on normal mucosa and ulcers in a porcine model. Saudi J Gastroenterol 2014;20:360-5.

Endoscopic clips have evolved tremendously over the last four decades since their first description in 1975.^[1] They were initially used as a therapeutic tool for hemostasis; however, technical difficulties with clip deployment and low retention rates limited their use. Subsequent improvement in clip

design has led to their widespread use for the treatment of nonvariceal gastrointestinal (GI) bleeding. Furthermore, indications have now expanded to include closure of iatrogenic perforations and anastomotic leaks, marking tumors prior to surgery or radiotherapy, and anchoring stents and feeding tubes.^[2-6] For the majority of these indications, it is critical to know how long the clip will remain *in situ* (clip retention time) and perform its intended function. Prior studies have demonstrated long retention rates of the Resolution clip (Boston Scientific, Natick, MA, USA) in comparison to the Triclip (Cook Medical Inc, Winston-Salem, NC, USA), HX-5L clip (Olympus America, Inc., Center Valley, PA, USA), and QuickClip (Olympus America) in gastric ulcer and bleeding animal models.^[7-9] Healing of ulcers treated

Access this article online	
Quick Response Code: 	Website: www.saudijgastro.com
	DOI: 10.4103/1319-3767.145328

with endoclipping (Resolution and Triclip) was achieved in 2-3 weeks and appeared to be quicker than control ulcers without clips or those treated with Quickclips.^[7] However, endoscopic clips have continued to evolve and the Triclip and HX-5L clips are no longer available. The current commercially available clips include the Instinct clip with 16 mm jaw width (Cook Medical Inc), Resolution clip with 11 mm jaw width (Boston Scientific), and two versions of the QuickClip2: QuickClip2Long with 11 mm jaw width and QuickClip2 with 9 mm jaw width (Olympus) [Figure 1].^[10] A recent study compared mechanical strength, rotational capabilities, and endoscope retroflexion capabilities with the currently available endoscopic clips.^[11] All three clips have the ability to rotate.^[12] The Instinct and Resolution clips are magnetic resonance imaging (MRI) compatible (up to 3 Tesla) and can be re-opened several times prior to final deployment^[13,14] [Table 1]. The duration of attachment at the site of application is particularly important when clips are used for marking gastrointestinal (GI) tumors for radiotherapy or attachment of endoprosthesis such as enteral feeding tubes.^[15,16] Therefore, establishing retention rates can help determine which clip should be used for various clinical applications. To date, there are no studies comparing the retention rates of the three current clips on ulcers or normal tissue. The aim of this study was to compare retention rates

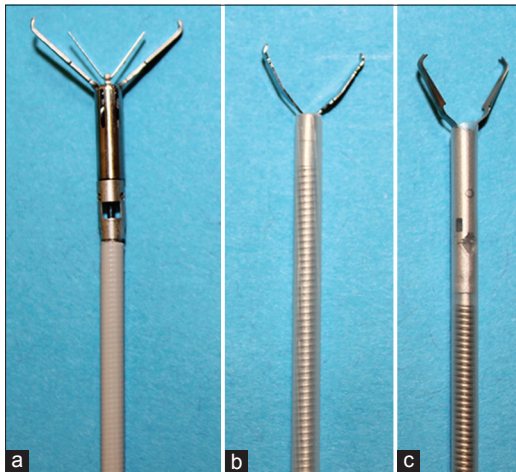


Figure 1: The instinct clip (a) with 16 mm jaw span, QuickClip2Long (b) with 11 mm jaw span and resolution clip (c) with 11 mm jaw span

of the Instinct, QuickClip2Long, and Resolution clips on normal tissue and ulcers in a survival porcine model.

MATERIALS AND METHODS

The study was approved by the Johns Hopkins University School of Medicine Institutional Animal Care and Use Committee. Six × 50 kg female pigs (*Sus scrofa domestica*) were fasted overnight prior to the procedure but allowed free access to water. Pre-anesthesia medication, which consisted of an intramuscular injection of 500 mg Telazol (tiletamine HCl and zolazepam HCl; Lederle Parenterals, Inc, Carolina, Puerto Rico) reconstituted with 2.5 ml of 100 mg/mL ketamine HCl and 2.5 ml of 100 mg/mL xylazine, at a total dose of approximately 0.05 mL/kg, was administered. An intravenous (IV) line was placed in a marginal ear vein. Normal saline solution was given during the procedure and general anesthesia was maintained with 1.5%-2% isoflurane and 7.0-mm endotracheal intubation (Mallinckrodt Co, C. D. Juarez, Chihuahua, Mexico). Heart rate, end tidal CO₂, and electrocardiogram were monitored throughout the procedures. All procedures were performed using a forward-viewing double channel endoscope (GIF-2T160; Olympus). One Resolution clip (Boston Scientific), one QuickClip2Long (Olympus) and one Instinct clip (Cook Medical) were placed alongside each other in the gastric body, on visible gastric folds. An 11 mm snare (Boston Scientific) was used to create three separate defects to simulate ulcers by performing cold snare resection of the gastric body mucosa. Each resection was standardized by opening the snare to maximum capacity during tissue capture. Subsequently, one of each of the three clips was used to close the “simulated ulcer” by apposing the “ulcer” edges. The Resolution clips were deployed after removing the sheath, to allow rotation of the clip to achieve optimal ulcer closure.^[12] A diagram of the stomach with location of 6 clips (3 on normal mucosa and 3 on ulcers) was drawn. Each type of clip (Resolution, QuickClip2Long, Instinct) was clearly identified on the diagram. Accompanying endoscopic photographs were also taken to document clip placement. The Instinct and QuickClip2Long clips were deployed as per manufacturers’ instructions. The pigs were then extubated

Table 1: Characteristics of through-the-scope hemostatic clips currently available in USA

Clip	Jaw span (mm)	Opening angle (°)	MRI compatibility	Rotatability	Re-opening capability
Resolution®					
Boston scientific	11	72	Yes	Yes	Yes
Instinct™					
Cook medical	16	125	Yes	Yes	Yes
QuickClip2™					
QuickClip2 Long™	9	85	No	Yes	No
Olympus	11	85	No	Yes	No

MRI: Magnetic resonance imaging

and allowed to recover from general anesthesia. The pigs were evaluated daily and commenced on regular oral feeds with standard chow on the evening of the procedure. All pigs underwent repeat endoscopy on a weekly basis for a total of 4 weeks. Retention of each type of clip on normal mucosa and simulated ulcers was recorded. After the final endoscopy, all animals were euthanized. Survival analysis of each clip in the normal mucosa and simulated ulcer group were performed.

Statistical analysis

Kaplan–Meier analysis was performed for retention of each type of endoscopic clips at 1 and 4 weeks. All statistical analyses were performed by using the Stata software, version 9.2 (StataCorp, College Station, TX, USA).

RESULTS

A total of six pigs underwent endoscopic placement of clips. In total, 36 clips were deployed. All procedures were performed by a single endoscopist (MAK) and a single assistant (GA) deployed all clips. A total of six Resolution clips, six QuickClip2Long clips, and six Instinct clips were placed on normal mucosa in all six pigs. A total of 18 ulcers (approximately 1 cm diameter) were successfully created in six pigs (three ulcers in each pig). A total of six Resolution clips, six QuickClip2Long clips, and six Instinct clips were successfully placed to appose the ulcer edges of all 18 ulcers. There were no technical failures of clip rotation or deployment on normal or ulcerated mucosa. Upper endoscopy was repeated at week 1 ($n = 6$), week 2 ($n = 5$), week 3 ($n = 5$), and week 4 ($n = 4$). Pigs 1 and 2 could not undergo repeat endoscopy at week 2 and 3, respectively, and pigs 5 and 6 could not undergo repeat endoscopy at week 4 due to laboratory closures for unforeseen circumstances.

As illustrated in Table 2, total of six (100%) Instinct clips, three (50%) QuickClip2Long clips, and four (67%) Resolution clips remained attached on normal mucosa at week 1. At week 2, total of five (83%) Instinct, two (40%) QuickClip2Long, and four (67%) Resolution clips remained attached. At 3 weeks, five (83%) Instinct, one (17%) QuickClip2Long, and three (50%) Resolution clips remained adherent to normal mucosa. At 4 weeks, retention rates on normal mucosa declined further to three (60%) Instinct, zero QuickClip2Long, and two (40%) Resolution clips.

Retention rates in the ulcer group were notably lower [Table 3]. At week 1, two (33%) Instinct, one (17%) QuickClip2Long, and three (50%) Resolution clips remained attached. At weeks 2 and 3, one (17%) Instinct, one (17%) QuickClip2Long, and two (33%) Resolution clips remained attached. At week 4, only one (17%) Instinct, zero QuickClip2Long, and one (17%) Resolution clip remained in place.

Kaplan–Meier analysis of the clip retention of the three clip groups was performed [Figures 2 and 3]. There was no statistically significant difference at 4 weeks between the three clip groups ($P = 0.15$). There was also no statistically significant difference across each pair of clip groups at week 1 (Instinct vs. Resolution, $P = 0.35$; Instinct vs. QuickClip2Long, $P = 0.08$; Resolution vs. QuickClip2Long, $P = 0.41$) or at 4 weeks (Instinct vs. Resolution, $P = 0.73$; Instinct vs. QuickClip2Long, $P = 0.07$; Resolution vs. QuickClip2Long, $P = 0.11$).

There were no complications encountered for the duration of the study. At postmortem examination, there was no tissue injury at the site of clip attachment [Figure 4] or along the serosal aspect of the stomach by gross examination.

DISCUSSION

The first endoscopic clipping device was first described in 1975 and significant advances of through-the-scope (TTS) clipping

Table 2: Clips still attached on normal mucosa during repeat endoscopy

Type of clip	Week 1 $n=6$	Week 2 $n=5$	Week 3 $n=5$	Week 4 $n=4$
Instinct	6	5	5	3
QuickClip2Long	3	2	1	0
Resolution	4	4	3	2

n : Number of pigs

Table 3: Clips still attached on ulcers during repeat endoscopy

Type of clip	Week 1 $n=6$	Week 2 $n=5$	Week 3 $n=5$	Week 4 $n=4$
Instinct	2	1	1	1
QuickClip2Long	1	1	1	0
Resolution	3	2	2	1

n : Number of pigs

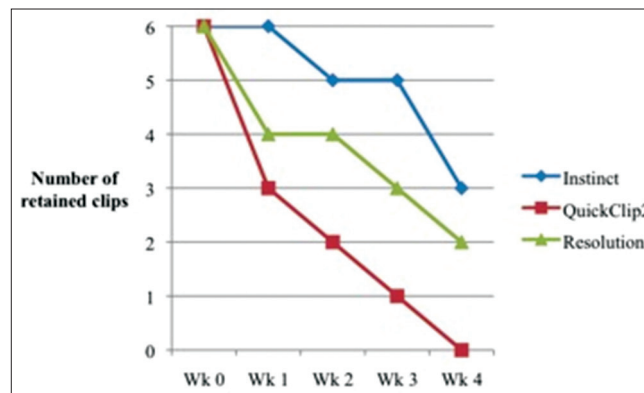


Figure 2: Survival analysis of instinct, QuickClip2Long, and resolution clips on normal mucosa at 4 week duration

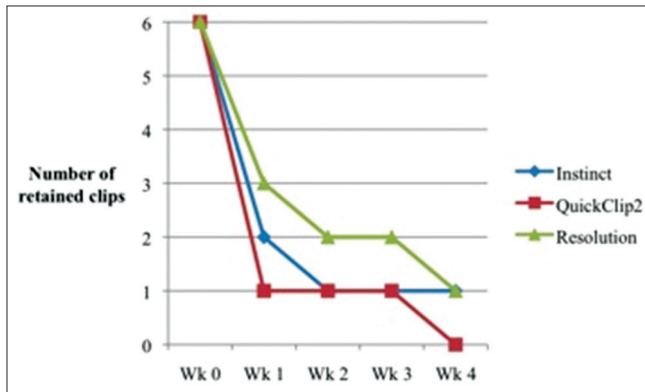


Figure 3: Survival analysis of instinct, QuickClip2Long, and resolution clips on simulated ulcers at 4 week duration

devices have ensued over the last three decades. The current commercially available clips have rotational capabilities (Resolution, Instinct, and QuickClip2Long),^[11,12,17] ability to reopen numerous times before deployment (Resolution, Instinct)^[17-19] and some are MRI compatible (Resolution, Instinct).^[14] Endoclips were initially used for hemostasis of nonvariceal bleeding. However, indications for endoclips have expanded significantly and now include marking of GI neoplasms for surgery or radiotherapy, attachment of endoprosthesis such as enteral feeding tubes or stents, and closure of GI fistulae, leaks, or perforations. Knowledge of retention rates of the different clips for many of these indications is crucial in determining which clip is best suited for the specific clinical application.

The current study is the first to compare retention rates of the currently commercially available hemoclips. Retention rates of both the Resolution clip and Instinct clip appeared to be greater than that of QuickClip2Long on normal mucosa and simulated ulcers in porcine stomachs. However, the difference did not reach statistical significance probably due to the relatively small sample size.

The mechanical properties of clips, including jaw length, opening angle, opening and closing forces, may correlate with clip retention rates. In the current study, a greater proportion of Instinct clips remained attached on normal mucosa in comparison to Resolution and QuickClip2Long clips at each time point during the study [Figure 2]. This may be related to greater opening force of Instinct clips in comparison to Resolution and QuickClip2Long clips as was demonstrated by Daram *et al.* in a bench-top model.^[11] Strength of clip closure may correlate with greater retention rate when clips are used for closing mucosal defects such as ulcers. The current study demonstrated similar retention rates of the Resolution clip and Instinct clips at week 4 and both remained attached for longer durations than QuickClip2Long in the current study [Figure 3]. Our results conform with Daram *et al.*'s

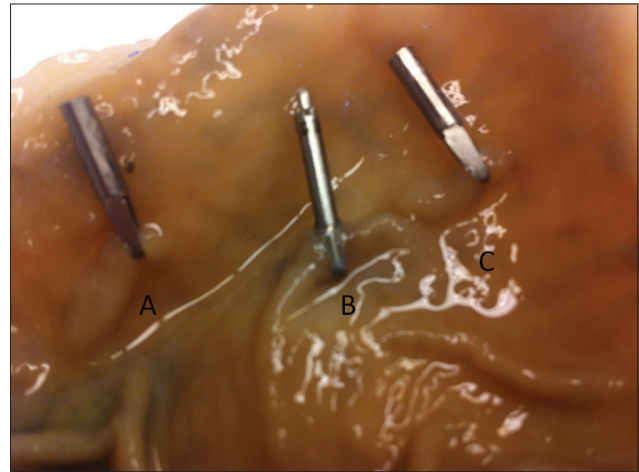


Figure 4: The Olympus clip (a), resolution clip (b), and instinct clip (c) in a porcine stomach at postmortem examination

findings that closure strengths of the Instinct and Resolution clips were comparable but superior to QuickClip2Long clip.^[11] It should be noted, however, that the studies have used the Long version of the QuickClip2 (11 mm vs 9 mm jaw width) and the mechanical characteristics of both clips would differ due to the varied clip arm length.

Prior studies assessing retention rates of various hemoclips have verified favorable results for the Resolution clip. In a study by Swellengrebel *et al.*, nine patients underwent clip placement for marking of inoperable rectal cancers prior to radiotherapy followed by repeat endoscopy at week 12. In total, 67% (4/6) of Resolution clips remained attached in comparison to 35% (7/20) of QuickClips.^[15] Shin *et al.* also found that the Resolution clip remained attached for a longer duration in comparison to the HX-5L clip (predecessor of QuickClip2Long) and TriClip (Cook Endoscopy) in five pig stomachs during a 5-week study. The majority (80%) of the HX-5L clips were dislodged at week 2 endoscopy.^[8] In a randomized controlled trial comparing control of hemostasis in canine ulcers using QuickClip2Long, TriClip, and Resolution clip, all three clips were similar for achieving hemostasis; however, median retention time for one or more clips was again higher for Resolution clips (8 weeks) in comparison to Triclip (1 week) and QuickClip2Long (2 weeks),^[7] also consistent with the findings of the current study. The usability and efficacy of hemoclips has been demonstrated in an ex vivo porcine model of bleeding gastric ulcers.^[20] The authors tested an over-the-scope clip (OTSC) and 2 hemoclips (Resolution, QuickClip) and found the OTSC to be superior with regard to time to achieve hemostasis yet both hemoclips performed similarly. The Resolution clip appeared to outperform QuickClip in terms of closing pressures. However, this study was performed on an ex vivo bench model, which simulates the anatomical conditions but may not adequately represent the physiological challenges of clip placement in live animals

(eg, peristalsis, hemodynamic changes in bleeding ulcers). From a clinical perspective, longer clip retention rates are required in cases of marking of tumors for radiotherapy, and anchoring feeding tubes or stents. However, closure of mucosal defects (eg, post-ESD) or acute perforations might require only short-term apposition of the sides of lesions for tissue repair and healing (1-2 weeks). Therefore, either of the currently available clips may be suitable for closure of iatrogenic mucosal defects without features of chronicity.

The main limitation of this study is the small number of animals. The difference in retention rates did not reach statistical significance, likely due to the relatively small sample size. The mucosal defects created in this animal model also lack features of chronicity and therefore may not represent the challenges of clipping in chronic gastric ulcers in patients. For example, there is no mucosal edema, fibrotic tissue, or exposed bleeding vessels, which are often associated with bleeding gastric ulcers and may pose different mechanics for clip closure and attachment. Additionally, “snare and resect” techniques do not induce significant bleeding in porcine stomachs since coagulation and aggregation in pigs is significantly higher in comparison to humans.^[21,22] Porcine models for bleeding peptic ulcers have been used for training. Surgically created models^[23] are not cost or time effective but the “snare and resect” model (with the use of anticoagulation and antiplatelet therapy) has been validated for training fellows.^[24] It should also be noted that porcine stomachs are prone to acute and stress ulceration (particularly in the esophagogastric region).^[25] Therefore, the endoscopist should be mindful to observe for any newly forming ulcers during follow-up endoscopic examinations. Hence, a study examining clip retention rate after therapeutic clip placement in patients (eg, ulcer bleeding, post-ESD, or polypectomy closure) with weekly abdominal X-rays would be of interest in ascertaining if our study findings can be replicated in clinical scenarios.

In conclusion, the Resolution and Instinct clips have comparable retention rates and appeared to be greater than the QuickClip2Long on normal mucosa and acute mucosal defects, although the difference was not statistically significant. Both the Resolution clip and the Instinct clip may be preferred in clinical situations when long-term clip attachment is required, including marking of tumors for radiotherapy, and anchoring feeding tubes or stents. Either of the currently available clips may be suitable for closure of iatrogenic mucosal defects without features of chronicity.

REFERENCES

- Hayashi T, Yonezawa M, Kuwabara T, Kudoh I. The study on staunch clip for treatment by endoscopy. *Gastrointest Endosc* 1975; 17:92-101.

- Frizzell E, Darwin P. Endoscopic placement of jejunal feeding tubes by using the Resolution clip: Report of 2 cases. *Gastrointest Endosc* 2006;64:454-6.
- Sebastian S, Buckley M. Endoscopic clipping: A useful tool to prevent migration of rectal stents. *Endoscopy* 2004;36:468.
- Segalin A, Bonavina L, Bona D, Chella B. Endoscopic clipping: A helpful tool for positioning self-expanding esophageal stents. *Endoscopy* 1995;27:348.
- Kim SH, Milsom JW, Church JM, Ludwig KA, Garcia-Ruiz A, Okuda J, *et al.* Perioperative tumor localization for laparoscopic colorectal surgery. *Surg Endosc* 1997;11:1013-6.
- Rodella L, Laterza E, De Manzoni G, Kind R, Lombardo F, Catalano F, *et al.* Endoscopic clipping of anastomotic leakages in esophagogastric surgery. *Endoscopy* 1998;30:453-6.
- Jensen DM, Machicado GA, Hirabayashi K. Randomized controlled study of 3 different types of hemoclips for hemostasis of bleeding canine acute gastric ulcers. *Gastrointest Endosc* 2006;64:768-73.
- Shin EJ, Ko CW, Magno P, Giday SA, Clarke JO, Buscaglia JM, *et al.* Comparative study of endoscopic clips: Duration of attachment at the site of clip application. *Gastrointest Endosc* 2007;66:757-61.
- Jensen DM, Machicado GA. Hemocliping of chronic canine ulcers: A randomized, prospective study of initial deployment success, clip retention rates, and ulcer healing. *Gastrointest Endosc* 2009;70:969-75.
- Saxena P, Chavez YH, Kord Valeshabad A, Kalloo AN, Khashab MA. An alternative method for mucosal flap closure during peroral endoscopic myotomy using an over-the-scope clipping device. *Endoscopy* 2013;45:579-81.
- Daram SR, Tang SJ, Wu R, To SD. Benchtop testing and comparisons among three types of through-the-scope endoscopic clipping devices. *Surg Endosc* 2013;27:1521-9.
- Saxena P, Khashab MA. Can all through-the-scope endoscopic clipping devices be rotated? Yes, they can. *Surg Endosc* 2013;27:3932-3.
- Daram SR, Tang SJ, Wu R, To SD. Benchtop testing and comparisons among three types of through-the-scope endoscopic clipping devices. *Surg Endosc* 2013;27:1521-9.
- Gill KR, Pooley RA, Wallace MB. Magnetic resonance imaging compatibility of endoclips. *Gastrointest Endosc* 2009;70:532-6.
- Swellengrebel HA, Marijnen CA, Vincent A, Cats A. Evaluating long-term attachment of two different endoclips in the human gastrointestinal tract. *World J Gastrointest Endosc* 2010;2:344-8.
- Schrijver AM, Siersema PD, Vleggaar FP, Hirdes MM, Monkelbaan JF. Endoclips for fixation of nasoenteral feeding tubes: A review. *Dig Liver Dis* 2011;43:757-61.
- Raju GS, Kaltenbach T, Soetikno R. Endoscopic mechanical hemostasis of GI arterial bleeding (with videos). *Gastrointest Endosc* 2007;66:774-85.
- Technology Assessment Committee, Chuttani R, Barkun A, Carpenter S, Chotiprasidhi P, Ginsberg GG, Hussain N, *et al.* Endoscopic clip application devices. *Gastrointest Endosc* 2006;63:746-50.
- Asge Technology Committee, Conway JD, Adler DG, Diehl DL, Farraye FA, Kantsevov SV, Kaul V, *et al.* Endoscopic hemostatic devices. *Gastrointest Endosc* 2009;69:987-96.
- Kato M, Jung Y, Gromski MA, Chuttani R, Matthes K. Prospective, randomized comparison of 3 different hemoclips for the treatment of acute upper GI hemorrhage in an established experimental setting. *Gastrointest Endosc* 2012;75:3-10.
- Roussi J, Samama M, Vaiman M, Nichols T, Pignaud G, Bonneau M, *et al.* An experimental model for testing von Willebrand factor function: Successful SLA-matched crossed bone marrow transplantations between normal and von Willebrand pigs. *Exp Hematol* 1996;24:585-91.

22. Bowie EJ, Owen CA Jr, Zollman PE, Thompson JH Jr, Fass DN. Tests of hemostasis in swine: Normal values and values in pigs affected with von Willebrand's disease. *Am J Vet Res* 1973;34:1405-7.
23. Hu B, Chung SC, Sun LC, Lau JY, Kawashima K, Yamamoto T, *et al.* Developing an animal model of massive ulcer bleeding for assessing endoscopic hemostatic devices. *Endoscopy* 2005;37:847-51.
24. Camus M, Marteau P, Pocard M, Bal Dit Sollier C, Lavergne-Slove A, Thibault A, *et al.* Validation of a live animal model for training in endoscopic hemostasis of upper gastrointestinal bleeding ulcers. *Endoscopy* 2013;45:451-7.
25. Swaby H, Gregory NG. A note on the frequency of gastric ulcers detected during post-mortem examination at a pig abattoir. *Meat Sci* 2012;90:269-71.

Source of Support: Nil, **Conflict of Interest:** None declared.