



Case Report

Coil embolization for ruptured distal anterior cerebral artery aneurysm at the supracallosal portion: Two case reports

Yuichiro Tsuji¹, Yuzo Kuroda¹, Masahiko Wanibuchi²

¹Department of Neurosurgery, Kano General Hospital, Osaka, ²Department of Neurosurgery, Osaka Medical and Pharmaceutical University, Takatsuki, Japan.

E-mail: *Yuichiro Tsuji - abyssinian1225@gmail.com; Yuzo Kuroda - yuzo77@gmail.com; Masahiko Wanibuchi - wanibuchi@omp.ac.jp



*Corresponding author:

Yuichiro Tsuji,
Department of Neurosurgery,
Kano General Hospital, Osaka,
Japan.

abyssinian1225@gmail.com

Received: 28 September 2023

Accepted: 25 November 2023

Published: 22 December 2023

DOI

10.25259/SNI_810_2023

Quick Response Code:



ABSTRACT

Background: Distal anterior cerebral artery (ACA) aneurysms occur more frequently in the genu portion and much less frequently in the supracallosal portion (A4–A5). This report describes two cases of ruptured cerebral aneurysms occurring at the supracallosal portion successfully treated with coil embolization.

Case Description: Case 1 involved a 61-year-old female with sudden-onset headache and vomiting attributed to subarachnoid hemorrhage (SAH). Digital subtraction angiography (DSA) revealed a bihemispheric ACA and aneurysm in the supracallosal portion. Coil embolization was performed, and the patient was discharged without neurological deficit. Case 2 involved a 35-year-old man with severe headache and disturbance of consciousness caused by SAH. DSA showed an aneurysm in A4 of the accessory ACA, and coil embolization was performed. After rehabilitation, he was discharged with a modified Rankin scale score of 2.

Conclusion: Coil embolization for a ruptured aneurysm at the supracallosal portion can yield good results if the patient is appropriately selected.

Keywords: Coil embolization, Distal anterior cerebral artery, Supracallosal portion

INTRODUCTION

Distal anterior cerebral artery (DACA) aneurysms account for approximately 5% of all aneurysms.^[3,5,9] DACA aneurysms typically occur in the genu portion and much less frequently in the supracallosal portion (A4–A5). Clipping surgery is frequently performed for ruptured DACA aneurysms that occur in the supracallosal portion.^[1,13]

In this report, we describe two cases of ruptured cerebral aneurysms in the supracallosal portion successfully treated with coil embolization.

CASE REPORTS

Case 1

A 61-year-old female presented to the emergency department after the sudden onset of headache and vomiting. Her Glasgow Coma scale (GCS) score was 15. Computed tomography (CT) of the brain

This is an open-access article distributed under the terms of the Creative Commons Attribution-Non Commercial-Share Alike 4.0 License, which allows others to remix, transform, and build upon the work non-commercially, as long as the author is credited and the new creations are licensed under the identical terms.

©2023 Published by Scientific Scholar on behalf of Surgical Neurology International

revealed a subarachnoid hemorrhage (SAH) and hematoma in the interhemispheric fissure [Figure 1a]. CT angiography (CTA) showed a saccular aneurysm in the DACA (A4–A5 portion) [Figure 1b]. Right internal carotid angiography revealed a bihemispheric anterior cerebral artery (ACA) and an aneurysm in the supracallosal portion [Figures 1c–e]. She underwent emergency coil embolization through a transfemoral route. Under general anesthesia, a 7Fr Roadmaster (Goodman, Aichi, Japan) was guided to the right internal cerebral artery (ICA), and a 4Fr Cerulean (Medikit, Tokyo, Japan) distal access catheter (DAC) was then guided to the ICA C2 portion. A Rester microcatheter (Hirata, Osaka, Japan) was deployed into the aneurysm with a 0.014-inch CHIKAI guidewire (Asahi Intec Co., Aichi, Japan). Coil embolization was performed with four coils using a simple technique, resulting in complete obliteration [Figure 1f]. A total of 4ED Extrasoft coils of helical type were deployed (Kaneka Medix, Osaka, Japan). After rehabilitation, the patient was discharged with a modified Rankin Scale (mRS) score of 0 on day 51 of hospitalization. She was followed up for 17 months with no recurrence.

Case 2

A 35-year-old man was admitted to the emergency room with a sudden onset of headache, vomiting, and

disturbance of consciousness. His GCS score was 6 (E1V1M4), and he was diagnosed with SAH. Brain CT revealed intracerebral hemorrhage and SAH from the corpus callosum to the cingulate gyrus [Figure 2a], and CTA revealed a saccular aneurysm in the DACA [Figure 2b]. 3D digital subtraction angiography indicated an aneurysm in A4 of the accessory ACA, which was bihemispheric type ACA [Figures 2c and d]. The aneurysm had a maximum diameter of 5 mm at its widest point but was 2.5 mm deep with a wide neck and cortical branches branching from the neck [Figure 2e]. He underwent endovascular embolization through transfemoral artery access. Under general anesthesia, a 7-Fr Optimo balloon-guiding catheter (Tokai Medical Products, Aichi, Japan) was placed into the right ICA, and a Guidepost DAC was then guided to the ICA C1 portion. A headway Duo microcatheter (MicroVention/Terumo, Tustin, CA, USA) was guided into the aneurysm using a 0.014-inch CHIKAI guidewire. Coil embolization was performed with six coils using a simple technique [Figure 2f]. A total of six coils of 3D type were deployed, of which four were Target 360 nano (Stryker, Fremont, CA, USA) coils and two were Microplex hypersoft 3D (MicroVention/Terumo, Tustin, CA, USA) coils. After rehabilitation for three months, the patient was discharged with a mRS score of 2.

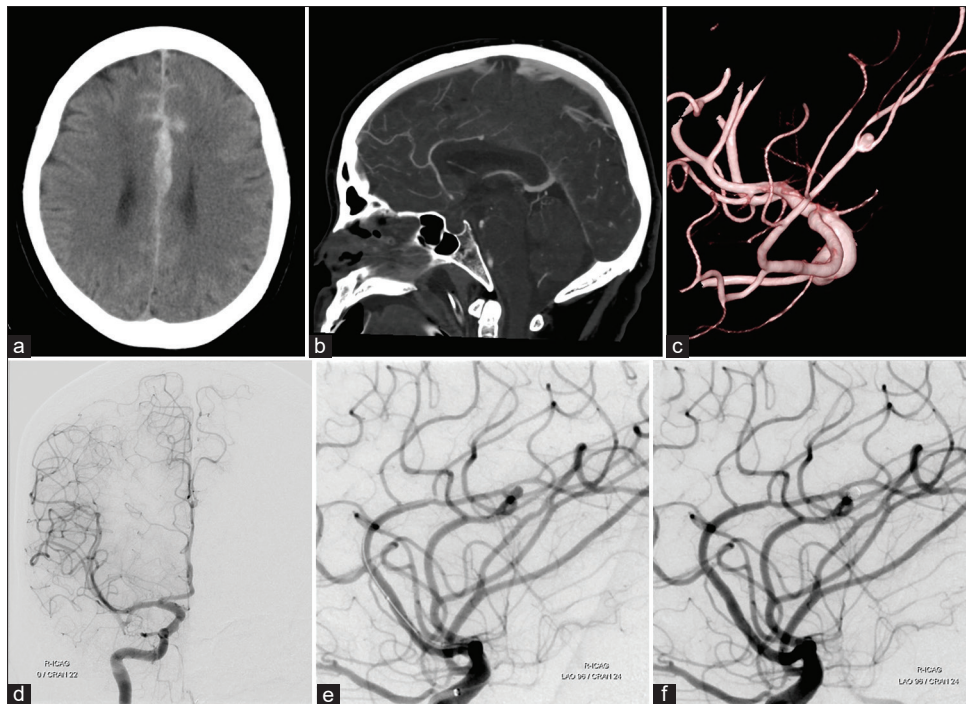


Figure 1: (a) Plain computed tomography (CT) of the brain revealed a subarachnoid hemorrhage and hematoma in the interhemispheric fissure. (b and c) CT angiography of sagittal view (b) and 3D digital subtraction angiography (c) showed an aneurysm at the A4–A5 junction. (d and e) Right internal cerebral artery angiogram showed a bihemispheric type anterior cerebral artery and a saccular aneurysm. (f) Postoperative angiogram showed complete obliteration of the aneurysm.

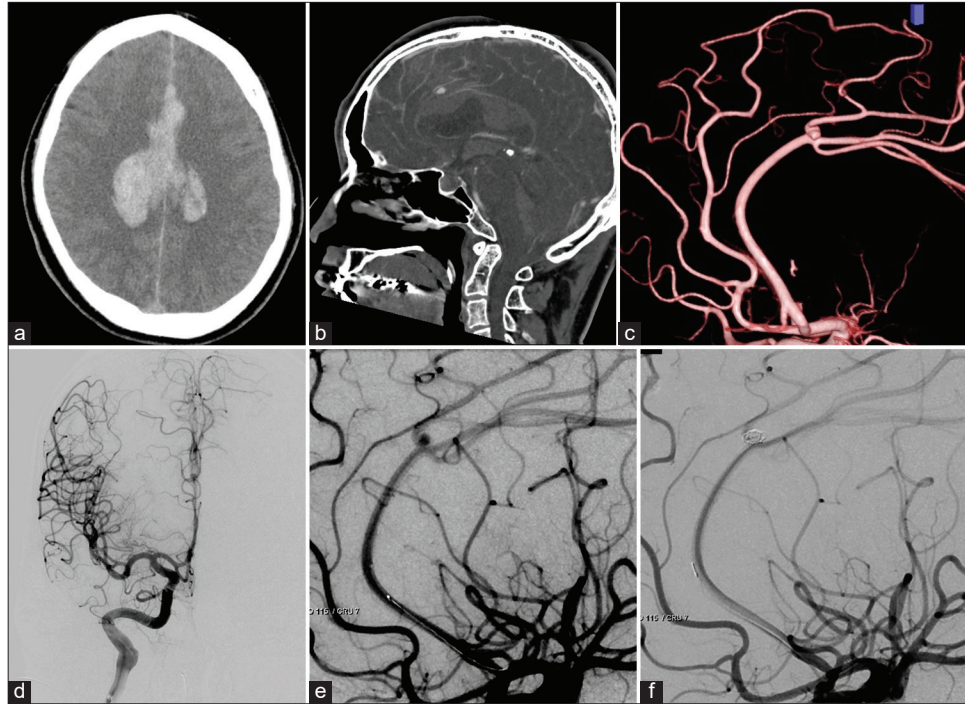


Figure 2: (a) Initial computed tomography (CT) of the brain showed intracerebral hemorrhage and subarachnoid hemorrhage in the cingulate gyrus. (b and c) CT angiography of sagittal view (b) and 3D digital subtraction angiography (c) showed a saccular aneurysm at the A3-A4 junction. (d and e) Right internal cerebral artery angiogram showed an accessory anterior cerebral artery and a saccular aneurysm. (f) Postoperative angiogram showed complete obliteration of the aneurysm.

DISCUSSION

Aneurysms in the A4 and A5 (supra callosal portion) located distal to the genu of the corpus callosum are estimated to account for 0.5% of all aneurysms.^[3-5,9] Previous studies have reported that ruptured DACA aneurysms are more frequently complicated with intracerebral hematomas than aneurysms in other portions, although the rates vary from 17% to 73%.^[1,3,13] Saccular aneurysms located in the distal portion of the genu are more frequently associated with ACA anomalies, such as bihemispheric type ACA or accessory ACA, which are considered to be primarily caused by hemodynamic stress.^[3,6,8,9] As cerebral aneurysms may occur in the same portion following head trauma, it is necessary to confirm any history of trauma.^[12]

In previous reports, almost all aneurysms in the supracallosal portion were treated with aneurysmal neck clipping.^[1,13] Compared with aneurysms in the genu portion, clipping surgery has a shallower operative field and is less likely to cause disorientation. Pericallosal artery aneurysms also tend to be wide-neck aneurysms that involve cortical branches from the dome neck despite their relatively small size.^[6]

Endovascular treatment of ruptured DACA aneurysms is considered preferable for patients with an aneurysm

dome/neck ratio >1.5 , poor or complicated clinical status, and no large hematoma within the intracranial area. In addition, coiling is more favorable than clipping in clinical outcomes and the incidence of treatment-related complications for ruptured DACA aneurysms.^[11] The advantages of endovascular treatment are as follows: Minimally invasive, low risk of intraoperative rupture, and the ability to treat multiple aneurysms in the same session.

During intraoperative rupture, hemostasis near the ruptured aneurysm using a balloon catheter is most effective; however, it is difficult to use for DACA aneurysms due to the small diameter of the mother vessel. Therefore, the use of a balloon-guiding catheter for intraoperative rupture was considered effective for treating DACA aneurysms, which is also used in Case 2. In the case of DACA aneurysms, it is difficult to completely block the blood flow due to cross-blood flow through the anterior communicating artery. However, it is effective in terms of hemostasis and flow control during intraoperative rupture and provides a safe treatment.

By contrast, coil embolization of DACA aneurysms has a higher incidence of recurrence after endovascular therapy than that of other portions. The loose coil packing rate is a factor that leads to recurrence.^[10] In addition, recurrence may

Table 1: Summary of previous reported cases and the present cases.

Case	Age, sex	diagnosis	Dome size	Segment	treatment	Outcome
Morigaki, <i>et al.</i> 2008 ^[7]	72, F	SAH	NR	A5	Coiling followed clipping	GR
Cavalcanti, <i>et al.</i> 2013 ^[2]	69, F	Unruptured	20 mm	A4	Coiling	NR
Zhou, <i>et al.</i> 2019 ^[15]	59, F	SAH	NR	A4	Coiling	NR
Uchino, <i>et al.</i> 2022 ^[14]	53, F	SAH	5.8 mm	A5	Coiling	GR
Present case 1	61, F	SAH	2.9 mm	A5	Coiling	GR
Present case 2	35, M	SAH	5.1 mm	A4	Coiling	GR

F: Female, M: Male, GR: Good recovery, SAH: Subarachnoid hemorrhage, NR: Not recorded

be caused by the high incidence of terminal-type aneurysms and the small diameter of the mother vessel, making it difficult to perform stent-assisted coil embolization.

To date, several cases of coil embolization or parent artery occlusion of a traumatic aneurysm have been reported at the supracallosal portion.^[12] In contrast, there are only four reports of coil embolization of a saccular aneurysm at the same portion, excluding traumatic aneurysms, as far as we could find [Table 1].^[2,7,14,15] All patients had bihemispheric type ACA supplying the bilateral parietal lobe in the distal segment of the aneurysm.

A simple technique is usually selected for coil embolization of aneurysms at the supracallosal portion due to the long approach route and vessel diameter of the parent artery.^[10] In recent years, the flexibility and trackability of DAC have improved, allowing the catheter to be guided to the top of the ICA or A1. However, fine control of microcatheterization remains difficult at distal A3. As coil embolization tends to be dependent on coil characteristics, coil selection is also important. As aneurysms at this portion tend to be small and have a wide neck, it is essential to select a soft helical-type coil or 3D-type coil with loops that do not spread outward. Although the use of a flow diverter has recently been reported in this portion, it is difficult to use in ruptured cases as it does not provide immediate hemostasis. It is also necessary to use a T-connector and 156- or 160-cm long microcatheter to achieve a long effective length. Furthermore, both cases were of relatively young patients without atherosclerosis, which were contributing factors for access. In the future, coil embolization could become the first-choice procedure for aneurysms at the supracallosal portion if DACs can be easily guided to the A1–A2 junction.

CONCLUSION

Coil embolization was performed in two cases of ruptured cerebral aneurysms in the supracallosal portion. Although clipping surgery is usually the selected treatment for ruptured aneurysms in this region, coil embolization can provide excellent results if patient selection is appropriate. We expect that indications for endovascular treatment will be expanded in the future.

Ethical approval

The current study has been performed in accordance with the Declaration of Helsinki. IRB approval number is 23012. Date; September 25th, 2023.

Declaration of patient consent

The authors certify that they have obtained all appropriate patient consent.

Financial support and sponsorship

Nil.

Conflicts of interest

There are no conflicts of interest.

Use of artificial intelligence (AI)-assisted technology for manuscript preparation

The authors confirm that there was no use of artificial intelligence (AI)-assisted technology for assisting in the writing or editing of the manuscript and no images were manipulated using AI.

REFERENCES

1. Carvi y Nieves MN. The influence of configuration and location of ruptured distal cerebral anterior artery aneurysms on their treatment modality and results: Analysis of our casuistry and literature review. *Neurol Res* 2010;32:73-81.
2. Cavalcanti DD, Abla AA, Martirosyan NL, McDougall CG, Spetzler RF, Albuquerque FC. Endovascular management of distal ACA aneurysms: Single-institution clinical experience in 22 consecutive patients and literature review. *AJNR Am J Neuroradiol* 2013;34:1593-9.
3. Hernesniemi J, Tapaninaho A, Vapalahti M, Niskanen M, Kari A, Luukkonen M. Saccular aneurysms of the distal anterior cerebral artery and its branches. *Neurosurgery* 1992;31:994-8.
4. Lehecka M, Dashti R, Hernesniemi J, Niemelä M, Koivisto T, Ronkainen A, *et al.* Microneurosurgical management of aneurysms at A4 and A5 segments and distal cortical branches

- of anterior cerebral artery. *Surg Neurol* 2008;70:352-67.
5. Lehecka M, Porras M, Dashti R, Niemelä M, Hernesniemi JA. Anatomic features of distal anterior cerebral artery aneurysms: A detailed angiographic analysis of 101 patients. *Neurosurgery* 2008;63:219-28.
 6. Matsuzaki K, Uno M, Fujihara T, Miyamoto T, Yokosuka K, Toi H, *et al.* Ruptured distal accessory anterior cerebral artery aneurysm-case report. *Neurol Med Chir (Tokyo)* 2011;51:839-42.
 7. Morigaki R, Uno M, Matsubara S, Satoh K, Nagahiro S. Choreoathetosis due to rupture of a distal accessory anterior cerebral artery aneurysm. *Cerebrovasc Dis* 2008;25:285-7.
 8. Morioka M, Fujioka S, Itoyama Y, Ushio Y. Ruptured distal accessory anterior cerebral artery aneurysm: Case report. *Neurosurgery* 1997;40:399-401.
 9. Ohno K, Monma S, Suzuki R, Masaoka H, Matsushima Y, Hirakawa K. Saccular aneurysms of the distal anterior cerebral artery. *Neurosurgery* 1990;27:907-12.
 10. Park HS, Kwon SC, Kim MH, Park ES, Sim HB, Lyo IU. Endovascular coil embolization of distal anterior cerebral artery aneurysms: Angiographic and clinical follow-up results. *Neurointervention* 2013;8:87-91.
 11. Park KY, Kim BM, Lim YC, Chung J, Kim DJ, Joo JY, *et al.* The role of endovascular treatment for ruptured distal anterior cerebral artery aneurysms: Comparison with microsurgical clipping. *J Neuroimaging* 2015;25:81-6.
 12. Sui M, Mei Q, Sun K. Surgical treatment achieves better outcome in severe traumatic pericallosal aneurysm: Case report and literature review. *Int J Clin Exp Med* 2015;8:1598-603.
 13. Take Y, Kamide T, Kikkawa Y, Ikegami M, Teranishi A, Ehara T, *et al.* Current treatment options and prognostic factors for ruptured distal anterior cerebral artery aneurysms. *Surg Neurol Int* 2021;12:171.
 14. Uchino K, Kondo K, Harada N, Aoki Y, Noguchi Y, Oishi H, *et al.* A case of a ruptured aneurysm at the supracallosal portion (A4-A5) of the bihemispheric anterior cerebral artery treated with endovascular surgery. *J Neuroendovasc Ther* 2022;16:147-51.
 15. Zhou J, Wang Y, Wang D, Chen Q, Wang H, Gao L. Endovascular treatment for ruptured aneurysms at distal cerebral arteries. *World Neurosurg* 2019;123:e387-92.

How to cite this article: Tsuji Y, Kuroda Y, Wanibuchi M. Coil embolization for ruptured distal anterior cerebral artery aneurysm at the supracallosal portion: Two case reports. *Surg Neurol Int.* 2023;14:444. doi: 10.25259/SNI_810_2023

Disclaimer

The views and opinions expressed in this article are those of the authors and do not necessarily reflect the official policy or position of the Journal or its management. The information contained in this article should not be considered to be medical advice; patients should consult their own physicians for advice as to their specific medical needs.