

Recent surgical options for vestibular vertigo

Abstract

Vertigo is not a well-defined disease but a symptom that can occur in heterogeneous entities diagnosed and treated mainly by otolaryngologists, neurologists, internal medicine, and primary care physicians. Most vertigo syndromes have a good prognosis and management is predominantly conservative, whereas the need for surgical therapy is rare, but for a subset of patients often the only remaining option. In this paper, we describe and discuss different surgical therapy options for hydropic inner ear diseases, Menière's disease, dehiscence syndromes, perilymph fistulas, and benign paroxysmal positional vertigo. At the end, we shortly introduce the most recent developments in regard to vestibular implants. Surgical therapy is still indicated for vestibular disease in selected patients nowadays when conservative options did not reduce symptoms and patients are still suffering. Success depends on the correct diagnosis and choosing among different procedures the ones going along with an adequate patient selection. With regard to the invasiveness and the possible risks due to surgery, in depth individual counseling is absolutely necessary. Ablative and destructive surgical procedures usually achieve a successful vertigo control, but are associated with a high risk for hearing loss. Therefore, residual hearing has to be included in the decision making process for surgical therapy.

Keywords: peripheral vestibular vertigo, surgical treatment, Menière's disease, dehiscence syndrome, endolymphatic sac surgery, vestibular implants

1 Introduction

The surgical treatment of different diseases of the peripheral vestibular system is one of the most controversially discussed topics within the otolaryngological scientific society as well as with neighbouring disciplines. According to the current literature, a surgical intervention is indicated in slightly more than 1% of the patients at hospitals specialized for vertigo [1]. In selected disease such as MM about 20% of the patients may need surgical therapy in the course of the disease [2], [3], [4], [5]. Retrospectively, certain interventions or diseases are particularly in the focus of the discussion. In the 1960ies and 1970ies the "spontaneous perilymph fistula" was mainly in the USA controversially discussed, in the 1980ies, it was the surgery of the endolymphatic sac, and since 2000, it is the dehiscence syndrome of the superior semicircular canal. The available literature for studies of distinct surgical procedures is often very heterogeneous. Because of this the surgery of the endolymphatic sac and also the selective transection of the vestibular nerve are defined as obsolete in the (not yet revised) guidelines on "vertigo" of the German Society of Neurology and by other authors of the neurological discipline [6], [7]. Beside a certain diagnostic vagueness of some of the diseases that will be discussed in the following, another reason might possibly be the heterogeneity of the investigated and compared patient groups and

the not clearly defined success rates of the respective procedures in single trials (e.g. improvement vs. complete elimination of the symptoms). A Cochrane review is only available for saccus surgery and this is based on the results of 2 studies with only 59 patients [8], [9]. Observational trials with many thousands of operated patients were not included because they did not meet the strict quality criteria of the Cochrane Collaboration. For all other surgical therapy modalities, there is a lack of randomized placebo-controlled studies.

The development of additional functional diagnostic procedures in neuro-otology over the last decades allows a more exact diagnosis and differentiation of distinct diseases [10] and is associated with a revised indication for surgical interventions for diseases of the peripheral vestibular system raising hope for a more targeted application of invasive and partly destructive therapeutic modalities [11].

Since the diagnostics of the peripheral vestibular system is the topic of another contribution, it will not be in the focus here. Due to the restricted capacity of this booklet, the etiology of each disease will only be described when it is highly relevant for therapy. In the following, the development of the surgical procedures will be summarized for each entity and discussed based on current trials in order to be able to give a recommendation as a possible therapeutic option after failure of alternative procedures.

Stefan Volkenstein¹

Stefan Dazert¹

¹ Department of Otolaryngology, Head & Neck Surgery, Ruhr-University of Bochum at the St. Elisabeth Hospital of Bochum, Germany

2 Hydropic inner ear diseases – Menière’s disease and Menière’s syndrome

2.1 Overview and terminology

The paroxysmal occurrence of the classic symptom triad of rotational vertigo, fluctuating hearing ability, and tinnitus is called Menière’s disease or Morbus Menière (MM) according to Prosper Menière (1861) [12]. Later, further symptoms (sense of pressure/fullness in the ear, nausea and vomiting, falls etc.) were described in the context of this inner ear or labyrinthine disease. Already in 1938, 2 teams succeeded independent from each other in allotting the endolymphatic hydrops (ELH) as pathological correlate for this disease [13], [14]. Since then, there are several disease entities with a manifold and partly confusing terminology that are associated with ELH: cochlear and vestibular Menière’s disease, mono-symptomatic Menière’s disease etc. [4], [15], [16], [17]. Even if ELH is known to be the cause for the symptoms of MM for a long time, guidelines still recommend diagnosis based on medical history, audiometry, and the principle of exclusion diagnostics [17], [18], [19], [20], [21], [22]. In the future, the possibility of visualization of ELH by means of magnet resonance imaging in living patients [23] will contribute to easier exclude other diseases such as for example vestibular migraine that appears with similar symptoms [24]. This development contributes to an improved and more specific diagnosis of hydropic inner ear diseases and will probably lead to a revision of the mentioned clinical and audiological diagnostic criteria [25]. According to the most recent classification, the term of hydropic inner ear diseases summarizes different diseases that have an endolymphatic hydrops as morphological correlate. They are subdivided into primary and secondary hydropic inner ear diseases [26]. In some articles, the term of Menière’s syndrome is used. In the context of Menière’s syndrome, the symptoms appear secondarily because of a known primary disease, e.g. a pressure dysequilibrium in the middle ear due to Eustachian tube dysfunction or pathologies of the ossicular chain may influence the inner ear pressure [27] or tumors and inflammatory diseases may cause the ELH [17], [28]. In contrast to Menière’s syndrome, the ELH in MM develops idiopathically because of absorption disorders and/or deregulated production of endolymph fluid without known pathologies that lead to a pathologically changed endolymph homeostasis [13], [29].

2.2 Surgical procedures

Therapy of MM is primarily conservative and different gradual schemes are available that may be applied depending on the progress of the disease and the residual hearing ability [4], [30], [31], [32] (Figure 1). After failure of conservative therapeutic approaches, partly even despite application of off-label pharmaceuticals, repeatedly

verification of the diagnosis, and persisting symptom attacks indicate surgical therapy when the disease can be clearly assigned to one side. The indication prevalence for surgical interventions is different in the course of the disease and varies between 1 and 25% of the patients suffering from MM [2], [3], [6], [33], [34], [35], while the percentage is decreasing since the administration of intratympanic corticosteroids and gentamicin becomes more popular as well [36]. Not only in the context of treating patients with MM, but in general, evidence plays an increasing role in the medical field. Meanwhile the number of randomized, placebo-controlled trials has tripled during the last two decades (from 1994 to 2013) with an increasing attention that is paid to standardized assessment of the quality of life as additional evaluation criterion for the success of a therapy [36]. Regarding the surgical procedures, there are function preserving and destructive options (Figure 2) that can be performed with or without hearing preservation. In the following, these options will be described in more detail.

2.2.1 Function preserving procedures

2.2.1.1 Middle ear drainage

After Tumorin had promoted tympanostomy tubes as possible therapeutic option for patients with MM in 1966 [37], a series of experimental and clinical investigations was performed in the following years that justified this procedure and in particular showed an improvement of the vestibular symptoms by tympanostomy tube insertion [38], [39], [40], [41], [42], [43]. The hearing ability was not changed significantly [44]. In the 1970ies and also later, critics rejected this method as being useless with the argument that not all MM patients suffered from Eustachian tube dysfunction [45], [46], [47]. Even when an investigation performed in 1988 by Montandon et al. [39] finally confirmed the positive results of earlier, not really systematic publications on this topic, there are still doubts regarding the benefit and the usefulness of tympanostomy tubes for MM. The major part of the effect is interpreted as placebo effect by several people and it was not possible to identify a clinical correlation between cochleo-vestibular disorders and tube dysfunctions [15], [48]. Thomsen et al. compared the results after tympanostomy tube insertion and after saccus decompression/sac-cotomy and could not confirm significant differences between both therapy methods, however, a reduction of the vertigo attacks after both interventions was observed so that in conclusion the less invasive tympanostomy tube insertion was suggested as first option after failure of pharmaceutical/conservative therapy [49]. Since it could be shown that pressure changes in the middle ear may lead to pressure changes in the inner ear, the influence on the symptoms of MM was explained by this fact in the following [43], [50]. Furthermore, Kimura and Hutta could show in an animal model that pressure changes in the middle ear could significantly influence an experimentally induced ELH [42]. Park et al. investigated the functional

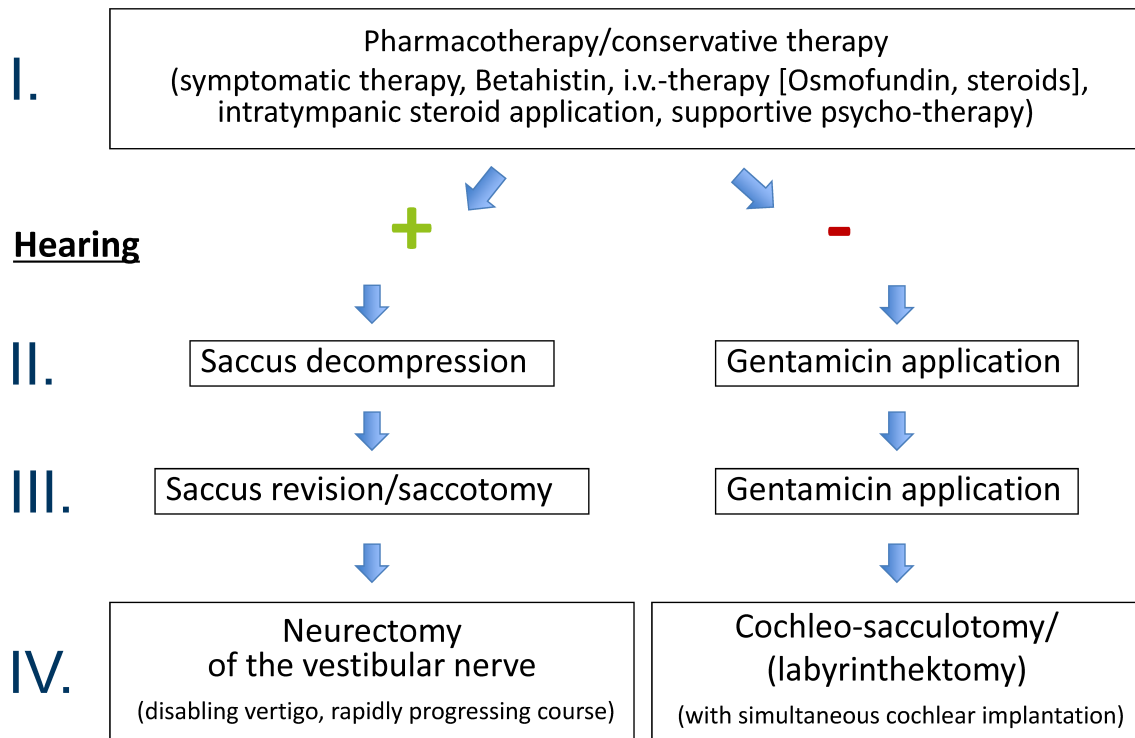


Figure 1: Bochum step-wise therapeutic scheme for patients with Menière's disease

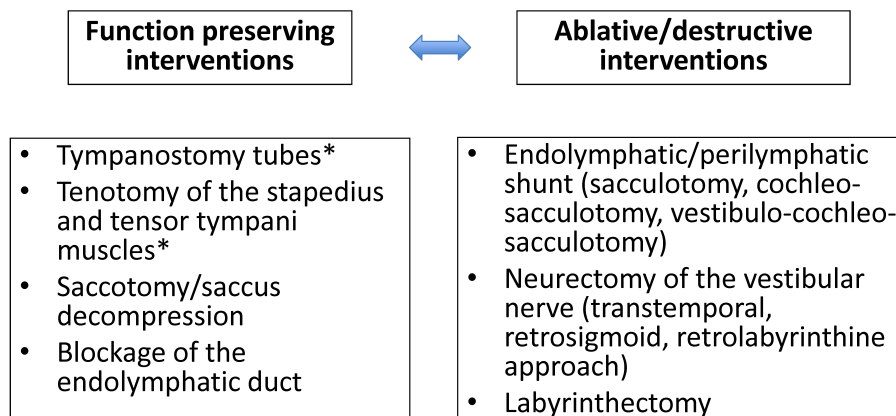


Figure 2: Surgical treatment procedures for patients with hydropic inner ear disease

(* especially patients with Menière's syndrome and pathological pressure conditions in the middle ear)

impact resulting from the insertion of tympanostomy tubes on the vestibular system and limited their trial to patients with MM who had a tube dysfunction (middle ear pressure <-50 daPa) [43]. Tympanostomy tubes did not lead to relevant complications and in 68.2% of the patients, the symptoms improved after tympanostomy tube insertion, however, without postoperative change of the sacculus or lateral semicircular canal function. The mechanisms that are responsible for the improvement of the complaints remain still unclear. It is important to select appropriate patients who might benefit from this therapy [28]. In this context, patients who have tube dysfunction with pathological middle ear pressure are recommended for tympanostomy tube insertion in selected cases [43]. The fact that some studies could not confirm the positive effects that are achieved by tym-

panostomy tubes, is possibly also based on the selection of inappropriate patients for this type of therapy [43]. Apparently there are patients who do not experience improvement after tympanostomy tube insertion [40], [44], [51]. Interestingly, some patients who benefited from tympanostomy tubes, had again vertigo attacks after extrusion of the tubes [39], [44] that disappeared again after tube re-insertion.

The tympanostomy tube insertion can be suggested for MM, especially in elderly patients, as early therapeutic option for a selected group of patients (e.g. with tube dysfunction) before applying an invasive or even destructive therapy procedure [44].

2.2.1.2 Tenotomy of the tendons of the stapedius and the tensor tympani muscles

Tenotomy of the tendons of the tensor tympani muscle and/or the stapedius muscle are considered as possible function preserving therapy options in patients with MM that might positively influence the audiological symptoms beside the vestibular ones [27], [52]. This method that is mainly applied in Austria consists of transecting the tendons of both middle ear muscles to influence the pressure coupling of the ossicular chain to the perilymphatic space [27]. Beside the reduction of the incidence of vertigo attacks and their intensity, case series of 30 and 45 patients showed an improvement of the audiometric results, especially in the frequency range between 500 Hz and 3 kHz [52], [53]. In a subsequent investigation of 42 patients with a follow-up time of up to 9 years, Loader et al. reported a significant reduction of the dizziness handicap inventory (DHI), a questionnaire on the subjective self-assessment of the impairment by vertigo complaints. It could also be shown that the therapeutic success was higher, the more severe the preoperative impairment was estimated [54].

In a retrospective study, Albu et al. investigated the results between tenotomy and endolymphatic mastoid shunt surgery in a homogeneous patient group [55]. While there were no differences regarding tinnitus, the symptom control of fullness sensation, vestibular symptoms, and especially hearing ability were significantly better in the group of patients with tenotomy; additionally 25% of the patients had to undergo revision after shunt surgery.

In a comparative study between an intratympanic gentamicin therapy alone and in combination with the described tenotomy, it could be revealed that there is no additional benefit after tenotomy regarding the quality of life, DHI, tinnitus, or the incidence of the severity of vertigo attacks [56].

All trials have been performed in patients who suffered from definitive unilateral MM according to the AAO-HNS criteria. Equally to the tympanostomy tube insertion attention must be paid to the appropriate patient selection (see above) in order to achieve maybe even better results in the future [27].

2.2.1.3 Saccotomy/sacculus decompression

Even if decompression of the endolymphatic sac was the most frequently performed surgical intervention for MM for a long time [57], and is at least still in the USA today [58], surgery involving those anatomical structures remain the most controversially discussed procedures [27], [59], [60]. In 1927, Portmann was the first to describe an intervention of the endolymphatic sac for treatment of vertigo [61]. Since then several interventions at the endolymphatic sac were reported [57], [62], [63], [64], [65], [66], [67]: only decompression of the endolymphatic sac, only incision (called saccotomy or endolymphatic shunt surgery), and the incision with insertion of silicone or Teflon sheets [68], [69]. Yokuta et al. suggest in addition

to saccotomy the intraoperative administration of corticosteroids directly into the endolymphatic sac [5]. Other procedures such as shunt surgery between the endolymphatic sac and the subarachnoidal space [70] could not prevail. Despite the success rates of sacculus surgery mentioned in the literature amounting to 60–90% [57], [67], [71], [72], [73], [74], [75], [76], [77], [78], [79], [80], these interventions are partly suspected to have unspecific or placebo effects [8], [9], [49], [81], [82], [83]. Interestingly, a post-mortem study of patients having undergone interventions at the endolymphatic sac could not reveal a clear correlation between the complaints and the surgical outcome so that some patients had experienced improvement of the complaints even if the target structure had not been reached in the context of surgery. Other patients who definitely had surgery of the endolymphatic sac, did not show an improvement of the preoperative stage [84].

The interventions at the endolymphatic sac were especially in the focus of the critics because of an article published by Thomsen et al. in 1981. In this large randomized, placebo-controlled trial, no difference could be confirmed between saccotomy and mastoidectomy without exposition of the endolymphatic sac [82]. Follow-up studies to this publication were added after 3 and after 9 years [85], [86] which allow similar conclusions, i.e. that there is no difference between the actual (saccotomy) and the placebo intervention. Since the publication of the original paper in 1981, there are doubts if the conclusions of the presented data were justified [87], [88]. In 1983, Pilsbury investigated the data again and revealed a significantly better vertigo control by saccotomy in contrast to placebo surgery [89]. Welling analyzed the original data of the study of 1981 again and demonstrated that there is a statistically significant improvement in the saccotomy group with regard to specific aspects (especially vertigo, tinnitus etc.) [90]. A Cochrane review of 2010 about the surgical options for patients with MM was again the topic of further discussions around sacculus surgery, also in its revised version of 2013, because no sufficient evidence for the benefit of sacculus surgery in patients with MM could be supported by valid data as their conclusion [8], [9]. Due to the strict inclusion criteria, the assessment is based on only 2 articles with a total of 59 patients. The already mentioned 9-years follow-up by Bretlau et al. regarding the study of Thomsen (1981) and another study from the same group comparing saccotomy with the results of tympanostomy tube insertion as placebo intervention in a non-blinded, randomized study [49]. In both trials no statistically significant difference in the response rate of saccotomy and the placebo intervention could be revealed although the overall symptoms improved in about 70% of the patients. This was considered as unspecific effect of all surgical interventions. Other studies that were performed in a relevantly larger patient population, but lacked the criteria of the Cochrane Collaboration, were ignored by the critics. In 1988, Monsell et al. reported about a study of 83 patients with a success rate of 75% [91]. In 2002, Paparella

and Fina published a series of more than 2000 interventions at the endolymphatic sac and achieved a complete control of the vertigo symptoms in 75% and an improvement in 90% of the treated patients with a hearing preservation rate of 98% [92]. The authors emphasized particularly their surgical technique including a complete mastoidectomy with broad decompression of the sigmoid sinus. Recurrent symptoms after improvement of the complaints occurred in 5% of the cases, typically 3–4 years after the first intervention. Huang reported about his summarized experiences with saccus surgery in 3000 cases and a success rate regarding vertigo symptoms of more than 90% after 2–3 years [93]. Lee et al. reported about satisfactory vertigo control in 78% of the patients in a series of 486 saccotomy interventions [94].

In 2014, Sood et al. compared the different interventions at the endolymphatic sac in a systematic review and meta-analysis [95]. The literature review addressed the problem with definition of the success rate of the different articles which made a comparison rather difficult. Although continuously revised guidelines exist [18], [19], [20], [21], they were not correctly applied in many of the cases [95]. Nearly 80% of the authors stated that they worked based on those guidelines, only half of them actually applied them correctly [96]. After evaluation of 36 trials, the conclusion could be drawn that control of the vertigo symptoms could be achieved in 75% of the patients after 12 months and after 2 years without a significant difference between saccus decompression and saccotomy/shunt surgery with regard to hearing preservation and control of the vertigo symptoms. Only the evaluation of the patients with saccotomy who underwent insertion of a silicone sheet or something similar, had a significantly poorer hearing preservation, but no difference regarding the vertigo symptoms was observed so that the usefulness of sheet insertion is in doubt due to the missing benefit [95].

Yokota et al. reported about 263 patients who had the indication of saccotomy, but 56 decided against this intervention and received the best possible pharmaceutical/conservative therapy [5]. After 2 years success rates of 92.8% compared to 46.4% in the conservative group were reported. After 7 years, the success rate was 81.0% in the surgical group compared to 30% in the control group. Additionally, it could be shown that patients with a concomitant neurosis or depression had significantly lower success rates after surgical therapy than patients without those concomitant diseases. One of the conclusions is the recommendation to perform supportive psychological therapy in order to further improve the surgical outcome as well as the conservative results.

If an intervention at the endolymphatic sac was successful at first (at least one year of improved symptoms) [4] and if then recurrent symptoms develop, saccus revision surgery leads to successful reduction of symptoms in 80–90% of the cases [97], [98]. Intraoperatively, connective or granulation tissue is regularly found as well as newly

formed bone around the area of the endolymphatic sac [99].

Among all surgical therapies that are mentioned in the context of MM, the best results regarding hearing preservation are achieved with interventions at the endolymphatic sac [100], [101] so that this kind of surgery can also be recommended for patients suffering from bilateral MM with success rates regarding vertigo control which can be compared to the one of unilaterally affected patients [102]. Beside a significant improvement of the specific symptoms, the quality of life can be significantly improved by interventions at the endolymphatic sac [101]. Before such an intervention, imaging should exclude a large vestibular aqueduct or tumors of the endolymphatic sac. Even patients older than 65 years do not have a higher perioperative morbidity for endolymphatic sac surgery [103] with a very low overall invasiveness so that saccus decompression is promoted from step III to II in our gradual scheme before gentamicin therapy in cases of usable hearing ability (Figure 1). In all endolymphatic sac surgeries, the intraoperative application of corticosteroids is recommended for hearing preservation [27].

2.2.1.4 Blockage of the endolymphatic duct

Saliba et al. described in 2015 a new, non-destructive surgical technique for treatment of MM where they perform a blockage of the endolymphatic duct. They compared this technique with endolymphatic sac decompression surgery in a prospective, non-blinded randomized trial [104]. After complete decompression of the endolymphatic sac, this intervention consists of exposing the endolymphatic duct medial to the saccus and ligating it with 2 titanium clips. In this way, the endolymphatic sac is isolated and the endolymph fluid in the inner ear is reduced so that the imbalance of the endolymph production and absorption is balanced by the blockage of the suspected overproduction of endolymph fluid in the saccus [105].

In the context of this study, 35 patients underwent blockage of the endolymphatic duct and 22 only saccus decompression. The postoperative results were assessed 1 week as well as 6, 12, 18, and 24 months afterwards. The recurrence of vertigo in the blockage group amounted to 3.5% after 6 and 24 months (1 patient), for the patients who had undergone decompression, it amounted to 80% after 6 months and 66% after 24 months. The symptoms of tinnitus and pressure sensation were significantly better in the blockage group after 24 months compared to the control group. With regard to the audiological results, there was no difference between both groups. In 14% of the patients who had undergone blockage of the endolymphatic duct, outflow of cerebrospinal fluid occurred intraoperatively during preparation of the dura, 11 of 35 patients presented the postoperative symptom of BPPV of the posterior semicircular canal; further important complications were not observed in neither of the groups. According to the study of Saliba et al., the new procedure of blocking the endolymphatic duct is clearly

superior to saccus decompression, especially in terms of controlling vertigo symptoms. However, it is eye-catching that rather poor results are reported about patients who had undergone decompression (see also 2.2.1.3) with a recurrence rate of the vertigo symptoms in 80% after only 6 months. It also remains open why this study was not conducted in the (double) blind way in order to increase the scientific quality [106].

In summary, the endolymphatic duct blockage seems to be an interesting surgical technique that shows good vertigo control as well as a significantly increased quality of life after surgery [60]. However, in comparison to decompression of the endolymphatic sac, it is clearly more challenging regarding the performance and it is associated with a higher risk of intraoperative liquor leakage with similar results regarding vertigo control in comparison to the literature.

2.2.2 Ablative and destructive procedures

Preliminary remarks: Among the non-surgical but ablative therapeutic procedures also the intratympanic gentamicin therapy must be mentioned with the risk of severe hearing loss as undesired side effect in some patients, independent from the duration or type of administration [107], however, it will not be in the focus of the following paragraphs.

2.2.2.1 Endolymphatic/perilymphatic shunt: sacculotomy/cochleo-sacculotomy/vestibulo-cochleo sacculotomy

In the 1960ies, a procedure was described that should lead to relief of the ELH by a perilymphatic/endolymphatic shunt [108], [109], [110], [111]. It was applied in patients with therapy-resistant vertigo after failure of alternative therapeutic options. The sacculus is punctured through the stapes footplate (according to Fick [109]) or through the round window membrane (according to Schuknecht [112]) and thus a permanent shunt is created, with accompanying destruction of the labyrinth and cochlear function. Earlier reports about the possibility to perform this intervention with just a low risk of postoperative hearing deterioration [111], [112] were probably partly due to the patient selection because further deterioration cannot be measured in cases of preoperative functional deafness or profound hearing loss [27]. In later studies conducted in patients with measurable residual hearing, those results could not be confirmed [113], [114]. Giddings et al. reported about sobering results after cochleo-sacculotomy with a significant hearing loss in 80% of the patients and recurrent vertigo attacks in an average follow-up period of 17 months in 4 of 11 patients so that again a destructive intervention had to be performed [114]. Wielinga et al. suggest sacculotomy and Kinney et al. recommend cochleo-sacculotomy because of the easy and less invasive surgery method especially for older patients as alternative to a labyrinthectomy. They describe a very good vertigo control, however, with

significant hearing loss in nearly all patients [115], [116]. In a study that compares cochleo-sacculotomy and saccus decompression a significantly better vertigo control is reported in patients after cochleo-sacculotomy with significant hearing deterioration [117]. In this study, a selection bias was observed since the patients with preoperative impaired hearing rather undergo cochleo-sacculotomy instead of saccus decompression. Especially for older patients without usable residual hearing ability such a surgery with its low invasiveness may be indicated [118]. Cochleo-sacculotomy performed at the same time as cochlear implantation may be discussed for deaf MM patients with persisting vertigo symptoms. This procedure was described by Westhofen who reports very good results [27].

2.2.2.2 Neurectomy of the vestibular nerve

In the 20th century, a fluctuating interest could be observed regarding the performance of neurectomies of the VIIIth cranial nerve [119]. The early neurectomies performed already at the end of the 19th and at the beginning of the 20th century for the treatment of vertigo consisted of complete transection of the nerve via different access routes [119], [120]. Later, Dandy and McKenzie described the selective neurectomy of the vestibular nerve via a suboccipital approach aiming to separate the vestibular organ from the brain and thus achieve vertigo control [121], [122], [123]. After this, House renewed the interest in this surgery by introducing microsurgery via a transtemporal approach through the middle fossa [124]. Fisch modified this access route [125] and reported in a series of 100 cases that no patient at all had significant postoperative hearing loss [126]. Further modifications of the surgical technique and the approach were performed by Silverstein (retrolabyrinthine approach [127]) and Bremond (retrosigmoid approach [128], [129]). Silverstein reported about a combination of both approaches that vertigo attacks stopped completely in 85% of the cases and improved in further 7% with a significant hearing loss in only 4% [130]. Independent from the access, success rates of more than 90% are mentioned with meanwhile significantly lower mortality and reduced complication rates in comparison to interventions at the beginning of the 20th century [131], [132], [133], [134], [135].

In a comparative study, Colletti et al. report about 209 patients who underwent neurectomy and 24 patients who received intratympanic gentamicin therapy (also called chemical labyrinthectomy). They found a vertigo control of 95.8% in the neurectomy group in comparison to 75% in the gentamicin group. The speech discrimination in the neurectomy group was reduced from 85 to 82% and in the gentamicin group from 87 to 65%. The gentamicin therapy is not a surgical intervention, however, it should be considered to be a destructive procedure. Patients have to be counseled about the relevant risk of hearing loss [3], [4]. In the early postoperative phase, neurectomy does not cause a relevant hearing deterioration in the vast majority of the cases. Comparing the long-term re-

sults of patient groups who had either undergone neurectomy or saccotomy or who were offered a surgical intervention that was refused, it becomes obvious, independent from the type of intervention, that in cases of poor hearing the situation is stabilized and that in cases of good preoperative hearing ability it deteriorates, which corresponds to the natural course of the disease in the group without surgical intervention [136]. Albera et al. report that meanwhile about 80% of patients with an indication of ablative therapy receive intratympanic gentamicin, the others are treated with neurectomy [35]. After neurectomy, insufficient vertigo control is reported to be about 5% and up to 20% in patients after gentamicin treatment [137].

The simultaneous [138] or sequential [139] combination of neurectomy with an endolymphatic sac surgery did not show advantages regarding vertigo control or hearing preservation compared to neurectomy of the vestibular nerve alone.

Setty et al. described a merely endoscopic retrosigmoid procedure and reported about improvement or completely stopped vertigo symptoms in more than 92% of 41 patients with a hearing preservation of 82.9% as well as a minimal craniotomy without retraction of the cerebellum [140].

Annotation: In the vast majority of the publications, neurectomy is reported although neurotomy is performed. Beside transection of the nerve fibers, neurectomy also includes an extirpation of Scarpa's ganglion [59].

2.2.2.3 Labyrinthectomy

For a long time, surgical labyrinthectomy has been considered as gold standard of surgical treatment for patients with therapy refractory MM when they did not have usable residual hearing or after failure of function-preserving surgical interventions [4], [141], [142] in which the residual hearing was sacrificed. Since Lake had described the first labyrinthectomy in 1904 [143], it took nearly to the middle of the 20th century until labyrinthectomy could be established as less invasive alternative in comparison to neurectomy of the vestibular nerve [144], [145]. In further publications until nowadays, the surgical techniques reach from opening one semicircular canal and resecting the endolymphatic duct to the opening of all semicircular canals as well as the vestibulum with resection of the complete neuroepithelium, partly combined with the resection of Scarpa's ganglion [146]. A comparison between labyrinthectomy and neurectomy as well as a combination of both does not show any superiority of one of the methods regarding vertigo control [147], [148], [149]. Especially for older patients, labyrinthectomy represents an alternative [150], [151], hereby the transmastoid approach should be preferred to the transmeatal access because of better vertigo control [151]. For a long time, the history of a labyrinthectomy was considered as relative contraindication for CI of MM patients despite the clear audiological criteria for this kind of hearing rehabilitation [152]. Temporal bone studies could not confirm

the expected ossification and fibrosis of the cochlea after labyrinthectomy to the extent where an electrode could not be inserted in the scala tympani [153], [154]. Furthermore, MRI examinations of 18 patients with a condition after transmastoid labyrinthectomy revealed even 3 years after surgery a bilaterally equal T2-weighted signal intensity in the cochlea as hint for missing fibrosis or even ossification [142]. In contrast to this, fibrosis or ossification with the loss of the fluid signal in MRI examinations can be detected in one third of the patients who undergo a translabyrinthine access to the internal auditory meatus because of vestibular schwannoma. In those cases, the simultaneous cochlear implantation or for sequential surgery a previous dummy insertion is recommended [155]. For "simple" labyrinthectomy, this does not seem to be necessary. Deafness of MM patients caused by the disease itself is relatively rare [156]. In most of the cases, it is a consequence of different therapeutic methods so that enough spiral ganglia neurons for electrical stimulation should be available in the affected patients [153]. MM patients sometimes have even better results than other CI users [157]. More recent reports show very good results for labyrinthectomy simultaneously performed with cochlear implantation as well as for cochlear implantation performed sometime after labyrinthectomy (interval up to 21 years), so that CI can be recommended also in the patient group in cases of unilateral and bilateral affection [152], [158], [159], [160], [161].

Residual or recurrent symptoms regarding vertigo complaints are observed in up to 40% of patients after labyrinthectomy which is often explained by an incomplete destruction of the sensory epithelium and remaining circuits between the 1st and 2nd neuron of the vestibular pathway so that a resection of Scarpa's ganglion should be performed [15].

Destructive surgical therapy modalities show the best success rates, however, there is a high risk for the complete loss of any existing residual hearing [162]. For ablative therapy procedures (labyrinthectomy and neurectomy) are success rates regarding vertigo control of 85–95% reported [4], [33], [163], [164]. In a study comparing both methods, no difference could be found with regard to the control of the vertigo attacks, however, a slight advantage regarding the postoperative instability sensation was found in the group of neurectomized patients [165]. This is very important for counseling towards or against an ablative intervention, but the estimation of the individual central compensatory possibilities have to be considered as well, especially because the respective patients get older and older [10]. Especially before considering destructive procedures, the risk of developing a bilateral MM must be discussed with the patient. Data in the literature are varying, the occurrence of Menière's symptoms on the second side is reported in up to 78% of the cases [166], [167], [168], [169]. Whether the performance of function-preserving surgical procedures may delay or even avoid the occurrence of ELH or according symptoms, is still controversially discussed [102], [170].

Today, ablative surgical procedures are mainly justified after failed intratympanic gentamicin therapy [171].

Silverstein et al. compared the long-term course of Menière's symptoms in a group of patients who had received surgical therapy (shunt surgery of the saccus or neurectomy) with the results of a group who had the recommendation of surgical therapy but refused [33]. It became obvious that in the non-surgery group after an average of 8.3 years no more vertigo attacks occurred in more than 70%. This has to be considered in the context of analyzing long-term results, but should not be given as justification to deny affected patients an early/direct success by surgical intervention. In order to reduce the influence of the natural course of the disease on the results that are due to a surgical intervention rather the one- and two-year success rates play a key role for the evaluation of different procedures [67].

Since the development of ELH is mostly multifactorial and probably rarely due to only one origin, no therapy method must be expected to be the standard for all patients. Moreover, different patient groups must be assessed systematically in a differentiated way regarding therapy success/failure [51]. In this way, future prognostic factors may be retrieved for the each method.

3 Dehiscence syndromes

The dehiscence of the bone above the superior semicircular canal as cause of vertigo, oscillopsia, and specific types of nystagmus, sometimes accompanied by conductive hearing loss, pulsatile tinnitus, or autophonia as reaction on loud noise, intracranial pressure increase, or increased pressure in the middle ear, was first described by Minor in 1998 [172], [173]. The description of those pathological mechanisms is controversially discussed since then, including the whole disease as well as the diagnostic and the indication for surgical therapy [27]. The dehiscence syndrome of the superior semicircular canal was described shortly afterwards with the therapeutic recommendation of occlusion or resurfacing of the superior semicircular canal, both with an access through the middle fossa, based on the experience with 5 patients [174]. The pathophysiological explanation of dehiscence syndromes refers to 2 already known phenomena: the Tullio phenomenon (vertigo and nystagmus symptoms caused by noise [175], [176], [177]) and the Hennebert's sign (syn: fistula sign; vertigo caused by pressure increase [178]). Meanwhile, also dehiscence syndromes have been described for the posterior and lateral semicircular canals as well as synchronous dehiscences of different semicircular canals [179], [180], [181], [182], [183]. The dehiscence of the lateral semicircular canal mostly occurs in relation with chronic otitis media (cholesteatoma) and is discussed in chapter 4 as labyrinth fistula. The theory of a mobile third window may well explain the different symptoms that many patients with semicircular canal dehiscence complain about [172], [184], [185], [186], [187], [188], [189]. Furthermore, animal models could

well show the audiological consequences of the third window [190], [191], [192]. Critics of the dehiscence syndrome theory argue that in an investigation only slightly more than half of 65 patients with a dehiscence syndrome had conductive hearing loss [173]. Finally, the reason for developing a dehiscence syndrome remains unclear in the majority of the cases [193], [194].

Because of the high symptom variability in patients with dehiscence syndrome [195], [196], otosclerosis (conductive hearing loss with lost stapedius reflexes), tube disorders (hyper- and hypofunction), Menière's disease, and perilymph fistula, are the most frequent differential diagnoses [197]. Especially patients who have persisting conductive hearing loss after middle ear intervention despite normal ossicular chain mobility should undergo the respective imaging to exclude a dehiscence syndrome. Already in 1980, House et al. created the term of inner ear conductive hearing loss after they had found no reflex at the round window membrane in patients with normal stapes mobility. The described "invisible inner ear pathology" was possibly a dehiscence of the superior semicircular canal so that already at that time the phenomenon of dehiscence syndrome could have been described [198]. Not all patients with the clinical and the radiological signs of a dehiscence syndrome need surgical therapy. In most of the cases, a satisfactory control of the disease can be achieved by avoiding the situations that cause the symptoms [174], [199], [200], [201], [202]. Only in about 10% of the patients with the constellation of complaints and findings of a dehiscence syndrome receive surgical therapy [27]. Vestibular symptoms are the most frequent reason for surgery [203]. When indicating surgery, the severity of the individual complaints and the associated impairment in the quality of life must be evaluated regarding the possible risks of surgery.

As surgical options, either the so-called resurfacing with cartilage, bone and/or fascia or as modification the covering with hydroxyl apatite or bone cement are possible. The last-mentioned procedure is also called "capping". In both methods, the membranous semicircular canal is not closed or compressed but the continuity of the dehiscent bone is restored. In contrast, for occlusion ("plugging") the according semicircular canal is compressed by muscle fascia, fibrous tissue, bone wax, or bone pâté and closed [204], [205], [206]. While the initial control, especially of the vestibular symptoms, seems to be more effective by resurfacing [207], [208], the recurrence of the symptoms after occlusion is lower [173], [209]. Possible access routes are craniotomy of the middle fossa as long-term transtemporal standard access [194], [209], [210], [211] as well as the transmastoid access that has gained in importance in the last years [196], [206], [212], [213], [214], [215], [216], [217] and also the complication-free access through the auditory canal with a round window covering is described [194]. For the last-mentioned procedure, the round window is closed with bone wax, muscle plugs or fascia [218]. Liming et al. described a navigation-based endoscopic 15 mm keyhole approach to the middle

fossa after they had demonstrated the feasibility with temporal bone specimens [208]. An endoscopic procedure has also been suggested by other groups [194], [207], [219], [220].

Interventions at the middle fossa may lead to the development of epidural hematoma [221], [222], seizures [223], or liquor fistulas [224] as well as intracranial bleedings, brain edema or meningitis [225]. Schick et al. described a newly occurring temporal flap gliosis in 69% of the cases after a transtemporal approach to the middle fossa as well as conspicuities in neuropsychological tests one year after surgery [226]. A postoperative paresis of the facial nerve seems to occur more frequently in cases of dehiscence syndrome than in patients who undergo such an intervention for other reasons [222], [227]. Patients who had stapedoplasty because of conductive hearing loss have a higher risk of hearing deterioration after occlusion of the semicircular canal, independent from the approach [228].

The assessment of the current literature on the different approaches is rather difficult because the postoperative "success" is sometimes defined as improvement and sometimes as complete absence of the symptoms. Additionally, mostly small and inhomogeneous patient groups are described who had undergone different surgical techniques in individually modified ways. The success rates of the different surgical therapies reach from 75–100% for occlusion, resurfacing, capping or resurfacing and occlusion, independent from the access route [215], [216], [229], [230], [231]. For resurfacing, different materials are suggested (cartilage, fascia, squamous part of the temporal bone, mastoid skin). Ma et al. recommend a combination of temporal fascia and covering bone dust because this combination adapts to the individual surface properties the best [217]. Hahn et al., in contrast, use a hydroxyl apatite plate in a modified resurfacing technique [232].

While the transtemporal approach allows good visualization, orientation, and handling of the instruments [207], the transmastoid approach is a significantly less invasive access with the disadvantage of an unfavorable exposition of the bone defect [214], [233]. Generally, covering with bone cement or occlusion of the semicircular canal is also possible via a transmastoid approach [212], [233], [234], [235], [236]. After resurfacing with calotte bone of the squamous part, more frequently the preoperative symptoms reoccurred because of bone absorption [211], [214]. The bone thickness of the squamous part is mostly lower in patients with dehiscence syndrome compared to normal people so that often an absorption of the transplanted bone material with subsequent recurrent symptoms is observed [211]. In cases of extensive defects of the tegmen tympani and the mastoid that occur relatively often in patients with dehiscence syndrome, surgery with an individually designed Bioerit implant may be indicated after failure of classical resurfacing technique with cartilage and bone material [10].

In a meta-analysis comparing these surgical techniques (resurfacing, occlusion, capping) by Vlastarkos et al. [237]

success rates of 50% for resurfacing which was significantly poorer than for occlusion (97%) or capping (93%) were reported. The most frequently occurring complication was sensory hearing loss and balance disorders. Another literature research showed better symptom control after occlusion in comparison to resurfacing, however, with a higher risk for postoperative deterioration of the bone conduction threshold [194], [238]. In contrast to the transtemporal approach, the transmastoid occlusion shows better results regarding the hearing ability [239] while the transtemporal technique reaches a hearing loss of up to 25%. Conversely, in a study of 24 interventions with temporal access, Goddard et al. reported about no significant hearing deterioration more than one year after surgery [240]. Powell et al. described a series of 20 surgically treated patients with dehiscence syndrome of the superior semicircular canal who experienced an improvement of the symptoms in 76% after transmastoid resurfacing. The patients without postoperative improvement were nearly exclusively those with atypical symptoms [241].

Comorbidities such as migraine often lead to prolonged hearing problems after surgical intervention of the semicircular canals [222]. Other diseases that mimic the symptoms of dehiscence syndrome should be examined by differential diagnostics and excluded if possible [227]. Regarding success rates and complications, a systematic review of Gioacchini et al. revealed no significant differences for 150 evaluated interventions regarding the access (middle fossa vs. transmastoid) or the surgery technique (resurfacing, capping, occlusion, or resurfacing with occlusion) with an overall success rate of 94% [230]. In an investigation of 84 interventions for dehiscence syndrome, Barber et al. found the development of BPPV mostly within 3 months after surgery, in the control group (patients without surgery) only in 6.2% [242]. The development of BPPV was independent from the different approaches or surgery techniques so that preoperative information of the patients should include this possibility. Benamira et al. investigated which patients decide in favor or against surgical treatment. Patients with vestibular symptoms, hyperacusis for own footsteps and chewing noise, autophony, and stress-related oscillopsia decided more frequently for surgery [202].

Patients who mainly suffer from hyperacusis and do not have a positive Tullio phenomenon, may benefit from closure of the round window to stop their complaints [188]. In this way, the most easily accessible "third" window is closed: the round window. While the surgical risks are calculable, there is the risk that an enhanced movement of the fluid in direction of the dehiscent semicircular canal may trigger a postoperative Tullio phenomenon [188]. That is why this procedure should only be suggested to patients without Tullio phenomenon and be reversible by applying fascia, muscle or connective tissue [197], [218]. According to the current literature, a reinforcement or covering of the round window membrane in patients with dehiscence syndrome is generally possible for audiological and vestibular system control. The surgi-

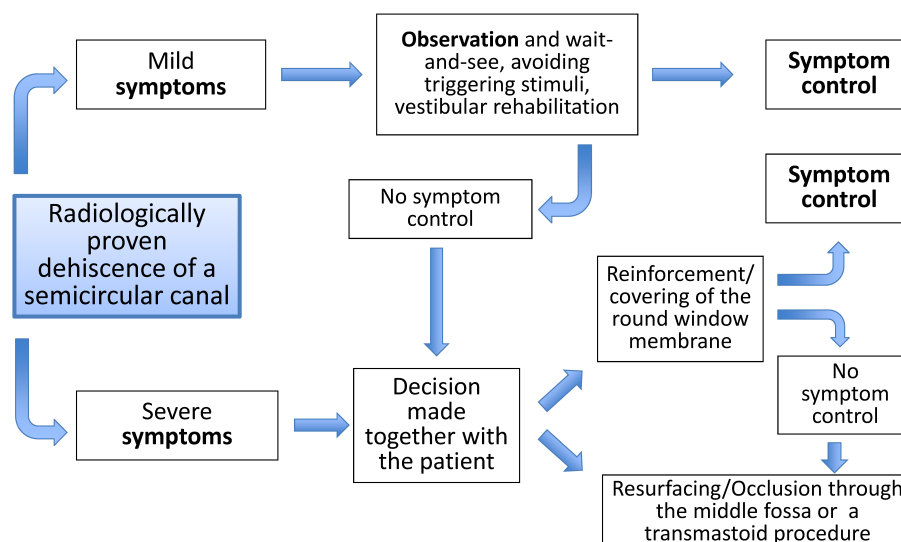


Figure 3: Therapeutic scheme for dehiscence syndrome of a semicircular canal
(modified according to [197])

cal risks are clearly less relevant than for alternative surgical procedures (resurfacing, occlusion, or capping), however, there are just a few experiences with this method and long-term results with adequate patient numbers are missing so far.

Patients who have bilateral dehiscences (radiologically confirmed in up to 50% [243], [244], [245]) should undergo surgery first of the side with the more severe symptoms. In most of the patients, symptoms stop after surgery so that surgery of the contralateral side is only rarely required. In cases of respective complaints, however, it may be performed with a positive outcome [231], [246], [247]. Agrawal et al. reported that after surgery of the first side the symptoms of the contralateral side are sometimes unmasked and that therefore the patients complain about different symptoms or deterioration of existing symptoms. The increased development of side effects in patients of this study is possibly due to the bilateral occlusion with subsequent oscillopsia [247], [248] so that resurfacing or capping should be preferred to occlusion for patients with bilateral dehiscence syndrome. Studies on the quality of life after the first intervention could show a significant improvement for different surgical procedures of dehiscence syndromes [203], [249], [250]. For some symptoms, the success rate of up to 100% is mentioned, however, complete loss of the symptoms cannot be regularly achieved after the first intervention [227], [251].

With increasing diagnosis and surgical therapy of dehiscence syndromes in the last years, also the experience was enlarged regarding revision surgeries. Revisions are frequently required because of dislocated or absorbed resurfacing or occlusion material [246], [251]. Sharon et al. look back to 23 revision surgeries in 21 patients and report about nearly 2 third who experienced complete or at least partly elimination of the symptoms [251]. All patients underwent resurfacing with occlusion via a trans-temporal approach in the context of revision intervention. There were no differences regarding the postoperative

hearing outcome in comparison to patients after the first intervention, but the overall success rate was slightly lower. Especially in the context of revision, typical symptoms of dehiscence syndromes should be present and the patient should be intensively counseled before surgery about the lower success rate compared to the first intervention [251].

The diagnosis of dehiscence syndrome in children is difficult because often history taking, especially for vestibular symptoms, is not reliable. However, there is an increasing number of reports about the symptomatic occurrence of this disease even in children [252], [253], [254]. Children with dehiscence syndrome are often only because of audiological symptoms noticed so that the indication for surgical therapy is made very reluctantly [253], [255]. From the literature, the age group of children younger than 7 years has radiologically a clearly higher prevalence of dehiscence or very thin bone of the superior but also posterior semicircular canal, even if those data are variable [256], [257], [258]. Clinical symptoms in this age group are often not present [256]. Lee et al. presented 10 cases of pediatric dehiscence syndrome (average age: 6.9 years). One of those patients had conservative therapy for several years and after progression of the vestibular symptoms she underwent successful transtemporal surgery at the age of 14 years [253]. In children and adolescents, a surgical procedure is only performed in very distinct cases.

Dehiscence syndromes get more and more in the focus of otolaryngologists and physicians of other disciplines and reach an increasing differential diagnostic significance. The challenge of this disease consists of the clinical severity of very different cochleo-vestibular disorders and an appropriate patient selection for the various treatment procedures. For those patients who have disabling complaints which are impairing the quality of life the above-mentioned surgical therapies are available with good prognosis regarding symptom control (Figure 3). Independent from the approach (transmastoid or trans-

temporal), the occlusion of the semicircular canal with simultaneous resurfacing of the dehiscent part seems to achieve the best results whereas the exact comparison of studies remains difficult.

4 Labyrinth/perilymph fistula

With exception of the round and the oval window, the membranous labyrinth is surrounded by the very dense petrous bone. Labyrinth fistulas are an unnatural connection between the inner ear and surrounding structures (middle ear, mastoid, dura, etc.) [259]. They include fistulas of the semicircular canals that might develop due to bone arrosion in the context of cholesteatoma, dehiscence syndromes of the semicircular canals (see chapter 3), and the so-called perilymph fistulas that are defined as perilymph leak through the round or oval window [260]. Similar to patients with ELH, there are also a multitude of sometimes confusing and contradictory classifications/definitions [260] that make systematic assessment of the therapeutic methods difficult because very different diseases have been compared with each other.

4.1 Perilymph fistula

Already in 1905, Hennebert noticed that patients with ear syphilis also suffer from vertigo or nystagmus caused by pressure changes (reduced or increased pressure) in the auditory meatus [178]. This so-called Hennebert's sign was used as diagnostic test for ear syphilis, nowadays it is generally called fistula test (syn. fistula symptom). Positive or negative pressure in the auditory meatus, generated by a pneumatic otoscope, stimulates the respective receptors of the semicircular canals. Perilymph fistulas developed at the beginning of stapes surgery in the 1960ies because of larger prosthesis and the not performed sealing of the footplate region with connective tissue as it is standard nowadays [261], [262]. Perilymph fistulas were also described after cranial trauma, intracranial pressure increase, or without visible cause as spontaneous perilymph fistula [263], [264], [265]. Other possible reasons may be barotrauma after flying or diving, nose blowing, coughing, airbag traumas, but also acoustic traumas [260], [266], [267]. The symptoms of perilymph fistula are unspecific: vertigo, sensation of instability, staggering, sometimes accompanied with hearing loss [268]. Clear and specific diagnostic tests are missing so that the presence of a positive Hennebert's sign or confirmed Tullio phenomenon sometimes led to generously indicating an explorative tympanotomy in cases of suspected perilymph fistula. In the literature of the 1980ies and 1990ies, numerous studies are found about experiences with the surgical exploration because of suspected perilymph fistula [268], [269], [270], [271]. The data on intraoperatively confirmed perilymph leak vary between 40% and nearly 90% of all explored middle ears. The majority of the authors recommend occlusion

of the round window niche and the footplate region with connective tissue, independent from the actual proof of perilymph leakage because even patients without intraoperative confirmation benefit in a similar positive way regarding the main symptoms compared to patients with confirmed diagnosis [268], [269], [272]. An explanation for this may be that some fistulas are only intermittently open [259]. While in the case of a fistula after cranial trauma nearly always the oval window was affected, leakages of the round window were found predominantly after barotrauma or unknown cause [260], [273]. Surgical techniques range from simple occlusion with connective tissue up to the application of a laser as well as the use of fibrin glue in order to reduce the re-occurrence of the symptoms after initially successful therapy from 27 to 8% [274].

Critical reviews and recent reports, partly also about endoscopic middle ear explorations for a suspected perilymph fistula, could not confirm the high rates of actually proven fistula mentioned in the literature and question in particular the existence of spontaneous perilymph fistulas because targeted history taking reveals trauma or other possibly triggering factors in most cases [260], [275], [276], [277]. Shea described in an impressive article from 1992 the myth of spontaneous perilymph fistula and doubted their existence because he had never seen such a phenomenon in more than 36,000 ear surgeries [278].

In our opinion and based on clinical experience, perilymph fistulas occur but they are due to direct trauma or barotrauma in most of the cases. If the suspicion and the according symptoms occur, tympanotomy with occlusion of the round window niche and the footplate region is reasonable as therapeutic option after thorough counselling of the patient.

4.2 Arrosion of the semicircular canals by cholesteatoma

Cholesteatomas may cause a functional loss of the peripheral vestibular organ and/or perilymph fistula because of bone arrosion, that is mostly located at the horizontal semicircular canal, more rarely also at the round window or the promontory [259], [279]. In the context of urgent restoring surgery, the epithelium must be removed completely and the perilymph tube must be covered in several layers with connective tissue, bone dust, fibrin glue, cartilage, or specially designed Bioverit implants for larger defects [10], [279], [280]. Especially in patients with an open mastoid cavity and recurrent inflammation of the cavity, perilymph fistulas must be expected in revision surgeries [279]. Suspect areas should be explored at the end of surgery and in cases of a true fistula they should be covered immediately. Some authors recommend to leave the cholesteatoma matrix above the semicircular canal for large bone defects and to include it in the epithelization process of an open mastoid cavity, especially in the context of surgeries of the last hearing ear because of the risk of hearing deterioration/deafness [281], [282].

5 Benign peripheral paroxysmal positional vertigo

Benign paroxysmal positional vertigo (BPPV) is the most frequently observed type of vertigo with an origin in the inner ear especially in older patients [233], [283], [284]. Typically, rotational vertigo and horizontal-rotatory nystagmus occur in a crescendo-decrescendo course for 30–60 s after reinclination of the head or body/head side position with a latency of a few seconds. More than 90% of the cases are idiopathic, fewer causes occur after trauma, after vestibular neuritis, or even after long-term bed rest [284], [285]. Even after surgical therapy due to dehiscence syndrome [230], otosclerosis [286], or even non-surgical interventions [284], BPPV is observed. The indication of surgery is only made in very rare cases [233], [287]. By means of different repositioning and positioning maneuvers, most cases can be treated successfully and permanently. If a therapy refractory BPPV is observed despite correct diagnostics and competently performed repositioning and positioning maneuvers, two surgical procedures may be a therapeutic option: partial neurectomy of the vestibular nerve (singular nerve) or occlusion of the affected (mainly posterior) semicircular canal [288].

5.1 Neurectomy of the singular nerve

In 1978, Silverstein suggested neurectomy of the singular nerve for the treatment of therapy refractory BPPV [289] which was and is nearly exclusively performed in North America [288]. Even for experienced surgeons, it is a technically challenging intervention and is associated with a significant risk of hearing deterioration as reported by Gacek in a study of 242 patients with 252 surgeries [290]. Beside Gacek who used an access through the auditory meatus only few other neuro-otologists have performed this intervention and published their results [291], [292], [293], [294], [295], [296], [297]. Silverstein described a postauricular approach with a maximum of drilling at the external auditory canal and reported about a complaint-free outcome of 80% in a series of 58 patients while just 3 patients had a significant postoperative hearing loss [291]. Various studies report a complete elimination of the symptoms in 75–100% of the cases. As possible reason for therapy failure, a false diagnosis, incomplete transection, failed identification of the nerve, or the presence of an accessory nerve portion are mentioned [288], [298]. Postoperative sensorineural hearing loss is described from 30 dB up to complete deafness and mainly depends on the surgeon's experience. Gacek reports about 3.7% (252 neurectomies), Epley about 41% in a series of 12 patients [290], [292]. Anatomical examination of the position of the singular nerve performed by Leuwer et al. led to the conclusion that the nerve can be exposed in at least 14% up to more than 30% of the cases only by opening the basal cochlear turn. That is why they question strongly the excellent results regarding hearing preservation [299].

5.2 Occlusion of the posterior semicircular canal

In 1990, Parnes and McClure described the transmastoid occlusion of the posterior semicircular canal as a relatively easy therapeutic procedure without severe complications, first in patients who had also an advanced sensorineural hearing loss [300] and later also in normal hearing patients [301]. Beyea reported about 65 of those interventions that had been performed by the same surgeon and mentioned an elimination of the vestibular symptoms in all cases, however, 3 patients revealed a persisting inner ear hearing loss (2 patients had a mild and 1 patient a severe hearing loss, however, this last-mentioned patient had already undergone 2 previous interventions in the sense of neurectomy of the vestibular nerve) [233]. Meanwhile, this surgical technique is internationally established and the good results are reproducible [302], [303], [304], [305], [306], [307], [308]. In some cases, a low-grade, transient, high-frequency hearing loss is reported after the surgery [233], [304]. For further preservation of the hearing ability, some authors have suggested the application of a CO₂ laser [309]. However, up to now no additional benefit could be confirmed [288].

Because of the very favorable results and experiences with occlusion of the posterior semicircular canal, this procedure is also suggested to patients who suffer from bilateral therapy refractory BPPV as sequential procedure. This shows the same results as in patients suffering on just one side from BPPV. The experience is rather low (n=6) but apart from the mentioned side effects (high-frequency hearing loss in one patient, transient postoperative balance disorders) no other severe complications occurred [233], [310]. Surgical interventions because of therapy refractory BPPV are only recommended for a highly selected group of patients and since the 1990ies this number is decreasing continuously [288]. This may be due to the improvement of diagnostic tools and the pathophysiological understanding of the diseases of the lateral and anterior semicircular canal as well as the respective repositioning maneuvers and also to the increasing number of diseases that are evaluated by differential diagnostics in the field of neurology that are very similar to the symptoms of BPPV [288]. Some authors recommend at least 12 months of conservative, physical (positioning and repositioning maneuvers) treatment with continuous verification of the correct diagnosis before surgical therapy may be offered [233], [288]. Patients who nonetheless need surgery for BPPV should undergo occlusion of the respective semicircular canal.

6 Vestibular implants

For permanent uni- or bilateral functional loss of the peripheral vestibular organs, no further therapeutic option exists apart from physical therapy and the associated activation of central compensatory mechanisms. The quality of life of these affected patients is significantly

impaired so that the interest is very high to provide a perspective of improving their situation [311]. Development of the first vestibular implants (VI) is expected to be very promising, also with regard to the great success of cochlear implants (CI) [312], [313], [314], [315]. After numerous and at least in parts very promising trials in animal models [316], [317], [318], [319], first VI were applied in humans, mainly in patients with bilateral loss of the vestibular function, but also in patients with MM [312], [314], [315], [320], [321]. Sensors of the VI register movements such as for rotation or acceleration (e.g. by means of gyroscope or accelerometer) and transform them into electrical impulses that stimulate the vestibular system via electrodes implanted in the semicircular canals near the respective ampulla. Depending on the stimulated semicircular canal, specific eye movements can be provoked in an animal model and also in humans which correspond to the vestibulo-ocular reflex (VOR) [315]. In rhesus monkeys, it was already possible to confirm that not only the VOR but also the orientation of the spatial position of the head can be influenced by electrical stimulation with VI [322]. Transferring the knowledge obtained in animal models to the application in humans was first rather difficult and led to some surprising and even disappointing results [315]. The reasons are manifold, for example other implants are used in humans than beforehand in the animal model. Because of the size of the target structure, there is a problem with the exact positioning of the stimulus electrode. The electrical fields and stimulus currents are still classified as very conservative in order not to cause undesired reactions such as pain or stimulation of the auditory system [315]. While the cochleo-vestibular functions in the animal model after implantation of the VI electrodes could be preserved [323], the few trials in humans show mainly other results [312]. Beside natural differences regarding the robustness of sensory structures of the hearing and vestibular organ of a single species, it must be taken into consideration that the implantations in animal models were performed in intact inner ears whereas the trials in humans were understandably performed only in patients with functional loss and thus damaged inner ears. Hence, the risk of further damage of the residual function of the vestibular organ as well as hearing function was clearly higher and the ability to recover from implantation trauma was reduced when a certain severity of previous damage was present [312]. The fact, however, that generally an intervention in/at the cochlea or a peripheral vestibular organ is possible without damaging the respective other part of the inner ear, is revealed by numerous cochlear implantations without damaging the vestibular organ and also by occlusion of the semicircular canal in the context of BPPV with hearing preservation (see chapter 5.2).

Reports about the development and first progress of vestibular implants recall the first reports about cochlear implantation. Hereby, the initial idea and objective were to facilitate lip-reading of the affected patients [324]. Those already optimistic expectations of the beginning

were exceeded by far in the following decades [325]. If the development of vestibular implant systems may experience similar gain in knowledge and the same promising results as in cochlear implant technology had been shown during the last 40 years, will be seen in the future.

Conclusion

Most disease of the peripheral vestibular system can be treated successfully by means of conservative therapy methods. For patients who still suffer from defined vertigo symptoms after exhaustion of pharmaceutical as well as other conservative treatment and who are severely impaired regarding their quality of life, surgical procedures are often the only remaining alternative. Because of the sometimes difficult selection of the patients, the improved neuro-otological diagnostic tools, and especially the further development of intratympanic drug application (first of all steroids, gentamicin etc.), surgical procedures for disease of the peripheral vestibular organs continuously decrease. Before surgical therapy, the diagnosis and the side assignment have to be double-checked, a sufficiently long conservative attempt has to be performed, and the benefits and risks of the offered surgical intervention have to be individually discussed with the patient during counselling.

In general, function preserving procedures are preferred where available. For patients with Menière's disease, in particular saccus surgery is an effective method with just minimal side effects that can also be repeated if needed. Hence, neurectomy as ultima ratio is only performed very rarely nowadays. After exploitation of conservative treatment in cases of benign paroxysmal positional vertigo, the occlusion of the respective semicircular canal turned out to be beneficial. This procedure can mostly be performed with hearing preservation.

The invasiveness of the applied method, i.e. the decision to perform a function preserving or ablative intervention, mostly depends on the amount of residual hearing and the individual vertigo-induced reduction of quality of life in each individual patient. This does not apply for suspected arrosion of a semicircular canal due to cholesteatoma or acute inflammatory disease of the mastoid. Here, the surgical covering/remediation has to be performed immediately and independent from the current hearing ability. Regarding all revisions or interventions at the second, also affected side, the following aspects must be considered: repeated verification of the diagnosis, differential diagnostic exclusion also of central disease, and in particular in older patients the estimation of possible compensation mechanisms after any kind of destructive intervention.

Abbreviations

BPPV – Benign paroxysmal positional vertigo
CI – Cochlear implant

DHI – Dizziness Handicap Inventory
 ELH – Endolymphatic hydrops
 MM – Ménière's disease
 VI – Vestibular implant
 VOR – Vestibulo-ocular reflex

Notes

Competing interests

The authors declare that they have no competing interests.

References

- Patnaik U, Srivastava A, Sikka K, Thakar A. Surgery for vertigo: 10-year audit from a contemporary vertigo clinic. *J Laryngol Otol*. 2015 Dec;129(12):1182-7. DOI: 10.1017/S0022215115002935
- Liston SL, Nissen RL, Paparella MM, Da Costa SS. Surgical treatment of vertigo. In: Paparella MM, Shumrick DA, Gluckman JL, Meyerhoff WL, editors. *Otolaryngology. Volume II: Philadelphia: WB Saunders Company; 1991. p. 1715-32.*
- Colletti V, Carner M, Colletti L. Auditory results after vestibular nerve section and intratympanic gentamicin for Ménière's disease. *Otol Neurotol*. 2007 Feb;28(2):145-51. DOI: 10.1097/MAO.0b013e31802c7989
- Sajjadi H, Paparella MM. Ménière's disease. *Lancet*. 2008;372:406-14. DOI: 10.1016/S0140-6736(08)61161-7
- Yokota Y, Kitahara T, Sakagami M, Ito T, Kimura T, Okayasu T, Yamashita A, Yamanaka T. Surgical results and psychological status in patients with intractable Ménière's disease. *Auris Nasus Larynx*. 2016 Jun;43(3):287-91. DOI: 10.1016/j.anl.2015.10.007
- Diener HC. Leitlinien für Diagnostik und Therapie in der Neurologie. 4. Überarbeitete Aufl. Stuttgart: Georg Thieme Verlag; 2008. p. 654 ff. ISBN 978-3-13-132414-6.
- Strupp M, Kremmyda O, Bremova T, Teufel J. Aktuelles zur Pharmakotherapie von Schwindel und Nystagmus. *Arzneimitteltherapie*. 2013;31:147-55.
- Pullens B, Giard JL, Verschuur HP, van Benthem PP. Surgery for Ménière's disease. *Cochrane Database Syst Rev*. 2010;1:CD005395. DOI: 10.1002/14651858.CD005395.pub2
- Pullens B, Verschuur HP, van Benthem PP. Surgery for Ménière's disease. *Cochrane Database Syst Rev*. 2013;2:CD005395. DOI: 10.1002/14651858.CD005395.pub3
- Westhofen M. Die operative Therapie des vestibulären Schwindels: Verfahren und Indikationen [Surgical treatment of vestibular vertigo: methods and indications]. *HNO*. 2008 Oct;56(10):1003-10. DOI: 10.1007/s00106-008-1807-x
- Van de Heyning PH, Wuyts F, Boudewyns A. Surgical treatment of Meniere's disease. *Curr Opin Neurol*. 2005 Feb;18(1):23-8.
- Ménière P. Mémoire sur des lésions de l'oreille interne donnant lieu à des symptômes de congestion cérébrale apoplectiforme. *Gazette médicale de Paris*. 1861;16:88-9, 239-40, 379-80, 597-601.
- Hallpike CS, Cairns H. Observations on the pathology of Ménière's syndrome. *J Laryngol Otol*. 1938;53:625-55. DOI: 10.1017/S0022215100003947
- Yamakawa K. Über die pathologische Veränderung bei einem Meniere-Kranken. *J Otorhinolaryngol Soc Jpn*. 1938;44:2310-2.
- Baier G, Ott I. Die chirurgische Therapie des M. Ménière. Historische Entwicklung und heutiger Stand [Surgical therapy in Ménière's disease. Historical development and today's state of the art]. *HNO*. 2008 May;56(5):553-64; quiz 565-6. DOI: 10.1007/s00106-008-1734-x
- Claes GM, De Valck CF, Van de Heyning P, Wuyts FL. Does 'cochlear Ménière's disease' exist? An electrocochleographic and audiometric study. *Audiol Neurootol*. 2013;18(1):63-70. DOI: 10.1159/000342686
- Gürkrov R, Ertl-Wagner B, Krause E. Endolymphatischer Hydrops in der Bildgebung. *HNO Nachrichten*. 2014;44:22-4. DOI: 10.1007/s00060-014-0456-9
- Committee on Hearing and Equilibrium. Report of Subcommittee on Equilibrium and its Measurement. Ménière's disease: criteria for diagnosis and evaluation of therapy for reporting. *Trans Am Acad Ophthalmol Otolaryngol*. 1972 Nov-Dec;76(6):1462-4.
- Committee on Hearing and Equilibrium guidelines for the diagnosis and evaluation of therapy in Ménière's disease. American Academy of Otolaryngology-Head and Neck Foundation, Inc. *Otolaryngol Head Neck Surg*. 1995 Sep;113(3):181-5. DOI: 10.1016/S0194-5998(95)70102-8
- Pearson BW, Brackmann DE. Committee on Hearing and Equilibrium guidelines for reporting treatment results in Ménière's disease. *Otolaryngol Head Neck Surg*. 1985 Oct;93(5):579-81. DOI: 10.1177/019459988509300501
- Lopez-Escamez JA, Carey J, Chung WH, Goebel JA, Magnusson M, Mandalà M, Newman-Toker DE, Strupp M, Suzuki M, Trabalzini F, Bisdorff A; Classification Committee of the Barany Society; Japan Society for Equilibrium Research; European Academy of Otolology and Neurotology (EAONO); Equilibrium Committee of the American Academy of Otolaryngology-Head and Neck Surgery (AAO-HNS); Korean Balance Society. Diagnostic criteria for Ménière's disease. *J Vestib Res*. 2015;25(1):1-7. DOI: 10.3233/VES-150549
- Goebel JA. 2015 Equilibrium Committee Amendment to the 1995 AAO-HNS Guidelines for the Definition of Ménière's Disease. *Otolaryngol Head Neck Surg*. 2016 Mar;154(3):403-4. DOI: 10.1177/0194599816628524
- Nakashima T, Naganawa S, Sugiura M, Teranishi M, Sone M, Hayashi H, Nakata S, Katayama N, Ishida IM. Visualization of endolymphatic hydrops in patients with Ménière's disease. *Laryngoscope*. 2007 Mar;117(3):415-20. DOI: 10.1097/MLG.0b013e31802c300c
- Gürkrov R, Kantner C, Strupp M, Flatz W, Krause E, Ertl-Wagner B. Endolymphatic hydrops in patients with vestibular migraine and auditory symptoms. *Eur Arch Otorhinolaryngol*. 2014 Oct;271(10):2661-7. DOI: 10.1007/s00405-013-2751-2
- Nakashima T, Pyykkö I, Arroll MA, Casselbrant ML, Foster CA, Manzoor NF, Megerian CA, Naganawa S, Young YH. Ménière's disease. *Nat Rev Dis Primers*. 2016 05;2:16028. DOI: 10.1038/nrdp.2016.28
- Gürkrov R, Pyykö I, Zou J, Kentala E. What is Ménière's disease? A contemporary re-evaluation of endolymphatic hydrops. *J Neurol*. 2016 Apr;263 Suppl 1:S71-81. DOI: 10.1007/s00415-015-7930-1
- Westhofen M. Indikation und Erfolge der operativen Therapie des vestibulären Schwindels [Indications for operative therapy of vestibular vertigo and the associated success rates]. *HNO*. 2013 Sep;61(9):752-61. DOI: 10.1007/s00106-013-2749-5
- Westhofen M. M. Ménière: Evidenzen und Kontroversen [Ménière's disease: evidence and controversies]. *HNO*. 2009 May;57(5):446-54. DOI: 10.1007/s00106-009-1915-2

29. Minor LB, Schessel DA, Carey JP. Ménière's disease. *Curr Opin Neurol*. 2004 Feb;17(1):9-16. DOI: 10.1097/00019052-200402000-00004
30. Arenberg IK, Bayer RF. Therapeutic options in Meniere's disease. *Arch Otolaryngol*. 1977;103:589-93. DOI: 10.1001/archotol.1977.00780270057007
31. Smith WC, Pillsbury HC. Surgical treatment of Ménière's disease since Thomsen. *Am J Otol*. 1988 Jan;9(1):39-43.
32. Jahnke K. Stadiengerechte Therapie der Menierschen Krankheit. *Deutsches Ärzteblatt*. 1994;91:428-33.
33. Silverstein H, Smouha E, Jones R. Natural history vs. surgery for Ménière's disease. *Otolaryngol Head Neck Surg*. 1989 Jan;100(1):6-16. DOI: 10.1177/01945988910000102
34. Teufert KB, Doherty J. Endolymphatic sac shunt, labyrinthectomy, and vestibular nerve section in Meniere's disease. *Otolaryngol Clin North Am*. 2010 Oct;43(5):1091-111. DOI: 10.1016/j.otc.2010.05.014
35. Albera R, Canale A, Parandero F, Ducati A, Lanotte M. Surgical indication in Ménière's disease therapy: clinical and epidemiological aspects. *Eur Arch Otorhinolaryngol*. 2011 Jul;268(7):967-72. DOI: 10.1007/s00405-011-1490-5
36. Syed MI, Ilan O, Leong AC, Pothier DD, Rutka JA. Ménière's Syndrome or Disease: Time Trends in Management and Quality of Evidence Over the Last Two Decades. *Otol Neurotol*. 2015 Sep;36(8):1309-16. DOI: 10.1097/MAO.0000000000000831
37. Tumarkin A. Thoughts on the treatment of labyrinthopathy. *J Laryngol Otol*. 1966 Oct;80(10):1041-53. DOI: 10.1017/S0022215100066366
38. Lall M. Ménière's disease and the grommet (a survey of its therapeutic effects). *J Laryngol Otol*. 1969 Aug;83(8):787-91. DOI: 10.1017/S002221510007095X
39. Montandon P, Guillemin P, Häusler R. Prevention of vertigo in Ménière's syndrome by means of transtympanic ventilation tubes. *ORL J Otorhinolaryngol Relat Spec*. 1988;50(6):377-81. DOI: 10.1159/000276016
40. Sugawara K, Kitamura K, Ishida T, Sejima T. Insertion of tympanic ventilation tubes as a treating modality for patients with Meniere's disease: a short- and long-term follow-up study in seven cases. *Auris Nasus Larynx*. 2003;30:25-8. DOI: 10.1016/S0385-8146(02)00105-0
41. Franz B, Altidis P, Altidis B, Collis-Brown G. The cervicogenic otoocular syndrome: a suspected forerunner of Ménière's disease. *Int Tinnitus J*. 1999;5(2):125-30.
42. Kimura RS, Hutta J. Inhibition of experimentally induced endolymphatic hydrops by middle ear ventilation. *Eur Arch Otorhinolaryngol*. 1997;254:213-8. DOI: 10.1007/BF00874091
43. Park JJ, Chen YS, Westhofen M. Meniere's disease and middle ear pressure: vestibular function after transtympanic tube placement. *Acta Otolaryngol*. 2009 Dec;129(12):1408-13. DOI: 10.3109/00016480902791678
44. Ogawa Y, Otsuka K, Hagiwara A, Inagaki A, Shimizu S, Nagai N, Itani S, Saito Y, Suzuki M. Clinical study of tympanostomy tube placement for patients with intractable Ménière's disease. *J Laryngol Otol*. 2015 Feb;129(2):120-5. DOI: 10.1017/S0022215115000079
45. Cinnamon MJ. Eustachian tube function in Ménière's disease. *J Laryngol Otol*. 1975 Jan;89(1):57-61. DOI: 10.1017/S0022215100080075
46. Hall MC, Brackmann DE. Eustachian tube blockage and Meniere's disease. *Arch Otolaryngol*. 1977;103:355-7. DOI: 10.1001/archotol.1977.00780230077012
47. Storms RF, Ferraro JA, Thedinger BS. Electrocochleographic effects of ear canal pressure change in subjects with Ménière's disease. *Am J Otol*. 1996 Nov;17(6):874-82.
48. Maier W, Ross U, Fradis M, Richter B. Middle ear pressure and dysfunction of the labyrinth: is there a relationship? *Ann Otol Rhinol Laryngol*. 1997 Jun;106(6):478-82. DOI: 10.1177/000348949710600607
49. Thomsen J, Bonding P, Becker B, Stage J, Tos M. The non-specific effect of endolymphatic sac surgery in treatment of Meniere's disease: a prospective, randomized controlled study comparing "classic" endolymphatic sac surgery with the insertion of a ventilating tube in the tympanic membrane. *Acta Otolaryngol*. 1998 Nov;118(6):769-73. DOI: 10.1080/00016489850182413
50. Feijen RA, Segenhout JM, Albers FW, Wit HP. Change of guinea pig inner ear pressure by square wave middle ear cavity pressure variation. *Acta Otolaryngol*. 2002 Mar;122(2):138-45. DOI: 10.1080/00016480252814135
51. De Ru JA, Heerens WC. Clinical study of tympanostomy tube placement for patients with intractable Ménière's disease. *J Laryngol Otol*. 2015 Jul;129(7):727. DOI: 10.1017/S0022215115001462
52. Franz P, Hamzavi JS, Schneider B, Ehrenberger K. Do middle ear muscles trigger attacks of Ménière's disease? *Acta Otolaryngol*. 2003 Jan;123(2):133-7. DOI: 10.1080/00016480310000999
53. Loader B, Beicht D, Hamzavi JS, Franz P. Tenotomy of the middle ear muscles causes a dramatic reduction in vertigo attacks and improves audiological function in definite Meniere's disease. *Acta Otolaryngol*. 2012 May;132(5):491-7. DOI: 10.3109/00016489.2011.642815
54. Loader B, Beicht D, Hamzavi JS, Franz P. Tenotomy of the stapedius and tensor tympani muscles reduces subjective dizziness handicap in definite Meniere's disease. *Acta Otolaryngol*. 2013 Apr;133(4):368-72. DOI: 10.3109/00016489.2012.746470
55. Albu S, Babighian G, Amadori M, Trabalzini F. Endolymphatic sac surgery versus tenotomy of the stapedius and tensor tympani muscles in the management of patients with unilateral definite Meniere's disease. *Eur Arch Otorhinolaryngol*. 2015 Dec;272(12):3645-50. DOI: 10.1007/s00405-014-3428-1
56. De Valck CF, Van Rompaey V, Wuyts EL, Van de Heyning PH. Tenotomy of the tensor tympani and stapedius tendons in Ménière's disease. *B-ENT*. 2009;5(1):1-6.
57. Paparella MM, Sajjadi H. Endolymphatic sac enhancement. *Otolaryngol Clin North Am*. 1994 Apr;27(2):381-402.
58. Ghossaini SN, Wazen JJ. An update on the surgical treatment of Ménière's diseases. *J Am Acad Audiol*. 2006 Jan;17(1):38-44. DOI: 10.3766/jaaa.17.1.5
59. Plontke SK, Gürkov R. Morbus Ménière [Ménière's Disease]. *Laryngorhinootologie*. 2015 Aug;94(8):530-54. DOI: 10.1055/s-0035-1555808
60. Gabra N, Asmar MH, Berbiche D, Saliba I. Endolymphatic duct blockage: quality of life assessment of a novel surgical technique for Ménière disease. *Eur Arch Otorhinolaryngol*. 2016 Oct;273(10):2965-73. DOI: 10.1007/s00405-015-3890-4
61. Portmann G. The saccus endolymphaticus and an operation for draining for the relief of vertigo. *Proc R Soc Med*. 1927;20:1862-7. DOI: 10.1017/S0022215100031297
62. House WF. Subarachnoid shunt for drainage of hydrops. A report of 63 cases. *Arch Otolaryngol*. 1964 Apr;79:338-54. DOI: 10.1001/archotol.1964.00750030347004
63. House WF. Shunt and other operations for hydrops. *Arch Otolaryngol*. 1969 Jan;89(1):104-7. DOI: 10.1001/archotol.1969.00770020106018

64. Shambaugh GE Jr. Surgery of the endolymphatic sac. *Arch Otolaryngol.* 1966;83:305-15. DOI: 10.1001/archotol.1966.00760020307003
65. Plester D. Surgical treatment of Ménière's disease. *Proc R Soc Med.* 1967 Oct;60(10):964-6.
66. Paparella MM, Kim CS, Shea DA. Sac decompression for refractory luetic vertigo. *Acta Otolaryngol.* 1980 May-Jun;89(5-6):541-6. DOI: 10.3109/00016488009127172
67. Ostrowski VB, Kartush JM. Endolymphatic sac-vein decompression for intractable Meniere's disease: long term treatment results. *Otolaryngol Head Neck Surg.* 2003;128:550-9. DOI: 10.1016/S0194-5998(03)00084-6
68. Stupp H. Zur operativen Behandlung des Morbus Ménière [Surgical treatment of Ménière's disease]. *Arch Klin Exp Ohren Nasen Kehlkopfheilkd.* 1970;196(2):261-6.
69. Shea JJ. Teflon film drainage of the endolymphatic sac. *Arch Otolaryngol.* 1966 Apr;83(4):316-9. DOI: 10.1001/archotol.1966.00760020318004
70. House WF. Subarachnoid shunt for drainage of endolymphatic hydrops. A preliminary report. *Laryngoscope.* 1962 Jun;72:713-29. DOI: 10.1288/00005537-196206000-00003
71. Telischi FF, Luxford WM. Long-term efficacy of endolymphatic sac surgery for vertigo in Ménière's disease. *Otolaryngol Head Neck Surg.* 1993 Jul;109(1):83-7. DOI: 10.1177/019459989310900115
72. Arenberg IK. Results of endolymphatic sac to mastoid shunt surgery for Ménière's disease, refractory to medical therapy. *Rev Laryngol Otol Rhinol (Bord).* 1987;108(5):453-8.
73. Brown JS. A ten year statistical follow-up of 245 consecutive cases of endolymphatic shunt and decompression with 328 consecutive cases of labyrinthectomy. *Laryngoscope.* 1983 Nov;93(11 Pt 1):1419-24.
74. Brinson GM, Chen DA, Arriaga MA. Endolymphatic mastoid shunt versus endolymphatic sac decompression for Ménière's disease. *Otolaryngol Head Neck Surg.* 2007 Mar;136(3):415-21. DOI: 10.1016/j.otohns.2006.08.031
75. Gianoli GJ, Larouere MJ, Kartush JM, Wayman J. Sac-vein decompression for intractable Meniere's disease: two-year treatment results. *Otolaryngol Head Neck Surg.* 1998 Jan;118(1):22-9. DOI: 10.1016/S0194-5998(98)70370-5
76. Kim SH, Ko SH, Ahn SH, Hong JM, Lee WS. Significance of the development of the inner ear third window effect after endolymphatic sac surgery in Ménière disease patients. *Laryngoscope.* 2012 Aug;122(8):1838-43. DOI: 10.1002/lary.23332
77. Kitahara M, Kitajima K, Yazawa Y, Uchida K. Endolymphatic sac surgery for Ménière's disease: eighteen years' experience with the Kitahara sac operation. *Am J Otol.* 1987 Jul;8(4):283-6.
78. Luetje CM. A critical comparison of results of endolymphatic subarachnoid shunt and endolymphatic sac incision operations. *Am J Otol.* 1988;9:95-101. DOI: 10.1097/00129492-198803000-00001
79. Huang TS, Lin CC. Endolymphatic sac surgery for Meniere's disease: a composite study of 339 cases. *Laryngoscope.* 1985 Sep;95(9 Pt 1):1082-6. DOI: 10.1288/00005537-198509000-00013
80. Glasscock ME 3rd, Kveton JF, Christiansen SG. Current status of surgery for Meniere's disease. *Otolaryngol Head Neck Surg.* 1984 Feb;92(1):67-72. DOI: 10.1177/019459988409200115
81. Jackson CG, Dickins JR, McMenemy SO, Graham SS, Glasscock ME 3rd, Minor LB, Strasnick B. Endolymphatic system shunting: a long-term profile of the Denver Inner Ear Shunt. *Am J Otol.* 1996 Jan;17(1):85-8.
82. Thomsen J, Bretlau P, Tos M, Johnsen NJ. Placebo effect in surgery for Ménière's disease. A double-blind, placebo-controlled study on endolymphatic sac shunt surgery. *Arch Otolaryngol.* 1981 May;107(5):271-7. DOI: 10.1001/archotol.1981.00790410009002
83. Thomsen J, Bretlau P, Tos M, Johnsen NJ. Endolymphatic sac-mastoid shunt surgery. A nonspecific treatment modality? *Ann Otol Rhinol Laryngol.* 1986 Jan-Feb;95(1 Pt 1):32-5. DOI: 10.1177/000348948609500107
84. Chung JW, Fayad J, Linthicum F, Ishiyama A, Merchant SN. Histopathology after endolymphatic sac surgery for Ménière's syndrome. *Otol Neurotol.* 2011 Jun;32(4):660-4. DOI: 10.1097/MAO.0b013e31821553ce
85. Thomsen J, Bretlau P, Tos M, Johnsen NJ. Placebo effect in surgery for Meniere's disease: three-year follow-up. *Otolaryngol Head Neck Surg.* 1983 Apr;91(2):183-6. DOI: 10.1177/019459988309100213
86. Bretlau P, Thomsen J, Tos M, Johnsen NJ. Placebo effect in surgery for Ménière's disease: nine-year follow-up. *Am J Otol.* 1989 Jul;10(4):259-61.
87. Arenberg IK. Placebo effect for Ménière's disease sac shunt surgery disputed [letter]. *Arch Otolaryngol.* 1981 Dec;107(12):773. DOI: 10.1001/archotol.1981.00790480049013
88. Vaisrub N. Placebo effect for Ménière's disease sac shunt surgery disputed [letter]. *Arch Otolaryngol.* 1981 Dec;107(12):773-4. DOI: 10.1001/archotol.1981.00790480049013
89. Pillsbury HC 3rd, Arenberg IK, Ferraro J, Ackley RS. Endolymphatic sac surgery. The Danish sham surgery study: an alternative analysis. *Otolaryngol Clin North Am.* 1983 Feb;16(1):123-7.
90. Welling DB, Nagaraja HN. Endolymphatic mastoid shunt: a reevaluation of efficacy. *Otolaryngol Head Neck Surg.* 2000 Mar;122(3):340-5. DOI: 10.1067/mhn.2000.101575
91. Monsell EM, Wiet RJ. Endolymphatic sac surgery: methods of study and results. *Am J Otol.* 1988 Sep;9(5):396-402.
92. Paparella MM, Fina M. Endolymphatic sac enhancement: reversal of pathogenesis. *Otolaryngol Clin North Am.* 2002;35:621-37. DOI: 10.1016/S0030-6665(02)00022-1
93. Huang TS. Endolymphatic sac surgery for Meniere's disease: experience with over 3000 cases. *Otolaryngol Clin North Am.* 2002 Jun;35(3):591-606. DOI: 10.1016/S0030-6665(02)00027-0
94. Lee L, Pensak ML. Contemporary role of endolymphatic mastoid shunt surgery in the era of transtympanic perfusion strategies. *Ann Otol Rhinol Laryngol.* 2008 Dec;117(12):871-5. DOI: 10.1177/000348940811701201
95. Sood AJ, Lambert PR, Nguyen SA, Meyer TA. Endolymphatic sac surgery for Ménière's disease: a systematic review and meta-analysis. *Otol Neurotol.* 2014 Jul;35(6):1033-45. DOI: 10.1097/MAO.0000000000000324
96. Thorp MA, Shehab ZP, Bance ML, Rutka JA; AAO-HNS Committee on Hearing and Equilibrium. The AAO-HNS Committee on Hearing and Equilibrium guidelines for the diagnosis and evaluation of therapy in Ménière's disease: have they been applied in the published literature of the last decade? *Clin Otolaryngol Allied Sci.* 2003 Jun;28(3):173-6. DOI: 10.1046/j.1365-2273.2003.00687.x
97. Schwager K, Baier G, El-Din N, Shehata-Dieler W, Carducci F, Helms J. Revision surgery after sacotomy for Meniere's disease: does it make sense? *Eur Arch Otorhinolaryngol.* 2002 May;259(5):239-42. DOI: 10.1007/s00405-002-0447-0
98. Paparella MM. Revision of endolymphatic sac surgery for recurrent Meniere's disease. *Otolaryngol Clin North Am.* 2002;35:607-19.

99. Paparella MM, Sajjadi H. Endolymphatic sac revision for recurrent Ménière's disease. *Am J Otol.* 1988 Nov;9(6):441-7.
100. Silverstein H, Lewis WB, Jackson LE, Rosenberg SI, Thompson JH, Hoffmann KK. Changing trends in the surgical treatment of Ménière's disease: results of a 10-year survey. *Ear Nose Throat J.* 2003 Mar;82(3):185-7, 191-4.
101. Durland WF Jr, Pyle GM, Connor NP. Endolymphatic sac decompression as a treatment for Meniere's disease. *Laryngoscope.* 2005 Aug;115(8):1454-7. DOI: 10.1097/01.mig.0000171017.41592.d0
102. Kitahara T, Horii A, Imai T, Ohta Y, Morihana T, Inohara H, Sakagami M. Does endolymphatic sac decompression surgery prevent bilateral development of unilateral Ménière disease? *Laryngoscope.* 2014 Aug;124(8):1932-6. DOI: 10.1002/lary.24614
103. Sajjadi H, Paparella MM, Williams T. Endolymphatic sac enhancement surgery in elderly patients with Ménière's disease. *Ear Nose Throat J.* 1998 Dec;77(12):975-82.
104. Saliba I, Gabra N, Alzahrani M, Berbiche D. Endolymphatic duct blockage: a randomized controlled trial of a novel surgical technique for Ménière's disease treatment. *Otolaryngol Head Neck Surg.* 2015 Jan;152(1):122-9. DOI: 10.1177/0194599814555840
105. Arnold W, Altermatt HJ. The significance of the human endolymphatic sac and its possible role in Ménière's disease. *Acta Otolaryngol Suppl.* 1995;519:36-42. DOI: 10.3109/00016489509121868
106. Volkenstein S, Gürkov R. Meniere's disease: new surgical therapy animates old discussion. *Laryngo Rhino Otol.* 2015;94:728-9.
107. Kusunoki T, Cureoglu S, Schachern PA, Baba K, Kariya S, Sampaio A, Paparella MM. Effects of gentamicin on sensorineural elements of the cochlea in human temporal bones. *Am J Otolaryngol.* 2004 Sep-Oct;25(5):313-7. DOI: 10.1016/j.amjoto.2004.04.002
108. Izak A, Fick N. Ménière's disease: aetiology and a new surgical approach: sacculotomy. (Decompression of the labyrinth). *J Laryngol Otol.* 1966 Mar;80(3):288-306. DOI: 10.1017/S0022215100065245
109. Fick IA. Decompression of the Labyrinth: A new surgical procedure for Meniere's disease. *Arch Otolaryngol.* 1964 May;79:447-58. DOI: 10.1001/archotol.1964.00750030458005
110. van Fick IA. Symposium: management of Ménière's disease. VI. Sacculotomy for hydrops. *Laryngoscope.* 1965 Oct;75(10):1539-46.
111. Cody DT, Simonton KM, Hallberg OE. Automatic repetitive decompression of the sacculle in endolymphatic hydrops (tack operation). Preliminary report. *Laryngoscope.* 1967 Aug;77(8):1480-501. DOI: 10.1288/00005537-196708000-00017
112. Schuknecht HF. Cochleosacculotomy for Meniere's disease: theory, technique and results. *Laryngoscope.* 1982 Aug;92(8 Pt 1):853-8. DOI: 10.1288/00005537-198208000-00004
113. Dionne J. Cochleosacculotomy. *J Otolaryngol.* 1985 Feb;14(1):59-61.
114. Giddings NA, Shelton C, O'Leary MJ, Brackmann DE. Cochleosacculotomy Revisited: Long-term Results Poorer Than Expected. *Arch Otolaryngol Head Neck Surg.* 1991 Oct;117(10):1150-2. DOI: 10.1001/archotol.1991.01870220098017
115. Kinney WC, Nalepa N, Hughes GB, Kinney SE. Cochleosacculotomy for the treatment of Ménière's disease in the elderly patient. *Laryngoscope.* 1995 Sep;105(9 Pt 1):934-7. DOI: 10.1288/00005537-199509000-00012
116. Wielinga EW, Smyth GD. Long-term results of sacculotomy in older patients. *Ann Otol Rhinol Laryngol.* 1989 Oct;98(10):803-6. DOI: 10.1177/000348948909801010
117. Soheilipour S, Abtahi SH, Soltani M, Khodadadi HA. Comparison the results of two different vestibular system surgery in patients with persistent Meniere's disease. *Adv Biomed Res.* 2015;4:198. DOI: 10.4103/2277-9175.166134
118. Vibert D, Caversaccio M, Häusler R. Meniere's disease in the elderly. *Otolaryngol Clin North Am.* 2010 Oct;43(5):1041-6. DOI: 10.1016/j.otc.2010.05.009
119. Jackler RK, Whinney D. A century of eighth nerve surgery. *Otol Neurotol.* 2001;22:401-16. DOI: 10.1097/00129492-200105000-00023
120. Frazier CH. Intracranial division of the auditory nerve for persistent aural vertigo. *Surg Gynecol Obstet.* 1912;15:524-9.
121. Dandy WE. Meniere's disease: its diagnosis and method of treatment. *Arch Surg.* 1928;16:1127-52. DOI: 10.1001/archsurg.1928.01440060002001
122. McKenzie KG. Intracranial Division of the Vestibular Portion of the Auditory Nerve for Ménière's Disease. *Can Med Assoc J.* 1936 Apr;34(4):369-81.
123. Greene RE. Surgical treatment of vertigo, with follow-up on Walter Dandy's cases. *Clin Neurosurg.* 1958;6:141-52. DOI: 10.1093/neurosurgery/6.CN_suppl_1.141
124. House WF. Surgical exposure of the internal auditory canal and its contents through the middle, cranial fossa. *Laryngoscope.* 1961 Nov;71:1363-85. DOI: 10.1288/00005537-196111000-00004
125. Fisch U. Vestibular and cochlear neurectomy. *Trans Am Acad Ophthalmol Otolaryngol.* 1974 Jul-Aug;78(4):ORL252-5.
126. Fisch U. Transtemporal supralabyrinthine (middle cranial fossa) vestibular neurectomy: a review of the last 100 cases. *Skull Base Surg.* 1996;6(4):221-5.
127. Silverstein H, Norrell H. Retrolabyrinthine surgery: a direct approach to the cerebellopontine angle. *Otolaryngol Head Neck Surg.* 1980 Jul-Aug;88(4):462-9.
128. Brémond G, Magnan J, Milliet JR. La neurotomie vestibulaire par voie postérieure rétro-sigmoïde. Technique, résultats et indications [Vestibular neurotomy by the posterior retrosinus approach. Technics, results and indications]. *Ann Otolaryngol Chir Cervicofac.* 1984;101(2):103-7.
129. Silverstein H, Norrell H, Smouha EE. Retrosigmoid-internal auditory canal approach vs. retrolabyrinthine approach for vestibular neurectomy. *Otolaryngol Head Neck Surg.* 1987 Sep;97(3):300-7. DOI: 10.1177/019459988709700309
130. Silverstein H, Norrell H, Smouha E, Jones R. Combined retrolab-retrosigmoid vestibular neurectomy. An evolution in approach. *Am J Otol.* 1989 May;10(3):166-9.
131. Reid CB, Eisenberg R, Halmagyi GM, Fagan PA. The outcome of vestibular nerve section for intractable vertigo: the patient's point of view. *Laryngoscope.* 1996 Dec;106(12 Pt 1):1553-6.
132. Pappas DG Jr, Pappas DG Sr. Vestibular nerve section: long-term follow-up. *Laryngoscope.* 1997;107:1203-9. DOI: 10.1097/00005537-199709000-00009
133. De Diego JI, Prim MP, Melcon E, de Sarriá MJ, Gavilán J. Result of middle fossa vestibular neurectomy in Meniere's disease. *Acta Otorrinolaringol Esp.* 2001;52:283-6. DOI: 10.1016/S0001-6519(01)78209-X
134. Nakahara H, Takemori S, Seki Y, Umezu H. Hearing changes and questionnaire responses in patients with paramedian suboccipital vestibular neurectomy. *Acta Otolaryngol Suppl.* 2001;545:108-12.

135. Schlegel M, Vibert D, Ott SR, Häusler R, Caversaccio MD. Functional results and quality of life after retrosigmoid vestibular neurectomy in patients with Ménière's disease. *Otol Neurotol*. 2012 Oct;33(8):1380-5. DOI: 10.1097/MAO.0b013e318268d1cd
136. Quaranta A, Onofri M, Sallustio V, Iurato S. Comparison of long-term hearing results after vestibular neurectomy, endolymphatic mastoid shunt, and medical therapy. *Am J Otol*. 1997 Jul;18(4):444-8.
137. Schmerber S, Dumas G, Morel N, Chahine K, Karkas A. Vestibular neurectomy vs. chemical labyrinthectomy in the treatment of disabling Ménière's disease: a long-term comparative study. *Auris Nasus Larynx*. 2009 Aug;36(4):400-5. DOI: 10.1016/j.anl.2008.08.001
138. Göksu N, Bayazit YA, Abdulhalik A, Kemalolu YK. Vestibular neurectomy with simultaneous endolymphatic subarachnoid shunt. *Eur Arch Otorhinolaryngol*. 2002 May;259(5):243-6. DOI: 10.1007/s00405-002-0452-3
139. Moody-Antonio S, House JW. Hearing outcome after concurrent endolymphatic shunt and vestibular nerve section. *Otol Neurotol*. 2003 May;24(3):453-9. DOI: 10.1097/00129492-200305000-00016
140. Setty P, Babu S, LaRouere MJ, Pieper DR. Fully Endoscopic Retrosigmoid Vestibular Nerve Section for Refractory Meniere Disease. *J Neurol Surg B Skull Base*. 2016 Aug;77(4):341-9. DOI: 10.1055/s-0035-1570348
141. Fisch U. Vestibular nerve section for Meniere's disease. *Am J Otol*. 1984 Oct;5(6):543-5.
142. Sargent EW, Liao E, Gonda RL Jr. Cochlear Patency After Transmastoid Labyrinthectomy for Ménière's Syndrome. *Otol Neurotol*. 2016 Aug;37(7):937-9. DOI: 10.1097/MAO.0000000000001105
143. Lake R. Removal of the semicircular canals in a case of uni-lateral aural vertigo. *Lancet*. 1904;1:1567-8. DOI: 10.1016/S0140-6736(00)78786-1
144. Cawthorne TE, Hallpike CS. Some Recent Work on the Investigation and Treatment of "Ménière's" Disease. *Proc R Soc Med*. 1943 Aug;36(10):533-50.
145. Day KM. Surgical treatment of hydrops of the labyrinth; surgical destruction of the labyrinth for Ménière's disease. *Laryngoscope*. 1952 Jun;62(6):547-55. DOI: 10.1288/00005537-195206000-00001
146. Jones R, Silverstein H, Smouha E. Long-term results of transmeatal cochleovestibular neurectomy: an analysis of 100 cases. *Otolaryngol Head Neck Surg*. 1989 Jan;100(1):22-9. DOI: 10.1177/019459988910000104
147. Langman AW, Lindeman RC. Surgery for vertigo in the nonserviceable hearing ear: transmastoid labyrinthectomy or translabyrinthine vestibular nerve section. *Laryngoscope*. 1993 Dec;103(12):1321-5. DOI: 10.1288/00005537-199312000-00001
148. Gacek RR, Gacek MR. Comparison of labyrinthectomy and vestibular neurectomy in the control of vertigo. *Laryngoscope*. 1996 Feb;106(2 Pt 1):225-30. DOI: 10.1097/00005537-199602000-00023
149. Eisenman DJ, Speers R, Telian SA. Labyrinthectomy versus vestibular neurectomy: long-term physiologic and clinical outcomes. *Otol Neurotol*. 2001 Jul;22(4):539-48. DOI: 10.1097/00129492-200107000-00022
150. Schwaber MK, Pensak ML, Reiber ME. Transmastoid labyrinthectomy in older patients. *Laryngoscope*. 1995 Nov;105(11):1152-4. DOI: 10.1288/00005537-199511000-00002
151. Langman AW, Lindeman RC. Surgical labyrinthectomy in the older patient. *Otolaryngol Head Neck Surg*. 1998;118:739-42. DOI: 10.1016/S0194-5998(98)70261-X
152. Lehner AA, Bonnet R, Linder TE. Klinische Aspekte der Cochleaimplantation bei Morbus Ménière sowie nach Labyrinthektomie [Clinical Aspects of Cochlear Implantation in Meniere's Disease and After Labyrinthectomy]. *Laryngorhinootologie*. 2016 Dec;95(12):831-36. DOI: 10.1055/s-0042-100283
153. Belal A, Ylikoski J. Pathology as it relates to ear surgery II. Labyrinthectomy. *J Laryngol Otol*. 1983 Jan;97(1):1-10. DOI: 10.1017/S0022215100093737
154. Chen DA, Linthicum FH Jr, Rizer FM. Cochlear histopathology in the labyrinthectomized ear: implications for cochlear implantation. *Laryngoscope*. 1988 Nov;98(11):1170-2. DOI: 10.1288/00005537-198811000-00004
155. Charlett SD, Biggs N. The Prevalence of Cochlear Obliteration After Labyrinthectomy Using Magnetic Resonance Imaging and the Implications for Cochlear Implantation. *Otol Neurotol*. 2015 Sep;36(8):1328-30. DOI: 10.1097/MAO.0000000000000803
156. Stahle J. Advanced Meniere's disease. A study of 356 severely disabled patients. *Acta Otolaryngol*. 1976;81:113-9. DOI: 10.3109/00016487609107484
157. Lustig LR, Yeagle J, Niparko JK, Minor LB. Cochlear implantation in patients with bilateral Ménière's syndrome. *Otol Neurotol*. 2003 May;24(3):397-403. DOI: 10.1097/00129492-200305000-00009
158. Osborn HA, Yeung R, Lin VY. Delayed cochlear implantation after surgical labyrinthectomy. *J Laryngol Otol*. 2012 Jan;126(1):63-5. DOI: 10.1017/S0022215111002374
159. Hansen MR, Gantz BJ, Dunn C. Outcomes after cochlear implantation for patients with single-sided deafness, including those with recalcitrant Ménière's disease. *Otol Neurotol*. 2013 Dec;34(9):1681-7. DOI: 10.1097/MAO.000000000000102
160. MacKeith SA, Bottrill LD, Ramsden JD. Simultaneous labyrinthectomy with cochlear implantation in patients with bilateral Ménière's disease. *Ann Otol Rhinol Laryngol*. 2014 Jul;123(7):485-9. DOI: 10.1177/0003489414527226
161. Heywood RL, Atlas MD. Simultaneous cochlear implantation and labyrinthectomy for advanced Ménière's disease. *J Laryngol Otol*. 2016 Feb;130(2):204-6. DOI: 10.1017/S0022215115003345
162. Snow JB Jr, Kimmelman CP. Assessment of surgical procedures for Ménière's disease. *Laryngoscope*. 1979 May;89(5 Pt 1):737-47.
163. Graham MD, Goldsmith MM. Labyrinthectomy. Indications and surgical technique. *Otolaryngol Clin North Am*. 1994 Apr;27(2):325-35.
164. Silverstein H, Willcox TO Jr. Vestibular nerve section. *Otolaryngol Clin North Am*. 1994 Apr;27(2):347-62.
165. De La Cruz A, Borne Teufert K, Berliner KI. Transmastoid labyrinthectomy versus translabyrinthine vestibular nerve section: does cutting the vestibular nerve make a difference in outcome? *Otol Neurotol*. 2007 Sep;28(6):801-8. DOI: 10.1097/MAO.0b013e3180a726af
166. Balkany TJ, Sires B, Arenberg IK. Bilateral aspects of Meniere's disease: an underestimated clinical entity. *Otolaryngol Clin North Am*. 1980 Nov;13(4):603-9.
167. Paparella MM, Griebie MS. Bilaterality of Meniere's disease. *Acta Otolaryngol*. 1984 Mar-Apr;97(3-4):233-7. DOI: 10.3109/00016488409130984
168. Stahle J, Friberg U, Svedberg A. Long-term progression of Ménière's disease. *Acta Otolaryngol Suppl*. 1991;485:78-83. DOI: 10.3109/00016489109128047

169. Havia M, Kentala E. Progression of symptoms of dizziness in Ménière's disease. *Arch Otolaryngol Head Neck Surg.* 2004 Apr;130(4):431-5. DOI: 10.1001/archotol.130.4.431
170. Rosenberg S, Silverstein H, Flanzer J, Wanamaker H. Bilateral Ménière's disease in surgical versus nonsurgical patients. *Am J Otol.* 1991 Sep;12(5):336-40.
171. Rah YC, Han JJ, Park J, Choi BY, Koo JW. Management of intractable Ménière's disease after intratympanic injection of gentamicin. *Laryngoscope.* 2015 Apr;125(4):972-8. DOI: 10.1002/lary.25009
172. Minor LB, Solomon D, Zinreich JS, Zee DS. Sound- and/or pressure-induced vertigo due to bone dehiscence of the superior semicircular canal. *Arch Otolaryngol Head Neck Surg.* 1998 Mar;124(3):249-58. DOI: 10.1001/archotol.124.3.249
173. Minor LB. Clinical manifestations of superior semicircular canal dehiscence. *Laryngoscope.* 2005 Oct;115(10):1717-27. DOI: 10.1097/01.mig.0000178324.55729.b7
174. Minor LB. Superior canal dehiscence syndrome. *Am J Otol.* 2000;21:9-19. DOI: 10.1016/S0196-0709(00)80105-2
175. Tullio P. *Das Ohr und die Entstehung der Sprache und Schrift.* Berlin: Urban & Schwarzenberg; 1929.
176. Huizinga E. On the sound reactions of Tullio. *Acta Otolaryngol (Stockh).* 1935;22(3):359-70. DOI: 10.3109/00016483509118116
177. Eunen AJH, Huizinga HC, Huizinga E. Die Tulliosche Reaktion in Zusammenhang mit der Funktion des Mittelohres. *Acta Otolaryngol.* 1943;31(3-4):265-339. DOI: 10.3109/00016484309123252
178. Hennebert C. Labyrinthine double reflex moteur otoculaire. *Clinique.* 1905;19:214-5.
179. Gopen Q, Zhou G, Poe D, Kenna M, Jones D. Posterior semicircular canal dehiscence: first reported case series. *Otol Neurotol.* 2010 Feb;31(2):339-44. DOI: 10.1097/MAO.0b013e3181be65a4
180. Chien WW, Carey JP, Minor LB. Canal dehiscence. *Curr Opin Neurol.* 2011 Feb;24(1):25-31. DOI: 10.1097/WCO.0b013e328341ef88
181. Russo JE, Crowson MG, DeAngelo EJ, Belden CJ, Saunders JE. Posterior semicircular canal dehiscence: CT prevalence and clinical symptoms. *Otol Neurotol.* 2014 Feb;35(2):310-4. DOI: 10.1097/MAO.0000000000000183
182. Spasic M, Trang A, Chung LK, Ung N, Thill K, Zarinkhou G, Gopen QS, Yang I. Clinical Characteristics of Posterior and Lateral Semicircular Canal Dehiscence. *J Neurol Surg B Skull Base.* 2015 Dec;76(6):421-5. DOI: 10.1055/s-0035-1551667
183. Zhou G, Poe DS. Multiple semicircular canals with dehiscence. *Otol Neurotol.* 2009 Feb;30(2):241-2. DOI: 10.1097/MAO.0b013e3181662cd4
184. Cawthorne T. Some observations on the pathology and surgical treatment of labyrinthine vertigo of non-infective origin. *Ann R Coll Surg Engl.* 1949 Jun;4(6):342-59.
185. Mikulec AA, McKenna MJ, Ramsey MJ, Rosowski JJ, Herrmann BS, Rauch SD, Curtin HD, Merchant SN. Superior semicircular canal dehiscence presenting as conductive hearing loss without vertigo. *Otol Neurotol.* 2004 Mar;25(2):121-9. DOI: 10.1097/00129492-200403000-00007
186. Sohmer H, Freeman S, Perez R. Semicircular canal fenestration - improvement of bone- but not air-conducted auditory thresholds. *Hear Res.* 2004 Jan;187(1-2):105-10. DOI: 10.1016/S0378-5955(03)00335-6
187. Merchant SN, Rosowski JJ. Conductive hearing loss caused by third-window lesions of the inner ear. *Otol Neurotol.* 2008 Apr;29(3):282-9. DOI: 10.1097/mao.0b013e318161ab24
188. Nikkar-Esfahani A, Whelan D, Banerjee A. Occlusion of the round window: a novel way to treat hyperacusis symptoms in superior semicircular canal dehiscence syndrome. *J Laryngol Otol.* 2013 Jul;127(7):705-7. DOI: 10.1017/S0022215113001096
189. Rosowski JJ, Songer JE, Nakajima HH, Brinsko KM, Merchant SN. Clinical, experimental, and theoretical investigations of the effect of superior semicircular canal dehiscence on hearing mechanisms. *Otol Neurotol.* 2004 May;25(3):323-32. DOI: 10.1097/00129492-200405000-00021
190. Songer JE, Rosowski JJ. The effect of superior canal dehiscence on cochlear potential in response to air-conducted stimuli in chinchilla. *Hear Res.* 2005 Dec;210(1-2):53-62. DOI: 10.1016/j.heares.2005.07.003
191. Songer JE, Rosowski JJ. A mechano-acoustic model of the effect of superior canal dehiscence on hearing in chinchilla. *J Acoust Soc Am.* 2007 Aug;122(2):943-51. DOI: 10.1121/1.2747158
192. Hirvonen TP, Carey JP, Liang CJ, Minor LB. Superior canal dehiscence: mechanisms of pressure sensitivity in a chinchilla model. *Arch Otolaryngol Head Neck Surg.* 2001 Nov;127(11):1331-6. DOI: 10.1001/archotol.127.11.1331
193. Hegemann SC, Carey JP. Is superior canal dehiscence congenital or acquired? A case report and review of the literature. *Otolaryngol Clin North Am.* 2011 Apr;44(2):377-82, ix. DOI: 10.1016/j.otc.2011.01.009
194. Chilvers G, McKay-Davies I. Recent advances in superior semicircular canal dehiscence syndrome. *J Laryngol Otol.* 2015 Mar;129(3):217-25. DOI: 10.1017/S0022215115000183
195. Zhou G, Gopen Q, Poe DS. Clinical and diagnostic characterization of canal dehiscence syndrome: a great otologic mimicker. *Otol Neurotol.* 2007 Oct;28(7):920-6. DOI: 10.1097/MAO.0b013e31814b25f2
196. Teixeira MT, Artz GJ, Kung BC. Clinical experience with symptomatic superior canal dehiscence in a single neurotologic practice. *Otolaryngol Head Neck Surg.* 2008 Sep;139(3):405-13. DOI: 10.1016/j.otohns.2008.06.023
197. Silverstein H, Kartush JM, Parnes LS, Poe DS, Babu SC, Levenson MJ, Wazen J, Ridley RW. Round window reinforcement for superior semicircular canal dehiscence: a retrospective multi-center case series. *Am J Otolaryngol.* 2014 May-Jun;35(3):286-93. DOI: 10.1016/j.amjoto.2014.02.016
198. House JW, Sheehy JL, Antunez JC. Stapedectomy in children. *Laryngoscope.* 1980 Nov;90(11 Pt 1):1804-9. DOI: 10.1016/j.amjoto.2014.02.016
199. Smullen JL, Andrist EC, Gianoli GJ. Superior semicircular canal dehiscence: a new cause of vertigo. *J La State Med Soc.* 1999 Aug;151(8):397-400.
200. Brantberg K, Bergenius J, Tribukait A. Vestibular-evoked myogenic potentials in patients with dehiscence of the superior semicircular canal. *Acta Otolaryngol.* 1999;119(6):633-40. DOI: 10.1080/00016489950180559
201. Mong A, Loevner LA, Solomon D, Bigelow DC. Sound- and pressure-induced vertigo associated with dehiscence of the roof of the superior semicircular canal. *AJNR Am J Neuroradiol.* 1999 Nov-Dec;20(10):1973-5.
202. Benamira LZ, Maniakas A, Alzahrani M, Saliba I. Common features in patients with superior canal dehiscence declining surgical treatment. *J Clin Med Res.* 2015 May;7(5):308-14. DOI: 10.14740/jocmr2105w
203. Crane BT, Minor LB, Carey JP. Superior canal dehiscence plugging reduces dizziness handicap. *Laryngoscope.* 2008 Oct;118(10):1809-13. DOI: 10.1097/MLG.0b013e31817f18fa

204. Mueller SA, Vibert D, Haeusler R, Raabe A, Caversaccio M. Surgical capping of superior semicircular canal dehiscence. *Eur Arch Otorhinolaryngol*. 2014 Jun;271(6):1369-74. DOI: 10.1007/s00405-013-2533-x
205. Zhao YC, Somers T, van Dinther J, Vanspauwen R, Husseman J, Briggs R. Transmastoid repair of superior semicircular canal dehiscence. *J Neurol Surg B Skull Base*. 2012 Aug;73(4):225-9. DOI: 10.1055/s-0032-1312713
206. Deschenes GR, Hsu DP, Megerian CA. Outpatient repair of superior semicircular canal dehiscence via the transmastoid approach. *Laryngoscope*. 2009 Sep;119(9):1765-9. DOI: 10.1002/lary.20543
207. Peterson EC, Lazar DA, Nemecek AN, Duckert L, Rostomily R. Superior semicircular canal dehiscence syndrome: Successful treatment with repair of the middle fossa floor: technical case report. *Neurosurgery*. 2008 Dec;63(6):E1207-8; discussion E1208. DOI: 10.1227/01.NEU.0000335179.02759.A8
208. Liming BJ, Westbrook B, Bakken H, Crawford JV. Cadaveric Study of an Endoscopic Keyhole Middle Fossa Craniotomy Approach to the Superior Semicircular Canal. *Otol Neurotol*. 2016 Jun;37(5):533-8. DOI: 10.1097/MAO.0000000000000995
209. Mikulec AA, Poe DS, McKenna MJ. Operative management of superior semicircular canal dehiscence. *Laryngoscope*. 2005 Mar;115(3):501-7. DOI: 10.1097/01.mlg.0000157844.48036.e7
210. Ramsey MJ, McKenna MJ, Barker FG 2nd. Superior semicircular canal dehiscence syndrome. Case report. *J Neurosurg*. 2004 Jan;100(1):123-4. DOI: 10.3171/jns.2004.100.1.0123
211. Friedland DR, Michel MA. Cranial thickness in superior canal dehiscence syndrome: implications for canal resurfacing surgery. *Otol Neurotol*. 2006 Apr;27(3):346-54. DOI: 10.1097/00129492-200604000-00010
212. Agrawal SK, Parnes LS. Transmastoid superior semicircular canal occlusion. *Otol Neurotol*. 2008 Apr;29(3):363-7. DOI: 10.1097/mao.0b013e3181616c9d
213. Fiorino F, Barbieri F, Pizzini FB, Beltramello A. A dehiscent superior semicircular canal may be plugged and resurfaced via the transmastoid route. *Otol Neurotol*. 2010 Jan;31(1):136-9. DOI: 10.1097/MAO.0b013e3181b76b9e
214. Crovetto M, Areitio E, Elexpuru J, Aguayo F. Transmastoid approach for resurfacing of Superior Semicircular Canal dehiscence. *Auris Nasus Larynx*. 2008 Jun;35(2):247-9. DOI: 10.1016/j.anl.2007.06.010
215. Amodi HA, Makki FM, McNeil M, Bance M. Transmastoid resurfacing of superior semicircular canal dehiscence. *Laryngoscope*. 2011 May;121(5):1117-23. DOI: 10.1002/lary.21398
216. Wijaya C, Dias A, Conlon BJ. Superior semicircular canal occlusion-Transmastoid approach. *Int J Surg Case Rep*. 2012;3(2):42-4. DOI: 10.1016/j.ijscr.2011.09.003
217. Ma XB, Zeng R, Wang GP, Gong SS. Transmastoid approach for resurfacing the superior semicircular canal dehiscence with a dumpling structure. *Chin Med J*. 2015 Jun;128(11):1490-5. DOI: 10.4103/0366-6999.157657
218. Silverstein H, Van Ess MJ. Complete round window niche occlusion for superior semicircular canal dehiscence syndrome: a minimally invasive approach. *Ear Nose Throat J*. 2009 Aug;88(8):1042-56.
219. Shaia WT, Diaz RC. Evolution in surgical management of superior canal dehiscence syndrome. *Curr Opin Otolaryngol Head Neck Surg*. 2013 Oct;21(5):497-502. DOI: 10.1097/M00.0b013e328364b3ff
220. Carter MS, Lookabaugh S, Lee DJ. Endoscopic-assisted repair of superior canal dehiscence syndrome. *Laryngoscope*. 2014 Jun;124(6):1464-8. DOI: 10.1002/lary.24523
221. Fukamachi A, Koizumi H, Nagaseki Y, Nukui H. Postoperative extradural hematomas: computed tomographic survey of 1105 intracranial operations. *Neurosurgery*. 1986 Oct;19(4):589-93. DOI: 10.1227/00006123-198610000-00013
222. Niesten ME, McKenna MJ, Grolman W, Lee DJ. Clinical factors associated with prolonged recovery after superior canal dehiscence surgery. *Otol Neurotol*. 2012 Jul;33(5):824-31. DOI: 10.1097/MAO.0b013e3182544c9e
223. Kvam DA, Loftus CM, Copeland B, Quest DO. Seizures during the immediate postoperative period. *Neurosurgery*. 1983 Jan;12(1):14-7. DOI: 10.1227/00006123-198301000-00003
224. Yamakami I, Serizawa T, Yamaura A, Nakamura T. Cerebrospinal fluid leak after cranial base surgery. *No Shinkei Geka*. 1996 Jan;24(1):29-33.
225. Angeli S. Middle fossa approach: indications, technique, and results. *Otolaryngol Clin North Am*. 2012 Apr;45(2):417-38. ix. DOI: 10.1016/j.otc.2011.12.010
226. Schick B, Greess H, Gill S, Pauli E, Iro H. Magnetic resonance imaging and neuropsychological testing after middle fossa vestibular schwannoma surgery. *Otol Neurotol*. 2008 Jan;29(1):39-45. DOI: 10.1097/mao.0b013e31815c2ad7
227. Ward BK, Wenzel A, Ritzl EK, Gutierrez-Hernandez S, Della Santina CC, Minor LB, Carey JP. Near-dehiscence: clinical findings in patients with thin bone over the superior semicircular canal. *Otol Neurotol*. 2013 Oct;34(8):1421-8. DOI: 10.1097/MAO.0b013e318287efe6
228. Limb CJ, Carey JP, Srireddy S, Minor LB. Auditory function in patients with surgically treated superior semicircular canal dehiscence. *Otol Neurotol*. 2006 Oct;27(7):969-80. DOI: 10.1097/01.mao.0000235376.70492.8e
229. Gianoli GJ. Deficiency of the superior semicircular canal. *Curr Opin Otolaryngol Head Neck Surg*. 2001;9(5):336-41. DOI: 10.1097/00020840-200110000-00016
230. Gioacchini FM, Alicandri-Ciuffelli M, Kaleci S, Scarpa A, Cassandro E, Re M. Outcomes and complications in superior semicircular canal dehiscence surgery: A systematic review. *Laryngoscope*. 2016 May;126(5):1218-24. DOI: 10.1002/lary.25662
231. Chung LK, Ung N, Spasic M, Nagasawa DT, Pelargos PE, Thill K, Voth B, Hirt D, Gopen Q, Yang I. Clinical outcomes of middle fossa craniotomy for superior semicircular canal dehiscence repair. *J Neurosurg*. 2016 Nov;125(5):1187-93. DOI: 10.3171/2015.8.JNS15391
232. Hahn Y, Zappia J. Modified resurfacing repair for superior semicircular canal dehiscence. *Otolaryngol Head Neck Surg*. 2010 May;142(5):763-4. DOI: 10.1016/j.otohns.2010.01.011
233. Beyea JA, Agrawal SK, Parnes LS. Transmastoid semicircular canal occlusion: a safe and highly effective treatment for benign paroxysmal positional vertigo and superior canal dehiscence. *Laryngoscope*. 2012 Aug;122(8):1862-6. DOI: 10.1002/lary.23390
234. Lundy L, Zapala D, Moushey J. Cartilage cap occlusion technique for dehiscent superior semicircular canals. *Otol Neurotol*. 2011 Oct;32(8):1281-4. DOI: 10.1097/MAO.0b013e31822e5b27
235. Brantberg K, Bergenius J, Mendel L, Witt H, Tribukait A, Ygge J. Symptoms, findings and treatment in patients with dehiscence of the superior semicircular canal. *Acta Otolaryngol*. 2001 Jan;121(1):68-75. DOI:10.1080/000164801300006308
236. Mikulec AA, Poe DS. Operative management of a posterior semicircular canal dehiscence. *Laryngoscope*. 2006 Mar;116(3):375-8. DOI: 10.1097/01.mlg.0000200358.93385.5c

237. Vlastarakos PV, Proikas K, Tavoulari E, Kikidis D, Maragoudakis P, Nikolopoulos TP. Efficacy assessment and complications of surgical management for superior semicircular canal dehiscence: a meta-analysis of published interventional studies. *Eur Arch Otorhinolaryngol.* 2009 Feb;266(2):177-86. DOI: 10.1007/s00405-008-0840-4
238. Carey JP, Migliaccio AA, Minor LB. Semicircular canal function before and after surgery for superior canal dehiscence. *Otol Neurotol.* 2007 Apr;28(3):356-64. DOI: 10.1097/O1.mao.0000253284.40995.d8
239. Van Haesendonck G, Van de Heyning P, Van Rompaey V. Retrospective cohort study on hearing outcome after transmastoid plugging in superior semicircular canal dehiscence syndrome: Our Experience. *Clin Otolaryngol.* 2016 Oct;41(5):601-6. DOI: 10.1111/coa.12539
240. Goddard JC, Wilkinson EP. Outcomes following Semicircular Canal Plugging. *Otolaryngol Head Neck Surg.* 2014 Sep;151(3):478-83. DOI: 10.1177/0194599814538233
241. Powell HR, Khalil SS, Saeed SR. Outcomes of Transmastoid Surgery for Superior Semicircular Canal Dehiscence Syndrome. *Otol Neurotol.* 2016 Aug;37(7):e228-33. DOI: 10.1097/MAO.0000000000001103
242. Barber SR, Cheng YS, Owoc M, Lin BM, Remenschneider AK, Kozin ED, Lee DJ. Benign paroxysmal positional vertigo commonly occurs following repair of superior canal dehiscence. *Laryngoscope.* 2016 Sep;126(9):2092-7. DOI: 10.1002/lary.25797
243. Elmali M, Polat AV, Kucuk H, Atmaca S, Aksoy A. Semicircular canal dehiscence: frequency and distribution on temporal bone CT and its relationship with the clinical outcomes. *Eur J Radiol.* 2013 Oct;82(10):e606-9. DOI: 10.1016/j.ejrad.2013.06.022
244. Belden CJ, Weg N, Minor LB, Zinreich SJ. CT evaluation of bone dehiscence of the superior semicircular canal as a cause of sound- and/or pressure-induced vertigo. *Radiology.* 2003 Feb;226(2):337-43. DOI: 10.1148/radiol.2262010897
245. Carey JP, Minor LB, Nager GT. Dehiscence or thinning of bone overlying the superior semicircular canal in a temporal bone survey. *Arch Otolaryngol Head Neck Surg.* 2000 Feb;126(2):137-47.
246. Hillman TA, Kertesz TR, Hadley K, Shelton C. Reversible peripheral vestibulopathy: the treatment of superior canal dehiscence. *Otolaryngol Head Neck Surg.* 2006 Mar;134(3):431-6. DOI: 10.1016/j.otohns.2005.10.033
247. Agrawal Y, Minor LB, Schubert MC, Janky KL, Davalos-Bichara M, Carey JP. Second-side surgery in superior canal dehiscence syndrome. *Otol Neurotol.* 2012 Jan;33(1):72-7. DOI: 10.1097/MAO.0b013e31823c9182
248. Deuschländer A, Strupp M, Jahn K, Jäger L, Quiring F, Brandt T. Vertical oscillopsia in bilateral superior canal dehiscence syndrome. *Neurology.* 2004 Mar;62(5):784-7.
249. Crane BT, Lin FR, Minor LB, Carey JP. Improvement in autophony symptoms after superior canal dehiscence repair. *Otol Neurotol.* 2010 Jan;31(1):140-6.
250. Remenschneider AK, Owoc M, Kozin ED, McKenna MJ, Lee DJ, Jung DH. Health Utility Improves After Surgery for Superior Canal Dehiscence Syndrome. *Otol Neurotol.* 2015 Dec;36(10):1695-701. DOI: 10.1097/MAO.0000000000000886
251. Sharon JD, Pross SE, Ward BK, Carey JP. Revision Surgery for Superior Canal Dehiscence Syndrome. *Otol Neurotol.* 2016 Sep;37(8):1096-103. DOI: 10.1097/MAO.0000000000001113
252. Paladin AM, Phillips GS, Raske ME, Sie KC. Labyrinthine dehiscence in a child. *Pediatr Radiol.* 2008 Mar;38(3):348-50. DOI: 10.1007/s00247-007-0696-6
253. Lee GS, Zhou G, Poe D, Kenna M, Amin M, Ohlms L, Gopen Q. Clinical experience in diagnosis and management of superior semicircular canal dehiscence in children. *Laryngoscope.* 2011 Oct;121(10):2256-61. DOI: 10.1002/lary.22134
254. Zhou G, Ohlms L, Liberman J, Amin M. Superior semicircular canal dehiscence in a young child: implication of developmental defect. *Int J Pediatr Otorhinolaryngol.* 2007 Dec;71(12):1925-8. DOI: 10.1016/j.ijporl.2007.08.009
255. Meiklejohn DA, Corrales CE, Boldt BM, Sharon JD, Yeom KW, Carey JP, Blevins NH. Pediatric Semicircular Canal Dehiscence: Radiographic and Histologic Prevalence, With Clinical Correlation. *Otol Neurotol.* 2015 Sep;36(8):1383-9. DOI: 10.1097/MAO.0000000000000811
256. Chen EY, Paladin A, Phillips G, Raske M, Vega L, Peterson D, Sie KC. Semicircular canal dehiscence in the pediatric population. *Int J Pediatr Otorhinolaryngol.* 2009 Feb;73(2):321-7. DOI: 10.1016/j.ijporl.2008.10.027
257. Saxby AJ, Gowdy C, Fandiño M, Chadha NK, Kozak FK, Sargent MA, Lea J. Radiological prevalence of superior and posterior semicircular canal dehiscence in children. *Int J Pediatr Otorhinolaryngol.* 2015 Mar;79(3):411-8. DOI: 10.1016/j.ijporl.2015.01.001
258. Jackson NM, Allen LM, Morell B, Carpenter CC, Givens VB, Kakade A, Jeyakumar A, Arcement C, Arriaga MA, Ying YL. The relationship of age and radiographic incidence of superior semicircular canal dehiscence in pediatric patients. *Otol Neurotol.* 2015 Jan;36(1):99-105. DOI: 10.1097/MAO.0000000000000660
259. Minor LB. Labyrinthine fistulae: pathobiology and management. *Curr Opin Otolaryngol Head Neck Surg.* 2003 Oct;11(5):340-6. DOI: 10.1097/00020840-200310000-00006
260. Hornibrook J. Perilymph fistula: fifty years of controversy. *ISRN Otolaryngol.* 2012;2012:281248. DOI: 10.5402/2012/281248
261. Harrison WH, Shambaugh GE Jr, Derlacki EL, Clemis JD. Perilymph fistula in stapes surgery. *Laryngoscope.* 1967 May;77(5):836-49. DOI: 10.1288/00005537-196705000-00011
262. Shea JJ. Stapedectomy - long-term report. *Ann Otol Rhinol Laryngol.* 1982 Sep-Oct;91(5 Pt 1):516-20. DOI: 10.1177/000348948209100510
263. Fee GA. Traumatic perilymphatic fistulas. *Arch Otolaryngol.* 1968 Nov;88(5):477-80. DOI: 10.1001/archotol.1968.00770010479005
264. Goodhill V. Sudden deafness and round window rupture. *Laryngoscope.* 1971 Sep;81(9):1462-74. DOI: 10.1288/00005537-197109000-00010
265. Stroud MH, Calcaterra TC. Spontaneous perilymph fistulas. *Laryngoscope.* 1970 Mar;80(3):479-87. DOI: 10.1288/00005537-197003000-00012
266. Ferber-Viart C, Postec F, Duclaux R, Dubreuil C. Perilymphatic fistula following airbag trauma. *Laryngoscope.* 1998 Aug;108(8 Pt 1):1255-7. DOI: 10.1097/00005537-199808000-00033
267. Kung B, Sataloff RT. Noise-induced perilymph fistula. *Ear Nose Throat J.* 2006 Apr;85(4):240-1, 245-6.
268. Meyerhoff WL, Pollock KJ. A patient-oriented approach to perilymph fistula. *Arch Otolaryngol Head Neck Surg.* 1990 Nov;116(11):1317-9. DOI: 10.1001/archotol.1990.01870110089011
269. Shelton C, Simmons FB. Perilymph fistula: the Stanford experience. *Ann Otol Rhinol Laryngol.* 1988 Mar-Apr;97(2 Pt 1):105-8. DOI: 10.1177/000348948809700201
270. Rizer FM, House JW. Perilymph fistulas: the House Ear Clinic experience. *Otolaryngol Head Neck Surg.* 1991 Feb;104(2):239-43. DOI: 10.1177/019459989110400213

271. Black FO, Pesznecker S, Norton T, Fowler L, Lilly DJ, Shupert C, Hemenway WG, Peterka RJ, Jacobson ES. Surgical management of perilymphatic fistulas: a Portland experience. *Am J Otol.* 1992 May;13(3):254-62.
272. Hughes GB, Sismanis A, House JW. Is there consensus in perilymph fistula management? *Otolaryngol Head Neck Surg.* 1990 Feb;102(2):111-7. DOI: 10.1177/019459989010200203
273. Muntarhorn K, Webber PA. Labyrinthine window rupture with round window predominance: a long-term review of 32 cases. *Clin Otolaryngol Allied Sci.* 1987 Apr;12(2):103-8. DOI: 10.1111/j.1365-2273.1987.tb00170.x
274. Black FO, Pesznecker S, Norton T, Fowler L, Lilly DJ, Shupert C, Hemenway WG, Peterka RJ, Jacobson ES. Surgical management of perilymph fistulas. A new technique. *Arch Otolaryngol Head Neck Surg.* 1991 Jun;117(6):641-8. DOI: 10.1001/archotol.1991.01870180077015
275. Friedland DR, Wackym PA. A critical appraisal of spontaneous perilymphatic fistulas of the inner ear. *Am J Otol.* 1999 Mar;20(2):261-76; discussion 276-9.
276. Karhuketo TS, Puhakka HJ. Endoscope-guided round window fistula repair. *Otol Neurotol.* 2001 Nov;22(6):869-73. DOI: 10.1097/00129492-200111000-00027
277. Selmani Z, Pyykkö I, Ishizaki H, Marttila TI. Role of transtympanic endoscopy of the middle ear in the diagnosis of perilymphatic fistula in patients with sensorineural hearing loss or vertigo. *ORL J Otorhinolaryngol Relat Spec.* 2002 Sep-Oct;64(5):301-6. DOI: 10.1159/000066074
278. Shea JJ. The myth of spontaneous perilymph fistula. *Otolaryngol Head Neck Surg.* 1992 Nov;107(5):613-6. DOI: 10.1177/019459989210700501
279. Hakuba N, Hato N, Shinomori Y, Sato H, Gyo K. Labyrinthine fistula as a late complication of middle ear surgery using the canal wall down technique. *Otol Neurotol.* 2002 Nov;23(6):832-5. DOI: 10.1097/00129492-200211000-00003
280. Beleites E, Schumann D, Schneider G, Fried W, Linß W. 3-D-Referenzimplantate für den Gesichts- und Hirnschädel. *Dtsch Arztebl.* 2001;98(5):A-244/B-192/C-180.
281. Sheehy JL, Brackmann DE. Cholesteatoma surgery: management of the labyrinthine fistula—a report of 97 cases. *Laryngoscope.* 1979 Jan;89(1):78-87. DOI: 10.1288/00005537-197901000-00008
282. Sismanis A. Surgical management of common peripheral vestibular diseases. *Curr Opin Otolaryngol Head Neck Surg.* 2010 Oct;18(5):431-5. DOI: 10.1097/M00.0b013e328333de79e
283. Strupp M, Brandt T. Leitsymptom Schwindel: Diagnose und Therapie. *Dtsch Arztebl.* 2008;105(10):173-80. DOI: 10.3238/arztebl.2008.0173
284. Kansu L, Aydin E, Gulsahi K. Benign paroxysmal positional vertigo after nonotologic surgery: case series. *J Maxillofac Oral Surg.* 2015 Mar;14(Suppl 1):113-5. DOI: 10.1007/s12663-012-0356-8
285. Karlberg M, Hall K, Quickert N, Hinson J, Halmagyi GM. What inner ear diseases cause benign paroxysmal positional vertigo? *Acta Otolaryngol.* 2000 Mar;120(3):380-5. DOI: 10.1080/000164800750000603
286. Atacan E, Sennaroglu L, Genc A, Kaya S. Benign paroxysmal positional vertigo after stapedectomy. *Laryngoscope.* 2001 Jul;111(7):1257-9. DOI: 10.1097/00005537-200107000-00021
287. Blankenburg S, Westhofen M. Zur Differenzierung des benignen paroxysmalen Lagerungsschwindels [Differentiation of benign paroxysmal positional vertigo subtypes]. *Laryngorhinootologie.* 2007 Jun;86(6):410-4. DOI: 10.1055/s-2007-982584
288. Leveque M, Labrousse M, Seidermann L, Chays A. Surgical therapy in intractable benign paroxysmal positional vertigo. *Otolaryngol Head Neck Surg.* 2007 May;136(5):693-8. DOI: 10.1016/j.otohns.2006.04.020
289. Silverstein H. Partial or total eighth nerve section in the treatment of vertigo. *Otolaryngology.* 1978 Jan-Feb;86(1):ORL-47-60. DOI: 10.1177/019459987808600111
290. Gacek RR, Gacek MR. Results of singular neurectomy in the posterior ampullary recess. *ORL J Otorhinolaryngol Relat Spec.* 2002 Nov-Dec;64(6):397-402. DOI: 10.1159/000067572
291. Silverstein H, White DW. Wide surgical exposure for singular neurectomy in the treatment of benign positional vertigo. *Laryngoscope.* 1990 Jul;100(7):701-6. DOI: 10.1288/00005537-199007000-00005
292. Epley JM. Singular neurectomy: hypotympanotomy approach. *Otolaryngol Head Neck Surg.* 1980 May-Jun;88(3):304-9. DOI: 10.1177/019459988008800320
293. Fernandes CM. Singular neurectomy in South African practice. *S Afr J Surg.* 1993 Jun;31(2):79-80.
294. Meyerhoff WL. Surgical section of the posterior ampullary nerve. *Laryngoscope.* 1985 Aug;95(8):933-5. DOI: 10.1288/00005537-198508000-00009
295. Häusler R, Pampurik J. Die chirurgische und die physiotherapeutische Behandlung des benignen paroxysmalen Lagerungsschwindels [Surgical and physical therapy treatment of benign paroxysmal positional vertigo]. *Laryngorhinootologie.* 1989 Jun;68(6):349-54. DOI: 10.1055/s-2007-998351
296. Parnes LS, Agrawal SK, Atlas J. Diagnosis and management of benign paroxysmal positional vertigo (BPPV). *CMAJ.* 2003 Sep;169(7):681-93.
297. Pournaras I, Kos I, Guyot JP. Benign paroxysmal positional vertigo: a series of eight singular neurectomies. *Acta Otolaryngol.* 2008 Jan;128(1):5-8. DOI: 10.1080/00016480701275279
298. Okano Y, Sando I, Myers EN. Branch of the singular nerve (posterior ampullary nerve) in the otic capsule. *Ann Otol Rhinol Laryngol.* 1980 Jan-Feb;89(1 Pt 1):13-9. DOI: 10.1177/000348948008900105
299. Leuwer RM, Westhofen M. Surgical anatomy of the singular nerve. *Acta Otolaryngol.* 1996 Jul;116(4):576-80. DOI: 10.3109/00016489609137892
300. Parnes LS, McClure JA. Posterior semicircular canal occlusion for intractable benign paroxysmal positional vertigo. *Ann Otol Rhinol Laryngol.* 1990 May;99(5 Pt 1):330-4. DOI: 10.1177/000348949009900502
301. Parnes LS, McClure JA. Posterior semicircular canal occlusion in the normal hearing ear. *Otolaryngol Head Neck Surg.* 1991 Jan;104(1):52-7. DOI: 10.1177/019459989110400111
302. Pace-Balzan A, Rutka JA. Non-ampullary plugging of the posterior semicircular canal for benign paroxysmal positional vertigo. *J Laryngol Otol.* 1991 Nov;105(11):901-6. DOI: 10.1017/S0022215100117785
303. Dingle AF, Hawthorne MR, Kumar BU. Fenestration and occlusion of the posterior semicircular canal for benign positional vertigo. *Clin Otolaryngol Allied Sci.* 1992 Aug;17(4):300-2. DOI: 10.1111/j.1365-2273.1992.tb01000.x
304. Hawthorne M, el-Naggar M. Fenestration and occlusion of posterior semicircular canal for patients with intractable benign paroxysmal positional vertigo. *J Laryngol Otol.* 1994 Nov;108(11):935-9. DOI: 10.1017/S0022215100128579
305. Zappia JJ. Posterior semicircular canal occlusion for benign paroxysmal positional vertigo. *Am J Otol.* 1996 Sep;17(5):749-54.

306. Walsh RM, Bath AP, Cullen JR, Rutka JA. Long-term results of posterior semicircular canal occlusion for intractable benign paroxysmal positional vertigo. *Clin Otolaryngol Allied Sci.* 1999 Aug;24(4):316-23. DOI: 10.1046/j.1365-2273.1999.00266.x
307. Westhofen PM. Okklusion des posterioren Bogengangs bei therapieresistentem benignem paroxysmalem Lagerungsschwindel (BPLS) [Occlusion of the posterior semicircular canal]. *Laryngorhinootologie.* 2007 Jul;86(7):484-9. DOI: 10.1055/s-2007-980317
308. Kisilevsky V, Bailie NA, Dutt SN, Rutka JA. Lessons learned from the surgical management of benign paroxysmal positional vertigo: the University Health Network experience with posterior semicircular canal occlusion surgery (1988-2006). *J Otolaryngol Head Neck Surg.* 2009 Apr;38(2):212-21.
309. Kartush JM, Sargent EW. Posterior semicircular canal occlusion for benign paroxysmal positional vertigo—CO2 laser-assisted technique: preliminary results. *Laryngoscope.* 1995 Mar;105(3 Pt 1):268-74. DOI: 10.1288/00005537-199503000-00009
310. Ramakrishna J, Goebel JA, Parnes LS. Efficacy and safety of bilateral posterior canal occlusion in patients with refractory benign paroxysmal positional vertigo: case report series. *Otol Neurotol.* 2012 Jun;33(4):640-2. DOI: 10.1097/MAO.0b013e31824bae56
311. Guinand N, Boselie F, Guyot JP, Kingma H. Quality of life of patients with bilateral vestibulopathy. *Ann Otol Rhinol Laryngol.* 2012 Jul;121(7):471-7. DOI: 10.1177/000348941212100708
312. Golub JS, Ling L, Nie K, Nowack A, Shepherd SJ, Bierer SM, Jameyson E, Kaneko CR, Phillips JO, Rubinstein JT. Prosthetic implantation of the human vestibular system. *Otol Neurotol.* 2014 Jan;35(1):136-47. DOI: 10.1097/MAO.0000000000000003
313. van de Berg R, Guinand N, Nguyen TA, Ranieri M, Cavuscens S, Guyot JP, Stokroos R, Kingma H, Perez-Fornos A. The vestibular implant: frequency-dependency of the electrically evoked vestibulo-ocular reflex in humans. *Front Syst Neurosci.* 2014;8:255. DOI: 10.3389/fnsys.2014.00255
314. Guinand N, van de Berg R, Ranieri M, Cavuscens S, DiGiovanna J, Nguyen TA, Micera S, Stokroos R, Kingma H, Guyot JP, Perez Fornos A. Vestibular implants: Hope for improving the quality of life of patients with bilateral vestibular loss. *Conf Proc IEEE Eng Med Biol Soc.* 2015;2015:7192-5. DOI: 10.1109/EMBC.2015.7320051
315. Phillips JO, Ling L, Nie K, Jameyson E, Phillips CM, Nowack AL, Golub JS, Rubinstein JT. Vestibular implantation and longitudinal electrical stimulation of the semicircular canal afferents in human subjects. *J Neurophysiol.* 2015 Jun;113(10):3866-92. DOI: 10.1152/jn.00171.2013
316. Gong W, Merfeld DM. Prototype neural semicircular canal prosthesis using patterned electrical stimulation. *Ann Biomed Eng.* 2000 May;28(5):572-81. DOI: 10.1114/1.293
317. Della Santina C, Migliaccio A, Patel A. Electrical stimulation to restore vestibular function development of a 3-d vestibular prosthesis. *Conf Proc IEEE Eng Med Biol Soc.* 2005;7:7380-5. DOI: 10.1109/IEMBS.2005.1616217
318. Merfeld DM, Haburcakova C, Gong W, Lewis RF. Chronic vestibulo-ocular reflexes evoked by a vestibular prosthesis. *IEEE Trans Biomed Eng.* 2007 Jun;54(6 Pt 1):1005-15. DOI: 10.1109/TBME.2007.891943
319. Dai C, Fridman GY, Chiang B, Rahman MA, Ahn JH, Davidovics NS, Della Santina CC. Directional plasticity rapidly improves 3D vestibulo-ocular reflex alignment in monkeys using a multichannel vestibular prosthesis. *J Assoc Res Otolaryngol.* 2013 Dec;14(6):863-77. DOI: 10.1007/s10162-013-0413-0
320. Merfeld DM, Lewis RF. Replacing semicircular canal function with a vestibular implant. *Curr Opin Otolaryngol Head Neck Surg.* 2012 Oct;20(5):386-92. DOI: 10.1097/M00.0b013e328357630f
321. Nguyen TA, Ranieri M, DiGiovanna J, Peter O, Genovese V, Perez Fornos A, Micera S. A real-time research platform to study vestibular implants with gyroscopic inputs in vestibular deficient subjects. *IEEE Trans Biomed Circuits Syst.* 2014 Aug;8(4):474-84. DOI: 10.1109/TBCAS.2013.2290089
322. Lewis RF, Haburcakova C, Gong W, Lee D, Merfeld D. Electrical stimulation of semicircular canal afferents affects the perception of head orientation. *J Neurosci.* 2013 May;33(22):9530-5. DOI: 10.1523/JNEUROSCI.0112-13.2013
323. Rubinstein JT, Bierer S, Kaneko C, Ling L, Nie K, Oxford T, Newlands S, Santos F, Risi F, Abbas PJ, Phillips JO. Implantation of the semicircular canals with preservation of hearing and rotational sensitivity: a vestibular neurostimulator suitable for clinical research. *Otol Neurotol.* 2012 Jul;33(5):789-96. DOI: 10.1097/MAO.0b013e318254ec24
324. Brackmann DE. The cochlear implant; basic principles. *Laryngoscope.* 1976 Mar;86(3):373-88. DOI: 10.1288/00005537-197603000-00007
325. Shannon RV. Auditory implant research at the House Ear Institute 1989-2013. *Hear Res.* 2015 Apr;322:57-66. DOI: 10.1016/j.heares.2014.11.003

Corresponding author:

Priv.-Doz. Dr. med. Stefan Volkenstein
Department of Otolaryngology, Head & Neck Surgery,
Ruhr-University of Bochum at the St. Elisabeth Hospital
of Bochum, Bleichstr. 15, 44787 Bochum, Germany
stefan.volkenstein@rub.de

Please cite as

Volkenstein S, Dazert S. Recent surgical options for vestibular vertigo. *GMS Curr Top Otorhinolaryngol Head Neck Surg.* 2017;16:Doc01.
DOI: 10.3205/cto000140, URN: urn:nbn:de:0183-cto0001409

This article is freely available from

<http://www.egms.de/en/journals/cto/2017-16/cto000140.shtml>

Published: 2017-12-18

Copyright

©2017 Volkenstein et al. This is an Open Access article distributed under the terms of the Creative Commons Attribution 4.0 License. See license information at <http://creativecommons.org/licenses/by/4.0/>.