



Since January 2020 Elsevier has created a COVID-19 resource centre with free information in English and Mandarin on the novel coronavirus COVID-19. The COVID-19 resource centre is hosted on Elsevier Connect, the company's public news and information website.

Elsevier hereby grants permission to make all its COVID-19-related research that is available on the COVID-19 resource centre - including this research content - immediately available in PubMed Central and other publicly funded repositories, such as the WHO COVID database with rights for unrestricted research re-use and analyses in any form or by any means with acknowledgement of the original source. These permissions are granted for free by Elsevier for as long as the COVID-19 resource centre remains active.



# Peripheral neurological complications during COVID-19: A single center experience

Nara Miriam Michaelson<sup>a,\*</sup>, Ashwin Malhotra<sup>a</sup>, Zehui Wang<sup>a</sup>, Linda Heier<sup>b</sup>, Kurenai Tanji<sup>c</sup>, Scott Wolfe<sup>d</sup>, Alka Gupta<sup>e</sup>, Daniel MacGowan<sup>a</sup>

<sup>a</sup> New York-Presbyterian Hospital/Weill Cornell Medical Center, Department of Neurology, New York, NY, United States of America

<sup>b</sup> New York-Presbyterian Hospital/Weill Cornell Medical Center, Department of Radiology, New York, NY, United States of America

<sup>c</sup> New York-Presbyterian Hospital/Columbia University Medical Center, Departments of Neurology, Pathology, and Cell Biology, New York, NY, United States of America

<sup>d</sup> Hospital for Special Surgery, Weill Cornell Medical College, Department of Orthopedic Surgery, New York, NY, United States of America

<sup>e</sup> New York-Presbyterian Hospital/Weill Cornell Medical Center, Department of Medicine, New York, NY, United States of America

## ARTICLE INFO

### Keywords:

COVID-19

SARS-CoV-2

Brachial plexopathy

Peripheral neuropathy

Entrapment neuropathy

RA02

## ABSTRACT

**Background and aims:** We highlight the peripheral neurologic complications of coronavirus disease 2019 (COVID-19) associated with severe acute respiratory syndrome coronavirus 2 (SARS-CoV-2), an ongoing global health emergency.

**Methods:** We evaluated twenty-five patients admitted to the COVID-19 Recovery Unit (CRU) at New York-Presbyterian Weill Cornell University Medical Center after intensive care hospitalization with confirmed severe acute respiratory syndrome coronavirus-2 (SARS-CoV-2), whom neurology was consulted for weakness and/or paresthesias. All patients were clinically evaluated by a neuromuscular neurologist who performed electrodiagnostic (EDX) studies when indicated. Magnetic resonance imaging (MRI) of the affected regions, along with nerve and muscle biopsies were obtained in select patients to better elucidate the underlying diagnosis.

**Results:** We found fourteen out of twenty-five patients with prolonged hospitalization for COVID-19 infection to have peripheral neurological complications, identified as plexopathies, peripheral neuropathies and entrapment neuropathies. The other eleven patients were not found to have peripheral neurologic causes for their symptoms. Patients with peripheral neurological complications often exhibited more than one type of concurrently. Specifically, there were four cases of plexopathies, nine cases of entrapment neuropathies, and six cases of peripheral neuropathies, which included cranial neuropathy, sciatic neuropathy, and multiple mononeuropathies.

**Conclusions:** We explore the possibility that the idiopathic peripheral neurologic complications could be manifestations of the COVID-19 disease spectrum, possibly resulting from micro-thrombotic induced nerve ischemia.

## 1. Introduction

Many neurological complications of the coronavirus disease 2019 (COVID-19) pandemic, such as encephalitis, ischemic stroke, and acute inflammatory demyelinating polyneuropathy (AIDP) have been documented in the literature [1,2]. However, the full spectrum of peripheral neurological complications of COVID-19 and risk factors have not been well described. Here we present a single center experience as a case series of peripheral neurological complications observed in patients hospitalized with COVID-19.

## 2. Materials and methods

From March to June of two thousand twenty-one, the neurology service evaluated twenty-five patients admitted to the COVID-19 Recovery Unit (CRU) at New York-Presbyterian Weill Cornell University Medical Center after intensive care hospitalization with confirmed severe acute respiratory syndrome coronavirus-2 (SARS-CoV-2), whom neurology was consulted for weakness and/or paresthesias. All patients were clinically evaluated by a neuromuscular neurologist who performed electrodiagnostic (EDX) studies when indicated. Magnetic resonance imaging (MRI) of the affected regions, along with nerve and

\* Corresponding author at: Peripheral Neuropathy Center, New York-Presbyterian Hospital/Weill Cornell Medicine, 1305 York Avenue, 2nd Floor, New York, NY 10021, United States of America.

E-mail address: [nam9193@nyp.org](mailto:nam9193@nyp.org) (N.M. Michaelson).

<https://doi.org/10.1016/j.jns.2021.120118>

Received 19 September 2021; Received in revised form 27 November 2021; Accepted 19 December 2021

Available online 23 December 2021

0022-510X/© 2021 Elsevier B.V. All rights reserved.

muscle biopsies were obtained in select patients to better elucidate the underlying diagnosis.

### 3. Results

Table 1 describes key demographic patient data, comorbidities, inpatient complications, and relevant peak lab values organized by type of peripheral neurological complication. Table 2 summarizes results EDX studies, MRIs, and muscle and nerve biopsies by peripheral neurologic complication diagnosis. There were ultimately fourteen patients that were found to have peripheral neurological complications from the original twenty-five patients we were asked to evaluate (the remaining eleven were not found to have peripheral causes for their symptoms).

Of the four patients with sciatic neuropathies, one with bilateral sciatic neuropathies was explained by rhabdomyolysis induced bilateral

**Table 1**  
Demographics, characteristics, and peripheral neurological complication

Total patients (14)	Peripheral neurological complication			
		<i>Plexopathy</i> (n = 4)	<i>Peripheral neuropathy</i> (n = 6)	<i>Entrapment neuropathy</i> (n = 10)
Median age, range (years)	57, 33–82	54, 43–66	51, 33–71	56, 33–82
Male no. (%)	14 (100)	4 (100)	6 (100)	9 (100)
White no. (%)	6 (43)	1 (25)	4 (67)	3 (33)
Hispanic/Latino no. (%)	6 (43)	3 (75)	2 (33)	4 (44)
Asian no. (%)	2 (14)	0 (0)	0 (0)	2 (22)
COVID-19 status no. (%)	13 (93)	4 (100)	5 (83)	9 (100)
Diabetes mellitus no. (%)	6 (43)	1 (25)	1 (17)	6 (67)
Obesity no. (%)	4 (29)	1 (25)	1 (17)	4 (44)
Intubation for COVID-19 no. (%)	14 (100)	4 (100)	6 (100)	9 (100)
Paralysis during hospitalization no. (%)	6 (43)	2 (50)	4 (67)	3 (33)
Pronation for ARDS no. (%)	4 (29)	2 (50)	2 (33)	3 (33)
Hydroxychloroquine no. (%)	13 (93)	4 (100)	6 (100)	8 (89)
Corticosteroids use no. (%)	6 (43)	1 (25)	4 (67)	3 (33)
Remdesivir no. (%)	4 (29)	0 (0)	3 (50)	2 (22)
Rhabdomyolysis no. (%)	1 (7)	1 (25)	1 (17)	1 (11)
Cutaneous rash no. (%)	2 (14)	1 (25)	1 (17)	1 (11)
VTE no. (%)	5 (36)	2 (50)	2 (33)	3 (33)
RRT no. (%)	5 (36)	2 (50)	2 (33)	3 (33)
Vasopressor support no. (%)	11 (79)	4 (100)	5 (83)	7 (78)
Bacteremia no. (%)	7 (50)	3 (75)	3 (50)	5 (56)
COVID-19 diagnosis to neurological symptoms onset (days)	35	37	33	35
Length of hospitalization (days)	52	53	53	48
Length of rehabilitation (days)	22	28	24	23
<b>Average peak values</b>				
CPK (U/L)	1958	2517	2461	2710
D-dimer (ng/mL)	4916	4820	6427	3255
CRP (mg/dL)	128	93	126	119
ESR (mm/h)	106	101	113	100
Ferritin (ng/mL)	2358	1875	2794	2467

**Abbreviations:** n = total cases of neuropathy in each category. ARDS: acute respiratory distress syndrome. VTE: venous thromboembolism. RRT: renal replacement therapy. CPK: creatine phosphokinase. CRP: C-reactive protein. ESR: erythrocyte sedimentation rate.

**Table 2**  
Clinical summary

Patient no.	Peripheral neurologic complication	Electrodiagnostic studies	Muscle & nerve biopsies
			Magnetic resonance imaging
1	Brachial plexopathy	L. brachial plexopathy with sparing of axillary n. and suprascapular n. fibers	Not done
			L. brachial plexus showed asymmetric T2-hyperintensity of plexus trunks, divisions, and cords
2	Brachial plexopathy	L. brachial plexopathy with sparing of axillary n. fibers	Not done
			Diffuse L. brachial plexitis with serratus anterior muscle T2-hyperintense signal and enhancement reflecting acute denervation edema
3	Brachial plexopathy	Normal	Not done
			L. brachial plexus showed increased T2 signal of the left C5, C6 and C7 nerve roots extending to the upper and middle trunks
4	Peripheral neuropathy	Bilateral sciatic neuropathies	L. PB. m biopsy: severe myofiber atrophy, rare myonecrosis
			L. sural n. biopsy: severe, active axonal loss
5	Peripheral neuropathy	Bilateral upper trunk brachial plexopathies	Bilateral brachial plexi showed increased T2 signal in the C5/C6 roots
			Not done
6	Peripheral neuropathy	Triceps-sparing L. radial neuropathy	Normal MRI of the R. brachial plexus
			R. PB m. biopsy: moderate m. atrophy
7	Peripheral neuropathy	Bilateral sciatic neuropathies	R. medial antebrachial cutaneous n. biopsy: myelinated axon loss with numerous phagocytosing macrophages within the endoneurium
			MRI R. forearm showed T2-hyperintense posterior interosseous nerve in the Arcade of Frohse
8	Peripheral neuropathy	Bilateral cubital tunnel syndromes; R. PIN entrapment	Not done
			MRI L. lumbosacral plexus without contrast showed an enlarged, edematous L. sciatic nerve behind the L. greater trochanter, distal to the sciatic notch
9	Peripheral neuropathy	L. sciatic neuropathy	R. SPN biopsy: severe axonal neuropathy without vasculitis or thrombosis
			R. PB m. biopsy: extensive m. atrophy
10	Peripheral neuropathy	Complete R. facial axonotmesis	MRI not done (normal CT pelvis without contrast)
			Not done
11	Peripheral neuropathy	Complete R. facial axonotmesis	MRI brain shows long segment enhancement
			(continued on next page)

**Table 2** (continued)

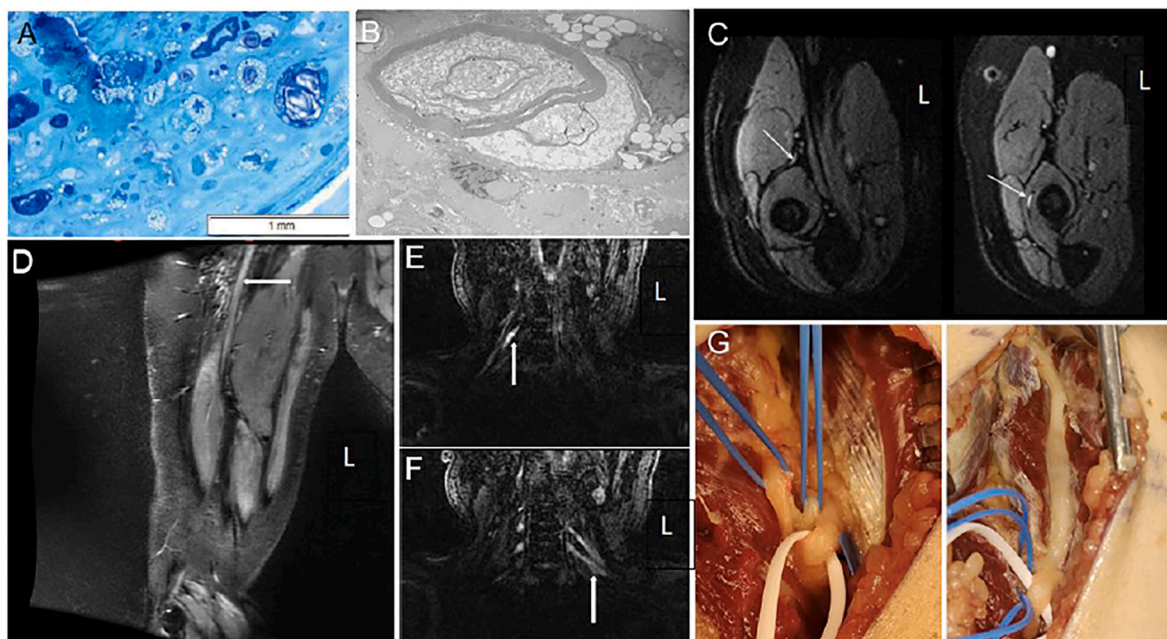
Patient no.	Peripheral neurologic complication	Electrodiagnostic studies	Muscle & nerve biopsies
			Magnetic resonance imaging
			of the R. facial nerve from the fundus of the intra-canalicular segment through the mastoid
			Not done
10	Entrapment neuropathy	Not done; clinical diagnosis of bilateral common peroneal entrapment neuropathies at the fibular heads	Not done
11	Entrapment neuropathy	Bilateral common peroneal (axonotmetic) neuropathies at the fibular head	Not done
12	Entrapment neuropathies	L. common peroneal neuropathy at fibular head; R. median neuropathy at the wrist	Not done
13	Entrapment neuropathy	R. ulnar neuropathy at cubital tunnel	Not done
14	Entrapment neuropathies	R. ulnar neuropathy at Guyon's canal; L. common peroneal neuropathy at the fibular head	Not done
			MRI R. wrist showed R. ulnar nerve enlargement and increased signal in Guyon's canal

**Abbreviations:** L = left, R = right, PB = peroneus brevis muscle, m. biopsy = muscle biopsy, SPN = superficial peroneal nerve, n. biopsy = nerve biopsy, PIN = posterior interosseous nerve.

gluteal compartment syndromes, with a peak creatine phosphokinase levels of greater than 80,000 (U/L), and edema with enhancement of the bilateral quadratus femoris muscles on pelvic MRI. Peroneus brevis muscle biopsy demonstrated severe myofiber atrophy, multifocal myofibrillar derangement and rare myonecrosis. There have been several cases of rhabdomyolysis complicating COVID-19 infection, including one as a presenting symptom [3], and the other as a later complication [4]. Neither of these cases had muscle biopsy performed. Of the four patients with brachial plexopathy, one had been managed with respiratory proning therapy while intubated and sedated who rapidly recovered indicating a compressive neurapraxic plexopathy caused by shoulder hyperabduction during proning, a well described complication of proning therapy in critically ill patients, before and after the advent of COVID-9 [5,6]. None of the remaining three patients with brachial plexopathies, one of whom underwent proning, nor the remaining three patients with bilateral sciatic neuropathies and the patient with upper extremity mononeuritis multiplex experienced any recovery during their hospitalization. MRI findings of these idiopathic brachial plexopathies and sciatic neuropathies are shown in Fig. 1.

#### 4. Discussion

Of the ten patients with entrapment neuropathies, one was found to have posterior interosseous nerve entrapment (PIN) at the arcade of Frohse in the supinator channel, which has not been described as a complication of prolonged immobilization due to sedation [7]. The patient underwent right posterior interosseous neurolysis with biopsy of the right medial antebrachial cutaneous nerve, due to clinical numbness in this nerve's territory with an absent right medial antebrachial cutaneous sensory response. The involvement of this nerve along with the posterior interosseous does suggest possible neuralgic amyotrophy or Parsonage Turner syndrome which has been described as a cause of posterior interosseous neuropathy [8]. There have been several cases of



**Fig. 1.** Nerve biopsy, MRI findings, and intraoperative photos.

**Nerve biopsy, MRI findings, and intraoperative photos:** (A) Epoxy resin section of the nerve, magnification x400. Axonal loss associated with numerous macrophages engulfing degenerating nerve fibers. (B) Electron microscopy, original magnification x5000. A macrophage appears to be stripping myelin sheath. (C) MRI FLAIR: normal intensity of the posterior interosseous branch of the radial nerve prior to the supinator tunnel, left, and increased intensity within the supinator tunnel, right. (D) MRI neurogram demonstrates enlargement and increased T2 hyperintensity of right sciatic nerve (white arrow). (E, F) MRI neurogram demonstrates increased T2 hyperintensity seen in the roots of the brachial plexus bilaterally (white arrows) in the same patient. (G) Intraoperative photos pre- (left) and post-surgical decompression (right) of the posterior interosseous branch of the radial nerve at the Arcade of Frohse.

Abbreviations: FLAIR - fluid-attenuated inversion recovery



Parsonage Turner syndrome, including one that was pure sensory, associated with COVID-19 infection [9]. The medial antebrachial cutaneous biopsy was done to clarify the underlying neuropathology and etiology of this unusual neuropathy in this critically ill patient with COVID-19 infection. It revealed significant axonal loss and numerous phagocytosing macrophages present within the endoneurium. Electron microscopy showed remaining myelinated fibers were entirely or partially engulfed by macrophages, with some macrophages appearing to penetrate loosened myelin loops, occasionally exhibiting features of vesicular degeneration. Naked axons were also present in the widened and edematous endoneurium. Fig. 1 shows these nerve biopsy findings and intraoperative photographs of pre- and post-release of the posterior interosseous branch of the radial nerve at the Arcade of Frohse. We felt these biopsy findings were suggestive of microvascular thrombotic ischemia, however the findings were not robust.

We observed ten patients to have typical peripheral neurological complications of prolonged hospitalization [10], including entrapment neuropathies of the median, ulnar, radial and peroneal nerves. None of our patients had critical illness polyneuropathy or critical illness myopathy. Of note, five patients had systemic thrombotic complications, including deep venous thrombosis and pulmonary embolism. Two patients were diagnosed with COVID-19 cutaneous rashes, which have been suggested to be complement-mediated and caused by microscopic angiopathy from an underlying systemic process [11]. There was no clear correlation between the systemic thrombotic complications and a specific peripheral neurologic complication. No patient had premorbid plexopathy, peripheral neuropathy, or entrapment neuropathy to confound our observations.

Certain peripheral neurologic complications secondary to prolonged hospitalizations and ICU care are expected in patients with COVID-19, namely median, ulnar and peroneal entrapment neuropathies, critical illness polyneuropathy and critical illness myopathy [11]. The underlying cause may be lack of frequent position changes while hospitalized, such as prolonged extension of the knee for peroneal nerve injury and prolonged flexion of the elbow for cubital tunnel syndrome. These entrapment neuropathies are preventable and may be under-recognized. Preventative measures such as avoiding shoulder hyperabduction in prone patients, wedge pillows to maintain some knee flexion, extension bracing and padding at the elbows to prevent ulnar neurapraxias, with frequent physical therapy using passive range of motion, are crucial adjunctive therapies in COVID-19 patients to reduce the risk of developing peripheral neurological complications from prolonged hospitalization.

We also found patients with peripheral neurological complications that are not typical of prolonged hospitalization, specifically three cases of bilateral sciatic neuropathies, three patients with brachial plexopathies, and one ipsilateral median, musculocutaneous and radial mononeuritis multiplex patient. One possible mechanism for these findings may be the result of uncontrolled systemic inflammation triggering microthrombotic angiopathy involving the vasa nervorum. In support of this, we found complete clinical and electromyographic sparing of axillary and infraspinatus fascicles in two cases of otherwise severe brachial plexopathies that showed complete clinical and electromyographic denervation of the musculocutaneous and radial fascicles in the upper trunks that anatomically carry these fascicles all together, suggesting a patchy microvascular injury to the epineural vasa nervorum supplying individual nerve fascicles of the upper brachial plexus trunks in these two patients. Coronaviruses such as severe acute respiratory syndrome (SARS) and Middle East Respiratory Syndrome (MERS) have previously been postulated to cause muscle and nerve injury through multiple mechanisms, including direct neuronal invasion, systemic inflammation and prolonged illness [12,13]. However, we did not find supporting pathological evidence for this on nerve biopsies, albeit from superficial peroneal nerves far distal from the injured sciatic nerves.

Direct neuronal invasion, complement-mediated inflammation, and

endothelial dysfunction have been proposed as the underlying mechanisms for COVID-19 neurological injury [1,2,13,14]. Viral entry into the central nervous system (CNS) via angiotensin-converting enzyme-2 (ACE2) receptors has been suggested to cause CNS pathologies such as ischemic strokes and encephalitis [14]. It is possible that SARS-CoV-2 may disrupt endothelial cell function in a similar ACE2 receptor-mediated mechanism involving the blood-nerve barrier, which could trigger the release of thrombogenic ultra-large von Willebrand factor (ULVWF) multimers and cause micro-thrombotic injury in the peripheral nerves. Under normal conditions, ULVWF multimers are cleaved by the protease ADAMTS-13 (a disintegrin and metalloproteinase with a thrombospondin type 1 motif, member 13) to prevent microthrombi formation [15]. COVID-19 patients have also been found to have moderately reduced serum level of ADAMTS-13, and subsequent excessive microthrombi in vasa nervorum could cause nerve ischemia and fascicular infarction in the setting of a refractory hypercoagulable state, not fully mitigated by current anti-inflammatory, anticoagulation, and antithrombotic therapies [15,16]. Alternative potential therapies could include monoclonal antibodies which inhibit complement activation, and plasmapheresis, which has been shown to reduce von Willebrand Factor concentration in plasma [16], potentially reducing the burden of micro-thrombotic injury in COVID-19.

Limitations of our observations include our small sample size and all male patient population. Furthermore, nerve biopsies could not be performed on the sciatic nerve or brachial plexus. Given the recent nature of the pandemic, we are likely only seeing glimpses of the long-term complications from COVID-19. Larger observational and longitudinal studies following the course and recovery of COVID-19 patients are crucial for better understanding of the underlying disease mechanisms.

## 5. Conclusions

We present the main clinical and laboratory findings of patients with COVID-19 in our single institution who were found to have peripheral neurological complications. We further explore the possibility that these could be manifestations of the COVID-19 disease spectrum, hypothesizing that they could be related to micro-thrombotic induced nerve ischemia.

## Financial disclosures

None of the authors have conflicts of interest to disclose.

## Study funding

No targeted funding reported.

## Publication history

The manuscript is not under publication consideration elsewhere.

## Ethical publication statement

We confirm that we have read the Journal's position on issues involved in ethical publication and affirm that this report is consistent with those guidelines.

## Consents

Verbal informed consents were obtained from all patients at the initial clinical encounter. Institutional review board approval was obtained for this study.

## Acknowledgements

We acknowledge Dr. Matthew Fink for his critical review.

## Appendix A. Abbreviations

COVID-19	coronavirus disease 2019
AIDP	acute inflammatory demyelinating polyneuropathy
CRU	COVID-19 Recovery Unit
SARS-CoV-2	severe acute respiratory syndrome coronavirus-2
EDX	electrodiagnostic
CIM	critical illness myopathies
CIPN	critical illness polyneuropathy
MRI	magnetic resonance imaging
SARS	severe acute respiratory syndrome
MERS	Middle East respiratory syndrome
CNS	central nervous system
ACE2	angiotensin-converting enzyme-2
ULVWF	ultra-large von Willebrand factor
ADAMST13	a disintegrin and metalloproteinase with a thrombospondin type 1 motif, member 13
CT	computerized tomography
L	left
R	right
m. biopsy	muscle biopsy
n. biopsy	nerve biopsy

## References

- [1] L. Mao, H. Jin, M. Wang, et al., Neurologic manifestations of hospitalized patients with coronavirus disease 2019 in Wuhan, China, *JAMA Neurol.* 77 (6) (2020) 683–690.
- [2] G. Toscano, F. Palmerini, S. Ravaglia, L. Ruiz, P. Invernizzi, M.G. Cuzzoni, D. Franciotta, F. Baldanti, R. Daturi, P. Postorino, A. Cavallini, G. Miceli, Guillain-Barré syndrome associated with SARS-CoV-2, *N. Engl. J. Med.* 382 (26) (2020 Jun 25) 2574–2576, <https://doi.org/10.1056/NEJMc2009191>. Epub 2020 Apr 17, 323 02082. PMC7182017.
- [3] K. Suwanwongse, N. Shabarek, Rhabdomyolysis as a presentation of 2019 novel coronavirus disease, *Cureus* 12 (4) (2020) e7561, <https://doi.org/10.7759/cureus.7561>. Apr 6, 32382463. PMC7202588.
- [4] M. Jin, Q. Tong, Rhabdomyolysis as potential late complication associated with COVID-19, *Emerg. Infect. Dis.* 26 (7) (2020 Jul) 1618–1620, <https://doi.org/10.3201/eid2607.200445>. Epub 2020 Jun 21, 32197060. PMC7323559.
- [5] A. Sánchez-Soblechero, C.A. García, A. Sáez Ansotegui, J. Fernández-Lorente, I. Catalina-Álvarez, F. Grandas, J.L. Muñoz-Blanco, Upper trunk brachial plexopathy as a consequence of prone positioning due to SARS-CoV-2 acute respiratory distress syndrome, *Muscle Nerve* 62 (5) (2020 Nov) E76–E78, <https://doi.org/10.1002/mus.27055>. Epub 2020 Sep 10, 32875575.
- [6] Joel O'Sullivan, Caroline Miller, Jack Jeffrey, Dominic Power, Brachial plexus neuropathies during the COVID-19 pandemic: a retrospective case series of 15 patients in critical care, *Phys. Ther.* 101 (1) (2021) 1–8, 2021-01-04, Vol.101 (1). Web.
- [7] Alan C. Dang, Craig M. Rodner, Unusual compression neuropathies of the forearm, part I: radial nerve, *J. Hand Surg. (American Ed.)* (2009) 1906–1914, 34.10.
- [8] Mao Akane, Katsuyuki Iwatsuki, Masahiro Tatebe, Takanobu Nishizuka, Shigeru Kurimoto, Michiro Yamamoto, Hitoshi Hirata, Anterior interosseous nerve and posterior interosseous nerve involvement in neuralgic amyotrophy, *Clin. Neurol. Neurosurg.* 151 (2016) 108–112.
- [9] Mario Cacciavillani, Alessandro Salvalaggio, Chiara Briani, Pure sensory neuralgic amyotrophy in COVID-19 infection, *Muscle Nerve* 63 (1) (2021) E7–E8.
- [10] C. Magro, J.J. Mulvey, D. Berlin, et al., Complement associated microvascular injury and thrombosis in the pathogenesis of severe COVID-19 infection: a report of five cases, *Transl. Res. J. Lab. Clin. Med.* 220 (2020) 1–13.
- [11] Lisa D. Hobson-Webb, Vern C. Juel, Common entrapment neuropathies, *CONTINUUM: Lifelong Learn. Neurol.* 23 (2) (2017) 487–511.
- [12] L.-K. Tsai, S.-T. Hsieh, C.-C. Chao, et al., Neuromuscular disorders in severe acute respiratory syndrome, *Arch. Neurol.* 61 (11) (2004) 1669–1673.
- [13] Y.M. Arabi, A. Harthi, J. Hussein, et al., Severe neurologic syndrome associated with Middle East respiratory syndrome corona virus (MERS-CoV), *Infection* 43 (4) (2015) 495–501.
- [14] A.M. Baig, A. Khaleeq, U. Ali, H. Syeda, Evidence of the COVID-19 virus targeting the CNS: tissue distribution, host-virus interaction, and proposed neurotropic mechanisms, *ACS Chem. Neurosci.* 11 (7) (2020) 995–998.
- [15] N. Morici, M. Bottiroli, R. Fumagalli, C. Marini, M. Cattaneo, Role of von Willebrand factor and ADAMTS-13 in the pathogenesis of thrombi in SARS-CoV-2 infection: time to rethink, *Thromb. Haemost.* (2020) 20–23.
- [16] U. Zachariah, S.C. Nair, A. Goel, et al., Targeting raised von Willebrand factor levels and macrophage activation in severe COVID-19: consider low volume plasma exchange and low dose steroid, *Thromb. Res.* 192 (2020) 2.