

ORAL PRESENTATION

Open Access

Imaging contrast agent concentration and extracellular volume fraction in the right ventricle

Joseph J Pagano^{1*}, Kelvin Chow¹, Ian Paterson², Richard B Thompson¹

From 15th Annual SCMR Scientific Sessions
Orlando, FL, USA. 2-5 February 2012

Background

Globally increased myocardial extracellular volume fraction (ECVF) has been associated with diffuse myocardial fibrosis. ECVF can be estimated using blood and tissue concentrations of gadolinium contrast agent, [Gd], which are calculated using baseline and post-contrast T_1 values [1]. To date, T_1 quantification has been limited to the left ventricle (LV) with moderate spatial resolution (~2 mm) and long imaging windows (>200 ms) to accommodate breath-hold acquisitions. These methods have insufficient spatial resolution to image the relatively thin-walled right ventricle (RV). A new cine-imaging approach for the measurement of contrast agent concentration and ECVF using saturation-recovery preparation is evaluated in the LV and RV.

Methods

A saturation-recovery gated-segmented cine SSFP sequence, similar to the multi-contrast late enhancement imaging method [2], provides a short acquisition window (< 50 ms) enabling end-systolic imaging and higher spatial resolution (~1 mm). Bloch equation simulations of the sequence were used to generate a look-up table to relate the measured ratio of post- to pre-contrast image intensity to the tissue concentration of contrast agent (CLAIR - Contrast Level Assessment using Intensity Ratios). Short axis images were acquired in 9 subjects from an ongoing study of heart failure (Alberta HEART), with contrast-enhanced images at 15 min post 0.15mmol/kg Gadovist. Typical CLAIR pulse sequence parameters: FOV=300mm, 256 matrix, 8 mm slice, flip angle=73°, TE=1.66ms, TR=3.32ms, VPS=14, TI=300ms. Average LV [Gd] in subjects was compared to values obtained using a saturation-recovery SSFP T_1 -mapping sequence [3] calculated using $[Gd] = \Delta R1/r$ ($\Delta R1 =$

change in $1/T_1$ with contrast, $r =$ relaxivity). For both methods $ECVF = (1-Hct)*[Gd]Tissue/[Gd]Blood$, with [Gd]Blood obtained via the T_1 mapping sequence and an assumed Hct of 0.4. Data are presented as mean±SD and differences compared with the two-tailed paired Student's t-test.

Results

Subject age was 60.7 ± 14.3 yrs, with 5 males. Images from an individual using CLAIR (end-systole) and conventional T_1 -mapping (end-diastole) are shown in Fig. 1. LV [Gd] is not statistically different between CLAIR and T_1 mapping (0.188 ± 0.042 vs. 0.198 ± 0.029 mM, $p=0.151$) and is significantly correlated between methods ($p<0.01$) (Fig. 2 left). LV ECVF is not statistically different between CLAIR and T_1 mapping (0.216 ± 0.027 vs. 0.231 ± 0.027 , $p=0.120$) with negligible bias (Fig. 2 right) between the two methods. CLAIR RV [Gd] (0.212 ± 0.066 mM) and ECVF (0.245 ± 0.054) were not statistically different from LV values ($p=0.134$ and $p=0.093$).

Conclusions

CLAIR yields similar LV myocardial contrast concentration and ECVF in the LV to T_1 -mapping and provides sufficient temporal and spatial resolution for end-systolic RV imaging.

Funding

CIHR.

Alberta HEART Team Grant.

Author details

¹Biomedical Engineering, University of Alberta, Edmonton, AB, Canada.

²Medicine, University of Alberta, Edmonton, AB, Canada.

Published: 1 February 2012

¹Biomedical Engineering, University of Alberta, Edmonton, AB, Canada
Full list of author information is available at the end of the article

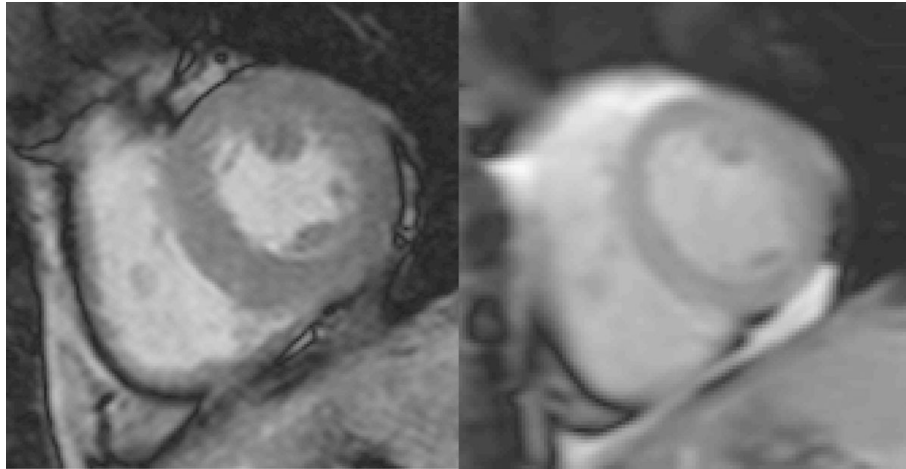


Figure 1 CLAIR image (left) at end-systole (1.17 mm resolution, 46 ms temporal resolution) and conventional T₁-mapping image at end-diastole (right) (1.88 mm resolution, 225 ms temporal resolution) from the same subject (15 minutes post contrast).

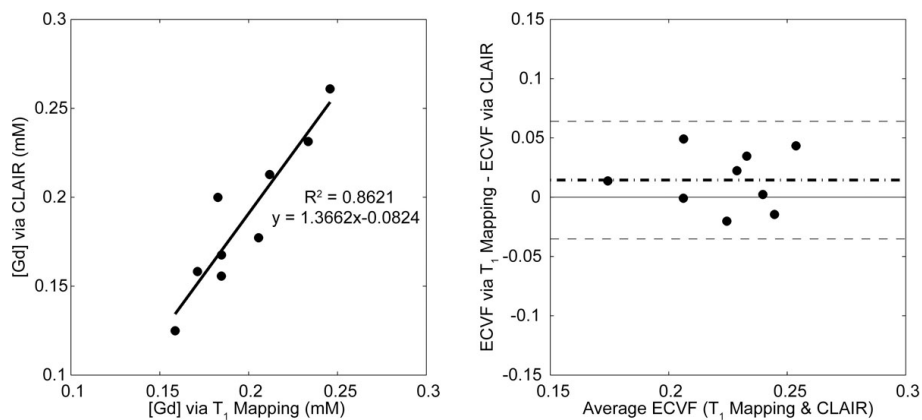


Figure 2 Comparison of CLAIR and conventional T₁-mapping methods: LV contrast concentration (left) and Bland-Altman plot of extracellular volume fraction (right).

References

1. Donahue, *et al.* *Magn Reson Med.*34(3):423-32.
2. Connelly, *et al.* *JMRI.*30:771-7.
3. Chow, *et al.* *J Cardio Magn Reson.*13(Suppl1):P31.

doi:10.1186/1532-429X-14-S1-O109

Cite this article as: Pagano *et al.*: Imaging contrast agent concentration and extracellular volume fraction in the right ventricle. *Journal of Cardiovascular Magnetic Resonance* 2012 **14**(Suppl 1):O109.

**Submit your next manuscript to BioMed Central
and take full advantage of:**

- Convenient online submission
- Thorough peer review
- No space constraints or color figure charges
- Immediate publication on acceptance
- Inclusion in PubMed, CAS, Scopus and Google Scholar
- Research which is freely available for redistribution

Submit your manuscript at
www.biomedcentral.com/submit

