

Surgical Planning and Counseling in Adolescence: A Case Report of a 16-Year-Old with an Aborting Pelvic Mass

Jessica Suzanne Zigman*, Joy Brotherton, Christina Truong, Tajnoos Yazdany

Department of Obstetrics and Gynecology, Harbor UCLA Medical Center, California, USA

Abstract

This case illustrates a rare finding and successful treatment of an aborting fibroid in a virginal adolescent. Careful consideration for the exam process, specific counseling, surgical planning and approach in this case are presented.

Keywords: Adolescent gynecology, fibroid, leiomyoma, pelvic mass

INTRODUCTION

As the most common pelvic mass in women, uterine leiomyoma affect up to 70%–80% of females.^[1] Despite their prevalence in older women, leiomyomas are infrequently diagnosed in children and adolescents, with few reported cases in the literature.^[2] While rarely reported, leiomyomas are an important consideration in the differential diagnoses for adolescents with pelvic masses. To date, there are no case reports that use vaginal myomectomy with uterine curettage. In this unusual presentation of an aborting leiomyoma in a 16-year-old female, we discuss the presentation, counseling, office examination, and surgical planning of pelvic masses in adolescence.

CASE REPORT

A 16-year-old virginal female was referred from her primary care provider (PCP) for complaints of copious vaginal discharge. As part of the initial workup, her PCP noted a pelvic mass and ordered a magnetic resonance imaging (MRI) of the pelvis. The MRI revealed an 8-cm pelvic mass in the lower cervix/upper vagina connected to the myometrium of the left uterine body by a vascular stalk, measuring 2.3 cm in diameter [Figure 1].

The patient had a history of normal monthly menses; however, the month before presentation, she experienced an abnormally heavy period soaking 7 pads per day for 6 days, followed by copious amounts of clear vaginal discharge. Laboratory values revealed a hemoglobin of 6.9 g/dL. The patient was virginal and had no significant medical or surgical history.

The patient was counseled and offered a vaginal examination in clinic versus an examination under anesthesia (EUA) in the operating room. The patient consented to a single-digit vaginal examination in the clinic. On examination, a large, smooth, firm mass was palpated in the midvagina. While a malignant process could not be ruled out, the heterogeneous appearance and presence of internal hemorrhage suggested the most likely diagnosis of an aborting, degenerating fibroid.

After the physical examination and review of the images, the recommendation was made for surgical management. Together with her guardian, we recommended an EUA with removal of the aborting mass by operative hysteroscopy versus vaginal myomectomy with possible dilation and curettage. The patient and her guardian were also counseled extensively regarding

Address for correspondence: Dr. Jessica Suzanne Zigman, Department of Obstetrics and Gynecology, Harbor UCLA Medical Center, 1000 W Carson Street Building D3, Torrance, California 90509, USA. E-mail: jszigman@gmail.com

Article History:

Received 15 February 2018

Received in revised form 6 June 2018

Accepted 29 June 2018

Available online 26 September 2018

Access this article online

Quick Response Code:



Website:
www.e-gmit.com

DOI:
10.4103/GMIT.GMIT_19_18

This is an open access journal, and articles are distributed under the terms of the Creative Commons Attribution-NonCommercial-ShareAlike 4.0 License, which allows others to remix, tweak, and build upon the work non-commercially, as long as appropriate credit is given and the new creations are licensed under the identical terms.

For reprints contact: reprints@medknow.com

How to cite this article: Zigman JS, Brotherton J, Truong C, Yazdany T. Surgical planning and counseling in adolescence: A case report of a 16-year-old with an aborting pelvic mass. *Gynecol Minim Invasive Ther* 2018;7:175-7.

the risk for life-threatening intraoperative hemorrhage. In addition, the patient was consented for the unlikely possibility of the uterine occlusion balloon, exploratory laparotomy, and possible hysterectomy in the case of life-threatening hemorrhage. Finally, they were counseled on the possibility of additional surgery or treatment in the unlikely event of malignancy. In preparation for the procedure, a blood transfusion was recommended due to her preoperative anemia, symptoms, and risk of bleeding during the surgery. Due to the fact that her cervix was dilated and the perceived risk of ascending infection, the decision was made to initiate twice-daily doxycycline to reduce the risk of infection until surgery could be performed. The patient was consented and booked for an outpatient procedure including an EUA, vaginal myomectomy, uterine curettage, and a bedside abdominal ultrasound, performed under general anesthesia.

Preoperative surgical planning ensured that any necessary medications and equipment were present in the operating room at the time of surgery. Uterotonic agents including methergine and misoprostol tablets were brought to the operating room. A 30-cc Foley balloon, as well as hemostatic agents including oxidized regenerated cellulose (SURGICEL SNoW, Ethicon, Cincinnati, OH, USA) and thrombin in a gelatin matrix (FloSeal, Baxter, Healthcare Corp, Deerfield, IL, USA), along with an abdominal hysterectomy tray, was brought into the operating room in the event of hemorrhage. Next, a Pederson speculum was gently placed into the vagina and an 8-cm fibroid was noted to be on a 3-cm stalk. The cervix was noted to be dilated 4 cm. A suture was placed around the base of the stalk in an attempt to prevent bleeding. This can be done with a free tie or with a laparoscopic pretied suture loop. Dilute vasopressin (20 units in 100 mL of normal saline), a neurohypophysial hormone that constricts blood vessels, decreasing intraoperative blood loss, increasing

postoperative hemoglobin, and decreasing blood transfusion rate, was injected into the mass in four locations, with special attention to the base of the stalk.^[3] The mass was grasped with a Lahey clamp and manually debulked with a scalpel from the most distal portion of the mass into retrievable pieces [Figure 2]. The morcellation was continued until the stay suture was reached at the stalk. The stalk was made flush with the lower uterine segment wall using a sharp curettage. Minimal bleeding was encountered throughout the entire procedure. The uterine cavity began to contract at this time without the use of uterotonic agents. A bedside abdominal ultrasound was performed to confirm that the mass was removed in its entirety and a thin endometrial stripe was noted. The estimated blood loss was 25 mL. Pathology revealed tissue consistent with a submucosal uterine leiomyoma with focal hemorrhage.

DISCUSSION

This case illustrates a rare finding and successful treatment of an aborting fibroid in a virginal adolescent. Careful consideration for the examination process, specific counseling and surgical planning and approach, in this case, are summarized below.

While a malignant process without a tissue sample could not be ruled out, it is very rare in this age group. Andrade *et al.* reviewed nine adolescent adenosarcoma cases and reported that patients usually presented with painless polypoid protrusion of tissue through the hymen, abnormal vaginal discharge, or abnormal vaginal bleeding.^[4] Sarcoma botryoides is more common under the age of 10 and arises from the vagina or cervix and is typically a lobulated, grape-like vaginal mass. Other causes of pelvic masses in adolescence include hematocolpos from imperforate hymen and cystic and solid tumors of various origins. In adolescents, degenerating fibroids are exceedingly rare with only one previous case report.^[5]

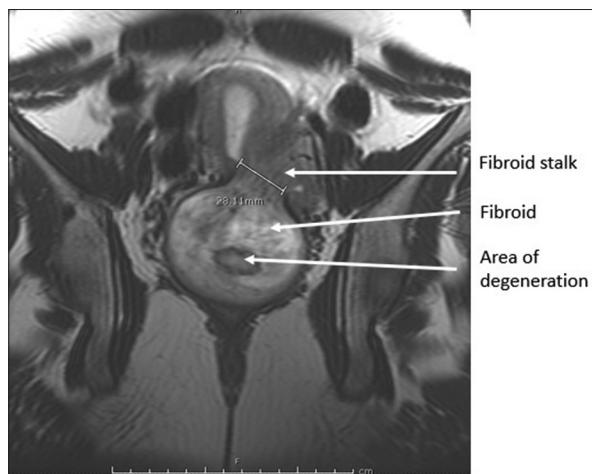


Figure 1: Magnetic resonance imaging, coronal view. Stalk of aborting fibroid

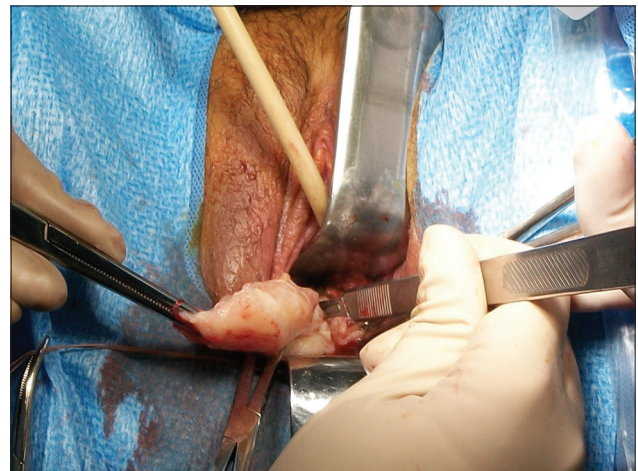

Figure 2: Vaginal morcellation of aborting fibroid

When performing a gynecological examination in an adolescent patient, it is paramount to explain the process to the patient and her guardian before attempting the examination. Because this patient was in late adolescence, she was given a choice of who was in the room during the examination. A hand mirror can be used so she can follow along with the examination. If vaginal assessment was not able to be accomplished due to anxiety or pain, an EUA in the operating room could be offered in the case of a patient who is bleeding and anemic.^[6]

Counseling adolescents are very important and can be more complex because it must also include the guardian. All risks were described for the procedure as well as the risks if the recommended procedure was declined.

Adolescents, as well as their consenting parents/guardians, should be informed about the procedure and its risks in an understandable manner and given sufficient time to ask questions. Discussion recurrence is important as upto 11% of women undergoing single fibroid removal require subsequent surgery for recurrence of myomas.^[7] Finally, alternatives to having surgery, including delaying the timing of surgery or not having surgery at all, should be discussed.

We present this case to contribute to the literature on the surgical approaches and counseling in rare cases such as degenerating fibroids in adolescence. The preoperative preparation and counseling allowed the operation to run smoothly and safely.

The patient and guardian's consent was obtained to write this article.

Declaration of patient consent

The authors certify that they have obtained all appropriate patient consent forms. In the form the patient(s) has/have given his/her/their consent for his/her/their images and other clinical information to be reported in the journal. The patients understand that their names and initials will not be published and due efforts will be made to conceal their identity, but anonymity cannot be guaranteed.

Financial support and sponsorship

Nil.

Conflicts of interest

The authors have no conflicts of interest relevant to this article except Dr. Joy Brotherton who discloses the following: Ethicon Endo-Surgery, Inc.: Consultant, AbbVie: Speakers Bureau, and Baxter Healthcare Corp.: Advisory board.

REFERENCES

1. Baird DD, Dunson DB, Hill MC, Cousins D, Schectman JM. High cumulative incidence of uterine leiomyoma in black and white women: Ultrasound evidence. *Am J Obstet Gynecol* 2003;188:100-7.
2. Moroni RM, Vieira CS, Ferriani RA, Reis RM, Nogueira AA, Brito LG. Presentation and treatment of uterine leiomyoma in adolescence: A systematic review. *BMC Womens Health* 2015;15:4.
3. Hickman LC, Kotlyar A, Shue S, Falcone T. Hemostatic techniques for myomectomy: An evidence-based approach. *J Minim Invasive Gynecol* 2016;23:497-504.
4. Andrade LA, Derchain SF, Vial JS, Alvarenga M. Mullerian adenocarcinoma of the uterus in adolescents. *Int J Gynaecol Obstet* 1992;38:119-23.
5. Salehi PP, Tyson N. Laparoscopic myomectomy of a symptomatic uterine leiomyoma in a 15-year-old adolescent. *J Pediatr Adolesc Gynecol* 2016;29:e87-90.
6. Emans SJ, Laufer MR. Emans, Laufer, Goldstein's Pediatric and Adolescent Gynecology. 6th ed. Philadelphia, PA: Lippincott Williams & Wilkins; 2012.
7. Parker WH. Uterine myomas: Management. *Fertil Steril* 2007;88:255-71.