

CASE REPORT

Radiculopathies caused by spontaneous pneumorrhachis: Two case reports and review of literature

Hanene Lassoued Ferjani^{1,2,3}  | Lobna Ben Ammar¹ | Dhia Kaffel^{1,2,3} |
Kaouther Maatallah^{1,2,3} | Wafa Triki^{1,2,3} | Dorra Ben Nessib^{1,2,3}  | Wafa Hamdi^{1,2,3}

¹Department of Rheumatology,
Mohammed Kassab National Institute
of Orthopaedics, Mannouba, Tunisia

²Faculty of Medicine of Tunis,
University Tunis El Manar, Tunis,
Tunisia

³Research Unit UR17SP04, Tunis,
Tunisia

Correspondence

Hanene Lassoued Ferjani, Department
of Rheumatology, Mohammed Kassab
National Institute of Orthopaedics,
Mannouba, Tunisia.
Email: lassouedferjanihanene@gmail.
com

Funding information

Not applicable

Abstract

Pneumorrhachis is a rare condition of low back pain. It is usually asymptomatic and secondary to trauma. Spontaneous pneumorrhachis is scarce.

KEYWORDS

gas-containing herniation, intraspinal gas, lumbar nerve root compression, pneumorrhachis, radiculopathy, vacuum phenomenon

1 | INTRODUCTION

Pneumorrhachis is a rare condition. We report two cases of radiculopathy caused by spontaneous pneumorrhachis. Patients complain for back pain. The radiological findings showed the intra spinal gas comprising the nerve root. Conservative treatment was sufficient to improve symptom.

Pneumorrhachis is a rare phenomenon defined as the presence of intraspinal air. It can be caused by various etiologies, mainly trauma, and medical procedures such as spine surgery or epidural anesthesia. Less common causes of pneumorrhachis include spinal infection, tumoral, or degenerative disk diseases. It is usually an asymptomatic and incidental imaging finding. However, it can seldom lead to radicular or spinal nerve compression.¹

We report herein two cases of spontaneous pneumorrhachis due to degenerative disk disease and discuss the mechanism, diagnosis, and management of this rare condition.

2 | CASE 1

A 78-year-old woman presented with a 1-year history of progressive low back mechanical pain associated with low right limb paraesthesia. She has no history of trauma or spinal surgery. The lumbar spine range of motion was limited (Schober's test = 10 mm) and the Leri test was positive. The neuromuscular examination was unremarkable. Biochemical investigations were normal (Table 1).

This is an open access article under the terms of the Creative Commons Attribution-NonCommercial License, which permits use, distribution and reproduction in any medium, provided the original work is properly cited and is not used for commercial purposes.

© 2021 The Authors. *Clinical Case Reports* published by John Wiley & Sons Ltd.

TABLE 1 Case reports of radiculopathies caused by a gas-containing cyst or pseudo-cyst

Author	Sex	Age (years)	Symptoms duration	Spinal location	Neurologic symptoms	Treatment	Outcome
Bouraqui et al ¹³	M	56	6 months	L3–L4	None	Conservative treatment	4 weeks later: improvement
Kim ¹⁸	M	64	3 weeks	L5–S1	Left big toe dorsiflexion weakness	Selective nerve L5 block	2 months later: clinical improvement and nearly complete disappearance of intraspinal air on CT
Giraud et al ¹⁶	M	55	4 months	S1	None	Epidural glucocorticoid injection	5 months later: complete relief
	F	69	-	L5	Foot flexor weakness	Conservative treatment	1 month later: complete relief and improvement of motor deficit
	M	58	-	S1	None	Hemilaminectomy Light disc curettage	Relapse 1 year later
Tamburelli et al ²⁶	M	61	-	L4–L5	Dysesthesia of the right foot	Hemilaminectomy Incision of the PLL Foraminotomy	-
Odderson et Matthies ¹⁷	M	73	6 months	L4–L5 S1 Apophyseal joints at L5–S1 level	None	Conservative treatment	Complete relief CT: resorption of the intraspinal gas
Demierre et al ¹¹	F	37	Acute	S1	Sensory deficit	CT guided aspiration	Relapse 2 months later. 1 st surgery: removal of little disc material Relapse one week later. 2 nd surgery: removal of the pseudo-cyst and the PLL 1 year later: free of pain
Belfquih et al ²⁴	F	45	9 months	L5–S1	None	Removal of the pseudo-cyst	1 year later: complete relief
Lee et al ¹²	F	76	2 years	L4	Left ankle dorsiflexion weakness	Hemilaminectomy Removal of the PLL flavectomy	6 months later: complete relief
Impiombato et al ¹⁹	F	85	2–3 years	L5	None	Aspiration under fluoroscopic guidance	6 months later: complete relief CT: absence of gas
Akhaddar et al ²⁵	F	37	6 months	L5	None	Removal of the pseudo-cyst	Improvement
Kumar et al ²¹	M	64	1 year	L3	Motor and sensory deficit	L3 hemilaminectomy Removal of the cyst	Complete relief

(Continues)

TABLE 1 (Continued)

Author	Sex	Age (years)	Symptoms duration	Spinal location	Neurologic symptoms	Treatment	Outcome
Kawaguchi et al ²⁷	F	60	1 month	L3–L4	Sensory deficit	Laminectomy Cyst removal	1 year later: complete relief
Bosser et al ¹⁰	F	62	6 months	L5	None	CT guided aspiration	Relapse few days later Surgery with complete relief
Ricca et al ²²	M	57	1 month	L5–S1 extended to L4	Sensory deficit	Removal of the cyst Disc curettage	Complete relief
Song et Lee ¹⁵	M	72	1 month	C7 causing cervical myelopathy	Bilateral motor weakness and sensory deficit of the lower limbs	C7 total laminectomy	4 weeks later: full recovery

Abbreviations: CT, computed Tomography; F, Female; M, Male; PLL, Posterior longitudinal ligament.

The plain X-ray of the spine showed disk space narrowing at L4-L5 and L5-S1. Computed tomography (CT) visualized a degenerated L4-L5 disk with a vacuum phenomenon as well as a moderate protrusion at L5-S1 space. A gas bubble was noticed in the right lateral recess at L4-L5 with probable evidence of right L4 root compression (Figure 1).

The patient was treated conservatively with analgesics combined with spine rehabilitation.

3 | CASE 2

A 61-year-old, retired sheet metal worker, with chronic low back pain presented with a 2-month history of left sciatica that irradiated to the foot in the L5 dermatome. Past medical history was unremarkable. There was no paraesthesia, weakness, or bowel or bladder dysfunction. Physical examination demonstrated a full range of motion. Motor and sensory functions were normal and the straight leg-raising test was positive in the left. Biological tests showed hemoglobin level at 13 g/dl, white blood cell count 7600 elements/mm³, C-reactive protein and erythrocytes sedimentation rate at 5 mg/L and 17 mm; respectively.

Radiographs showed degenerative changes in the lumbar spine. CT scans demonstrated a foraminal disk protrusion with intradiscal gas compressing the left L5 nerve root (Figure 2). The patient improved on conservative management or symptomatic treatment (Table 2).

4 | DISCUSSION

In addition to trauma causes, other air sources may be found as epidural infection with gas-producing organisms, air introduction via lumbar puncture, or spinal surgery. Relatively rare, the presence of epidural gas in the degenerative spine was reported in a few cases of literature, secondary to vacuum phenomenon.

The vacuum phenomenon is a radiological finding defined as the presence of gaseous collection in the intervertebral disk space resulting from the movement of the spine, especially extension and traction.² It is a common finding that has been detected or reported in 46% of patients aged over 40 years.³

The intradiscal gas diffuses from the extra-cellular fluid into areas of subatmospheric pressure and it cannot be reabsorbed because the degenerated disk is avascular. Some authors have discussed the role of disk aging in the genesis of the gas.^{2,4} This would be due to dehydration and the decrease in the proportion of proteins in the disk.⁵ The gas is composed of 90%–92% nitrogen along with oxygen, carbon dioxide, and other trace gases.^{2,6}

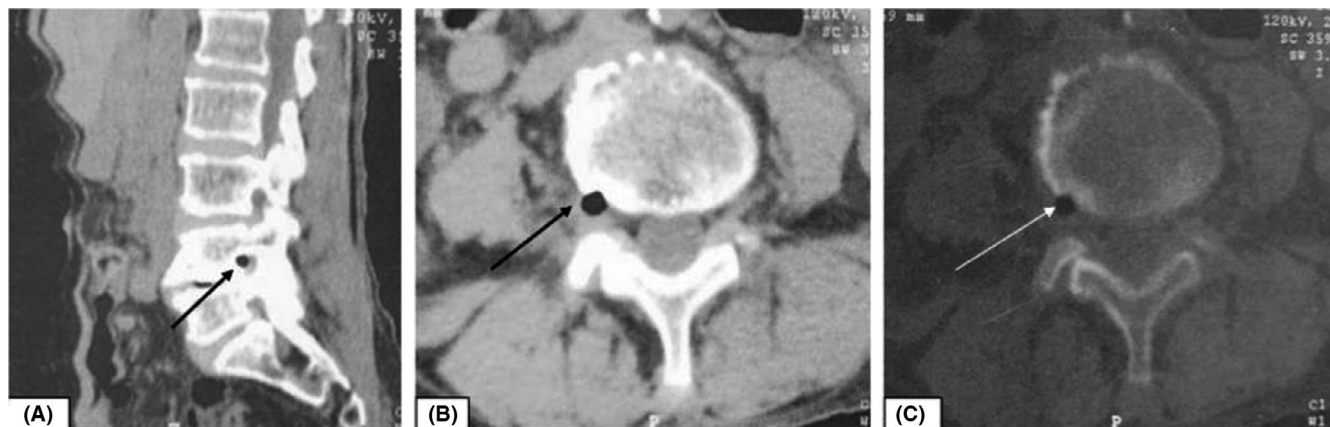

FIGURE 1 Spinal CT scan: Sagittal (A), axial (B, C) showing a vacuum disk phenomenon and moderate protrusion at L5–S1 space (arrows). A gas bubble was noticed in the right lateral recess at L4–L5 with probable evidence of right L4 root compression

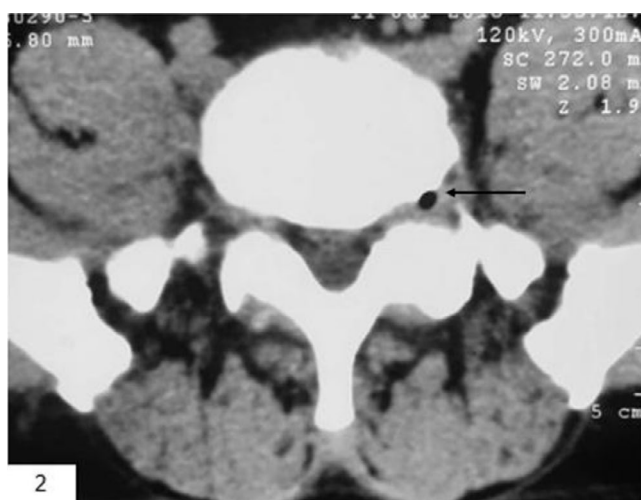


FIGURE 2 Spinal CT scan axial showing foraminal disk protrusion with intradiscal gas (black arrow) compressing the left L5 nerve root

The vacuum phenomenon has been mostly observed in L5–S1 disk with decreasing frequency at a higher lumbar level.⁷

Whereas the vacuum phenomenon is a common finding, the presence of gaseous collection within the spinal canal is unusual. The gas formation is often associated with a disk herniation such as in our second case, but it can also be found free within the spinal canal as in the first case.^{8,9}

In most previous cases, the gas-containing cyst has been noticed at the level of an intervertebral disk with a vacuum phenomenon suggesting that the gas is originated from the intervertebral disk.¹⁰

Interestingly, the gas can migrate to the spinal canal within a degenerated nucleus pulposus, resulting in a gas-containing disk herniation. Otherwise, the gas that fills the disk is expelled in the spinal canal by a “valve-pump” mechanism through ruptures in the annulus fibrosus and collects under pressure within a fibrous capsule or a pseudo-capsule.⁶

The histological study of a few cases of free gas noticed that the gas cyst was surrounded by the posterior longitudinal ligament (PLL) suggesting that air coming from the disk was trapped between the PLL and the bone. Furthermore, no recurrence has been observed after the PLL removal.^{11,12} Damierre et al. reported the case wherein gas aspiration was failed due to the persistence of pseudo capsules. Surgical removal of membrane proved identical PLL tissue of capsule and improved patient pain.¹¹

Mostly asymptomatic, only a few cases of intraspinal gas can cause compressive radiculopathy. The clinical features are similar to those of common sciatica. Moreover, we can notice an exacerbation of the pain at the change of positions reflecting the free movements of the air in the epidural space.¹³ Furthermore, only a few cases reported neurological symptoms as lower extremity paresthesia and paralysis. An acute cauda equina syndrome and cervical myelopathy have been reported.^{14,15}

On standard spine x-rays, we often notice degenerative modifications of the spine and sometimes a vacuum phenomenon.¹³

CT scan is currently the imaging tool of choice to diagnosis pneumorrhachis showing the degenerative modifications of the spine with a vacuum phenomenon and, at the same level, the intraspinal gas collection with a density from -200 to -900 Hounsfield units.¹⁶ On MRI, gas is seen in low signal on the T1 and T2 weighted sequences.¹⁶

For the management of intraspinal gas, most authors recommend conservative therapy including bed rest, analgesics, non-steroidal anti-inflammatory drugs, myorelaxant drugs, and epidural glucocorticoid injections.¹⁶ Intraspinal gas may disappear spontaneously.^{17,18} In our cases, we noticed an improvement without using invasive procedures.

Some authors reported the efficacy of the CT-guided aspiration of the gas cyst.^{19,20} However, in some cases, intraspinal gas recurred with a relapse of the radicular syndrome.^{10,11} Indeed, this procedure does not modify the local environment, and the origin of the air remains.

TABLE 2 Case reports of radiculopathies caused by a gas-containing herniation

Author	Sex	Age (years)	Symptoms duration	Spinal location	Neurologic symptoms	Treatment	Outcome
Konya et al ²⁸	F	78	5 years	L4–L5	Sensory deficit	Conservative treatment	1 year later: moderate improvement CT: persistence of the intraspinal gas
Ryu et al ²⁹	M	72	4 weeks	L3–L4	None	Removal of gas-containing disc and PLL	Complete relief
Ovejero ³⁰	F	64	2 years	L2–L3	Motor and sensory deficit	Laminectomy + Durotomy + removal of disc fragments	3 years later: improvement of motor weakness, moderate lumbar pain
Mortensen et al ³¹	F	63	1 year	L4–L5	None	L4–L5 laminectomy + removal of herniated fragment	Improvement
Ryu et al ²⁹	M	65	1 year	L5–S1	Left toe-raising weakness	Laminectomy + left L5–S1 discectomy	Complete relief
	M	55	1 year	S1	Limited flexion and right toe-raising weakness	Surgery	Improvement Mild weakness
Mehta et Sharp ¹⁴	-	78	Acute	L4–L5	Cauda equina syndrome	L4–L5 laminectomy + wide posterior lumbar spinal decompression	Improvement of pain Persistence of bowel and bladder dysfunction
Anda et al ³²	M	40	Acute	L5	Motor and sensory deficit	Conservative treatment	-
Pierpaolo et al ⁹	F	62	3 months	L4–L5	None	Removal of the herniated disc	Complete relief
Pak et al ²⁰	M	83	Acute	L5–S1	none	Aspiration under fluoroscopic guidance	6 months later: complete relief
Cheng et al ²³	M	80	6 weeks	L2	None	Hemilaminectomy + Facetomy of inferior L2 and superior L3 facets on the left side	Complete relief

Abbreviations: CT, computed Tomography; F, Female; M, Male; PLL, Posterior longitudinal ligament.

Surgery is the preferred treatment for patients who failed to respond to conservative therapy. The procedure combines gas evacuation with a disk curettage to prevent recurrence.^{12,21–25}

5 | CONCLUSION

Pneumorrhachis caused by degenerative disk disease is a rare condition that can rarely lead to a radicular syndrome. Its prevalence increases with age and it may be due to two mechanisms: a gas-containing disk herniation or an intraspinal free gas. CT scan is the preferred imaging technique. The treatment is conservative at first. CT-guided needle aspiration can be suggested despite the risk of relapse. Surgery remains the treatment of choice in case of neurological signs or recurrence under conservative treatment.

ACKNOWLEDGEMENTS

None.

CONFLICT OF INTEREST

None declared.

AUTHORS CONTRIBUTIONS

HLF, KM, DBN, and WT: analyzed and interpreted the patient data and provided advice for treatment. DK ensured the clinical follow-up of the patient. LBA wrote the manuscript; and all authors: read, revised, and approved the final manuscript.

CONSENT

Written informed consent was obtained from the two patients for the publication of this case report.

DATA AVAILABILITY STATEMENT

The data that support the findings of this study are available from the corresponding author upon reasonable request.

ORCID

Hanene Lassoued Ferjani  <https://orcid.org/0000-0002-8658-0936>

Dorra Ben Nessib  <https://orcid.org/0000-0002-6284-5856>

REFERENCES

1. Chaichana KL, Pradilla G, Witham TF, Gokaslan ZL, Bydon A. The clinical significance of pneumorachis: a case report and review of the literature. *J Trauma Inj Infect Crit Care*. 2010;68:736–744.
2. Ford L, Gilula L, Murphy W, Gado M. Analysis of gas in vacuum lumbar disc. *Am J Roentgenol*. 1977;128:1056–1057.
3. Larde D, Mathieu D, Fria J, Gaston A, Vasile N. Spinal vacuum phenomenon: CT diagnosis and significance. *J Comput Assist Tomogr*. 1982;6:671–676.
4. Resnick D, Niwayama G, Guerra J, Vint V, Usselman J. Spinal vacuum phenomena: anatomical study and review. *Radiology*. 1981;139:341–348.
5. Gower WE, Pedrini V. Age-related variations in proteinopolysaccharides from human nucleus pulposus, annulus fibrosus, and costal cartilage. *J Bone Joint Surg Am*. 1969;51:1154–1162.
6. Yoshida H, Shinomiya K, Nakai O, Kurosa Y, Yamaura I. Lumbar nerve root compression caused by lumbar intraspinal gas: report of three cases. *Spine*. 1997;22(3):348–351.
7. Sauser DD, Goldman AB, Kaye JJ. Discogenic vertebral sclerosis. *J Can Assoc Radiol*. 1978;29:44–50.
8. Coulrier B. The spectrum of vacuum phenomenon and gas in spine. *JBR-BTR*. 2004;87:9–16.
9. Pierpaolo L, Luciano M, Fabrizio P, Paolo M. Gas-containing lumbar disc herniation: a case report and review of the literature. *Spine*. 1993;18(16):2533–2536.
10. Bosser V, Dietemann JL, Warter JM, Granel de Solignac M, Beaujeux R, Buchheit F. L5 radicular pain related to lumbar extradural gas-containing pseudocyst: role of CT-guided aspiration. *Neuroradiology*. 1990;31:552–553.
11. Demierre B, Ramadan A, Hauser H, Reverdin A, Rilliet B, Berney J. Radicular compression due to lumbar intraspinal gas pseudocyst: case report. *Neurosurgery*. 1988;22:731–733.
12. Lee CH, Cho JH, Hyun S-J, Yoon SH, Kim K-J, Kim HJ. Symptomatic gas-containing herniated disc with the vacuum phenomenon: mechanism and treatment. *Neurol Med Chir*. 2012;52:106–108.
13. Hasni Bouraoui I, Gamoun W, Mrad Dali K, et al. Pneumorrhachis: illustration de trois étiologies rares. *J Radiol*. 2010;91:495–499.
14. Mehta TA, Sharp DJ. Acute cauda equina syndrome caused by a gas-containing prolapsed intervertebral disk. *J Spinal Disord*. 2000;13:532–534.
15. Song KJ, Lee KB. Spontaneous extradural pneumorrhachis causing cervical myelopathy. *Spine J*. 2009;9:e16–e18.
16. Giraud F, Fontana A, Mallet J, Fischer LP, Meunier PJ. Sciatica caused by epidural gas, four case reports. *Joint Bone Spine*. 2001;68:434–437.
17. Odderson IR, Matthies R. Lumbar radiculopathy and intraspinal gas. *J Back Musculoskelet Rehabil*. 1995;5:155–158.
18. Kim CH. Pneumorrhachis and paraspinal air with vacuum disc: case report and literature review. *J Korean Neurosurg Soc*. 2007;42:490.
19. Impiombato FA, Lunghi V, Gambacorta D, Zocchi M. Treatment of a symptomatic epidural gas cyst using an angiographic 5F catheter in the epidural space of the spinal cord through the sacral hiatus: a case report. *Neuroradiol J*. 2011;24:914–918.
20. Pak KI, Hoffman DC, Herzog RJ, Lutz GE. Percutaneous intradiscal aspiration of a lumbar vacuum disc herniation: a case report. *HSS J*. 2011;7:89–93.
21. Kumar R, West CGH, Gillespie JE. Gas in a spinal extradural cyst: case report. *J Neurosurg*. 1989;70:486–488.
22. Ricca GF, Robertson JT, Hines RS. Nerve root compression by herniated intradiscal gas: case report. *J Neurosurg*. 1990;72:282–284.
23. Cheng TM, Link MJ, Onofrio BM. Pneumatic nerve root compression: epidural gas in association with lateral disc herniation: report of two cases. *J Neurosurg*. 1994;81:453–458.

24. Belfquih H, mostarchid BE, Akhaddar A, gazzaz M, Boucetta M. Sciatica caused by lumbar epidural gas. *Pan Afr Med J*. 2014;18:162.
25. Akhaddar A, Eljebbouri B, Naama O, Boucetta M. Sciatica due to lumbar intraspinal gas pseudocyst. *Intern Med*. 2010;49:2647.
26. Tamburrelli F, Leone A, Pitta L. A rare cause of lumbar radiculopathy: spinal gas collection. *J Spinal Disord*. 2000;13:451-454.
27. Kawaguchi S, Yamashita T, Ida K, Ikeda T, Ohwada O. Gas-filled intradural cyst of the lumbar spine: case report. *J Neurosurg Spine*. 2001;95:257-259.
28. Konya D, Ozgen S, Sun IH, Pamir NM. Intraspinal gas. *J Clin Neurosci*. 2007;14:569-572.
29. Ryu KS, Rathi NK, Shin MH, Park CK. Gas-containing disc herniations: dual nerve root compression at a single disc level. *Neurol Med Chir*. 2012;52:649-651.
30. Hidalgo-Ovejero ÁM, García-Mata S, Gozzi-Vallejo S, Izco-Cabezón T, Martínez-Morentín J, Martínez-Grande M. Intradural disc herniation and epidural gas: something more than a casual association? *Spine*. 2004;29(20):E463-E467.
31. Mortensen WW, Thorne RP, Donaldson WF. Symptomatic gas-containing disc herniation. Report of four cases. *Spine*. 1976;1991(16):190-192.
32. Anda S, Støvring J, Rø M. CT of extraforaminal disc herniation with associated vacuum phenomenon. *Neuroradiology*. 1988;30:76-77.

How to cite this article: Lassoued Ferjani H, Ben Ammar L, Kaffel D, et al. Radiculopathies caused by spontaneous pneumorrhachis: Two case reports and review of literature. *Clin Case Rep*. 2021;9:e05061. <https://doi.org/10.1002/ccr3.5061>