



Original Article

Outcomes of non-arthroplasty surgical treatment of proximal humeral head fractures[☆]



Alberto Naoki Miyazaki, Pedro Doneux Santos, Guilherme do Val Sella*, Denis Cabral Duarte, Giovanni Di Giunta, Sergio Luiz Checchia

Irmandade da Santa Casa de Misericórdia de São Paulo, Faculdade de Ciências Médicas da Santa Casa de São Paulo, Departamento de Ortopedia e Traumatologia, São Paulo, SP, Brazil

ARTICLE INFO

Article history:

Received 3 September 2015

Accepted 3 December 2015

Available online 20 August 2016

Keywords:

Epiphyses/injuries

Fracture fixation, internal

Shoulder fractures/surgery

Shoulder/surgery

Treatment outcome

Adult

ABSTRACT

Objective: This study aimed to assess the outcomes of patients with humeral head fractures treated by reduction and osteosynthesis.

Method: A total of 53 shoulders (52 patients) with humeral head fractures were operated between October 1996 and December 2009. Patients previously treated with primary arthroplasty and/or those who had less than two years follow-up were excluded. A total of 34 shoulders of 34 patients were therefore reassessed. In the sample studied, 23 patients were male and mean age was 47 years. Cases were assessed based on the UCLA score.

Results: Mean post-operative follow-up was 50 months. Twelve patients evolved with excellent outcome, seven good, five regular, and ten with poor outcome (55.8% satisfactory and 44.2% unsatisfactory outcomes). Mean UCLA score was 26 points. Mean post-operative range of motion measurements was 117° elevation, 36° LR and L1 MR. At the immediate post-operative radiography, anatomic reduction was evident in 17 patients (50%). Necrosis was detected in 18 patients, six Grade II and 12 Grade III cases. Female gender and anatomically reduced fractures were statistically better at UCLA scale ($p = 0.01$ and $p = 0.0001$ respectively). **Conclusions:** Female patients had a higher mean UCLA score than male patients ($p = 0.01$). Anatomically reduced fractures had higher UCLA scores ($p = 0.0001$) and lower necrosis rate ($p = 0.0001$). Reconstruction of humeral head fractures had a satisfactory outcome in 55.8% of cases and should be indicated in young and active patients.

© 2016 Sociedade Brasileira de Ortopedia e Traumatologia. Published by Elsevier Editora Ltda. This is an open access article under the CC BY-NC-ND license (<http://creativecommons.org/licenses/by-nc-nd/4.0/>).

[☆] Study conducted at the Shoulder and Elbow Group, Department of Orthopedics and Traumatology, Irmandade da Santa Casa de Misericórdia de São Paulo, Faculdade de Ciências Médicas da Santa Casa de São Paulo, São Paulo, SP, Brazil.

* Corresponding author.

E-mail: gvsella@gmail.com (G.V. Sella).

<http://dx.doi.org/10.1016/j.rboe.2016.08.011>

2255-4971/© 2016 Sociedade Brasileira de Ortopedia e Traumatologia. Published by Elsevier Editora Ltda. This is an open access article under the CC BY-NC-ND license (<http://creativecommons.org/licenses/by-nc-nd/4.0/>).

Resultados do tratamento cirúrgico não artroplástico das fraturas da epífise proximal do úmero

R E S U M O

Palavras-chave:

Epifises/lesões
Fixação interna de fraturas
Fraturas do ombro/cirurgia
Ombro/cirurgia
Resultado do tratamento
Adulto

Objetivo: Avaliar os resultados dos pacientes com fraturas epifisárias tratados com redução e osteossíntese.

Método: Entre outubro de 1996 e dezembro de 2009 foram operados 53 ombros (52 pacientes) com fraturas epifisárias. Foram excluídos os pacientes tratados com artroplastia primária e/ou que tinham seguimento inferior a dois anos. Foram reavaliados 34 ombros de 34 pacientes, 23 do sexo masculino, com média de 47 anos. A avaliação foi feita com a escala da UCLA.

Resultados: O tempo de seguimento pós-operatório médio foi de 50 meses. Doze pacientes evoluíram com resultados excelentes, sete bons, cinco regulares e dez maus (55,8% de resultados satisfatórios e 44,2% de insatisfatórios). O escore UCLA teve média de 26 pontos. As médias de mobilidade pós-operatória foram de 117° de elevação, 36° de RL e L1 de RM. No RX pós-operatório imediato, verificamos a redução anatômica em 17 pacientes (50%). A necrose foi constatada em 18 pacientes, seis grau II e 12 grau III. Sexo feminino e fraturas reduzidas anatomicamente foram estatisticamente melhores na escala da UCLA ($p=0,01$ e $p=0,0001$ respectivamente).

Conclusões: O sexo feminino teve um valor médio do UCLA superior ao sexo masculino ($p=0,01$). As fraturas reduzidas anatomicamente obtiveram UCLA superior ($p=0,0001$) e um menor índice de necrose ($p=0,0001$). A reconstrução das fraturas epifisárias levou a resultados satisfatórios em 55,8%, deve ser indicada para pacientes jovens e ativos.

© 2016 Sociedade Brasileira de Ortopedia e Traumatologia. Publicado por Elsevier Editora Ltda. Este é um artigo Open Access sob uma licença CC BY-NC-ND (<http://creativecommons.org/licenses/by-nc-nd/4.0/>).

Introduction

Proximal humeral head fractures (PHHF) are rare and their treatment is always a challenge for the orthopedic surgeon, due to the complexity of the fracture lines and high complication rates.¹⁻⁴

Neer³ considers them as part of the group of fracture-dislocations, because a surface of the articular fragment is compressed or fragmented against the glenoid cavity and the rest is incongruent with it. He subdivided fracture-dislocations into two types: impaction and those with an epiphyseal line.^{3,5} In the first, impaction, the articular surface sinks due to compression of the humeral head against the edge of the glenoid at the time of dislocation, regardless of direction: anterior (Hill-Sachs lesion) or posterior (MacLaughlin lesion).³ The second type are the head fractures of the humerus with epiphyseal line (epiphyseal fractures), caused by the impact of the humeral head against the glenoid cavity, which fragments the articular surface (Fig. 1).³ These are usually associated with three- and four-part fractures, are related to high-energy trauma, and usually occur in young patients.^{2,3,6,7} They are characterized by great involvement of blood supply to the humeral head and its fragments; therefore, they often evolve into necrosis.³

Gerber et al.⁸ included epiphyseal fractures in the set of complex fractures, defining them as fractures in which the cephalic segment is highly offset, with greatly impaired vascularization, presenting a higher risk of osteonecrosis and collapse of the humeral head. In addition to epiphyseal fractures, this group includes two-part fractures

of the anatomical neck and three- and four-part fracture-dislocations.⁷

There are some reports in the literature of isolated cases in which the authors comment on the rarity of the injury.^{6,9} Chesser et al.² described eight patients with epiphyseal fracture, three of whom underwent open reduction and internal fixation (ORIF). Gerber et al.⁷ treated 32 complex fractures using ORIF; only two were classified as epiphyseal, which had a good outcome.

Some authors indicate hemiarthroplasty as the treatment of choice for epiphyseal fractures, due to technical difficulties in achieving an anatomic reconstruction of the bone and of maintaining such reconstruction through osteosynthesis. Furthermore, ORIF in this kind of fracture progresses with high complication rates, including malunion, pseudarthrosis, and osteonecrosis.^{1,3,5,10-14} Hemiarthroplasty leads to satisfactory results to the patient regarding pain improvement, but usually there is loss of lifting strength and decreased range of motion, i.e., it is observed that the functional outcome of arthroplasties for the treatment of fractures is generally unsatisfactory.^{10,15}

This study aimed to evaluate the results of patients treated with ORIF of the PHHF.

Methods

Between October 1996 and December 2009, the Shoulder and Elbow Group, Department of Orthopedics and Traumatology, Santa Casa de Misericórdia de São Paulo – Fernandinho Simonsen Pavilion, a tertiary referral hospital for severe cases, operated on 53 shoulders of 52 patients with epiphyseal

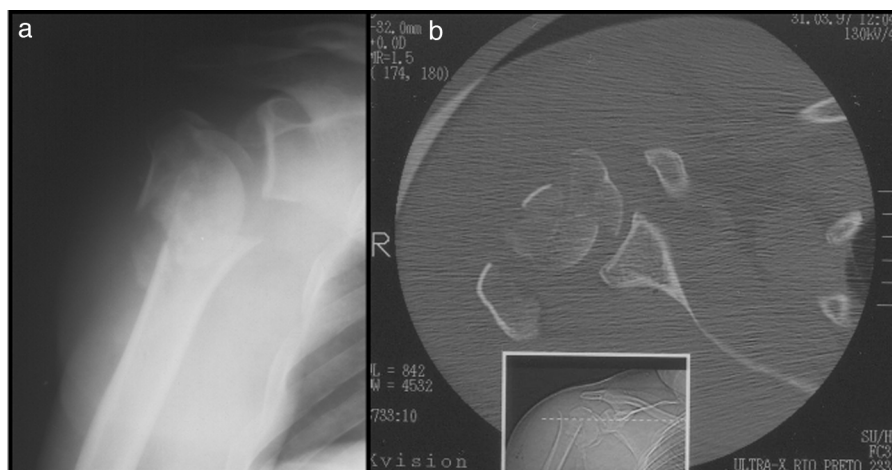


Fig. 1 – Case 4 – epiphyseal fracture of the proximal third of the right humerus into four parts: frontal radiograph (a) and computed axial tomography (b).

fractures. The inclusion criteria comprised all adult patients undergoing non-arthroplasty surgical treatment of proximal humerus fractures classified as epiphyseal, who were followed-up for at least two years in the postoperative period. Patients with epiphyseal fractures treated with primary arthroplasty and/or those with less than two years of follow-up were excluded. Primary arthroplasty was indicated for patients who were considered to be less active and in those cases where reconstruction surgery was not possible during the procedure, which prevented its fixation. Thus, 34 shoulders of 34 patients were reassessed.

Of the patients, 23 were male (67.6%) and 11 female (32.4%), with a mean age of 47 years (range: 24–77; Table 1), and 35.3% of patients were younger than 40 years. The dominant limb was affected in 15 cases (44.1%).

Trauma mechanisms were: falling to the ground in 14 (41.3%), automobile accident in seven (20.6%), motorcycle accident in six (17.6%), fall from height in four (11.7%), and being run over in three (8.8%; Table 1).

Two patients (cases 8 and 15) had, in addition to the fracture, neurological damage to the affected limb.

In all patients, “trauma series radiographs” (corrected frontal, axillary profile, and scapula profile) were made for fracture classification.⁴⁻¹⁶ Computed tomography was performed in cases where there was doubt as to fracture classification (27 patients). All fractures affected the articular

surface of the humeral head: in four cases (11.8%) the epiphyseal fracture was associated with fracture of anatomical neck in two parts; in 12 cases (35.2%), in three parts; and in 18 cases (53%), in four parts, according to the Neer³ classification (Table 1).

The mean interval between trauma and surgery was seven days, ranging from zero to 15 days (Table 2); in 55.8% of patients, this interval was less than one week.

The chosen surgical treatment method was ORIF, through the deltopectoral approach, choosing the least traumatic surgical technique possible. Fixation methods varied according to the type of fracture and the material available at the time of the procedure, as specified in Table 2. PFS-80[®] plates,⁵ external fixators, cloverleaf plate, Kirschner wires, Philos[®] plate, ligature with a non-absorbable suture (Ethibond[®]), and cancellous screws. In some procedures, more than one fixation method was used. The Philos[®] plate was used in 14 patients (43.1%) (Table 2).

Autologous cancellous bone from the iliac crest was used as necessary, according to the comminution, in eight patients, which corresponds to 23.5% of the cases (Table 2).

Shoulder mobility was measured by a goniometer. The parameters of the American Academy of Orthopedic Surgeons (AAOS) were used.¹⁷ Results were assessed by the points system established by the University of California at Los Angeles (UCLA), proposed by Ellman and Kay.¹⁸ The Ficat and Enneking

Table 1 – Epidemiological data of patients with epiphyseal humeral fracture.

N	Age (Mean, years)	Sex	Trauma	Fracture
34	47 (24–77)	M (67.6%) F (32.4%)	Fall to the ground (41.3%) Car accident (20.6%) Motorcycle accident (17.6%) Fall from height (11.7%) Being run over (8.8%)	4P ft-dis post (11.8%) 4P (41.2%) 3P (35.2%) 2P (11.8%)

Source: Medical records of the Hospital.

N, number of cases; M, male; F, female; P, parts; ft, fracture; dis, dislocation; post, posterior.

Table 2 – Treatment data of patients with epiphyseal humeral fracture.

N	DT (Mean, days)	Surgery	Bone graft	IPO
34	7 (0–15)	Cancellous screws (53%) Philos® plate (43.1%) Kirschner wires (23.5%) PFS80® plate (17.6%) LNS (8.8%) Cloverleaf plate (5.9%) External fixator (3%)	8 cases (23.5%)	Anatomical reduction (50%) Joint incongruency (50%)

Source: Medical records of the Hospital.
N, number of cases; DT, time interval between the fracture and the treatment; LNS, stitching with a non-absorbable suture; IPO, immediate postoperative period.

Table 3 – Results of patients treated for epiphyseal fracture of the proximal humerus.

N	Mean follow-up (months)	ROM (mean)	Necrosis	UCLA (mean)
34	50 (24–156)	E 117° (50° to 160°) LR 36° (–20° to 70°) MR L1 (T5 to Troc)	Absence (16 pts, 47.1%) Grade 1 (0) Grade 2 (6 pts, 17.6%) Grade 3 (12 pts, 35.3%)	26 (9–35)

Source: Medical records of the Hospital.
N, number of cases; ROM, range of motion; E°, elevation in degrees; LR°, lateral rotation in degrees; MR, medial rotation; Troc, trochanteric; pts, patients.

classification, modified by Neer, was also used for the evaluation of humeral head osteonecrosis when present.¹⁹

The Minitab version 16.0 software was used for statistical analysis. The nonparametric Mann-Whitney test was used to evaluate the following variables: gender, age (≤ 40 years or >40 years), dominant side, time interval between the date of trauma and surgery (Δt), type of fracture, osteosynthesis method, use of graft, immediate postoperative radiograph, and the presence or absence of humeral head osteonecrosis in the final radiograph, compared to the end result of treatment, with $p \leq 0.05$.

This study was assessed and approved by the hospital's Research Ethics Committee.

Results

Minimum postoperative follow-up time was 24 months and maximum was 156 months, with a mean of 50 months. Twelve patients had excellent results; seven, good; five, regular; and ten, poor. Therefore, 55.8% of the results were considered satisfactory (excellent and good) and 44.2%, unsatisfactory (regular and poor). Mean UCLA score was 26 points; the lowest value was 9 and the highest value, 35 (Table 3).

Mean postoperative mobility measures were 117° elevation (50° to 160°), 36° lateral rotation (–20° to 70°), and lumbar vertebra (L1) in medial rotation (T5 to trochanteric region; Table 3).

In the immediate postoperative radiograph, it was observed whether the reduction of the fracture was anatomical or if there was joint incongruity. Anatomical reduction occurred in 17 patients (50%). In the final radiograph, the presence of necrosis of the humeral head was observed in 18 patients (52.9%), six classified as grade II and 12 as grade III (Table 3).

Five cases had complications: two patients had synthesis material in the intra-articular space (cases 5 and 10) and underwent surgery for implant removal; one patient (case 8) had neurological damage – iatrogenic neurotmesis of the axillary nerve; two patients developed infection (cases 13 and 17).

When the UCLA variable was assessed in relation to age (≤ 40 years or >40 years), no statistically significant difference was observed ($p=0.94$). This demonstrates that age did not influence the functional outcome of the shoulder in these patients. The same was observed for the dominant limb ($p=0.30$), the number of parts of the fracture ($p=0.37$), the type of fixation (using or not using the blocked Philos® plate) ($p=0.87$), and the use of autologous bone graft ($p=0.56$).

In relation to gender, it was observed that females had a higher mean UCLA than males, a statistically significant difference ($p=0.01$). Patients whose fracture was anatomically reduced, as observed in the immediate postoperative radiograph, obtained a higher UCLA ($p=0.0001$), as well as patients who did not develop necrosis ($p=0.0001$).

For the variable time interval between trauma and surgery, a descriptive level (p) equal to 0.11 was observed. It can be concluded that, at the 5% significance level, there was no difference in the observed mean UCLA scores. However, the descriptive level was very close to the significance level, suggesting that calculations made with a larger sample may change this conclusion.

To test the significant linear correlation between the UCLA variables and the time between trauma and surgery (Δt), Pearson's linear correlation coefficient was calculated as 0.340 ($p=0.049$). This indicates that there is a decreasing linear relationship between these variables, i.e., the greater the time interval, the lower the UCLA index.

This significant correlation motivated the construction of a multiple regression model with the index variable UCLA score

Table 4 – Published scientific articles.

Collopy D, Skirving A. Transcondral fracture dislocation of the shoulder. <i>J Bone Joint Surg Br</i> 1995.	Report of one case
Chesser TJ, Langdon IJ, Ogilvie C, Sarangi PP, Clarke AM. Fractures involving splitting of the humeral head <i>J Bone Surg Br</i> .	Eight cases (only three underwent ORIF)
Gerber C, Werner CML, Vienne P. Internal fixation of complex fractures of the proximal humerus. <i>J Bone Joint Surg Br</i> 2004.	32 (only two epiphyseal fractures)
Bailie AG, McAlinden MG. Complex head-splitting fracture-dislocation of the proximal humerus successfully treated with minimal internal fixation: a case report and discussion. <i>Injury</i> 2006.	Report of one case

as the dependent variable, and using as independent variables gender (1 when the patient is male and 0 when female), elapsed time interval (days), and the presence of necrosis (1 when it occurred and 0 otherwise).

$$UCLA = 39.5 - 3.72X_{\text{Gender}} - 0.592X_{\text{At}} - 11.6X_{\text{Necrosis}}$$

It is worth mentioning that the model indicates that there is a decrease in the UCLA index of 3.72 when the patient is male, of 0.592 for every elapsed day, and of 11.6 when there is necrosis.

Discussion

PHHF is an uncommon injury.¹⁻⁴ However, Palvanen et al.²⁰ suggest that the incidence of proximal humerus fractures will triple in the next 30 years. There are few published studies that compare the results of ORIF of the PHHF. The present study included 34 patients, the greatest sample found in studies published in recent years (Table 4).

The prevalence of patients that were considered young observed in the present study, with a mean age of 47 year-old

(35.3% under 40 years), is in agreement with that observed in the literature, as well as the prevalence of males (67.6%; Table 1).^{6,7,9} Women had a higher mean UCLA score; however, there are no published studies to compare this finding. These results are probably related to the lower-energy mechanism of injury in this group, since 72.7% of the women experienced fall to the ground, while the trauma mechanisms in men were higher-energy.

It was observed that the shorter the time between trauma and surgery, the better the results. Although this association was not statistically proven, the analysis suggests that a larger sample would be able to do so.

Based on the difficulty of reconstructing the anatomy (Fig. 2) and the high risk of osteonecrosis, hemiarthroplasty is a treatment option for PHHF, but it must be borne in mind that these are extremely serious fractures affecting young patients, in which the partial arthroplasty will likely lead to worse results.

With a mean of 63 months of follow-up, Gerber et al.⁷ described in their study on complex fractures a case of epiphyseal fracture reduction which was not considered anatomical and developed partial osteonecrosis, presenting regular result.

Schai et al.,¹⁴ in a multicenter study on severe fractures of the humeral neck, concluded that the patient's age is an important factor in the choice of treatment and that there is a higher probability of humeral head revascularization, through intramedullary vessels and their anastomoses, when stable osteosynthesis is used. Gerber et al.⁸ and Chesser et al.² advocate treatment with reduction and osteosynthesis, because even in case of unfavorable development, the replacement revision would be technically easier than the primary hemiarthroplasty if an anatomical reconstruction had been obtained.

A wide variety of fixation methods (Table 2) were used in the present study; choice was made according to the type of fracture and the material available at the time; the most prevalent methods were the Philos[®] plate, used in 14 cases, and cancellous screws, used in 18 patients. Collopy and Skirving⁹ used two cancellous screws as a fixation method, as well as Bailie and McAlinden.⁶ Warner et al.⁴ reported a preference

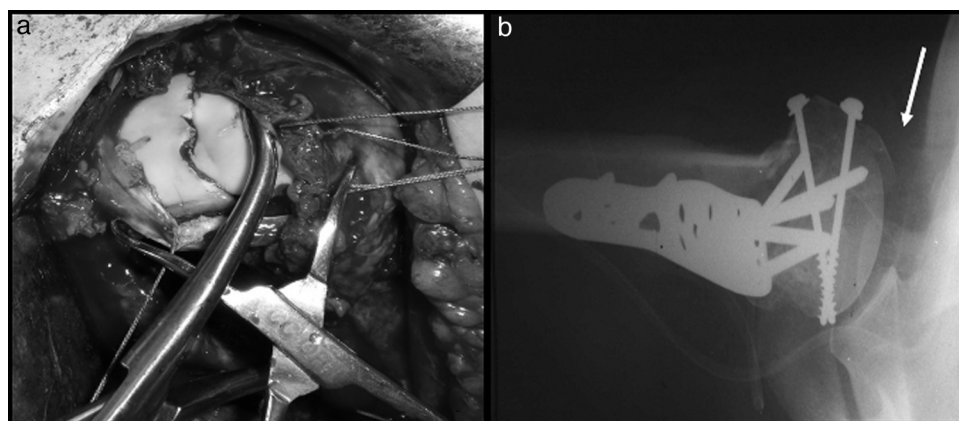


Fig. 2 – Case 23 – epiphyseal fracture of the proximal third of the right humerus in three parts: intraoperative image, showing open reduction of the humeral head (a) and osteosynthesis with cannulated screws and Philos[®] plate. However, anatomical reduction was not achieved even with open reduction; joint incongruity can be observed (b) (arrow).

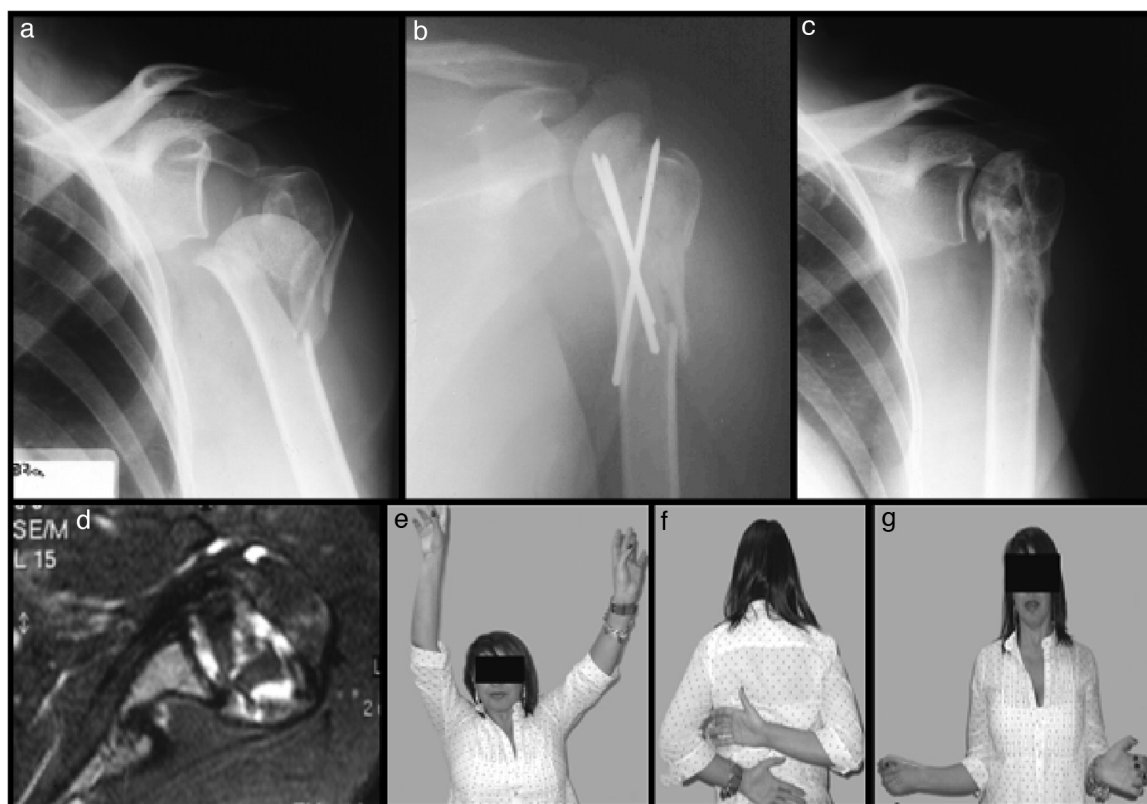

Fig. 3 – Case 12 – fracture of the proximal third of the left humerus in four parts, impacted in valgus with epiphyseal line: frontal radiographic image of the left shoulder (a) showing the acute fracture and after fixation (immediate post-operative period) with threaded wires and stitching of the greater tuberosity (b). Consolidated fracture two years and six months postoperative, but with signs of necrosis and collapse of subchondral bone in the frontal radiography (c) and axial T2-weighted MRI (d). Clinical picture of patient with range of motion of 125° elevation, (e) L1 in medial rotation (f) and 10° lateral rotation (g). Good final result (UCLA = 29 points).

for using screws, whether cannulated or not, for this type of fracture.

No significant differences were observed between the synthesis material used and the final result. Gerber et al.⁷ and Moonot et al.²¹ support the thesis that a good result can be obtained when there is an anatomical reconstruction of the fracture. In the present study, fractures with anatomical reduction evolved with good and excellent results ($p=0.0001$).

Several authors have reported the importance of filling with bone graft the space between the humeral head and metaphyseal region that is created during reduction of the fracture, due to the loss of trabecular bone due to compression of the joint surface at the time of trauma. This is done in an attempt to promote greater bone support and help local revascularization.^{22,23} In the present study, autologous bone graft from the iliac crest was used in eight patients; five of them developed some degree of osteonecrosis. Similarly to Gerber et al.,⁷ no relationship was observed in the present study between the use of bone graft and the development of osteonecrosis. However, there is a bias in the present study, since bone graft was used for more comminuted fractures.

Humeral head osteonecrosis is a common complication of complex shoulder fractures, with an incidence of 9% to

75%.^{3,8,23-25} Its presence is not associated with poor functional outcome, particularly in patients with necrosis up to grade II. These patients may present satisfactory clinical results, especially in cases where the anatomy of the proximal third of the humerus was restored during surgery (Fig. 3).^{8,26}

Of the 34 cases in the present study, 18 patients (52.9%) developed humeral head osteonecrosis, six classified as grade II and 12 as grade III (Table 3). The presence of necrosis also led to the rejection of the hypothesis of equality between the mean UCLA scores, which were higher in patients without necrosis ($p=0.0001$).

Two patients (cases 8 and 15) suffered neurological damage the traumatized limb and some kind of sequelae persisted during follow-up. Both evolved with unsatisfactory results and osteonecrosis grade III; this fact may be a bias of the present study when considering the osteonecrosis results. Nerve injury contributed, in a greater or lesser degree, to the decreased shoulder function (Fig. 4).

Two cases of osteomyelitis of the proximal humerus were observed. Case 13, after 21 months of follow-up, underwent resection arthroplasty, while case 17, a patient with thromboangiitis obliterans (Berger's disease), underwent removal of the synthesis material. Despite the poor result, this patient did not present clinical conditions to undergo surgery.

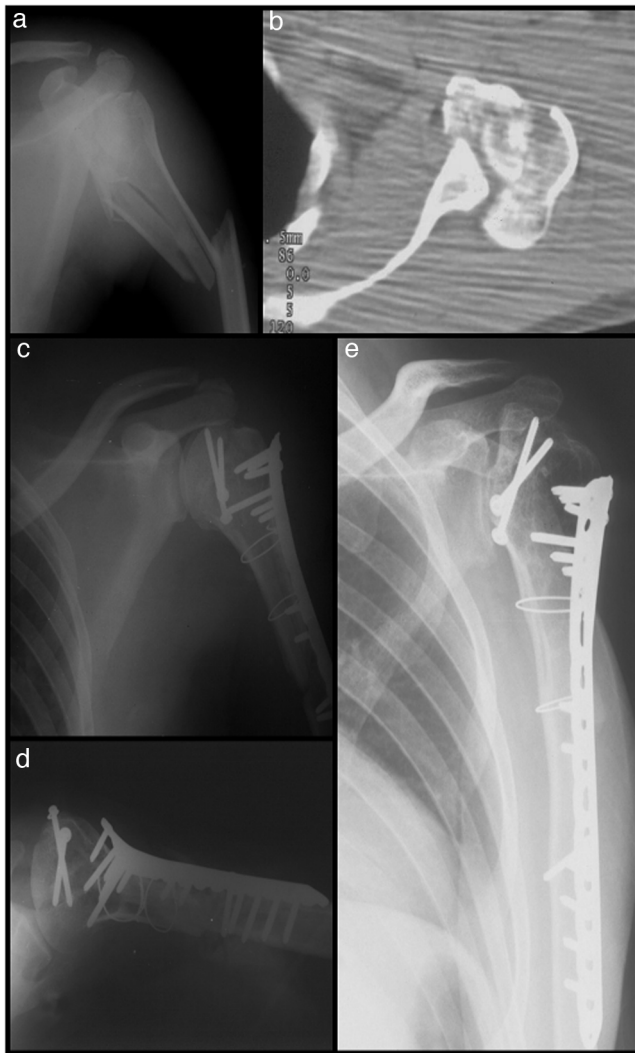


Fig. 4 – Case 15 – complex fracture of the left proximal humerus with traumatic brachial plexus injury: frontal radiograph of the shoulder (a) and axial computed tomography image (b) showing the epiphyseal fracture. Immediate postoperative radiographic image showing the double-line signal (c), in axillary profile showing the articular incongruity (d), and 18-month postoperative radiograph showing grade II necrosis (e). This patient evolved with unsatisfactory results (UCLA = 18).

Conclusion

It can be concluded that the ORIF of the PHHF led to good and excellent results in 55.8% of cases; it should be indicated in cases of young patients and active adults.

It was observed that female gender, shorter interval of time between the trauma and surgery, anatomical reduction of the fracture as observed in the immediate postoperative radiograph, and the absence of osteonecrosis in the postoperative follow-up were factors that influenced the best results.

Conflicts of interest

The authors declare no conflicts of interest.

REFERENCES

1. Blaine TA, Bigliani LU, Levine WN. Fractures of the proximal humerus. In: Rockwood CA, Matsen FA 3rd, Wirth MA, Lippitt SB, editors. *The shoulder*. Philadelphia: Saunders; 2004. p. 355–412.
2. Chesser TJ, Langdon JJ, Ogilvie C, Sarangi PP, Clarke AM. Fractures involving splitting of the humeral head. *J Bone Surg Br*. 2001;83(3):423–6.
3. Neer CS. Displaced proximal humeral fractures. I. Classification and evaluation. *J Bone Joint Surg Am*. 1970;52(6):1077–89.
4. Warner JJP, Costouros JG, Gerber C. Fractures of the proximal humerus. In: Rockwood CA, Green DP, editors. *Fractures in adults*. Philadelphia: Lippincott Williams & Wilkins; 2006. p. 1163–210.
5. Neer CS. Four-segment classification of proximal humeral fractures: purpose and reliable use. *J Shoulder Elbow Surg*. 2002;11(4):389–400.
6. Bailie AG, McAlinden MG. Complex head-splitting fracture-dislocation of the proximal humerus successfully treated with minimal internal fixation: a case report and discussion. *Injury*. 2006;37(2):82–5.
7. Gerber C, Werner CM, Vienne P. Internal fixation of complex fractures of the proximal humerus. *J Bone Joint Surg Br*. 2004;86(6):848–55.
8. Gerber C, Hersche O, Berberat C. The clinical relevance of posttraumatic avascular necrosis of the humeral head. *J Shoulder Elbow Surg*. 1998;7(6):586–90.
9. Collopy D, Skirving A. Transchondral fracture dislocation of the shoulder. *J Bone Joint Surg Br*. 1995;77(6):975–6.
10. Compito CA, Self EB, Bigliani LU. Arthroplasty and acute shoulder trauma. Reasons for success and failure. *Clin Orthop Relat Res*. 1994;307:27–36.
11. Moeckel BH, Dines DM, Warren RF, Altchek DW. Modular hemiarthroplasty for fractures of the proximal part of the humerus. *J Bone Joint Surg Am*. 1992;74(6):884–9.
12. Nho SJ, Brophy RH, Barker JU, Cornell CH, MacGillivray JD. Management of proximal humeral fractures based on current literature. *J Bone Joint Surg Am*. 2007;89:44–58.
13. Prakash U, McGurty DW, Dent JA. Hemiarthroplasty for severe fractures of the proximal humerus. *J Shoulder Elbow Surg*. 2002;11(5):428–30.
14. Schai P, Imhoff A, Preiss S. Comminuted humeral head fractures: a multicenter analysis. *J Shoulder Elbow Surg*. 1995;4(5):319–30.
15. Checchia SL, Santos PD, Miyazaki AN, Fregoneze M, Silva LA. Tratamento das fraturas do terço proximal do úmero com a prótese parcial Eccentra. *Rev Bras Ortop*. 2005;40(3):130–40.
16. Checchia SL, Santos PD, Miyazaki AN, Fregoneze M, Silva LA. Padronização do estudo radiográfico da cintura escapular. *Rev Bras Ortop*. 1998;33(11):883–8.
17. *Joint motion: method of mensuring and recording*. Chicago: American Academy of Orthopaedics Surgeons; 1965.
18. Ellman H, Kay SP. Arthroscopic subacromial decompression for chronic impingement – two to five years results. *J Bone Joint Surg Br*. 1991;73(3):395–8.
19. Neer CS. Glenohumeral arthroplasty. In: Neer R, editor. *Shoulder reconstruction*. Philadelphia: Saunders; 1990. p. 143–272.

20. Palvanen M, Kannus P, Niemi S, Parkkari J. Update in the epidemiology of proximal humeral fractures. *Clin Orthop Relat Res.* 2006;(442):87-92.
21. Moonot P, Ashwood N, Hamlet M. Early results for treatment of three-and four-part of the fractures of the proximal humerus using the PHILOS plate system. *J Bone Joint Surg Br.* 2007;89(9):1206-9.
22. Resch H, Beck E, Bayley I. Reconstruction of the valgus-impacted humeral head fracture. *J Shoulder Elbow Surg.* 1995;4(2):73-80.
23. Russo R, Visconti V, Lombardi LV, Ciccarelli M, Giudice G. The block-bridge system: a new concept and surgical technique to reconstruct articular surfaces and tuberosities in complex proximal humeral fractures. *J Shoulder Elbow Surg.* 2008;17(1):29-36.
24. Resch H, Provacz P, Fröhlich R, Wambacher M. Percutaneous fixation of three-and four-part fractures of the proximal humerus. *J Bone Joint Surg Br.* 1997;79(2):295-300.
25. Sturzenegger M, Fornaro E, Jakob RP. Result of surgical treatment of multifragmented fractures of the humeral head. *Arch Orthop Trauma Surg.* 1982;100(4):249-59.
26. Lee CK, Hansen HR. Post-traumatic avascular necrosis of the humeral head in displaced proximal humeral fracture. *J Trauma.* 1981;21(9):788-91.