



The effect of pars plana vitrectomy with internal limiting membrane peeling on the durability of the intravitreal dexamethasone implant in the treatment of diabetic macular edema

Elia Franzolin^{a,*}, Elena Gusson^a, Giacomo Panozzo^b

^a Ophthalmic Unit, Department of Neurosciences, Biomedicine and Movement Sciences, University of Verona, Verona, Italy

^b Department of Ophthalmology, Bussolengo Civil Hospital, Verona, Italy

ARTICLE INFO

Keywords:

Dexamethasone intravitreal implant
Diabetes
Diabetic macular edema
Internal limiting membrane peeling
Pars plana vitrectomy

ABSTRACT

Purpose: To evaluate the influence of pars plana vitrectomy with internal limiting membrane peeling on recurrence time of diabetic macular edema in eyes under treatment with dexamethasone intravitreal implant injections.

Material and methods: Twelve pseudophakic eyes of 12 patients with non-proliferative diabetic retinopathy and non-tractional diabetic macular edema were included. All eyes had already been treated with two or more dexamethasone intravitreal implant injections evidencing a recurrence time of three months or less (early recurrence). At baseline, they underwent pars plana vitrectomy with internal limiting membrane peeling, ending with dexamethasone intravitreal implant injection. Patients were then followed-up monthly, treated with a second injection at the first recurrence, and followed up to the second recurrence. Measurements of best corrected visual acuity, intraocular pressure, and central foveal thickness by spectral-domain optical coherence tomography were performed at each follow-up examination.

Results: Vitrectomized eyes showed a significant extension of recurrence time of diabetic macular edema, and specifically from 3.4 (3.2–3.7) to 6.5 (5.7–8.2) months after the first injection, and to 7.0 (5.7–8.2) months ($p < 0.01$) after the second injection ($p < 0.01$).

Conclusions and importance: Pars plana vitrectomy with internal limiting membrane peeling seems not to influence functional and anatomical results in eyes under treatment with dexamethasone intravitreal implant injections for diabetic macular edema, but appears to significantly extend the benefit of the drug.

1. Introduction

Diabetic macular edema (DME) represents a major cause of visual loss, affecting up to 12.8% of diabetic patients.¹ A slow-release intravitreal implant of 0.7 mg Dexamethasone (DEX-I) (Ozurdex, Allergan, Dublin, Republic of Ireland) is a proven therapy for DME, improving Best Corrected Visual Acuity (BCVA) and reducing Central Foveal Thickness (CFT) for up to six months,² although in some eyes the first signs of recurrence are found after three or four months.^{3–5}

The vitreous body, together with the posterior hyaloid and the internal limiting membrane (ILM), may be involved in the pathogenesis of DME,^{6–8} and pars plana vitrectomy (PPV) may have a positive functional effect especially when macular traction is evident. Nevertheless, before

the advent of intravitreal therapy, many case series reported positive effects of PPV also in eyes with non-tractional DME.^{9–12}

In the last years, it has been reported that PPV does not influence the functional or anatomical efficacy of DEX-I on DME in terms of visual acuity.^{13–16} Until now, it has not yet been analyzed if surgery may influence another interesting parameter: the duration of efficacy. This brief report aims to give contribution to filling this gap.

2. Materials and methods

Twelve eyes of 12 consecutive patients with non-proliferative diabetic retinopathy and non-tractional DME, and followed at the Ophthalmology Unit of Bussolengo General Hospital (Verona, Italy)

* Corresponding author. Ophthalmic Unit, Department of Neurosciences, Biomedicine and Movement Sciences, University of Verona, P.le L. A. Scuro 10, 37134, Verona, Italy.

E-mail address: franzolinelia@gmail.com (E. Franzolin).

<https://doi.org/10.1016/j.ajoc.2022.101401>

Received 11 February 2021; Received in revised form 28 January 2022; Accepted 1 February 2022

Available online 17 February 2022

2451-9936/© 2022 The Authors.

Published by Elsevier Inc.

This is an open access article under the CC BY-NC-ND license

(<http://creativecommons.org/licenses/by-nc-nd/4.0/>).

were included in this study. All eyes had already been treated with two or more DEX-I and had evidenced an "early recurrence" of DME, defined as BCVA worsening by 5 or more letters on the Early Treatment Diabetic Retinopathy Study (ETDRS) chart and/or CFT increasing by 50 μm within three months after the moment of greatest therapeutic efficacy.¹⁷

The following exclusion criteria have been established: previous ocular surgeries other than cataract surgery (including laser photocoagulation), previous treatment with intravitreal anti-VEGF, epiretinal membrane, glaucoma, or history of ocular hypertension, and uncontrolled or severe systemic disease.

At the time of the following DME recurrence (baseline), patients underwent PPV + ILM peeling plus DEX-I injection. All surgeries have been performed by the same surgeon (GP): core vitrectomy with the creation of posterior vitreous detachment (needed in 20% of eyes) and dye-assisted (brilliant blue) ILM peeling with a radius of one disc diameter. Levels of Hemoglobin A1c (HbA1C) were measured at the time of enrollment.

Patients were followed monthly with a complete ocular examination including BCVA measurement with ETDRS charts, slit-lamp biomicroscopy, Goldmann tonometry, dilated funduscopy and Spectral Domain Optical Coherence Tomography (SD-OCT) scan to measure the central foveal thickness (CFT), and then have been re-injected until the second consecutive DME recurrence (see above for definition). Following patients for two consecutive recurrences has allowed us to determine if the potential effect of surgery could be temporary or persistent.

3. Statistical analysis

Demographical and clinical data are presented as median (interquartile range, IQR). Due to the small sample and the non-normal distribution of the analyzed data, non-parametric tests have been chosen. A two tailed Wilcoxon signed-rank test has been used to compare CFT, BCVA and DME recurrence time of the pre- and post-surgery periods. For statistical significance, a p-value <0.05 has been considered. All statistical analysis have been done in XLSTAT Version 2018.6 (Addinsoft).

4. Results

Twelve eyes of 12 patients have been enrolled in the study between November 2018 and April 2019. Seven subjects were male and five were female. Clinical characteristics of enrolled patients and eyes at baseline are reported in Table 1.

10 out of 12 enrolled patients presented DME in the fellow eye: six eyes were under treatment with DEX-I every 6 months (no evidence of

"early recurrence"), and four eyes were affected by sub-atrophic DME.

Two months after treatment, we found a significant reduction in CFT ($p < 0.001$) and improvement of BCVA ($p < 0.01$) when compared to baseline. The median CFT decreased from 566 μm (506–604 μm) to 226 μm (196–275 μm), while the median BCVA improved from 60 ETDRS letters (45–65 letters) to 70 ETDRS letters (69–71 letters). The time elapsed before the 1st DME recurrence differed significantly from the one previous to the surgery and specifically extended from 3.4 months (3.2–3.7 months) to 6.5 months (5.7–8.2 months) ($p < 0.01$). Only 1 out of 12 patients recurred within 4 months (Fig. 1). Similarly to the first round of treatment, the timing of 2nd DME recurrence showed a statistically significant difference when compared to the pre-vitrectomy period, reaching 7.0 months (5.7–8.2 months) ($p < 0.01$). Even after the second injection, only 1 out of 12 eyes needed retreatment within 4 months from the 1st recurrence. The timing of the 1st and 2nd DME recurrence did not show a significant change ($p = 0.629$). Two months after the 2nd treatment, the median CFT was 209 μm (200–253 μm) and the median BCVA was 65 ETDRS letter (range: 60–71).

No adverse events (including raised intraocular pressure) have been recorded throughout the follow-up.

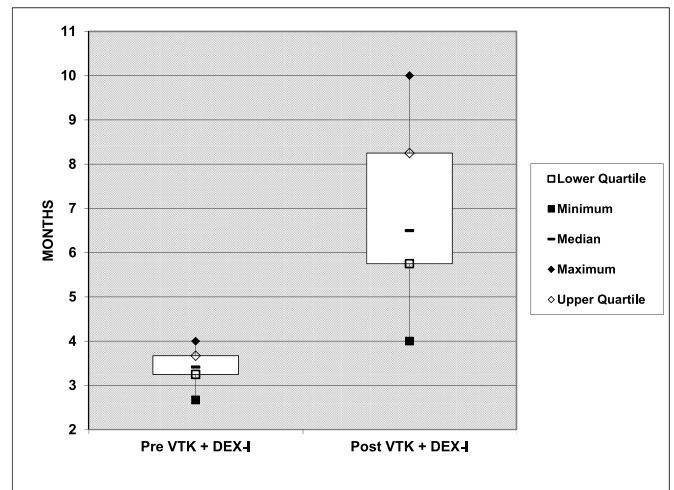


Fig. 1. DME recurrence time before and after surgery. DEX-I: dexamethasone intravitreal implant; VTK: vitrectomy.

Table 1
Characteristics of enrolled patients at baseline.

Patient ID	Age	Duration of DM2 (Years)	Insulin Use	HbA1c (%)	DR stage	CFT (um)	BCVA (ETDRS letters)	Number of previous DEX-I	Mean Recurrence Time (months)
1	65	18	No	8.1	Severe NP	600	35	3	3.33
2	57	8	Yes	7.4	Moderate NP	555	35	2	3
3	66	15	Yes	6.6	Mild NP	443	50	3	3.33
4	54	4	Yes	7.3	Mild NP	654	50	3	2.67
5	61	6	Yes	7.3	Moderate NP	529	65	2	4
6	60	8	Yes	7.8	Moderate NP	602	60	3	3.67
7	59	15	No	7.6	Mild NP	577	65	3	3.67
8	55	11	No	8.3	Severe NP	490	65	3	3.67
9	59	7	No	8.1	Moderate NP	623	60	3	3
10	54	3	No	7.7	Mild NP	412	70	2	3.5
11	62	10	No	8.2	Severe NP	611	65	3	3.5
12	59	10	Yes	6.8	Severe NP	512	50	3	3.33
Whole Sample	59 (56.5–61.2)	9 (6.7–12)	Yes: 6 No: 6	7.6 (7.3–8.1)	Mild NP: 4 Mod. NP: 4 Sev. NP: 4	566 (506–604)	60 (50–65)	3 (2.7–3.0)	3.4 (2.7–4.0)

BCVA: best corrected visual acuity; CFT: central foveal thickness; DEX-I: dexamethasone intravitreal implant; DM2: diabetes mellitus type 2; DR: diabetic retinopathy; HbA1c: glycated hemoglobin; NP: non proliferant retinopathy.

5. Discussion

Non-tractional diabetic macular edema is a consequence of a blood-retina barrier breakdown, induced by chronic hyperglycemia. The main pathogenic mechanism is the activation of inflammatory pathways and the increased expression of vascular endothelial growth factor (VEGF).¹⁸

Intravitreal Anti-VEGFs are considered the first line of treatment. Unfortunately, the efficacy of these drugs is temporary, so the treatment is based on multiple injections.¹⁹ Among steroids, which acts on DME by downregulating pro-inflammatory mediators,²⁰ a slow-release dexamethasone implant has been approved for the DME and is a more durable alternative to anti-VEGF therapy. A slow-release fluocinolone acetonide implant (Iluvien, Alimera Sciences Inc., Alpharetta, USA) has also been approved and long term results are promising,²¹ with pharmacokinetics studies showing drug delivery for over a year,²² though no work has yet focused on early recurring macular edema.

For DEX-I, the meantime of DME retreatment is 7.3 months.³ Some patients, however, undergo recurrence at a much faster rate, needing injections as often as every 4 months.²³ Considering the risks associated with every procedure,³ and the clinical and economic burden of macular edema,²⁴ there would be a high rationale in elongating the time of recurrence.

The vitreous has been hypothesized to play a role in the formation of DME ever since it was observed that posterior vitreous detachment is less frequent in eyes with diabetic macular edema.⁹ Vitrectomy with ILM peeling may act on macular edema in several ways: by removing sub-clinical tractional forces on the retina,¹⁰ improving oxygen diffusion through the vitreous cavity,¹¹ and removing the largest reservoir of pro-inflammatory factors.¹²

Vitrectomy does not alter the pharmacokinetics of slow-release Dexamethasone,²⁵ and comparisons between vitrectomized and not vitrectomized eyes demonstrated similar results in terms of macular edema reduction and BCVA improvement.^{13–16} To the best of our knowledge, however, no study has been conducted to test whether vitrectomy could influence the frequency of macular edema recurrence in eyes treated with DEX-I.

As expected, from baseline, patients showed significant improvement in terms of visual acuity and macular thickness. A statistically significant difference emerged also in the timing of retreatment, in fact the DME recurrence occurred with a delay of a few months after the vitrectomy (Pre-Study: 3.4 months; 1st recurrence: 6.5 months). The positive effect of vitreous removal seemed to persist even after the 1st recurrence, possibly indicating a continuative positive effect of PPV + ILM peeling in these eyes.

6. Conclusions

PPV with ILM peeling seems not to influence functional and anatomical results in the eyes under treatment with DEX-I injections for DME, but appears to significantly extend the benefit of the drug. There would be a strong convenience in elongating the recurrence time of edema in such a chronic condition since it would imply less management burden, and a reduction of risk associated with intravitreal injections.

The main limitations of this study are the small number of subjects, the lack of a control group, and the selected population of diabetic pseudophakic patients with a history of early recurrence. Nevertheless, these preliminary results warrant further research, possibly throughout a prospective controlled study and may suggest considering vitrectomy for pseudophakic eyes with early recurrent DME.

Statement of ethics

The study has been conducted following the ethical standards laid down in the Declaration of Helsinki. The potential risks and benefits of treatment were discussed with all patients before the surgical procedure and informed consent was obtained from every patient before their

inclusion in the study. The study protocol has been preliminarily submitted and approved by the Institutional Revisional Board of the Bus-solengo Civil Hospital.

Authorship

All authors attest that they meet the current ICMJE criteria for Authorship.

Declaration of competing interest

The authors have no conflicts of interest to disclose.

Acknowledgments

This research did not receive any specific grant from funding agencies in the public, commercial, or not-for-profit sectors.

References

- Lee R, Wong TY, Sabanayagam C. Epidemiology of diabetic retinopathy, diabetic macular edema and related vision loss. *Eye Vis.* 2015;2:17. <https://doi.org/10.1186/s40662-015-0026-2>.
- Boyer DS, Yoon YH, Belfort Jr R, et al. Three-year, randomized, sham-controlled trial of dexamethasone intravitreal implant in patients with diabetic macular edema. *Ophthalmology.* 2014;121(10):1904–1914. <https://doi.org/10.1016/j.ophtha.2014.04.024>.
- Malclès A, Dot C, Voirin N, et al. REAL-LIFE study IN diabetic macular edema treated with dexamethasone implant: the redex study. *Retina.* 2017;37(4):753–760.
- Guigou S, Hajjar C, Parrat E, et al. Étude rétrospective du traitement par Ozurdex® dans l'œdème maculaire diabétique: MOZART study [Multicenter Ozurdex® assessment for diabetic macular edema: MOZART study]. *J Fr Ophtalmol.* 2014;37(6):480–485. <https://doi.org/10.1016/j.jfo.2014.03.001>.
- Panozzo G, Gussone E, Dalla Mura G. Dexamethasone intravitreal implant for diabetic macular edema: indications for a PRN regimen of treatment. *Eur J Ophthalmol.* 2015;25(4):347–351. <https://doi.org/10.5301/ejo.5000563>.
- Sebag J, Balazs EA. Pathogenesis of cystoid macular edema: an anatomic consideration of vitreoretinal adhesions. *Surv Ophthalmol.* 1984;28(Suppl):493–498. [https://doi.org/10.1016/0039-6257\(84\)90231-5](https://doi.org/10.1016/0039-6257(84)90231-5).
- Crim N, Velez-Montoya R, Morales-Canton V. Surgical versus medical treatment for diabetic macular edema: a review. *Med Hypothesis, Discov Innovation (MEHDI) Ophthalmol.* 2017;6(4):136–142.
- Bhagat N, Grigorian RA, Tutela A, Zarbin MA. Diabetic macular edema: pathogenesis and treatment. *Surv Ophthalmol.* 2009;54(1):1–32. <https://doi.org/10.1016/j.survophthal.2008.10.001>.
- Nasrallah FP, Jalkh AE, Van Coppenolle F, et al. The role of the vitreous in diabetic macular edema. *Ophthalmology.* 1988;95(10):1335–1339. [https://doi.org/10.1016/s0161-6420\(88\)33004-6](https://doi.org/10.1016/s0161-6420(88)33004-6).
- Ghassemi F, Bazvand F, Roohipoor R, Yaseri M, Hassanpoor N, Zarei M. Outcomes of vitrectomy, membranectomy and internal limiting membrane peeling in patients with refractory diabetic macular edema and non-tractional epiretinal membrane. *J Curr Ophthalmol.* 2016;28(4):199–205. <https://doi.org/10.1016/j.joc.2016.08.006>.
- Stefánsson E. The therapeutic effects of retinal laser treatment and vitrectomy. A theory based on oxygen and vascular physiology. *Acta Ophthalmol Scand.* 2001;79(5):435–440. <https://doi.org/10.1034/j.1600-0420.2001.790502.x>.
- Simó-Servat O, Hernández C, Simó R. Usefulness of the vitreous fluid analysis in the translational research of diabetic retinopathy. *Mediat Inflamm.* 2012;1–11. <https://doi.org/10.1155/2012/872978>, 2012.
- Houben I, De Zaeytjij J, Deghislage C, Frost NA, Nijs I, Van Calster J. Efficacy of multiple dexamethasone intravitreal implants for refractory retinal vein occlusion-related macular edema and effect of prior vitrectomy. *J Ocul Pharmacol Therapeut.* 2018;34(10):710–719. <https://doi.org/10.1089/jop.2018.0012>.
- Medeiros MD, Alkabes M, Navarro R, García-Arumí J, Mateo C, Corcóstegui B. Dexamethasone intravitreal implant in vitrectomized versus nonvitrectomized eyes for treatment of patients with persistent diabetic macular edema. *J Ocul Pharmacol Therapeut.* 2014;30(9):709–716. <https://doi.org/10.1089/jop.2014.0010>.
- Rezkallah A, Malclès A, Dot C, et al. Evaluation of efficacy and safety of dexamethasone intravitreal implants before and after vitrectomy in a real-life study. *Acta Ophthalmol.* 2018;96(4):e544–e546. <https://doi.org/10.1111/aos.13608>.
- Bastakis GG, Dimopoulos D, Stavrakakis A, Pappas G. Long-term efficacy and duration of action of dexamethasone implant, in vitrectomized and non-vitrectomized eyes with persistent diabetic macular oedema. *Eye.* 2019;33(3):411–418. <https://doi.org/10.1038/s41433-018-0219-8>.
- Photocoagulation for diabetic macular edema. Early treatment diabetic retinopathy study report number 1. Early treatment diabetic retinopathy study research group. *Arch Ophthalmol.* 1985;103(12):1796–1806, 1985.
- Miller K, Fortun JA. Diabetic macular edema: current understanding, pharmacologic treatment options, and developing therapies. *Asia Pac J Ophthalmol.* 2018;7(1):28–35. <https://doi.org/10.22608/APO.2017529>.

19. Schmidt-Erfurth U, Garcia-Arumi J, Bandello F, et al. Guidelines for the management of diabetic macular edema by the European society of retina specialists (EURETINA). *Ophthalmologica*. 2017;237(4):185–222. <https://doi.org/10.1159/000458539>.
20. Wu MY, Yiang GT, Lai TT, Li CJ. The oxidative stress and mitochondrial dysfunction during the pathogenesis of diabetic retinopathy. *Oxid Med Cell Longev*. 2018;1–12. <https://doi.org/10.1155/2018/3420187>, 2018.
21. Fusi-Rubiano W, Blow RR, Lane M, Morjaria R, Denniston AK. Iluvien™ (fluocinolone acetonide 0.19 mg intravitreal implant) in the treatment of diabetic macular edema: a review. *Ophthalmol Th*. 2018;7(2):293–305. <https://doi.org/10.1007/s40123-018-0145-7>.
22. Campochiaro PA, Hafiz G, Shah SM, et al. Sustained ocular delivery of fluocinolone acetonide by an intravitreal insert. *Ophthalmology*. 2010;117(7):1393–1399. <https://doi.org/10.1016/j.ophtha.2009.11.024>. e3.
23. Bonnin S, Dupas B, Sanharawi ME, et al. Efficacy of dexamethasone intravitreal implant for the treatment of diabetic macular edema. *Eur J Ophthalmol*. 2015;25(5):448–453. <https://doi.org/10.5301/ejo.5000581>.
24. Kiss S, Chandwani HS, Cole AL, Patel VD, Lunacek OE, Dugel PU. Comorbidity and health care visit burden in working-age commercially insured patients with diabetic macular edema. *Clin Ophthalmol*. 2016;10:2443–2453. <https://doi.org/10.2147/OPTH.S114006>.
25. Chang-Lin JE, Burke JA, Peng Q, et al. Pharmacokinetics of a sustained-release dexamethasone intravitreal implant in vitrectomized and nonvitrectomized eyes. *Invest Ophthalmol Vis Sci*. 2011;52(7):4605–4609. <https://doi.org/10.1167/iovs.10-6387>. Published 2011 Jun 28.