



A Rare Case of Bilateral Agenesis of Central Lower Incisors Associated With Upper Impacted Canine- A Case Report

*Anca PORUMB, Ioana IGNAT ROMANUL, Camelia DALAI, Gabriela CIAVOI, *Ioan Andrei TIG*

Dept. of Dentistry, Faculty of Medicine and Pharmacy, University of Oradea, Romania

***Corresponding Author:** Email: nelutig@yahoo.com

(Received 11 Jul 2015; accepted 22 Nov 2015)

Abstract

This case of a female patient, 14 yr old with association of the two anomalies, which we came across with in 2014, is rarely met in the specialty practice. The impacted canines are part of the group of dental anomalies of position, while the agenesis is part of the group of dental number anomalies. The orthodontic treatment in the two arches has to be differentiated, the therapeutic objectives being, also different in the two arches.

Keywords: Agenesis, Impacted canines, Orthodontic appliances

Introduction

The development of the dental-maxillary device represents a long and complex process, in which can appear different abnormalities from normal, variable regarding the way they are produced, the manifestations, the moment of appearance and the consequences (1).

The dental anomalies represent a special group of the dental-maxillary anomalies, in this category being included affection with a common characteristic: the dominant modification is that of the dental system, while the modification of the bone is discreet, sometimes hardly perceivable, and sometimes secondary to the dental disturbances (2, 3).

The dental anomalies can appear as freestanding, namely isolated dental anomalies, and in the orthodontic syndromes (4).

Agenesis of bilateral (both right and left) mandibular central incisors is not well documented and literature shows paucity of data pertaining to this

anomaly. The first report of congenitally missing two mandibular incisors was earlier (5).

The prevalence of agenesis in European populations is estimated at 0.08% (6). Females have shown higher predilection than males (7). Certain discrete malpositions of the human canine tooth and agenesis of at least one tooth are abnormalities known to occur together, one of the situations being the association between agenesis with palatal displaced canine (8).

Depending on research, it is estimated that on average there is a 1.6% incidence of maxillary impacted canines (9). Impactions are twice as common in females (1.17%) as in males (0.51%) (9). In patients who present with impacted maxillary canines, it is estimated that 8% of these are bilateral (9). Reasons for impactions can be varied and are categorized as both localized and generalized. The most common reasons for canine impaction are usually localized and are the result of any one or combination of the following

factors: tooth size/arch length discrepancies, prolonged retention, or early loss of the deciduous canine, abnormal position of the tooth bud, the presence of an alveolar cleft, ankylosis, cystic or neoplastic formation, dilacerations of the root, iatrogenic origin, and idiopathic condition. Irradiation, febrile diseases, and endocrine deficiencies are some of the general causes (9).

The aim of the present article is to report a rarely case of bilateral agenesis of central lower incisors, associated with upper impacted canine. The documentation of such case reports is necessary due to its rarity, to provide a review to minimize the clinicians challenge in diagnosing such cases and thus helpful in providing a multidisciplinary approach in treating the patient.

Possibilities of treatment in this type of dental anomalies are multiple, from orthodontic, through

prosthetic, till implants, depending on many factors, age of patient being the most important in our opinion. This kind of anomalies does not have typical treatment, the choice of choosing orthodontic, prosthetic or implant treatment relies only on clinician's decision in order to obtain the best results possible.

Case presentation

The female patient, 14 yr old in 2014, comes for an orthodontic consultation, being brought by the mother, displeased with the physiognomic aspect of her teenage daughter.

At the clinical examination are observed the following (Fig. 1):

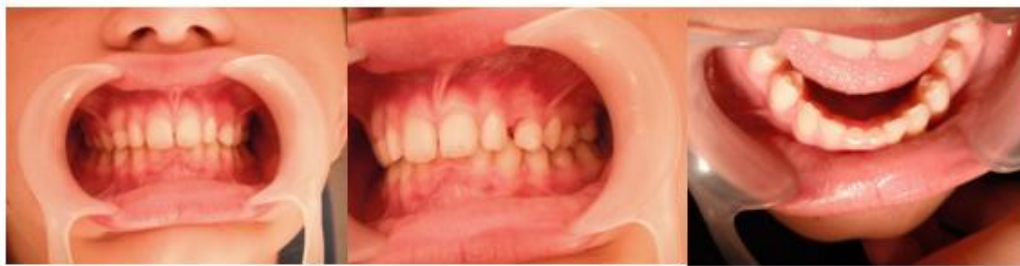

Fig. 1: Initial clinical aspect

-on the upper arch is found the persistence of both temporary canines and of the second temporary molars, over the physiological limit of replacing.

-on the inferior arch is found the presence on the arch of both temporary inferior central incisors, more over the physiological limit of replacing.

Orthopantomography (Fig. 2) and CBCT (Fig. 3) underlines:

-intra-maxillary presence of germs 1.7, 1.5, 1.3, 2.3, 2.5, 2.7

-intra-maxillary presence of germs 3.8 and 4.8, in process of mineralization

-intra-maxillary absence of germs 3.1 and 4.1

Following the clinical examination, carefully studied, the analysis of the study models, the beginning photos, orthopantomography (OPT) and CBCT, we gave the diagnosis of bilateral agenesis

of inferior central incisors and the diagnosis of impacted right upper canine.

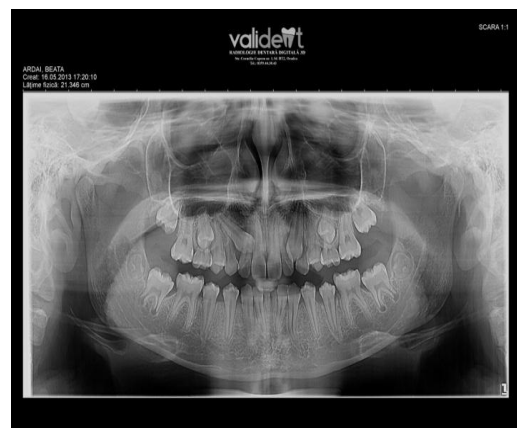

Fig. 2: Aspect of orthopantomography

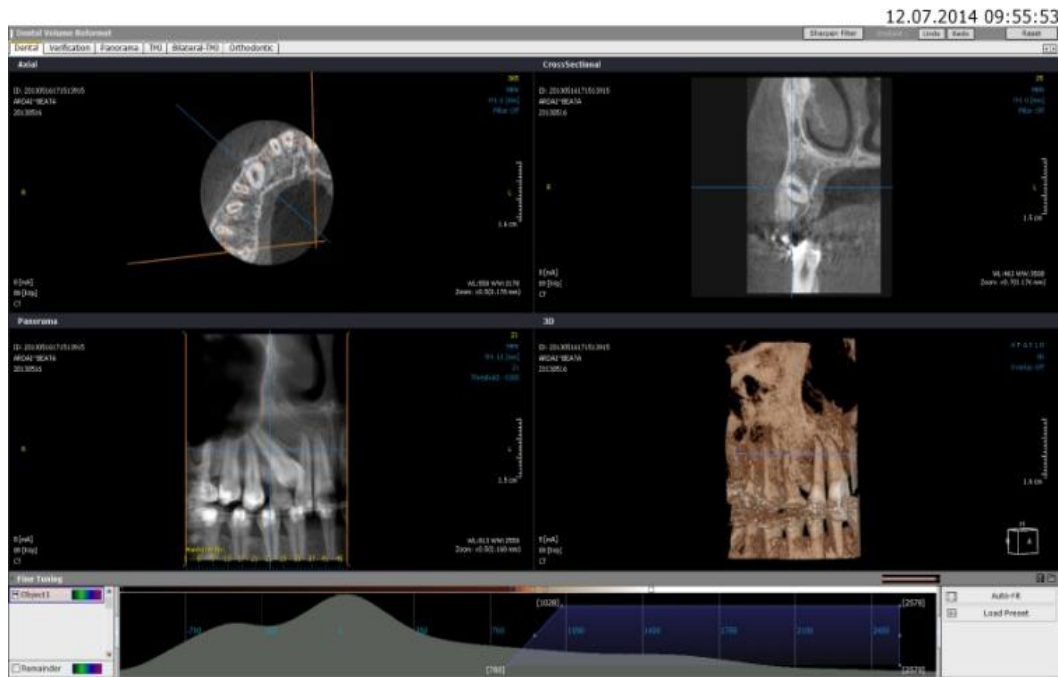


Fig. 3: Aspects of Cone Beam Computer Tomography (CBCT)

The diagnosis of bilateral agenesis of inferior central incisors was given based on the radiologic examination: the intra-maxillary absence of the inferior central incisors germs, more over the physiological limit of the replacing period (10-12).

The diagnosis of impacted right upper canine was given based on the radiologic examination: the intra-maxillary presence of the germ of 1.3, with the root completely formed and the apex closed, 2 years over the maximum age of the physiological replacing (13-15).

The treatment of the two arches was differentiated, the therapeutic objectives being different in the two arches, thus:

-In the inferior arch, after the extraction of the two temporary inferior central incisors, will be chosen the closing of the distance by physiological mesializations (16-19).

-In the upper arch, after the extraction of all the temporary teeth persistent on the arch over the physiological limit of replacing, we will wait a period of a few months for the spontaneous eruption of the definitive teeth on the arch and in case of 1.3 we will choose its surgical exposing and

bringing it on the arch by the slow tractioning, to a fixed poly-aggregate orthodontic appliance (20, 21).

Thus were performed dental extractions of 5.5, 5.3, 6.3 and 6.5 in the upper arch and of 7.1 and 8.1 in the inferior arch.

It followed then the applying of a fixed poly-aggregate bimaxillary metallic appliance (Fig. 4-6).

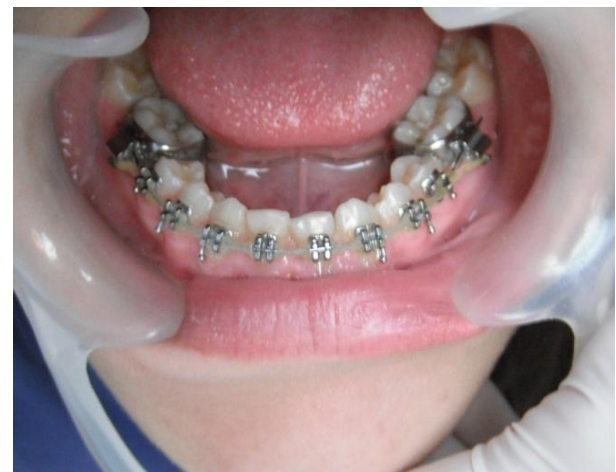

Fig. 4: Final aspect of inferior arch

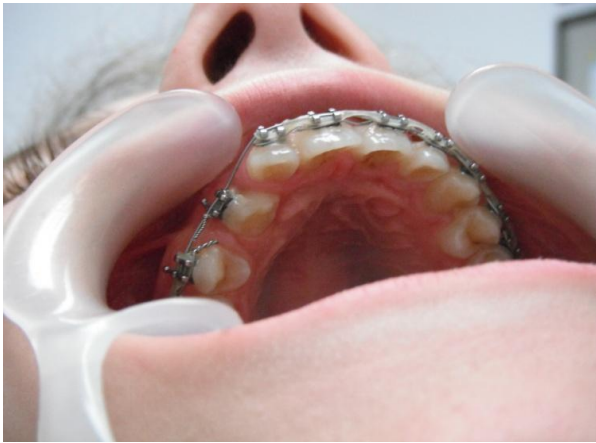

Fig. 5: Aspect of upper arch after 2 months

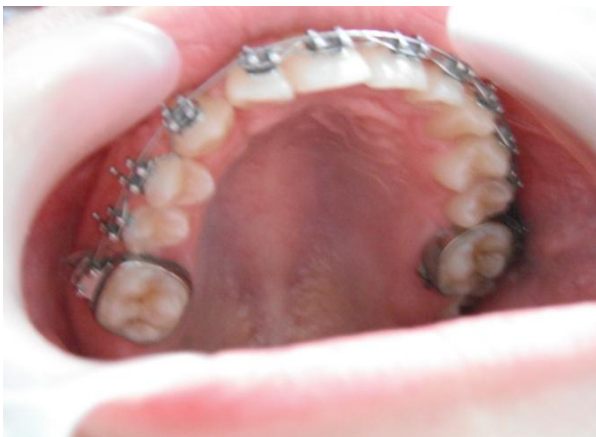

Fig. 6: Aspect of upper arch after 4 months

Discussions

The exact etiology of congenital agenesis of both central incisors is unknown, several factors like trauma, radiations, infection, metabolic disorders and idiopathic are the possible etiologic factors (22). Newman has given four main theories mainly for the cause of agenesis of incisors (23). Heredity or familial distribution is the primary cause. Second, anomalies in the development of the mandibular symphysis may affect the dental tissue forming the tooth buds of the lower incisors (24). Third, a reduction of the dentition regarded as nature's attempt to fit the shortened dental arches (an expression of the evolutionary trend) (25) and finally, localized inflammation or infec-

tions in the jaw and disturbance of the endocrine system destroying the tooth buds (5,7).

Genes *MSX1*, *TGFA* and *PAX9* interaction sometimes play a role in human tooth agenesis (26). Mandibular incisor agenesis has a large effect on mandibular symphysis growth and morphology. Buschang demonstrated that, vertical and horizontal growth changes during childhood and puberty were most pronounced in the upper half of the mandibular symphysis, resulting in an increase in the height of the mandibular body (27). Hence patients with absence of mandibular both central incisors, exhibit significantly smaller mandibular symphysis area than the normal patients. They have also reported that, the growth of alveolar bone is also associated with continuous eruption of the dentition (27). Endo M. have concluded from their study that, before planning/implementing orthodontic treatment on a patient with congenital missing incisors, some factors like retroclination of alveolar bone and reduced mandibular alveolar bone area should be taken into consideration, as these may affect the treatment outcome (28).

Some orthodontists say that congenital absence of both mandibular central incisor is advantageous, as the extraction of mandibular central incisors is sometimes considered as the treatment of choice in crowded class I malocclusion, especially when a preexisting tooth-size discrepancy (severe mandibular excess) prevents the achievement of an acceptable occlusion (29, 30).

The other consequence of agenesis of both mandibular incisors is disturbance in tongue-lip pressure balance and lack of lingual support. Severe malocclusion usually class II Div I malocclusion is also seen with severe anterior deep bite and absence of dental midline or sometimes wide spacing in the anterior region exists resulting in unaesthetic appearance for a child.

The other problem encountered with congenital absence of incisors is the difficulty in identification of teeth. Because of the existing space resulting from missing teeth, the adjacent teeth move to this space, leading to difficulty in identification of incisors. Thus, for correct diagnosis of teeth,

radiographic examination is mandatory in order to see the exact position of the root.

Conclusion

The association of the two anomalies is rarely met in specialty practice. The impacted canines are part of the group of position dental anomalies, while agenesis is part of the number dental anomalies. The treatment is differentiated, on the two arches, the therapeutic objective being different in the two arches, thus:

-In the inferior arch we will choose the closing of the distance by physiological mesializations.

-In the upper arch we will choose the surgical exposing of 1.3 and bringing it on the arch by the slow tractioning, to a fixed poly-aggregate orthodontic appliance.

Due to the age of patient (only 14 years of age), we decided that orthodontic treatment is the proper choice in this particular case.

Ethical considerations

Ethical issues (Including plagiarism, informed consent, misconduct, data fabrication and/or falsification, double publication and/or submission, redundancy, etc.) have been completely observed by the authors.

Acknowledgments

The authors declare that there is no conflict of interests.

References

1. Cocarlä E (2000). *Pediatric dentistry* Editura Medicală Universitară "Iuliu Hațieganu" Cluj-Napoca, pp.162-163.
2. Backman B, Wahlin YB (2001). Variations in number and morphology of permanent teeth in 7-year-old Swedish children. *Int J Paediatr Dent*, 11(1): 11.
3. Udom T, Terrence J F (1998). Prevalence of dental anomalies in orthodontic patients. *Aus Dent J*,43(6): 395-398.
4. Mesaroş M, Antonescu-Deac R (2004) Clinical and radiologic aspects in number dental anomalies. *Revista de Ortodontie și Ortopedie Dento-facială*, 5(2): 10-15.
5. Nagaveni NB, Umashankara KV (2009). Congenital bilateral agenesis of permanent mandibular incisors: case report and literature review. *Arch Orfac Sci*, 4(2):41-46.
6. Pirinen S, Kentala A, Nieminem P, Varilo T, Thesleff I, Arte S (2001). Recessively inherited lower incisor hypodontia. *J Med Genet*, 2001;38:551-556.
7. Satish B.N.V.S., Kumar P, Furquan M, Hugar D, Saraswati F.K (2014). Bilateral agenesis of Permanent Mandibular Central Incisors: Report of Two Cases. *J Int Oral Health*, 6(3): 103-105.
8. Peck S, Peck L, Kataja M (2002). Concomitant occurrence of canine malposition and tooth agenesis: Evidence of orofacial genetic fields. *Am J Orthod Dentofacial Orthop*, 122 (6): 657-660.
9. Bishara S (1992). Impacted maxillary canine: A review. *Am J Orthop Dentofac Orthop*, 101(2):159-171.
10. Silva Meza R (2003). Radiographic assessment of congenitally missing teeth in orthodontic patients. *Int J Paediatr Dent*, 13(2): 112- 116.
11. Pop V (2001). Dental number anomalies, form, volume and structure in a group of 741 children with the age of 9-15. *Revista Colegiului Ed-genise*, no.8: 67-74.
12. Tarmure V (2005). Dental anomalies by deficit of number for children from Cluj- Napoca. *Revista de Ortodontie și Ortopedie Dento-facială*, 6 (1,2): 13-19.
13. Andreasen JO, Petersen JK, Laskin DM (1997). *The impacted mandibular canine: Textbook and color atlas of tooth impactions*. Copenhagen: Munksgaard: pp.167-175.
14. Nagpal A, Pai KM, Setty S, Sharma G (2009). Localization of impacted maxillary canines using panoramic radiography. *J Oral Sci*, 51(1): 37-45.
15. Alif SM, Haque S, Nimmi N, Ashraf A, Khan SH, Khan MH (2011). Panoramic radiological study to identify locally displaced maxillary canines in Bangladeshi population. *Imaging Sci Dent*, 41(4): 155-9.
16. Tărmure V : Hypodontics - Diagnosis and therapeutic possibilities [Ph D thesis]. Editura

- Medicală Universitară "Iuliu Hațieganu" Cluj-Napoca; 2006
17. Vastardis H (2000). The genetic of human tooth agenesis: New discoveries for understanding dental anomalies. *Am J Orthod Dentofacial Orthop*, 117(6): 650-656.
 18. Olivera OMS, Pallos D, Gil F, Cortelli JR (2001). Prevalence of hypodontia and the alteration of dental anatomy related. *J Biosci*, 7(2): 25-31.
 19. Tavajohi-Kermani H, Kapur R, Sciotte JJ (2002). Tooth agenesis and craniofacial morphology in an orthodontic population. *Am J Orthod Dentofacial Orthop*, 122(1): 39-46.
 20. Sajnani AK, King NM (2012). Early prediction of maxillary canine impaction from panoramic radiographs. *Am J Orthod Dentofacial Orthop*, 142(1): 45-51.
 21. Abdolaziz H, Hooman ZN, Sima A (2014). Prevalence and Localization of Impacted Canine Teeth in Both Jaws Using Panoramic Radiograph in a Selected Iranian Population, Shiraz, 2012. *Galen Med J*, 3(1): 24-28.
 22. Endo T, Ozoe R, Kubota M, Akiyama M and Shimooka S (2006). A survey of hypodontia in Japanese orthodontic patients. *Am J Orthod Dentofacial Orthop*, 129(1): 29-35.
 23. Newman GV (1977). Transposition: orthodontic treatment. *J Am Dent Assoc*, 94(3): 544-547.
 24. Newman GV and Newman RA (1998). Report of four familial cases with congenitally missing mandibular incisors. *Am J Orthod Dentofacial Orthop*, 114(2): 195-207.
 25. Lavelle CL and Moore WJ (1973). The incidence of agenesis and polygenesis in the primate dentition. *Am J Phys Anthropol*, 38(3): 671-679.
 26. Vieira AR, Meira R, Modesto A and Murray JC (2004). MSX1, PAX9, and TGFA contribute to tooth agenesis in humans. *J Dent Res*, 83(9): 723-727.
 27. Buschang PH, Julien K, Sachdeva R and Demirjian A (1992). Childhood and pubertal growth changes of the human symphysis. *Angle Orthod*, 62(3): 203-210.
 28. Endo T, Ozoe R, Kojima K and Shimooka S (2007). Congenitally missing mandibular incisors and mandibular symphysis morphology. *Angle Orthod*, 77(6): 1079-1084.
 29. Kokich VG, Shapiro PA (1984). Lower incisor extraction in orthodontic treatment. *Angle Orthod*, 54(2): 139-153.
 30. Canut JA (1996). Mandibular incisor extraction: indications and long-term evaluation. *Eur J Orthod*, 18(5): 485-489.