

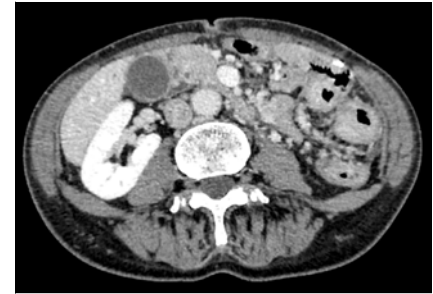
Underwater endoscopic mucosal resection for the diagnosis of metastatic gastric cancer in the descending colon

OPEN
ACCESS

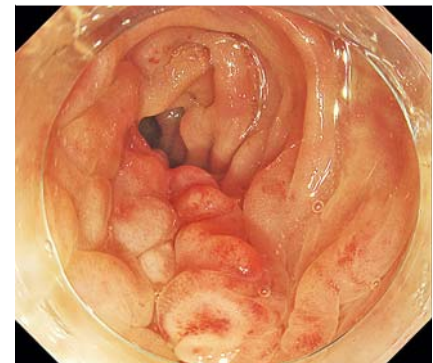
A 55-year-old woman underwent total gastrectomy for advanced type 4 (nonulcerated, diffusely infiltrating) gastric cancer (pT4a) with negative margins and received adjuvant chemotherapy for 1 year. Three years later, she developed abdominal pain, and colonoscopy revealed stenosis on the left side of the colon. Biopsy evaluations showed no primary or metastatic tumor, and she was referred to our institution for further investigation and treatment. Computed tomography showed abnormal thickness of the colonic wall in the descending colon (▶ Fig. 1). Colonoscopy revealed stenosis at the splenic flexure, and the colonoscope could not pass through (▶ Fig. 2). Uneven ridges continued in the longitudinal direction on one side. Narrow-band imaging showed no apparent tumor on the mucosa (▶ Fig. 3). Endoscopically, we diagnosed metastatic gastric cancer or primary advanced type 4 colonic cancer.

In order to obtain sufficient tissue for histology, we performed underwater endoscopic mucosal resection (EMR) (▶ Fig. 4, ▶ Video 1). Pathological diagnosis revealed adenocarcinoma (poorly differentiated, signet ring cell carcinoma) (▶ Fig. 5). Immunostaining was consistent with metastatic gastric cancer (CD7 positive, CD20 negative, MUC2 negative, MUC5AC partially positive, and MUC6 partially positive) and similar to the pathology of the patient's previously resected stomach.

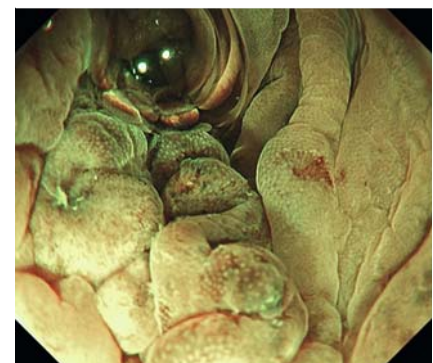
Underwater EMR was first reported by Binmoeller et al. in 2012 [1], and we reported its usefulness for resecting colorectal polyps [2] and duodenal tumors. The cutting depth with underwater EMR was comparable to that of conventional EMR [3]. For cases in which pathological diagnosis is difficult by endoscopic biopsy because only nontumor epithelium is obtained, endoscopic ultrasonography-guided fine-needle aspiration may be performed [4]; however, this procedure



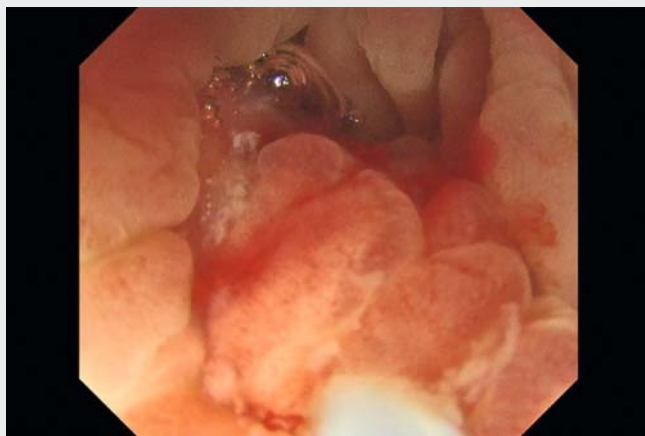
▶ Fig. 1 Computed tomography showed abnormal thickness of the colonic wall in the descending colon.



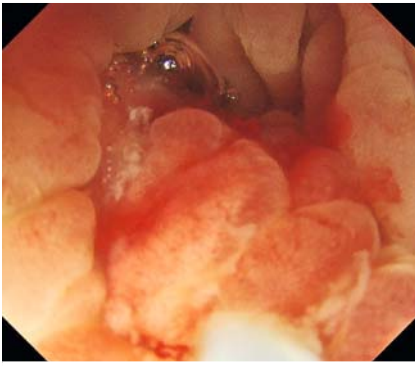
▶ Fig. 2 Uneven ridges continued in the longitudinal direction on the intestinal membrane side, leading to stenosis.



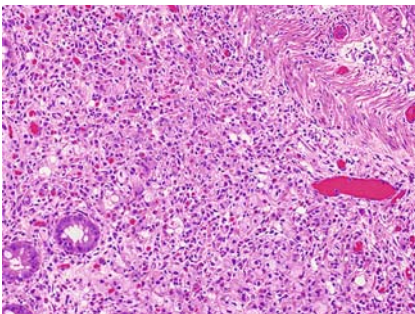
▶ Fig. 3 Observation with narrow-band imaging. No apparent tumor appeared on the mucosa.



▶ Video 1 Underwater endoscopic mucosal resection for the diagnosis of metastatic gastric cancer in the descending colon.



► **Fig. 4** Snaring of uneven ridges in the descending colon.



► **Fig. 5** Pathological diagnosis revealed adenocarcinoma (poorly differentiated, signet ring cell carcinoma).

carries the risk of abdominal dissemination [5]. Conventional EMR is another option, but injection may not lead to submucosal tumor elevation because of invasion, and the limited luminal space after injection would hinder snaring. Without using a needle or injection, underwater EMR minimized the risk of dissemination and yielded sufficient tissue for pathological diagnosis.

Endoscopy_UCTN_Code_TTT_1AQ_2AC

Acknowledgments

We would like to thank Editage (www.editage.com) for English language editing.

Competing interests

The authors declare that they have no conflict of interest.

The authors

Satoki Shichijo¹, **Hisashi Hara**², **Noriya Uedo**¹, **Tomoki Michida**¹, **Yoji Takeuchi**¹

- 1 Department of Gastrointestinal Oncology, Osaka International Cancer Institute, Osaka, Japan
- 2 Department of Surgery, Osaka International Cancer Institute, Osaka, Japan

Corresponding author

Satoki Shichijo, MD, PhD

Department of Gastrointestinal Oncology, Osaka International Cancer Institute, 3-1-69, Otemae, Chuo-ku, Osaka, 541-8567, Japan
7satoki@oici.jp

References

- [1] Binmoeller KF, Weibert F, Shah J et al. "Underwater" EMR without submucosal injection for large sessile colorectal polyps (with video). *Gastrointest Endosc* 2012; 75: 1086–1091
- [2] Yamashina T, Uedo N, Akasaka T et al. Comparison of underwater vs conventional endoscopic mucosal resection of intermediate-size colorectal polyps. *Gastroenterology* 2019; 157: 451–461.e2
- [3] Matsueda K, Takeuchi Y, Kitamura M et al. Depth of the cutting plane with underwater and conventional endoscopic mucosal resection: post-hoc analysis of a randomized study. *J Gastroenterol Hepatol* 2022; 37: 741–748
- [4] Pham BV, Phan HH, Ngo LL et al. A rare colonic metastasis case from hepatocellular carcinoma. *Open Access Maced J Med Sci* 2019; 7: 4368–4371
- [5] Kojima H, Kitago M, Iwasaki E et al. Peritoneal dissemination of pancreatic cancer caused by endoscopic ultrasound-guided fine needle aspiration: a case report and literature review. *World J Gastroenterol* 2021; 27: 294–304

Bibliography

Endoscopy 2022; 54: E956–E957
DOI 10.1055/a-1882-4942
ISSN 0013-726X
published online 21.7.2022
© 2022. The Author(s).

This is an open access article published by Thieme under the terms of the Creative Commons Attribution-NonDerivative-NonCommercial License, permitting copying and reproduction so long as the original work is given appropriate credit. Contents may not be used for commercial purposes, or adapted, remixed, transformed or built upon. (<https://creativecommons.org/licenses/by-nc-nd/4.0/>)
Georg Thieme Verlag KG, Rüdigerstraße 14, 70469 Stuttgart, Germany



ENDOSCOPY E-VIDEOS

<https://eref.thieme.de/e-videos>



Endoscopy E-Videos is an open access online section, reporting on interesting cases and new techniques in gastroenterological endoscopy. All papers include a high quality video and all contributions are freely accessible online. Processing charges apply (currently EUR 375), discounts and waivers acc. to HINARI are available.

This section has its own submission website at <https://mc.manuscriptcentral.com/e-videos>