



ORIGINAL ARTICLE

Comparison of the Treatment Outcomes of Photodynamic Therapy and Ingenol Mebutate in Bowen's Disease: A Retrospective Observational Study

Ji Hae An, Jung U Shin, Hyun Jung Kim, Hee Jung Lee, Moon Soo Yoon, Dong Hyun Kim

Department of Dermatology, CHA Bundang Medical Center, CHA University School of Medicine, Seongnam, Korea

Background: Bowen's disease (BD) is treated by multiple treatment modalities. **Objective:** To assess the effectiveness of photodynamic therapy (PDT) and ingenol mebutate (IMB) in treating BD and determine the factors affecting the treatment outcome. **Methods:** Patients with histologically confirmed BD from January 1, 2006, to December 31, 2017, were identified from the database of CHA Bundang Medical Center. Those treated with PDT or IMB were included. Patient, tumor characteristics, and treatment response data were retrospectively collected from the database. **Results:** Overall, 44 and 24 BD were treated with PDT and IMB, respectively. Mean time to the first follow-up visit was 1.2 (0.5~4) months. Mean follow-up duration was 7.6 (1~36) months. The mean number of treatment sessions for PDT is 2 sessions (1~5), while that of IMB was equally 1 session. The complete response rates at the first follow-up visit were 66.7% and 53.0% and recurrence rates were 10.3% and 15.3% for PDT and IMB, respectively. However, the treatment outcome and recurrence rate between both treatment modalities were not significantly different ($p=0.349$ and $p=0.993$, respectively). In factor analysis, the complete response rate significantly decreased with older patients in

IMB ($p=0.012$). Adverse events, occurred in 20.5% and 45.8% of patients treated with PDT and IMB, respectively. **Conclusion:** PDT and IMB are effective noninvasive treatment modalities for BD. However, PDT is a safer treatment modality, considering its fewer adverse events. Particularly, with age being a factor that reduces IMB outcome, in older patients, PDT can be considered as preferred treatments over IMB. (*Ann Dermatol* 32(1) 47~52, 2020)

-Keywords-

Bowen's disease, Ingenol mebutate, Photodynamic therapy, Treatment outcome

INTRODUCTION

Bowen's disease (BD) was first described by Bowen in 1912 as a cutaneous squamous cell carcinoma (SCC) *in situ*¹. BD appears as a slowly enlarging, sharply demarcated erythematous plaque². Histological examination reveals hyperkeratosis and parakeratosis, overlying an epidermis that is replaced by disorganized atypical keratinocytes and abnormal mitosis³. The risk of progressing BD to SCC is within 3%~8%, of which 13%~20% develop metastasis^{3,4}. Different guidelines for BD recommend various treatments such as surgical excision, photodynamic therapy (PDT), imiquimod 5% cream, 5-fluorouracil cream, cryotherapy, laser therapy, and curettage^{4,7}. However, the most effective treatment is uncertain because of the lack of controlled trials^{4,8}. The British guidelines state that no treatment modality is superior to others and that choosing a therapeutic option for a patient depends on the tumor location, expected efficacy, patient basal status, economic resources, and patient preference^{4,7}. PDT is a frequently used treat-

Received September 11, 2019, Revised November 5, 2019, Accepted for publication November 9, 2019

Corresponding author: Dong Hyun Kim, Department of Dermatology, CHA Bundang Medical Center, CHA University, 59 Yatap-ro, Bundang-gu, Seongnam 13496, Korea. Tel: 82-31-780-5243, Fax: 82-31-780-5247, E-mail: terios92@hanmail.net
ORCID: <https://orcid.org/0000-0003-3394-2400>

This is an Open Access article distributed under the terms of the Creative Commons Attribution Non-Commercial License (<http://creativecommons.org/licenses/by-nc/4.0>) which permits unrestricted non-commercial use, distribution, and reproduction in any medium, provided the original work is properly cited.

Copyright © The Korean Dermatological Association and The Korean Society for Investigative Dermatology

ment modality because of its noninvasive character and excellent cosmetic results. PDT has an advantage at body sites associated with poor wound healing and in the case of multiple lesions^{7,9,10}. Recently, ingenol mebutate (IMB), which is a drug approved by the US Food and Drug Administration for the treatment of actinic keratosis (AK), is being used off-label to treat BD. Unlike in AK treatment¹¹⁻¹³, no studies comparing the treatment outcomes of PDT and IMB are available in BD treatment. Also, no clinical or histological factors that affect the treatment outcome of IMB are reported.

This study aimed to assess the effectiveness of the PDT and IMB in the treatment of BD and to determine which clinical or histological factors affected the treatment outcome.

MATERIALS AND METHODS

Patient selection

Patients with histologically confirmed BD from January 1, 2006, to December 31, 2017, were identified from the histological database of CHA Bundang Medical Center. Of the selected patients, those treated with PDT or IMB were included. Patients with tumors found on the anogenital region were excluded because of their different etiologies and known high recurrence rates. Patients who lost to follow-up (FU) or with inadequate medical information in the patient electronic chart were also excluded from the analysis. Ethical approval was obtained from the ethic committee of CHA Bundang Medical Center (IRB no. 2019-07-039-001).

Procedure

Data on patient and tumor characteristics were retrospectively collected from the patient electronic chart. The parameters included in the analysis were as follows: age, sex, disease duration, tumor location, histological epidermal thickness, the number of treatment sessions and pretreatment with fractional CO₂ laser, clinical result at the first FU visit, the date of any recurrences noted during later FU visits, and adverse events. In this study, complete response was defined as the absence of clinical evidence of BD at the first FU visit. Conversely, any clinical evidence of BD in the treatment area at the first FU visit indicated an incomplete response. Meanwhile, recurrence was defined as the presence of any clinical or histological evidence of BD during later FU visits.

Therapy

For patients treated with PDT, all BD lesions were treated with the same methyl aminolevulinate cream (Metvix[®];

Galderma Laboratories, Paris, France), light source (Omnilux; Photo Therapeutics, Inc., Altrincham, UK; wavelength: 633 nm), and light dose (126 J/cm²). The methyl aminolevulinate cream was applied to BD lesions and covered with plastic film to avoid light exposure. The cream was removed after 4 hours, and the lesion was irradiated with the light source. 10 BD lesions out of 40 BD lesions were treated with fractional CO₂ laser (eCO₂; Lutronics, Seoul, Korea; 50 mJ × 200 spots/cm²) before PDT treatment. For patients treated with IMB, head and neck lesions were treated with 0.015% IMB (Picato[®]; Leo Pharma, Ballerup, Denmark) for 3 consecutive days, and trunk and limb lesions were treated with 0.05% IMB for 2 consecutive days. Patients were instructed on the modalities of IMB self-administration.

Statistical analysis

Distributions of patient characteristics were described by means of standard deviation.

To determine the presence of any potential factors associated with the treatment outcome after PDT or IMB, we performed logistic regression on the following parameters: age, sex, disease duration, tumor location, histological epidermal thickness, and the number of treatment sessions and pretreatment with fractional CO₂ laser. Statistical significance was considered when the *p*-value was below 0.05. Statistical analyses were performed using IBM SPSS Statistics ver. 25.0 (IBM Corp., Armonk, NY, USA).

RESULTS

Patient and tumor characteristics

During the study period, 160 histologically proven cases of BD in 145 patients were found in the histological database of CHA Bundang Medical Center. Of the 160 BD lesions, 13 on the anogenital region were excluded because of their different etiologies and known high recurrence rates. The treatment modality was retrieved from the patient electronic chart. Of the 147 remaining BD lesions, 64 treated with surgical excision (56), cryotherapy (4), and imiquimod (4) other than PDT and IMB were excluded. We also excluded 15 lesions in 15 patients who lost to FU or with inadequate medical information in the electronic chart. Consequently, the 68 remaining lesions in 61 patients were included. Among them, 44 BD lesions in 44 patients were treated with PDT, whereas 24 BD lesions in 17 patients were treated with IMB. The average age was 71.4 years (47~93 years), and 45 patients were female. A flowchart of patient selection is presented in Fig. 1, whereas the demographics of the patients and the clinical, histological characteristics of BD lesions are shown in Table 1.

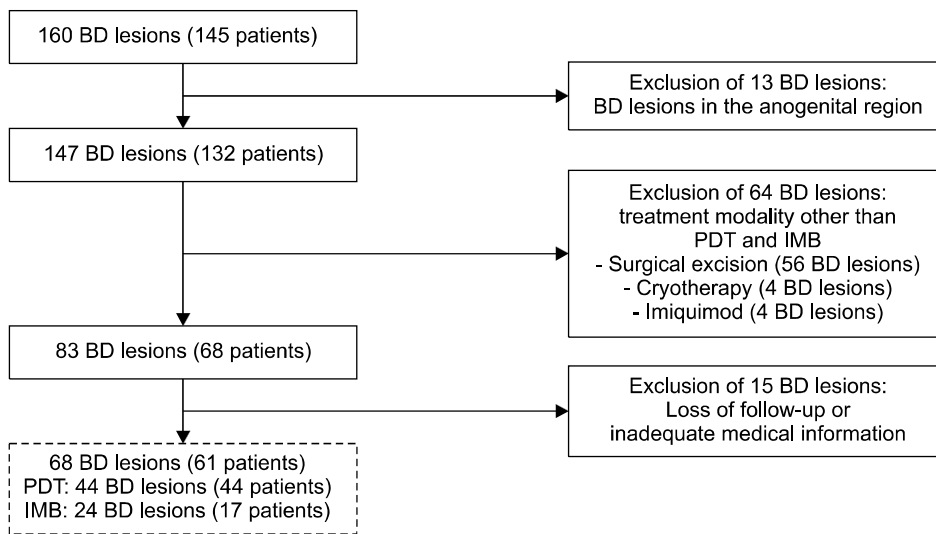


Fig. 1. Flowchart of patient selection. BD: Bowen's disease, PDT: photodynamic therapy, IMB: ingenol mebutate.

Table 1. Demographics of patients and clinical, histological characteristics of Bowen's disease

Variable	Total	PDT	IMB
Patients	61	44	17
Sex			
Male	16 (26.2)	15 (34.1)	1 (5.9)
Female	45 (73.8)	29 (65.9)	16 (94.1)
Age (yr)	71.4 (47~93)	70.3 (47~93)	74.3 (51~92)
Duration of disease (mo)	34.1 (2~96)	35.5 (2~96)	32.6 (6~60)
Total lesions	68	44	24
Tumor location			
Head/neck	42 (61.8)	23 (52.3)	19 (79.2)
Trunk	15 (22.1)	13 (29.5)	2 (8.3)
Extremities	11 (16.1)	8 (18.2)	3 (12.5)
Histological epidermal thickness (mm)	0.50	0.63	0.38
Number of treatment sessions	-	2 (1~5)	1
Pretreatment with fractional CO ₂	-	10 (23)	NA

Values are presented as number only, number (%), or median (range).

PDT: photodynamic therapy, IMB: ingenol mebutate, NA: not assessed, -: not available.

Evaluation of the treatment outcome

The mean time to the first FU visit of patients treated with PDT was 1.5 months (0.5~3.8 months), whereas that of patients treated with IMB was 0.9 months (0.5~1.5 months). The mean FU duration of patients treated with PDT was 7.6 months (1~24 months), whereas that of patients treated with IMB was 6.6 months (1~36 months). The mean number of treatment sessions for PDT is 2 sessions (1~5 sessions), while that of IMB was equally 1 session. Complete response was found in 29 lesions (66.7%) after PDT and 13 lesions (53.0%) after IMB ($p=0.349$). Of the 29 complete-response BD lesions treated with PDT, 3 lesions (10.3%) recurred. Meanwhile, 2 lesions (15.3%) recurred in the 13 complete-response BDs treated with IMB

($p=0.993$). Table 2 shows the number of BD lesions with a complete response and the recurrence rates noted after FU. In patients with BD treated with PDT, complete response was found in 8 out of 10 lesions (80%) with pretreatment with fractional CO₂ laser and 20 out of 34 lesions (60%) without fractional CO₂ laser ($p=0.096$; Table 3).

Factors associated with successful treatment

When analyzing the factors associated with successful treatment, no significant correlation was found in the success rates of PDT and IMB for BD and in any of the following parameters: sex, disease duration, tumor location, histological epidermal thickness, and the number of treatment sessions and pretreatment with fractional CO₂ laser.

Table 2. Evaluation of treatment outcome

Variable	PDT	IMB	<i>p</i> -value
Lesions response at first follow-up observation			
Complete response	29 (66.7)	13 (53.0)	0.349
Incomplete response	15 (33.3)	11 (47.0)	-
Recurrence during follow-up period	3 (11.5)	2 (15.3)	0.993

Values are presented as number (%) or median (range).

Statistical significance was considered when *p*-value was below 0.05.

PDT: photodynamic therapy, IMB: ingenol mebutate, -: not available.

Only older age significantly correlated with the lower complete-response rate of IMB (*p* = 0.012; Table 3).

Adverse events

A description of the adverse events in 20 of the 68 cases was available in the patient electronic chart. Among these 20 lesions, 9 were reported from PDT (20.5%), and 11 were reported from IMB (45.8%). In PDT, the most common adverse event was crusting, which was observed in four cases. Other observations were itching (2), hyperpigmentation (2), and erythema (1). In IMB, the most common adverse event was irritation, which was observed in four cases. Other observations were crusting (2), stinging (2), and erythema (2). Nonetheless, no serious adverse events and discontinuation of treatment caused by treatment-related adverse events were reported.

DISCUSSION

Our results show that the complete-response rate of BD treated with PDT (66.7%) was higher than that of BD treated with IMB (53.0%). Meanwhile, the recurrence rates of BD treated with PDT (10.3%) was lower than of BD treated with IMB (15.3%). In a previous study, the clinical clearance and recurrence rates of BD cases treated with PDT were 76.1% ~ 98% and 10.5% ~ 31%, respectively, thereby comparable to our results^{7,14-17}. Effective treatment with IMB in several cases of BD was also reported¹⁸⁻²⁴, but studies on the clinical clearance and recurrence rates of BD treated with IMB are unavailable. The treatment outcome of PDT in BD was previously compared with other non-invasive treatments, mostly with cryotherapy and topical 5-fluorouracil cream. The results of these studies demonstrate that PDT is superior to cryotherapy and 5-fluorouracil cream in terms of therapeutic efficacy^{25,26}. Meanwhile, a comparison of the treatment outcomes of PDT and IMB in BD has not yet been reported. However, according to the results of studies comparing the treatment outcomes of

Table 3. Factors associated with successful treatment

Variable	<i>p</i> -value	
	PDT	IMB
Gender	0.827	NA
Age (yr)	0.344	0.012
Duration of disease (mo)	0.166	0.748
Tumor location	0.632	0.067
Histological epidermal thickness	0.127	0.241
Number of treatment sessions	0.334	NA
Pretreatment with fractional CO ₂	0.096	NA

Statistical significance was considered when *p*-value was below 0.05.

PDT: photodynamic therapy, IMB: ingenol mebutate, NA: not assessed.

PDT and IMB in AK, the clinical clearance rates of PDT and IMB were 67.1% and 62.9%, respectively, indicating to be nonsignificant¹³. In our study, the results demonstrate that PDT is an effective treatment option for BD, with a higher complete-response rate and lower recurrence rate than IMB. No statically significant difference of the complete-response rate and recurrence rate was found between PDT and IMB, but a larger study population and a longer FU are needed to validate these results.

The outcome of BD treatment can be variable according to several clinical and histological factors. In our study, we searched for different clinical and histological factors influencing the PDT and IMB treatment outcomes in BD. A peak incidence of BD is described between the age of 70 and 79 years². The average age of patients with BD in our study was 71.4 years. Furthermore, a significantly low complete-response rate was found in elderly patients in the IMB treatment group. Advanced age is associated with a decreased function of the immune system²⁷. Perhaps, the immune response induced by cytokine secretion by activated protein kinase C toward tumor cells during IMB is decreased in the elderly. Also, PDT is prescribed by the physician, and the treatment is performed by appropriately trained staff on a day-case basis. By contrast, IMB is applied by the patient at home. Possibly, the elderly patient has not been treated appropriately because of decreased compliance. Hence, further study is needed to compare the treatment outcomes of patients treated with IMB at the hospital and patients treated with self-application.

Meanwhile, the longer the time from lesion onset to diagnosis, the more likely it will affect biological behavior and reduce the clearance rate of treatment. However, the duration of disease in our results did not affect the treatment outcome in both PDT and IMB.

A study by Truchuelo et al.⁷ showed a decreased clearance rate on the lower extremities. Tyrrell et al.²⁸ also showed that acral tumors exhibited a lower clearance rate after PDT than non-acral tumors. In our study, tumors were most commonly located on the head and/or neck in both PDT and IMB. However, the location of BD was not significantly associated with the treatment outcome. The proportion of female patients and that of tumors located on the head and/or neck were higher in the IMB than those in the PDT. This result is because female patients consider cosmetic aspects more and prefer a simpler and more rapid treatment than male patients.

In studies concerning basal cell carcinoma (BCC), tumor thickness was a substantial predictor of clinical clearance of PDT, with no response in BCC measuring more than 2 mm thick^{29,30}. Furthermore, invasive SCC, as well as nodular BCC, has low overall success rates after PDT^{31,32}. Therefore, increased epidermal thickness might also play an important role in BD. However, in our study, the epidermal thickness was not significantly associated with the treatment outcome. The mean epidermal thicknesses were 0.63 mm and 0.38 mm in PDT and IMB, respectively, and no BD was thicker than 2 mm. These findings suggest that protoporphyrin IX (PpIX) and IMB penetrated deep enough to reach the entire epidermis and might explain why the increased epidermal thickness did not influence the treatment outcome of PDT and IMB in BD.

Another possible influencing factor is pretreatment with fractional CO₂ laser. In comparing the treatment outcomes according to the presence or absence of pretreatment with fractional CO₂ laser in PDT, the pretreatment with fractional CO₂ laser could increase the rate of complete response. The American Society of Dermatological Surgery recommends the pretreatment of hyperkeratosis before the application of photosensitizer to improve the treatment outcome³³. A review by Bay et al.³⁴ showed that pretreatment with fractional CO₂ laser, rather than curettage/debulking, microdermabrasion, and microneedling, increases the accumulation of PpIX and the treatment outcome after PDT. Although not investigated in our study, Erlendsson et al.³⁵ reported that combination therapy with fractional CO₂ laser can increase the therapeutic effectiveness of IMB, enabling customized topical delivery and the potential use of IMB for the treatment of non-melanoma skin cancer.

The main limitation of our study is the retrospective study design with a small sample size. Another limitation is that the assessment of complete response and recurrence was mainly based on clinical findings.

This retrospective study of 68 BD lesions showed that both

PDT and IMB are effective noninvasive treatment modalities for BD. However, PDT is a safer treatment modality than IMB, considering that PDT has fewer adverse events. Especially in patients with old age, which is a factor that reduces IMB treatment outcome, PDT can be considered as preferred treatments over IMB for BD. In patients with BD treated with PDT, pretreatment with fractional CO₂ laser tends to increase the complete response rate. We recommend pretreatment with fractional CO₂ laser to improve the treatment outcome in BD treatment with PDT and IMB. Further prospective studies with a large sample size are required to acquire even better and more reliable data.

CONFLICTS OF INTEREST

The authors have nothing to disclose.

ORCID

Ji Hae An, <https://orcid.org/0000-0003-0497-9538>

Jung U Shin, <https://orcid.org/0000-0001-5259-6879>

Hyun Jung Kim, <https://orcid.org/0000-0001-5125-667X>

Hee Jung Lee, <https://orcid.org/0000-0001-9140-9677>

Moon Soo Yoon, <https://orcid.org/0000-0002-7470-6802>

Dong Hyun Kim, <https://orcid.org/0000-0003-3394-2400>

REFERENCES

1. Park MS, Kim YD, Seo YJ, Lee JH, Park JK. A clinicopathologic study of Bowen's disease. *Korean J Dermatol* 2003;41:1157-1162.
2. Choi HB, Joh OJ, Park SR, Kim NI. A clinicopathologic study of Bowen's disease. *Korean J Dermatol* 2006;44:1058-1064.
3. Cassarino DS, Derienzo DP, Barr RJ. Cutaneous squamous cell carcinoma: a comprehensive clinicopathologic classification—part two. *J Cutan Pathol* 2006;33:261-279.
4. Cox NH, Eedy DJ, Morton CA; Therapy Guidelines and Audit Subcommittee, British Association of Dermatologists. Guidelines for management of Bowen's disease: 2006 update. *Br J Dermatol* 2007;156:11-21.
5. Bonerandi JJ, Beauvillain C, Caquant L, Chassagne JF, Chaussade V, Clavère P, et al; French Dermatology Recommendations Association (aRED). Guidelines for the diagnosis and treatment of cutaneous squamous cell carcinoma and precursor lesions. *J Eur Acad Dermatol Venereol* 2011;25 Suppl 5:1-51.
6. National Comprehensive Cancer Network. NCCN clinical practice guidelines in oncology (NCCN Guidelines[®]). Basal cell and squamous cell skin cancers [Internet]. Pennsylvania, PA: National Comprehensive Cancer Network; 2012. Available from: <http://www.nccn.org/professionals>.
7. Truchuelo M, Fernández-Guarino M, Fleta B, Alcántara J, Jaén P. Effectiveness of photodynamic therapy in Bowen's

- disease: an observational and descriptive study in 51 lesions. *J Eur Acad Dermatol Venereol* 2012;26:868-874.
8. Bath-Hextall FJ, Matin RN, Wilkinson D, Leonardi-Bee J. Interventions for cutaneous Bowen's disease. *Cochrane Database Syst Rev* 2013;6:CD007281.
 9. Morton CA, McKenna KE, Rhodes LE; British Association of Dermatologists Therapy Guidelines and Audit Subcommittee and the British Photodermatology Group. Guidelines for topical photodynamic therapy: update. *Br J Dermatol* 2008; 159:1245-1266.
 10. Kim YJ, Kang HY, Lee ES, Kim YC. Photodynamic therapy for treatment of Bowen's disease. *Korean J Dermatol* 2007; 45:237-241.
 11. Genovese G, Fai D, Fai C, Mavilia L, Mercuri SR. Daylight methyl-aminolevulinate photodynamic therapy versus ingenol mebutate for the treatment of actinic keratoses: an individual comparative analysis. *Dermatol Ther* 2016;29:191-196.
 12. Moggio E, Arisi M, Zane C, Calzavara-Pinton I, Calzavara-Pinton P. A randomized split-face clinical trial analyzing daylight photodynamic therapy with methyl aminolaevulinate vs ingenol mebutate gel for the treatment of multiple actinic keratoses of the face and the scalp. *Photodiagnosis Photodyn Ther* 2016;16:161-165.
 13. Zane C, Fabiano A, Arisi M, Calzavara-Pinton P. A randomized split-face clinical trial of photodynamic therapy with methyl aminolevulinate versus ingenol mebutate gel for the treatment of multiple actinic keratoses of the face and scalp. *Dermatol* 2016;232:472-477.
 14. Shimizu I, Cruz A, Chang KH, Dufresne RG. Treatment of squamous cell carcinoma in situ: a review. *Dermatol Surg* 2011;37:1394-1411.
 15. Varma S, Wilson H, Kurwa HA, Gambles B, Charman C, Pearse AD, et al. Bowen's disease, solar keratoses and superficial basal cell carcinomas treated by photodynamic therapy using a large-field incoherent light source. *Br J Dermatol* 2001;144:567-574.
 16. Morton CA, Whitehurst C, McColl JH, Moore JV, MacKie RM. Photodynamic therapy for large or multiple patches of Bowen disease and basal cell carcinoma. *Arch Dermatol* 2001;137:319-324.
 17. Calin MA, Diaconeasa A, Savastru D, Tautan M. Photosensitizers and light sources for photodynamic therapy of the Bowen's disease. *Arch Dermatol Res* 2011;303:145-151.
 18. Mainetti C, Guillod C, Leoni-Parvex S. Successful treatment of relapsing Bowen's disease with ingenol mebutate: the use of dermoscopy to monitor the therapeutic response. *Dermatol* 2016;232 Suppl 1:9-13.
 19. Salleras Redonnet M, Quintana Codina M. Ingenol mebutate gel for the treatment of Bowen's disease: a case report of three patients. *Dermatol Ther* 2016;29:236-239.
 20. Lee JH, Lee JH, Bae JM, Kim GM. Successful treatment of Bowen's disease with ingenol mebutate 0.05% gel. *J Dermatol* 2015;42:920-921.
 21. Mohanna MT, Hofbauer GF. Bowenoid actinic keratosis and Bowen's disease treated successfully with ingenol mebutate. *Dermatol* 2016;232 Suppl 1:14-16.
 22. Alkhalaf A, Hofbauer GF. Ingenol mebutate 150 mg as physician-directed treatment of Bowen's disease under occlusion. *Dermatol* 2016;232 Suppl 1:17-19.
 23. Braun SA, Homey B, Gerber PA. [Successful treatment of Bowen disease with ingenol mebutate]. *Hautarzt* 2014;65: 848-850. German.
 24. Lee DW, Ahn HH, Kye YC, Seo SH. Clinical experience of ingenol mebutate gel for the treatment of Bowen's disease. *J Dermatol* 2018;45:425-430.
 25. Morton C, Horn M, Leman J, Tack B, Bedane C, Tjioe M, et al. Comparison of topical methyl aminolevulinate photodynamic therapy with cryotherapy or fluorouracil for treatment of squamous cell carcinoma in situ: results of a multicenter randomized trial. *Arch Dermatol* 2006;142:729-735.
 26. Salim A, Leman JA, McColl JH, Chapman R, Morton CA. Randomized comparison of photodynamic therapy with topical 5-fluorouracil in Bowen's disease. *Br J Dermatol* 2003; 148:539-543.
 27. Montecino-Rodriguez E, Berent-Maoz B, Dorshkind K. Causes, consequences, and reversal of immune system aging. *J Clin Invest* 2013;123:958-965.
 28. Tyrrell JS, Morton C, Campbell SM, Curnow A. Comparison of protoporphyrin IX accumulation and destruction during methylaminolevulinate photodynamic therapy of skin tumours located at acral and nonacral sites. *Br J Dermatol* 2011;164: 1362-1368.
 29. Li Q, Gao T, Jiao B, Hu X, Luan Q, Li K, et al. Tumor thickness predicts long-term complete response of facial basal cell carcinomas in Asian skin types iv/v treated with methyl aminolaevulinate photodynamic therapy. *Photomed Laser Surg* 2011;29:501-507.
 30. Morton CA, MacKie RM, Whitehurst C, Moore JV, McColl JH. Photodynamic therapy for basal cell carcinoma: effect of tumor thickness and duration of photosensitizer application on response. *Arch Dermatol* 1998;134:248-249.
 31. Calzavara-Pinton PG, Venturini M, Sala R, Capezzer R, Parinello G, Specchia C, Zane C. Methylaminolevulinate-based photodynamic therapy of Bowen's disease and squamous cell carcinoma. *Br J Dermatol* 2008;159:137-144.
 32. Mosterd K, Thissen MR, Nelemans P, Kelleners-Smeets NW, Janssen RL, Broekhof KG, et al. Fractionated 5-aminolaevulinic acid-photodynamic therapy vs. surgical excision in the treatment of nodular basal cell carcinoma: results of a randomized controlled trial. *Br J Dermatol* 2008;159:864-870.
 33. Ozog DM, Rkein AM, Fabi SG, Gold MH, Goldman MP, Lowe NJ, et al. Photodynamic therapy: a clinical consensus guide. *Dermatol Surg* 2016;42:804-827.
 34. Bay C, Lerche CM, Ferrick B, Philipsen PA, Togsverd-Bo K, Haedersdal M. Comparison of physical pretreatment regimens to enhance protoporphyrin IX uptake in photodynamic therapy: a randomized clinical trial. *JAMA Dermatol* 2017; 153:270-278.
 35. Erlendsson AM, Taudorf EH, Eriksson AH, Haak CS, Zibert JR, Paasch U, et al. Ablative fractional laser alters biodistribution of ingenol mebutate in the skin. *Arch Dermatol Res* 2015;307:515-522.