

A Rare Case of an Aneurysmal Bone Cyst of the Temporal Bone

Abstract

Aneurysmal bone cysts (ABCs) are benign bone lesions mainly occurring at the metaphyseal end of long bones and are a rarity in the calvarium. The reported incidence of this lesion in the skull is 1% of all the ABC. It is a benign condition that may extend intracranially. We report here a case of a 3½-year-old male child who presented with a bony hard, painless, and gradually enlarging swelling over his right temporal region. Radiological investigations and histology revealed that the lesion was an ABC. A total surgical excision was achieved despite its intracranial extension along with the involvement of dura. Prognosis is excellent with total removal as a total surgical removal of the lesion is considered curative. The rarity of the lesion along with a good surgical result despite an intracranial extension with dural involvement prompted this report.

Keywords: *Aneurysmal bone cyst, rare, temporal*

Introduction

Aneurysmal bone cyst (ABC) is a benign bony lesion, first described by Jaffe and Lichtenstein in 1942.^[1] Approximately 36%–50% of all ABCs are found in the metaphyseal end of long bones, and 25% may involve the vertebrae, hyoid, mandible, and adenoid.^[2,3] The reported incidence in the skull is 1% of all ABCs.^[4] Sixty-three cases of ABCs of the skull have been reported in the literature of which 11 were of the temporal bone.^[5] Most of the cases of ABC manifest before the age of 20 years.^[3] The pathogenesis of ABC is still obscure.^[6] An unusual case of ABC in the right temporal region of a very young child is reported here.

Case Report

A 3½-year-old male child [Figure 1] presented with gradually increasing painless swelling in the right temporozygomatic region for the past 8 months. He had occasional pain in the swelling for the past 3 months. On examination, a nontender mass was evident in the right temporozygomatic region measuring 6.5 cm × 5 cm × 2.5 cm, which was bony hard and fixed to the underlying bone with a smooth surface and a normal skin over the swelling. There was no neurological

deficit. Systemic examination and examination of the long bones were normal. Hemoglobin was 12 g%, and all other routine investigations were within normal limits.

X-ray skull revealed a rounded, well-defined radiolucent area in the right temporal bone with ballooned out distension of periosteum, outlined by a paper-thin subperiosteal bone. Computed tomography (CT) scan head (plain and contrast) showed [Figure 2] an extra-axial, heterogeneous mixed density mass in the right temporal region with multiple internal loculations and fluid levels, taking variegated contrast enhancement. The mass was extending medially and compressing the right temporal lobe. The mass showed rapid enlargement with more fluid levels in the past 3 months. Three-dimensional CT scan with bony reconstruction images showed erosion of the petrous and sphenoid wing of the temporal bone with partial involvement of the zygomatic bone. Magnetic resonance imaging (MRI) and angiography were not done.

Intraoperatively [Figure 3], control over the external carotid artery was taken in the neck. A right temporal question mark incision was taken, and the skin flap was raised with the

**Sarang Gotecha,
Prashant Punia,
Ashish Chugh,
Anil Patil,
Dushyant Kashyap,
Vybhav Raghu,
Shobhit Chhabra,
Ankit Patel,
Megha Kotecha**

*Department of Neurosurgery,
Dr. D. Y. Patil Medical
College and Hospital, Pune,
Maharashtra, India*

Address for correspondence:

*Dr. Prashant Punia,
Department of Neurosurgery,
Dr. D. Y. Patil Medical College
and Hospital, Sant Tukaram
Nagar, Pimpri, Pune - 411 018,
Maharashtra, India.
E-mail: getdrprashant@gmail.
com*

This is an open access journal, and articles are distributed under the terms of the Creative Commons Attribution-NonCommercial-ShareAlike 4.0 License, which allows others to remix, tweak, and build upon the work non-commercially, as long as appropriate credit is given and the new creations are licensed under the identical terms.

For reprints contact: WKHLRPMedknow_reprints@wolterskluwer.com

How to cite this article: Gotecha S, Punia P, Chugh A, Patil A, Kashyap D, Raghu V, *et al.* A rare case of an aneurysmal bone cyst of the temporal bone. *Asian J Neurosurg* 2020;15:699-702.

Submitted: 06-May-2019 **Revised:** 14-Jul-2019
Accepted: 13-Jan-2020 **Published:** 28-Aug-2020

Access this article online

Website: www.asianjns.org

DOI: 10.4103/ajns.AJNS_125_19

Quick Response Code:



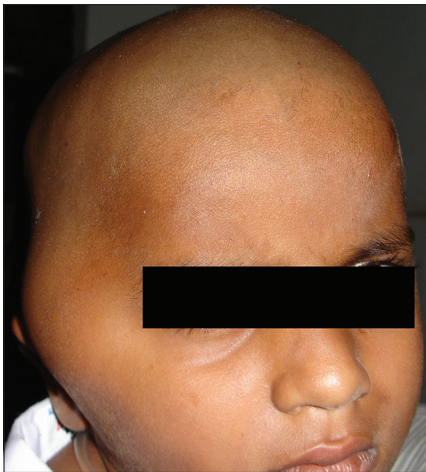

Figure 1: Subject with swelling in the right temporal region

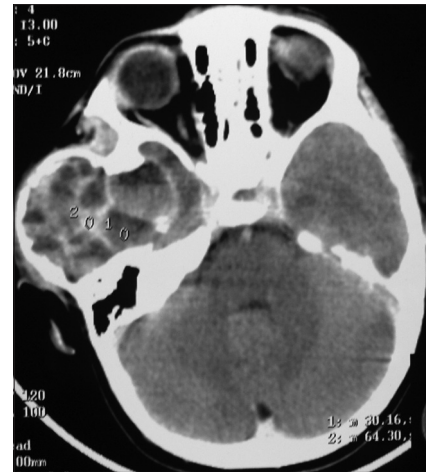

Figure 2: Computed tomography scan head (plain and contrast) showed an extra axial, heterogeneous mixed density mass in the right temporal region with multiple internal loculations and fluid levels, taking variegated contrast enhancement

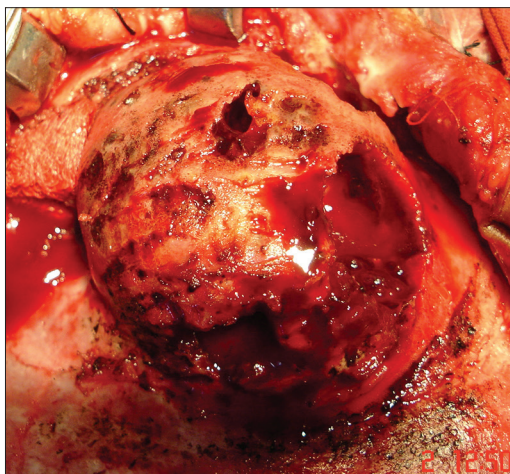


Figure 3: Intraoperative image showing well-defined capsulated and was soft in consistency involving the adjacent petrous temporal bone and greater wing of sphenoid tumor was densely adherent to the underlying dura

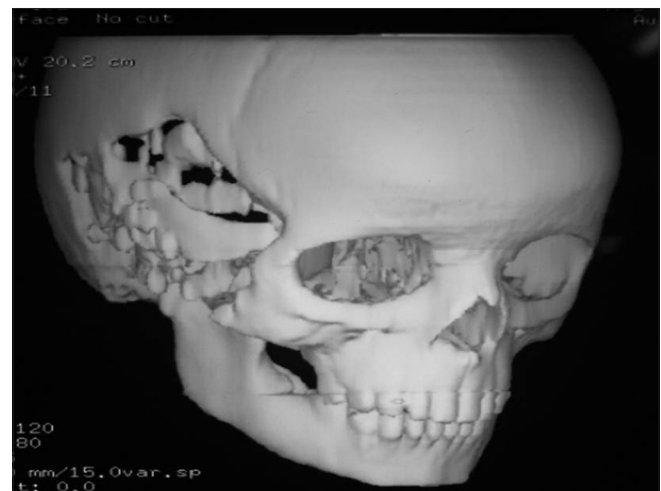

Figure 4: Three-dimensional recon image showing split calvarial bone graft placed intraoperatively

temporalis muscle. The underlying temporal bone was thinned out and was perforated during exploration through which dark-colored blood was seen coming out from the lesion. The tumor was well-defined capsulated and was soft in consistency involving the adjacent petrous temporal bone and greater wing of sphenoid. The zygomatic bone was also removed. The tumor was densely adherent to the underlying dura, which was torn during dissection. To ensure a complete removal of the lesion, the cyst was removed along with the underlying adherent dura with a sufficiently wide margin. The dural defect was then repaired with artificial dura. Total surgical excision was achieved. Cranioplasty was achieved from the normal bone taken from the surroundings of the lesion. Split calvarial bone graft pieces [Figure 4] were harvested from this normal bone and these pieces were then used to bridge the bony defect which was caused due to removal of the bony lesion.

The patient was symptom free in postoperative period except for mild cerebrospinal fluid leakage from the right external auditory canal, which resolved spontaneously in

3 days with conservative management. No adjuvant therapy was required in the postoperative period.

Histopathological examination showed numerous dilated blood spaces which were devoid of endothelial cells. Large areas of extravasated blood were seen. The spaces were separated by collagenous and osteoid trabeculae, bordered by numerous multinucleated giant cell osteoclasts. Normal bony trabeculae being permeated by the lesion in the periphery was suggestive of ABC.

Discussion

ABC is a benign, nonneoplastic lesion of the bone commonly seen in younger age group, usually before the age of 20 years with equal sex distribution [Table 1].^[6-9] They usually present as scalp masses and occasionally may present as intracranial space-occupying lesion^[10] or with cerebral hemorrhage.^[11] Reviewing 63 cases,

Table 1: Reported cases of temporal aneurysmal bone cyst other than the present case

Authors	Year
Kletke <i>et al.</i> ^[26]	2015
Ansari <i>et al.</i> ^[27]	2013

Sheikh *et al.*^[5] observed that the majority of ABCs occurred in the temporal and occipital bone. The exact pathogenesis of ABC is not well known; however, local trauma has been put forward as an important etiological factor.^[1,8,12,13]

Edling^[1] regarded ABC as one of the manifestations of solitary dysfibroplasia of bone, suggesting a defect in the development of the epiphyseal plate, but it does not explain its occurrence in mature bone. Jaffe^[14] reported that a preexisting lesion of bone may initiate an osseous arteriovenous fistula. Lichtenstein^[2] suggested that it could result from local circulatory disturbances, because of sudden vascular occlusion of venous drainage of that segment of bone or development of an A-V shunt, which resulted in the formation of progressive blood-filled spaces in the medulla, which may lead to gradual distension of the bone with atrophy.

Bony lesions such as fibrous dysplasia, chondrosarcoma, osteoclastoma, nonossifying fibroma, giant cell tumor, fibromyxoma, unicameral bone cyst, osteoblastoma, and cartilaginous hematoma of the chest wall of infants, were demonstrated to be associated with ABC.^[15,16]

Jaffe^[14] introduced the concept of ABC as a lesion with characteristic radiological appearance of ballooned out distension of the periosteum, usually outlined by a paper thin subperiosteal bone shell which is overlined by a region of disintegrated cortex.

CT scan is superior to plain radiology in defining extent and soft-tissue extension of an ABC, and particularly in the skull, multiple small fluid levels are important characteristics of ABC on CT scan, which represent the sedimentation of RBCs within the blood-filled cavities.^[17] MRI also shows fluid levels, particularly in the T1-weighted images. Other findings include complete delineation of the margin of the lesion by a rim of low-intensity signal and internal septations creating cystic cavities where wall contains diverticulum-like projection.^[18]

Several therapeutic modalities are used for the treatment of ABC, including simple curettage, complete surgical excision, radiotherapy, cryosurgery, and endovascular embolization.^[19-22]

The treatment of choice for these lesions is total excision, as it is curative.^[23,24] Simple curettage is related with high recurrence rates varying from 21% of 50%. These lesions being nonneoplastic, the use of radiotherapy is not

recommended although it is mentioned in literature and has been advocated for deeply situated lesions of the base of skull with dural involvement where subtotal excision is done, its effect is unclear.^[11] The suggested dose ranges from 600 to 3000 rads.^[5,19] Radiotherapy is however contraindicated in the treatment of ABC associated with fibrous dysplasia, as there are increased chances of malignant transformation.^[25] Chemotherapy has no role in the management of ABC.

Endovascular embolization plays an important role in preoperative devascularization of the lesion to reduce intraoperative bleeding. Endovascular embolization can be used in cases where the tumor is located in an area difficult for surgical resection.^[20]

Declaration of patient consent

The authors certify that they have obtained all appropriate patient consent forms. In the form the patient(s) has/have given his/her/their consent for his/her/their images and other clinical information to be reported in the journal. The patients understand that their names and initials will not be published and due efforts will be made to conceal their identity, but anonymity cannot be guaranteed.

Financial support and sponsorship

Nil.

Conflicts of interest

There are no conflicts of interest.

References

- Edling NP. Is the aneurysmal bone cyst a true pathologic entity? *Cancer* 1965;18:1127-30.
- Lichtenstein L. Aneurysmal bone cyst; observations on fifty cases. *J Bone Joint Surg Am* 1957;39-A:873-82.
- Tillman BP, Dahlin DC, Lipscomb PR, Stewart JR. Aneurysmal bone cyst: An analysis of ninety-five cases. *Mayo Clin Proc* 1968;43:478-95.
- Kumar R, Mukherjee KK. Aneurysmal bone cysts of the skull: Report of three cases. *Br J Neurosurg* 1999;13:82-4.
- El Deeb M, Sedano HO, Waite DE. Aneurysmal bone cyst of the jaws. Report of a case associated with fibrous dysplasia and review of the literature. *Int J Oral Surg* 1980;9:301-1.
- Jermiah BS. Aneurysmal bone cyst. Further observations. *Cancer* 1953;6:1228-37.
- Bhende YM, Kothare SN. Aneurysmal bone cyst; a case report. *Ind Med Gaz* 1950;85:544-6.
- Burns-cox CJ, Higgins AT. Aneurysmal bone cyst report. *J Neurosurg* 1980;53:113-6.
- Odeku EL, Mainwaring AR. Unusual aneurysmal bone cyst: A case Report. *J Neurosurg* 1965;22:172-6.
- Costantini FE, Iraci G, Benedetti A, Melanotte PL. Aneurysmal bone cyst as an intracranial space-occupying lesion. Case report. *J Neurosurg* 1966;25:205-7.
- Keuskamp PA, Horoupian DS, Fein JM. Aneurysmal bone cyst of the temporal bone presenting as a spontaneous intracerebral hemorrhage: Case report. *Neurosurgery* 1980;7:166-70.
- Barnes R. Aneurysmal bone cyst. *J Bone Joint Surg Br* 1956;38-B:301-11.

13. Komjátszegi S. Aneurysmal bone cyst of the skull. *J Neurosurg* 1981;55:497.
14. Jaffé HL. Discussion following a paper by Donaldson W F Jr. Aneurysmal bone cyst. *J Bone Joint Sur* 1962;44A:25-40.
15. Cacadac MA, Malis LI, Anderson PJ. Aneurysmal parietal bone cyst. Case report. *J Neurosurg* 1972;37:237-41.
16. Som PM, Schatz CJ, Flaum EG, Lanman TH. Aneurysmal bone cyst of the paranasal sinuses associated with fibrous dysplasia: CT and MR findings. *J Comput Assist Tomogr* 1991;15:513-5.
17. Hudson TM. Fluid levels in aneurysmal bone cysts: A CT feature. *AJR Am J Roentgenol* 1984;142:1001-4.
18. Beltran J, Simon DC, Levy M, Herman L, Weis L, Mueller CF. Aneurysmal bone cysts: MR imaging at 1.5 T. *Radiology* 1986;158:689-90.
19. Biesecker JL, Marcove RC, Huvos AG, Miké V. Aneurysmal bone cysts. A clinicopathologic study of 66 cases. *Cancer* 1970;26:615-25.
20. Cory DA, Fritsch SA, Cohen MD, Mail JT, Holden RW, Scott JA, *et al.* Aneurysmal bone cysts: Imaging findings and embolotherapy. *AJR Am J Roentgenol* 1989;153:369-73.
21. Chartrand-Lefebvre C, Dubois J, Roy D, Mercier C, Raymond J. Direct intraoperative sclerotherapy of an aneurysmal bone cyst of the sphenoid. *AJNR Am J Neuroradiol* 1996;17:870-2.
22. Ruitter DJ, van Rijssel TG, van der Velde EA. Aneurysmal bone cysts: A clinicopathological study of 105 cases. *Cancer* 1977;39:2231-9.
23. Kumar S, Retnam TM, Krishnamoorthy T, Parameswaran S, Nair S, Bhattacharya NR, *et al.* Intracranial aneurysmal bone cyst manifesting as a cerebellar mass. *Neurology India* 2003;51; p. 121-3.
24. Dahlin DC, McLeod RA. Aneurysmal bone cyst and other nonneoplastic conditions. *Skeletal Radiol* 1982;8:243-50.
25. Branch CL Jr., Challa VR, Kelly DL Jr. Aneurysmal bone cyst with fibrous dysplasia of the parietal bone. Report of two cases. *J Neurosurg* 1986;64:331-5.
26. Kletke SN, Popovic S, Algird A, Alobaid A, Reddy KK. Aneurysmal Bone Cyst of the Temporal Bone Presenting with Headache and Partial Facial Palsy. *J Neurol Surg Rep* 2015;76:e18-22.
27. Ansari S, Ahmad K, Gupta MK, Rauniyar RK. Aneurysmal Bone Cyst of the Temporal Bone. *BMJ Case Rep* 2013;2013:bcr2013009434.