


# Computed Tomographic Assessment of Autologous Fat Injection Augmentation for Vocal Fold Paralysis

Naoki Nishio, MD, PhD ; Yasushi Fujimoto, MD, PhD; Mariko Hiramatsu, MD, PhD; Takashi Maruo, MD, PhD; Kenji Suga, MD; Hidenori Tsuzuki, MD; Nobuaki Mukoyama, MD; Mariko Shimono, MD, PhD; Kazuhiro Toriyama, MD, PhD; Keisuke Takanari, MD, PhD; Yuzuru Kamei, MD, PhD; Michihiko Sone, MD, PhD

**Objective:** To perform a quantitative computed tomography (CT) assessment of short- and long-term outcomes of autologous fat injection augmentation in patients with unilateral vocal fold paralysis.

**Study Design:** Retrospective case series.

**Methods:** Twelve patients who had undergone autologous fat injection augmentation for unilateral vocal fold paralysis in our hospital between 2011 and 2015 were enrolled in this study. The autologous fat for injection was acquired from periumbilical subcutaneous tissue and was injected orally using a special-purpose laryngeal injection needle. To evaluate the injected fat at the follow-up assessments, CT was performed at several times after surgery in clinical practice. All thin-section CT images were transferred to a workstation, and the volume of the injected fat was calculated.

**Results:** Patients comprised 6 men and 6 women with a mean age at the time of surgery of 62.9 years (range, 46–82 years). The actual injected fat volume was 1.1–2.5 ml (mean, 1.6 ml). In seven patients assessed by CT two days after surgery, the average residual rate of the injected fat was 63.9%. The mean residual rates of the injected fat were 30.0% at 3 months, 33.7% at 6 months, 29.2% at 12 months, and 32.0% at 24 months.

**Conclusions:** Although the injected fat volume decreased within the first three months and the residual rate of the injected fat was 30.0% at three months after injection, the residual fat volume remained at the same level for 24 months after injection.

**Key Words:** fat injection, computed tomography, vocal fold paralysis.

**Level of Evidence:** 4

## INTRODUCTION

Patients with unilateral vocal fold paralysis (UVFP) often experience dysphonia and dysphagia, and have a poor quality of life.<sup>1,2</sup> Surgical options for this disorder include vocal fold injection, laryngoplasty type 1, arytenoid adduction, and reinnervation.<sup>3–6</sup> Injection augmentation is the oldest treatment method for UVFP; paraffin

was first used as an injection material in 1911.<sup>7</sup> Although several materials have been used for injection augmentation, reaction to a foreign body and absorption are problems to be solved, and no materials to solve these problems are known. Autologous fat injection therapy of the vocal folds was reported in 1991 by Mikaelian et al. and is ideal when the glottic gap is relatively small.<sup>8</sup> Although autologous fat injection therapy has become common because it does not induce any reaction to a foreign body, its effects diminish with time as the injected fat is gradually absorbed.<sup>3,8</sup> This gradually worsens the quality of voice over time.

Several authors have used computed tomography (CT) to provide a detailed quantitative assessment after autologous fat injection augmentation of a paralyzed vocal fold.<sup>5,9</sup> However, there are no reports of the CT image data immediately after fat injection and the sequential changes in the injected fat volume over long follow-up periods. The aim of the present study was to perform a quantitative CT assessment of the short- and long-term outcomes of autologous fat injection augmentation in patients with UVFP.

## MATERIALS AND METHODS

### Patients

The cases of 12 patients with UVFP who underwent autologous fat injection therapy in the Department of Otorhinolaryngology

This is an open access article under the terms of the Creative Commons Attribution-NonCommercial-NoDerivs License, which permits use and distribution in any medium, provided the original work is properly cited, the use is non-commercial and no modifications or adaptations are made.

From the Department of Otorhinolaryngology (N.N., Y.F., M.H., T.M., K.S., H.T., N.M., M.S., M. Sone), Nagoya University Graduate School of Medicine, Nagoya, Japan; the Department of Plastic and Reconstructive Surgery (K.T., K. Takanari, Y.K.), Nagoya University Graduate School of Medicine, Nagoya, Japan; and the Department of Plastic and Reconstructive Surgery (K.T.), Nagoya City University Hospital, Nagoya, Japan

Editor's Note: This Manuscript was accepted for publication 24 October 2017.

Sources of financial support: This work was supported in part by a Japan Society for the Promotion of Science Grant-in-Aid for Young Scientists (B) JP17K16906.

Conflict of interest: None.

Send correspondence to Naoki Nishio, MD, PhD, Department of Otorhinolaryngology, Nagoya University Graduate School of Medicine, 65, Tsurumai-cho, Showa-ku, Nagoya 466-8550, Japan. Email: naokin@med.nagoya-u.ac.jp

DOI: 10.1002/liv.2.125

at Nagoya University Hospital between 2011 and 2015 were reviewed retrospectively. We analyzed their clinical data such as age, sex, preoperative body mass index (BMI), primary disease, operation time, injected fat volume, and CT images of the neck. CT was performed at several times after surgery in clinical practice as considered appropriate to the primary disease and the patient's phonation. The enrollment criteria included the availability of a CT scan at least once within 12 months postoperatively. The same surgeons (the first and second authors) performed all fat injections. This retrospective study and the clinical record reviews were approved by the Ethics Review Committee of Nagoya University Hospital.

### **Treatment Strategy for UVFP**

We performed a multimodal diagnostic study using a combination of clinical history, direct flexible laryngoscopy, stroboscopy, and thin-slice CT, which included the thorax, to exclude nonidiopathic causes such as those secondary to nerve compression by a malignancy. For patients with UVFP with a small gap between the right and left vocal processes, fat injection therapy or laryngoplasty type 1 was performed. For patients with UVFP with a very large gap between these processes, fat injection therapy or laryngoplasty type 1 was not sufficient by itself to improve the voice. Considering the patient's request, clinical history, and general condition, arytenoid adduction was performed under general anesthesia before fat injection therapy or under local anesthesia at the time of the laryngoplasty type 1. If glottic incompetence caused by vocal fold atrophy remained and the improvement in the voice was not sufficient after only arytenoid adduction, fat injection therapy was performed under general anesthesia. We used the arytenoid adduction procedure described by Isshiki et al. in 1978 to correct the persistent posterior glottic gap and vocal fold height mismatch.<sup>10</sup>

### **Harvesting Adipose Tissue (Liposuction) and Vocal Fold Injection**

All surgical procedures were conducted under general anesthesia by head and neck or plastic and reconstructive surgeons. Ringer's lactate was first infused into the subcutaneous layer, and adipose tissue was harvested from the anterior abdominal wall by making one 3-mm incision. Manual liposuction was performed using an 18-G liposuction cannula and a 10-mL syringe as the collecting device. The inner syringe was pulled out to create a vacuum in the syringe. The autologous suctioned materials were collected by moving the cannula into the subcutaneous adipose tissue. The suctioned adipose tissue was irrigated with Ringer's lactate and then filtered with a sieve to separate the remaining blood, free fatty acids, and other cellular debris. The fat was loaded in a retrograde fashion into a 3-mL disposable syringe and was injected using a Celbrush instrument (Cytori Therapeutics; San Diego, CA, USA), which allowed the surgeon, with a brush of the thumb, to control exactly the amount of fat droplets injected into the vocal fold. The vocal fold was exposed by insertion of a rigid suspension laryngoscope (Rudert Anterior Commissure Triangular Laryngoscope; Karl Storz, Tuttingen, Germany). Autologous fat was injected into the paralyzed side on the lateral aspect of the vocal process at the posterior third of the membranous cord. The injection was performed orally using a special-purpose laryngeal injection needle (18-G; Nagashima Medical Instruments, Tokyo, Japan). To avoid rapid leakage of the fat from the insertion site of the laryngeal injection needle, cotton was pressed over the insertion site for about 5 min after fat injection.

### **CT Assessment of Injected Autologous Fat Volume**

CT images of the neck were obtained from 1.0- or 2.0-mm slices (64-row multidetector Aquilion scanner; Toshiba, Tokyo, Japan) after the fat injection therapy. All thin-section images were transferred to a Synapse Vincent volume analyzer (Fuji-film Medical Co., Ltd., Tokyo, Japan) to measure the injected autologous fat volume. In each patient, the borders of the injected fat were traced manually on a screen using a mouse-controlled cursor on an axial image. The software then generated a 3-dimensional (3D) model and calculated the injected fat volume directly (Fig. 1). To verify whether the injected fat calculated from the CT images reflects the actual residual fat tissue, the radiodensity of the injected fat calculated from CT images was measured in Hounsfield units (HU). The scale is a quantitative measure of radiodensity that ranges from -1,000 for air to +1,000 for bone. The mean HU, range, and standard deviation (SD) were calculated for all CT images. All measurements were performed twice by two head and neck surgeons independently, and the mean values were used for analysis.

### **Statistical Analysis**

The postoperative residual rates of the injected fat and other variables such as age, sex, lesion side, preoperative BMI, and previous treatment were compared between subgroups using the Mann-Whitney *U* test. The postoperative residual rate of the injected fat was defined as the mean residual rate three months postoperatively. To analyze the effects of age and BMI, we divided the patients into two groups: BMI  $\leq 22$  and  $>22$  kg/m<sup>2</sup>, and age  $\leq 60$  and  $>60$  years. Significance was defined as  $P < .05$ . The intraobserver repeatability and reproducibility of the two observers were evaluated using intraclass correlation coefficients (ICCs). The statistical analyses were performed using IBM SPSS Statistics (version 24; IBM Corp., Armonk, NY, USA).

## **RESULTS**

Table I shows the characteristics of the 12 patients with UVFP. The mean follow-up duration was 15 months (range, 1–24 months). The patients comprised six men and six women with a mean age at the time of surgery of 62.9 years (range, 46–82 years) and a mean BMI of 22.6 kg/m<sup>2</sup> (range, 18.3–27.1 kg/m<sup>2</sup>). The primary diseases related to UVFP were recurrent nerve paralysis caused by surgery for thyroid cancer in four patients, for aortic aneurysm in four patients, for lung cancer, for esophageal cancer, and for thymus tumor in one patient each, and invasion of thyroid cancer in one patient. The mean duration from the onset of UVFP to the fat injection therapy was 11 months (range, 4–21 months). Five patients had received arytenoid adduction before the fat injection therapy because of the existence of a gap between both vocal folds. Seven patients had received no phonosurgery before the fat injection therapy. The mean operation time was 66.4 min (range, 44–87 min). The mean actual injected fat volume was 1.6 mL (range, 1.1–2.5 mL). Seven of the 12 patients with UVFP were assessed by CT two days after surgery. The mean actual injected fat volume was 1.9 mL (range, 1.1–2.5 mL) for these seven patients. The mean residual rate of the injected fat two days after surgery as measured by CT

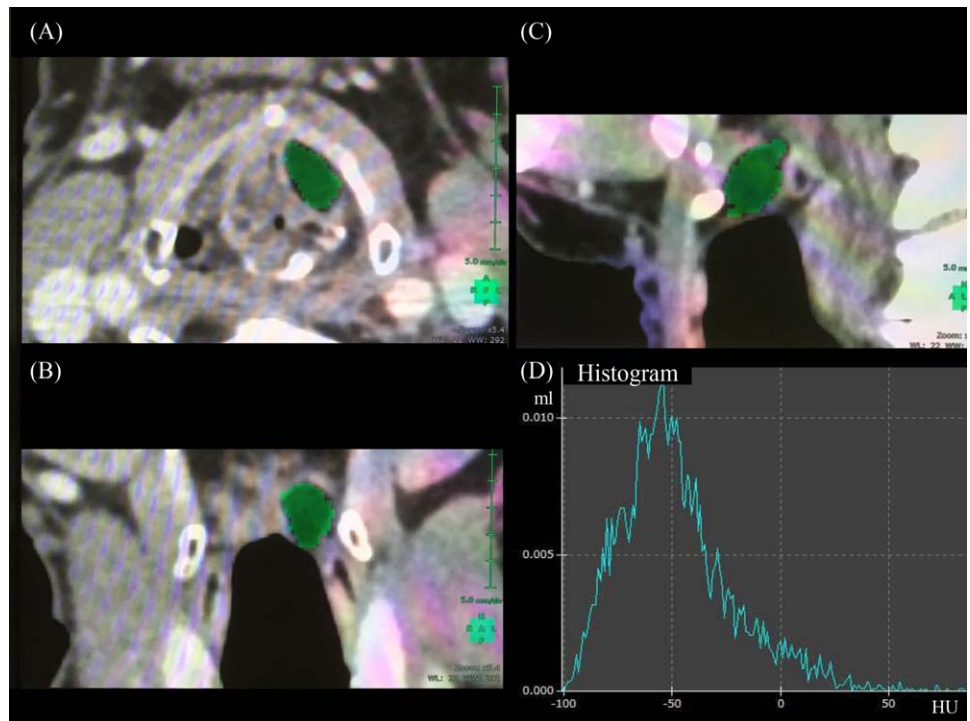


Fig. 1. Computed tomography images (A, axial; B, coronal; C, sagittal) of the larynx after autologous fat injection augmentation. The green regions reflect the injected fat. (D) Histogram of the traced regions.

was 63.9%. The mean radiodensity was  $-56$  HU (range,  $-69$  to  $-37$  HU).

Figure 2 shows the changes in the injected fat volume in 10 patients during the follow-up period. The mean residual rates of the injected fat were 30.0% (range, 15.6–46.3%, 7 patients) at 3 months, 33.7% (range, 14.0–44.4%, 5 patients) at 6 months, 29.2% (range, 17.3–46.7%, 6 patients) at 12 months, and 32.0% (range, 16.0–55.2%, 5 patients) at 24 months. The injected fat volume decreased within the first 3 months after injection, and the residual fat volume was maintained at the same level at 24 months after injection. The postoperative residual rate of the injected fat did not correlate with age, sex, lesion side, BMI, or previous treatment.

The intraobserver repeatability was high for both observers; the ICCs were 0.991 (95% confidence interval [CI]: 0.982–0.996) and 0.998 (95% CI: 0.996–0.999). The reproducibility of the two observers was also high (ICC: 0.986, 95% CI: 0.972–0.993).

### Illustrative Case

A 46-year-old woman (Patient 3) experienced dysphonia. Her right vocal fold had become fixed in the paramedian position after thyroid cancer surgery and showed signs of atrophy, and a gap between the vocal folds remained when vocalizing (Fig. 3). We chose autologous fat injection therapy and injected autologous fat (1.2 mL) into the right vocal fold under general anesthesia. CT assessments were performed at 3, 12, and 24 months after surgery, and the residual rates were 15.6% at 3 months, 16.9% at 12 months, and 16.5% at 24 months. In the follow-up period, evaluation using direct flexible laryngoscopy was conducted every three months. Fullness of the right vocal fold was seen one month after

injection therapy and a decrease in fullness was seen at three months. However, fullness of the right vocal fold did not change after three months, and the same extent of fullness remained at 6, 12, and 24 months after surgery.

### DISCUSSION

In this study, we performed quantitative CT assessment of the short- and long-term outcomes of autologous fat injection augmentation in patients with UVFP. This is the first report to assess immediate CT imaging data after fat injection and the sequential changes in the injected fat volume over a long follow-up period. Several authors have reported on the treatment and volume of injected autologous fat; however, no studies have reported the relationship between the actual injected fat volume and immediate quantitative assessment. To evaluate the residual rate of the injected fat over a long-term follow-up, it is essential to collect immediate quantitative CT image data. Our results indicate that the injected fat volume decreases rapidly within the first several days after insertion. We found that the average residual rate of the injected fat was 63.9% when assessed by CT two days after surgery. There are several possible reasons for the early decrease in the injected fat volume two days after surgery. First, the early decrease in the injected fat volume may be caused by leakage of some fat tissue from the vocal fold through the insertion site. Second, the pressure around the fat tissue in the syringe before surgery (at barometric pressure) and the fat tissue in the vocal fold just after injection may have differed. Although it is difficult to assess the pressure around the fat tissue in the vocal fold accurately, it is possible that this difference in the pressures around the

TABLE I.  
Clinical Characteristics of 12 Patients with Unilateral Vocal Fold Paralysis

Fat volume as assessed by CT follow-up period

Patient	Age(years)	Sex	BMI(kg/m <sup>2</sup> )	Injected Fat volume (ml)	Residual rate (%)	2 days		3 months		6 months		12 months		18 months		24 months	
						HU		Residual rate (%)		Residual rate (%)		Residual rate (%)		Residual rate (%)		Residual rate (%)	
						mean	SD	mean	SD	mean	SD	mean	SD	mean	SD	mean	SD
1	77	M	21.1	1.2	-	-	-	-	46.3	-	44.4	46.7	55.4	55.2	-	-	
2	65	F	18.8	2.5	43.0	-	-62	37	17.3	-	-	17.3	-	16.0	-	-	
3	46	F	24.1	1.2	-	-	-	-	15.6	-	-	16.9	-	16.5	-	-	
4	65	F	20.3	1.1	-	-	-	-	35.7	-	-	35.5	-	35.0	-	-	
5	46	M	26.2	2.0	33.0	-	-48	31	-	-	43.1	-	48.8	-	-	-	
6	52	M	26.2	2.2	63.3	-	-69	32	36.5	-	41.5	-	-	37.2	-	-	
7	55	F	23.1	1.1	60.7	-	-37	44	-	-	-	31.1	-	-	-	-	
8	78	M	21.6	1.5	-	-	-49	-	26.2	-	25.5	27.8	-	-	-	-	
9	66	M	27.1	2.0	63.0	-	-	32	-	-	-	-	-	-	-	-	
10	67	F	20.9	1.0	-	-	-	-	-	-	14.0	-	-	-	-	-	
11	82	F	23.4	1.5	91.5	-	-66	41	-	-	-	-	-	-	-	-	
12	56	M	18.3	2.0	73.1	-	-59	43	32.1	-	-	-	-	-	-	-	
Mean	62.9		22.6	1.6	63.9	-	-56	37	30.0	-	33.7	29.2	52.1	32.0	-	-	

BMI = body mass index; CT = computed tomography; HU = Hounsfield units; SD = standard deviation.



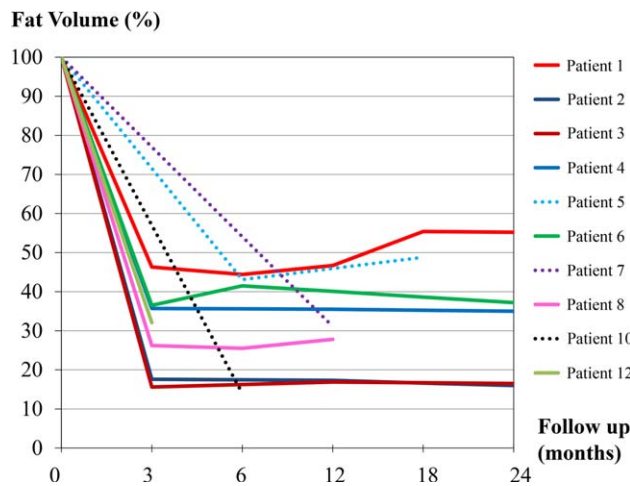


Fig. 2. Changes in the injected fat volume during the long follow-up period in 10 patients.

fat tissue before and after the injection may have caused or contributed to the decrease in fat volume in the vocal fold. Third, the autologous fat harvested before the injection was aqueous, and some moisture in the fat tissue may have been absorbed two days after surgery. The acute decrease in the residual rate of injected fat two days after surgery may reflect changes caused by leakage, pressure, and moisture content. By contrast, continuous degradation of the injected fat volume may be slower than that observed soon after injection. We performed serial CT assessment during the follow-up period and found that the mean residual rates of the injected fat were 30.0% at 3 months, 33.7% at 6 months, 29.2% at 12 months, and 32.0% at 24 months. Although both

the quantitative CT assessment and clinical observations using direct flexible laryngoscopy showed that the injected fat volume decreased within the first 3 months, the residual fat volume was maintained at the same level from 3 to 24 months after injection.

Grafts from lean individuals remain bulkier than those from obese individuals.<sup>11</sup> Sato et al. reported that the cell size and density of liposuctioned autologous fat can differ between individuals and that the diameter of fat cells correlates with BMI.<sup>12</sup> However, preoperative BMI was not predictive of residual fat volume in our study, possibly because only 12 patients were included in this analysis, because we didn't have a broad enough range of BMI to capture differences or because the volume of injected fat in the vocal fold was smaller than in other areas, such as the breast or the facial area. BMI generally reflects the quantity of fat tissue throughout the body, but we did not collect data on BMI at each time point. Therefore, it is unclear whether changes in BMI over time predicted the changes in fat volume over time. Future studies should measure BMI at each time point to determine whether it is related to the amount of fat in the vocal fold in the follow-up period.

In the clinical setting, direct flexible laryngoscopy and stroboscopy are the most useful ways to check the condition of the vocal folds and are performed routinely in clinical settings. Several imaging modalities, such as CT and magnetic resonance imaging (MRI), can be used to evaluate the volume of injected fat for research rather than clinical purposes. MRI is the method of choice for assessing the injected fat volume because of its ability to identify fatty tissue, and it is used to measure fat survivability and longevity in the breast and facial areas. Kruschewsky et al. performed an animal study to

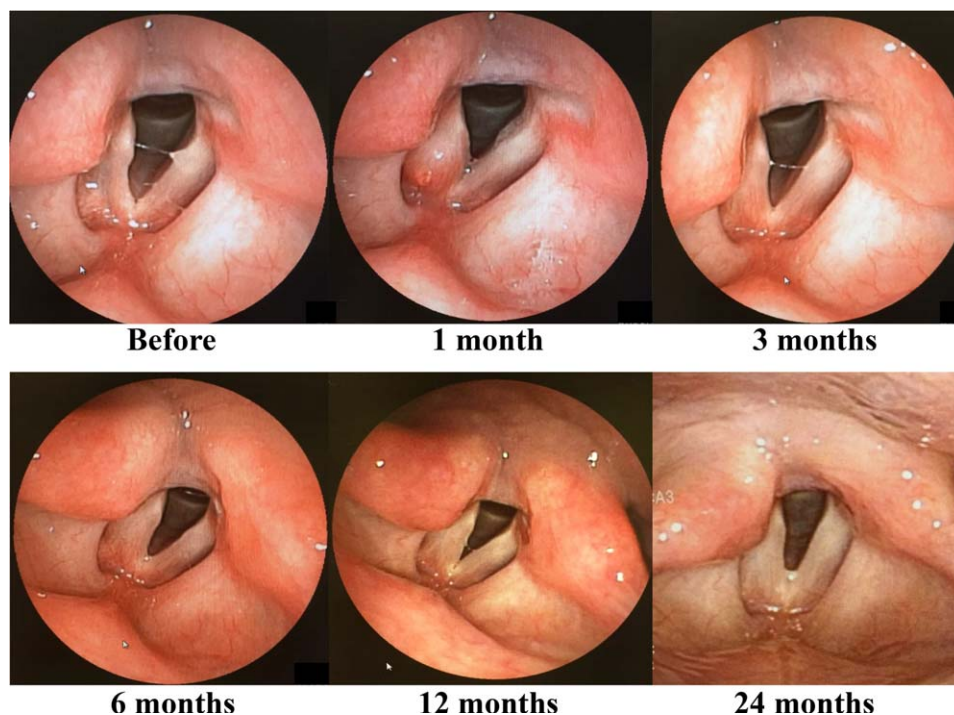


Fig. 3. Images of the view through the direct flexible laryngoscopy for patient 3 with right vocal fold paralysis. Fullness of the right vocal fold was seen at 1 month after injection therapy, and a decrease in the fullness of the right vocal fold was seen at 3 months. The fullness of the vocal fold was maintained after 3 months as observed at 6, 12, and 24 months after surgery.

determine the residual rate of autologous fat grafts in 24 paralyzed canine left vocal folds 12 weeks after the grafts and reported a residual rate of 18%.<sup>13</sup> Hörnl et al. reported that MRI provided an objective evaluation of volume loss with an average error of only 5% and residual rates of fat injection into facial defects of 51% at 3 months and 45% at 6, 9, and 12 months.<sup>14</sup> When assessing the accuracy of the measurement of the injected fat volume, a CT scan is also suitable for assessing the long-term viability of fat grafts.<sup>15</sup> Fang et al. identified the long-term residual fat volume by 3-D CT in 28 consecutive patients with UVFP and reported that the mean residual fat volume remained consistent ( $0.39 \pm 0.35$  mL; range, 0.01–1.6 mL).<sup>5</sup> However, they did not identify the point at which the injected fat volume stabilized at 3 months or at another time because the interval from fat injection to image evaluation was longer than 12 months. Tamura et al. studied the injection of buccal fat and reported rate of residual fat in tissue was  $19.8\% \pm 13.4\%$  of the injected quantity at  $7.7 \pm 8.1$  months after injection.<sup>9</sup> We analyzed the CT image data immediately after fat injection and the sequential changes in injected fat volume over long follow-up periods. This allowed us to differentiate the acute changes in the residual rate of the injected fat after surgery and to analyze precisely the continuous absorption rate over a long-term period. We performed routine CT scans, including of the neck, to check the condition of primary disease, such as thyroid cancer and esophageal cancer. Although MRI is a good imaging modality for fat assessment because it involves no radiation exposure, in patients with UVFP who undergo several follow-up CT scans to check for the recurrence of cancer or regrowth of an aneurysm, it is important that the assessment use the same diagnostic modality. In this study, we performed repeated CT assessment to compare the pre- and postoperative conditions.

When using quantitative image assessment of fat injection therapy, it is unclear whether the segmented region shown in the CT or MRI images reflects the actual residual fat. We used the HU for the injected fat to verify whether the injected fat volume calculated from CT images reflected the actual residual fat tissue. To provide a basis for evaluating the changes in HU of the injected fat over the long-term follow-up, we analyzed CT images two days after surgery in seven patients and used the HU to confirm the accuracy of our CT analysis. Ahmadi et al. reported that CT can accurately and quantitatively detect adipose tissue based on the CT HU threshold, which is  $-10$  to  $-190$  HU for adipose tissue.<sup>16</sup> Although the mean HU of the injected fat after injection augmentation has not been reported, Tamura et al. used a predefined range of  $-10$  to  $-50$  HU to identify pixels corresponding to fat tissue in the vocal fold.<sup>9</sup> The HU of the injected fat calculated from CT images ranged from  $-69$  to  $-37$  HU (mean value,  $-56$  HU) in this study and was within the range of HU for adipose tissue. For the volume estimation, although the measurements were performed by two head and neck surgeons, who were knowledgeable about fat injection therapy, our process of measuring the injected fat seems like a step that could

introduce bias. However, considering the HU in the CT images in our study, we believe that the injected fat volume calculated from CT images provided a valid measure of the actual residual fat tissue. Moreover, the high ICCs for intraobserver repeatability and reproducibility for the two observers indicated satisfactory stability of our process of measuring the injected fat.

Long-term graft absorption is inevitable and unpredictable. Adipose-derived stem cells (ASCs) have attracted recent attention and have been used in animal experiments to control the absorption of autologous fat injections. Several studies of autologous fat transplantation with ASCs have shown improvements in the residual rate and quality of transplanted fat tissue.<sup>17–20</sup> This high concentration of ASCs added to autologous fat injection therapy may improve treatment outcomes for patients with UVFP and is expected to be applied to clinical applications.

This study has several limitations. First, this was a retrospective study performed at a single institution with a small number of patients and the follow-up protocol for CT evaluation was not identical in all patients. The results need to be corroborated in a larger study population. Second, the fact that the amount of injected fat appeared to increase in some patients over time points toward a degree of inaccuracy in our means of measuring the injected fat volume from CT images. Third, we assessed only the images to determine the injected fat volume in the follow-up period. Because most pre- and postoperative voice data were not recorded, the voice outcomes, such as those measured using the grade, roughness, breathiness, asthenia, strain scale, and Voice Handicap Index, were not evaluated in detail in this study. Therefore, further studies are needed to determine the relationship between the injected fat volume and phonation.

## CONCLUSION

The injected fat volume decreased within the first three months and the residual rate of the injected fat was 30.0% at three months after injection. After 3 months, however, the residual fat volume remained at the same level for up to 24 months after injection.

## BIBLIOGRAPHY

1. Cohen SM, Dupont WD, Courey MS. Quality-of-life impact of non-neoplastic voice disorders: a meta-analysis. *Ann Otol Rhinol Laryngol* 2006;115(2):128–134.
2. Fang TJ, Li HY, Gliklich RE, Chen YH, Wang PC, Chuang HF. Quality of life measures and predictors for adults with unilateral vocal cord paralysis. *Laryngoscope* 2008;118(10):1837–1841.
3. McCulloch TM, Andrews BT, Hoffman HT, Graham SM, Karnell MP, Minnick C. Long-term follow-up of fat injection augmentation for unilateral vocal cord paralysis. *Laryngoscope* 2002;112(7):1235–1238.
4. Friedman AD, Burns JA, Heaton JT, Zeitels SM. Early versus late injection medialization for unilateral vocal cord paralysis. *Laryngoscope* 2010;120(10):2042–2046.
5. Fang TJ, Lee LA, Wang CJ, Li HY, Chiang HC. Intracordal fat assessment by 3-dimensional imaging after autologous fat injection in patients with thyroidectomy-induced unilateral vocal cord paralysis. *Surgery* 2009;146(1):82–87.
6. Wang W, Chen D, Chen S, et al. Laryngeal reinnervation using ansa cervicalis for thyroid surgery-related unilateral vocal fold paralysis: a long-term outcome analysis of 237 cases. *PLoS One* 2011;6(4):e19128.
7. Bruennings W. Über eine neue behandlungsmethode der rekurrenzlahmung. *Ver Deutsch Laryng* 1911;18:93–151.

8. Mikaelian DO, Lowry LD, Sataloff RT. Lipoinjection for unilateral vocal cord paralysis. *Laryngoscope* 1991;101(5):465–468.
9. Tamura E, Tabata Y, Yamada C, Okada S, Iida M. Autologous fat augmentation of the vocal fold with basic fibroblast growth factor: computed tomographic assessment of fat tissue survival after augmentation. *Acta Otolaryngol* 2015;135(11):1163–1167.
10. Isshiki N, Tanabe M, Sawada M. Arytenoid adduction for unilateral vocal cord paralysis. *Arch Otolaryngol* 1978;104(10):555–558.
11. Billings E, May JW. Historical review and present status of free fat graft autotransplantation in plastic and reconstructive surgery. *Plast Reconstr Surg* 1989;83(2):368–381.
12. Sato K, Umeno H, Nakashima T. Histological investigation of liposuctioned fat for injection augmentation. *Am J Otolaryngol* 2005;26(4):219–225.
13. Kruschewsky Lde S, de Mello-Filho FV, dos Santos AC, Rosen CA. Autologous fat graft absorption in unilateral paralyzed canine vocal folds. *Laryngoscope* 2007;117(1):96–100.
14. Hörnl HW, Feller AM, Biemer E. Technique for liposuction fat reimplantation and long-term volume evaluation by magnetic resonance imaging. *Ann Plast Surg* 1991;26(3):248–258.
15. Fontdevila J, Serra-Renom JM, Raigosa M, et al. Assessing the long-term viability of facial fat grafts: an objective measure using computed tomography. *Aesthet Surg J* 2008;28(4):380–386.
16. Ahmadi N, Hajsadeghi F, Conneely M, et al. Accurate detection of metabolically active “brown” and “white” adipose tissues with computed tomography. *Acad Radiol* 2013;20(11):1443–1447.
17. Lu F, Li J, Gao J, et al. Improvement of the survival of human autologous fat transplantation by using VEGF-transfected adipose-derived stem cells. *Plast Reconstr Surg* 2009;124(5):1437–1446.
18. Zhu M, Zhou Z, Chen Y, et al. Supplementation of fat grafts with adipose-derived regenerative cells improves long-term graft retention. *Ann Plast Surg* 2010;64(1):222–228.
19. Chang L, Wang J, Zheng D, et al. Improvement of the survival of autologous free-fat transplants in rats using vascular endothelial growth factor 165-transfected bone mesenchymal stem cells. *Ann Plast Surg* 2014;72(3):355–362.
20. Nishio N, Fujimoto Y, Suga K, et al. Autologous fat injection therapy including a high concentration of adipose-derived regenerative cells in a vocal fold paralysis model: animal pilot study. *J Laryngol Otol* 2016;130(10):914–922.