

Interhemispheric transcallosal transforaminal approach and its variants to colloid cyst of third ventricle: Technical issues based on a single institutional experience of 297 cases

Suresh Nair, C. V. Gopalakrishnan, Girish Menon, H. V. Easwer, Mathew Abraham

Department of Neurosurgery, Sree Chitra Tirunal Institute for Medical Sciences and Technology, Trivandrum, Kerala, India

ABSTRACT

Context: Colloid cysts are benign intracranial lesions that usually involve the anterior third ventricle with varying appearance on imaging studies. The number of articles debating the origin of this tumor is surpassed by papers proposing the best modality available for its treatment

Aim: The purpose of this study is to analyze the clinical presentation and surgical outcome of colloid cysts surgically managed over a period of thirty-two years and evaluate the technical issues based on our experience.

Study Design: This is a retrospective case series study.

Materials and Methods: This is a retrospective case series study on 297 consecutive patients with colloid cysts who were operated. The case records of all the patients were evaluated to record the clinical symptoms and signs, imaging findings, surgical procedure, complications and follow-up data.

Results: There were 178 (60%) males and 119 (40%) females, their age ranging from 9 to 66 years with a mean age of 28 years. The mean duration of symptoms was 1.8 months. Raised intracranial pressure headache was the most common initial presenting symptom followed by visual blurring, memory disturbance and drop attacks with gait unsteadiness. The tumor was an incidental imaging finding in five patients (2%). While an interhemispheric transcallosal approach was used in 275 (92.6%) patients, it was trans-cortical in 22 (7.4%). Twenty-two patients required emergency surgery in view of worsening sensorium. Postoperative complications included memory impairment, limb weakness and seizures. Despite documented complete excision of the tumor in 6 cases, 8 patients had recurrence of tumor during follow-up.

Conclusion: Colloid cysts are potential life threatening but benign lesions that can be removed safely with low morbidity and mortality through the interhemispheric transcallosal approach and its variants. The possibility for recurrence warrants, close imaging follow-up after surgery. It is essential for neurosurgeons to be familiar with the different transcallosal approaches to reach the third ventricle especially for a posteriorly situated cyst and a narrow foramen of Munro.

Key words: Colloid cyst, hydrocephalus, intraventricular tumor, transcallosal surgery

Access this article online

Quick Response Code:



Website:

www.asianjns.org

DOI:

10.4103/1793-5482.144185

Address for correspondence:

Dr. Suresh Nair, Professor and Head, Department of Neurosurgery, SCTIMST, Trivandrum - 695 011, Kerala, India.
E-mail: snair1952@yahoo.com

Introduction

Colloid cysts are benign lesions that almost always are located in the third ventricle. They represent 0.3 to 2% of all brain tumors^[1] and are presumed to be endodermal in origin.^[2] They typically present with raised intracranial pressure (ICP) headache caused by obstructive hydrocephalus. Acute neurological deterioration secondary to ventricular obstruction may lead to sudden death. Despite our increasing awareness of the natural history of colloid cysts, we do not know the actual risk of acute neurological deterioration.^[3] With the advent of routine imaging in patients with headache as their

presenting symptom, a significant number of colloid cysts are being diagnosed incidentally. Management of asymptomatic colloid cysts has always been a subject of controversy.

In this article we report a retrospective study of patients with colloid cysts operated in one single institution spanning the period from January 1980 to December 2011. The study re-evaluates the neuroimaging characteristics of symptomatic and asymptomatic patients with colloid cysts and their role in deciding the management strategy. The technical issues of the classic interhemispheric transcallosal transforaminal approach and its variants have been revisited along with the role of neuroendoscopy in the present era.

Materials and Methods

The medical records of all patients with colloid cysts who underwent surgery at our institute between January 1980 and December 2011 were retrospectively reviewed. Two hundred and ninety-seven patients with colloid cysts were identified. Using a standardized data sheet, clinical, radiological and surgical data were collected from medical records. Preoperative and postoperative MRI and/or CT images were reviewed to ascertain the imaging diagnosis and determine the extent of tumor resection. Descriptive statistics were used to summarize the patients' demographic and clinical characteristics.

Results

There were 178 (60%) males and 119 (40%) females, their age ranging from 9 to 66 years with a mean age of 28 years. The duration of symptoms at the time of presentation varied from 7 days to 36 months with a mean of 1.8 months. While headache due to raised ICP was the initial symptom occurring in 228 (74%) patients, there was intermittent poorly defined headache in 24 (7.6%). Other initial symptoms included visual blurring in 22 (7%), memory disturbances in 17 (5.3%) and drop attacks with gait disturbances in 9 (3.4%). In five patients (2%) the cyst was discovered incidentally. Two patients were admitted in a comatose stage [Table 1].

In two patients, admitted prior to availability of CT scanner in our institute, diagnosis was made by ventriculogram. CT and/or MRI were the diagnostic modality in the rest. The cyst on CT imaging demonstrated varying characteristics, being hyperdense in 71%, isodense in 26% and hypodense in 3% of the cases. In patients who underwent MRI, the cyst characteristics on T2-weighted images were compared. 66% of the cysts were hyperintense, 25% were hypointense and 19% were isointense on T2-weighted imaging. The various operative procedures undertaken are listed in Table 2. Twenty-two of the 297 patients underwent emergency surgery immediately after admission in view of deterioration in sensorium. While an interhemispheric transcallosal approach was used in 275, it was trans-cortical in 22 (endoscope assisted in six and endoscopically in two).

Twenty-eight patients had a CSF diversion procedure either prior to or following tumor resection [Table 3]. While 14 of these patients were referred to us from local hospitals following a shunt surgery, the other 14 required a post-operative CSF diversion procedure in the form of either ventriculoperitoneal (VP) shunt or endoscopic third ventriculostomy (ETV) due to persisting symptomatic hydrocephalus. There was an operative mortality of 1% (3 patients). Major postoperative complications [Table 4] included hemiplegia due to venous infarction in nine cases (4%) and seizures in 12 (5%). Of the 12 patients who had postoperative seizures, three had undergone surgery via the transcortical (transfrontal) route. While post-operative seizure incidence was 3% (9/275) for the patients operated by

Table 1: Patient symptomatology

Symptoms	Number of patients (%)
Raised ICP headache	228 (74)
Intermittent vague headache	24 (7.6)
Visual disturbance	22 (7)
Memory disturbance	17 (5.3)
Drop attacks	9 (3.4)
Incidental	5 (2)
Coma	2 (0.76)

ICP – intracranial pressure

Table 2: Surgical approaches

Approaches	Number of patients (%)
Transcortical	22 (7.5)
Interhemispheric	275 (92.5)
Transforaminal	226 (82)
Interforniceal	24 (10)
Subchoroidal	14 (5.8)
Suprachoroidal	07 (2.2)

Table 3: Patients who underwent CSF diversion

CSF diversion	Number of patients
Pre-op shunt (all referred)	14
Post-op diversion	14
Endoscopic foraminoplasty	2
Third ventriculostomy	1
VP shunt	11
Total	28

CSF – Cerebrospinal fluid; VP – Ventriculoperitoneal

Table 4: Post-operative complications

Complications	Number of patients (%)
Hemiplegia	9 (4)
Seizures	12 (5)
Mortality	3 (1.1)
Fungal meningitis	1 (0.5)
CSF Rhinorrhea	1 (0.5)

CSF – Cerebrospinal fluid

the transcallosal route, it was 14% for those who underwent surgery transcortically ($P = 0.049$). There was symptomatic recurrence in eight (3%) patients and all underwent revision surgery. The mean time to recurrence was 10.2 years. As per the operative records, six out of the eight patients had their tumor completely excised during the first surgery.

Discussion

To our knowledge, we present one of the largest series on third ventricular colloid cysts. These lesions have long intrigued neurosurgeons. Although patients with colloid cysts generally present after developing acute hydrocephalus, little information is available on the natural history of these tumors. The widespread use of CT and MRI for patients presenting with headache has resulted in the diagnosis of more patients with colloid cysts even prior to development of hydrocephalus. Moreover, there has been an increase in the diagnosis of incidental or asymptomatic colloid cysts. The theory proposed by Pollock *et al.*^[4] on the natural history of third ventricular colloid cysts is based on the interaction of three primary factors which include rate of cyst growth, progression of CSF obstruction and cessation of growth as age advances.

Imaging studies, both CT and MRI, can demonstrate varying characteristics of the cyst depending on its contents. An earlier unpublished study from our institute on the CT characteristics of 174 colloid cysts, showed the cyst to be hyperdense in 69%, isodense in 28% and hypodense in 4%. The density of the cyst probably depends on the cholesterol content within the cyst.^[5] There have been reports of changing CT characteristics following CSF diversion.^[6] Colloid cysts have varying signal intensity on various MRI sequences. Shorter duration of symptoms is often associated with hyperintense lesions on T2-weighted MR images.

The management of incidental or asymptomatic colloid cysts is a topic of debate. Decision to recommend observation or surgery in these cases is often unclear. Guidelines which can help neurosurgeons in assessing the potential risk of cyst enlargement have been published by Pollock *et al.*^[4] Older patients with small colloid cysts that are hypointense on T2-weighted MR images without any ventriculomegaly, usually remain asymptomatic. In contrast, younger patients who have large colloid cysts that are hyperintense on T2-weighted MRI scans with obstructive hydrocephalus tend to be symptomatic and require early surgery.

Surgical techniques

The treatment of colloid cysts has evolved rapidly since the first successful excision of a colloid cyst via the transcortical transventricular approach by Walter Dandy in 1921.^[7] This was followed closely by a transcallosal approach by Greenwood in 1949.^[8] Since then techniques like stereotactic aspiration^[9] and endoscopic^[10,11] removal of colloid cysts came into

practice. Isolated aspiration of the cyst by stereotactic or ventriculoscopic methods may minimize the surgical risk, but fails to offer a radical or permanent treatment of these benign lesions in view of the high viscosity of cyst contents. The use of microneurosurgical techniques has revolutionized the treatment and outcome of colloid cyst surgery. With wide spread use of the operating microscope since the 1980s in our institute, the interhemispheric transcallosal approach became the standard treatment for colloid cysts.^[12] Open surgical removal of colloid cyst is the gold standard treatment and is the only method at present, which can remove the cyst in totality and ensure definitive cure of this benign tumor.

The transcortical transventricular approach can be performed using stereotactic guidance to minimize brain damage, but carries the risk of postoperative seizures. This approach sometimes may be difficult in patients with small ventricles. Twenty-two patients in our series were operated using this approach. The anterior transcallosal approach usually provides a direct and adequate pathway to the lateral ventricles, where the foramen of Monro serves as a natural entrance into the third ventricle, especially when the foramen of Monro is dilated by the cyst. The greatest advantage of the transcallosal approach is that it avoids cortical incision and provides natural planes for dissection to the anterior part of the third ventricle. Also this approach provides many options to reach the third ventricle following entry into the lateral ventricle.

The simplest and safest way is to attempt excision of the lesion through the dilated foramen of Monro^[13] (transforaminal route) which was the most common approach in our series (76%; [Figure 1]). Colloid cysts are most commonly located in the anterior two-thirds of the third ventricle and expand the foramen of Monro in 80% of the cases.^[13] Therefore, dilatation of the foramen of Monro to a diameter of 5 to 15 mm usually allows piecemeal, complete removal of the colloid cyst without any damage to the neural and vascular structures in the vicinity.

Lesion located more posteriorly and superiorly in the third ventricle does not present itself at the foramen of Monro, and often occludes and diverges the foramen. In such cases, the trajectory should be dictated by the surgical anatomy rather than by a fixed approach. Three potential corridors of entry are possible to reach the lesion. When the lesion bulges superiorly displacing the fornices laterally, the interforaminal route is the best option.^[14] The septum is used as a guide to the interval between the fornices and into the third ventricle. Extreme care is taken not to damage the fornix. An interforaminal route was used in 24 patients (10%) in our series. When the lesion bulges on to the floor of the lateral ventricle, the subchoroidal approach [Figure 2] through the velum interpositum, lateral to the internal cerebral veins is a good option.^[15] This approach was used in 14 (5.8%) patients. In this approach the velum

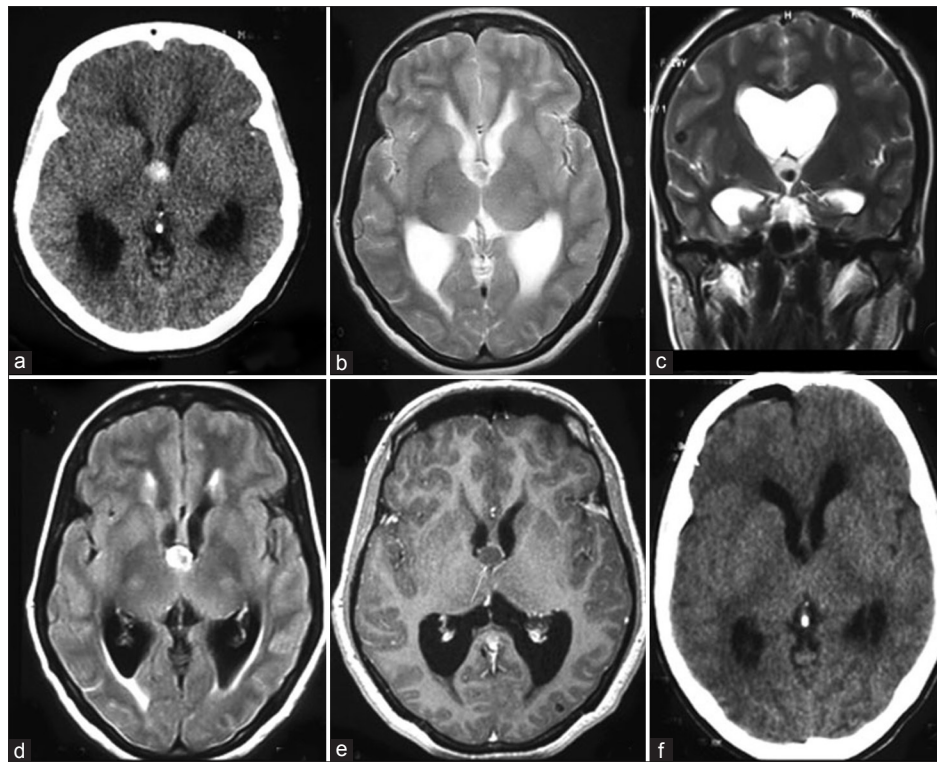


Figure 1: (a) Typical anterior third ventricle colloid cyst expanding the foramen of Munro and causing obstructive hydrocephalus. The preoperative axial CT (b) Shows a hyperdense cyst, appearing isointense with a central area of hypointensity on T2-weighted axial; (c) Coronal; (d) MRI. On axial FLAIR sequence; (e) The lesion is hyperintense with evidence of periventricular CSF seepage. Post-contrast axial T1-weighted MRI; (f) Demonstrates a hypointense cyst without any enhancement. This tumor was operated through a transcallosal transforaminal approach and excised completely as evidenced by the postoperative CT image

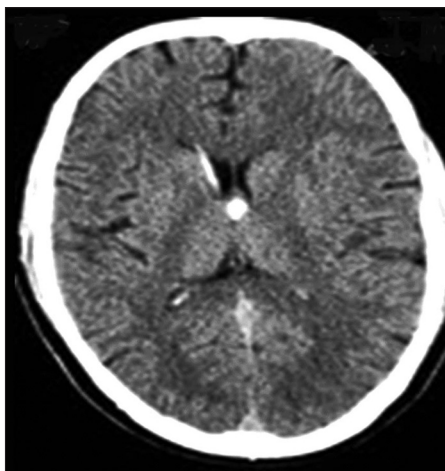


Figure 2: The patient was referred following a right VP shunt at a local hospital for hydrocephalus. The axial CT shows a hyperdense colloid cyst located posterior to the foramen. During surgery the foramen was narrow and the cyst could not be visualized. A subchoroidal approach through the velum interpositum helped in locating and resecting the tumor

is exposed below the choroid plexus and about 5 to 10 mm dorsal to the thalamostriate vein, with the surgeon remaining close to the thalamus and minimal elevation of the plexus. At the point of opening the velum, the internal cerebral vein should not shine through the velum, which can be the case

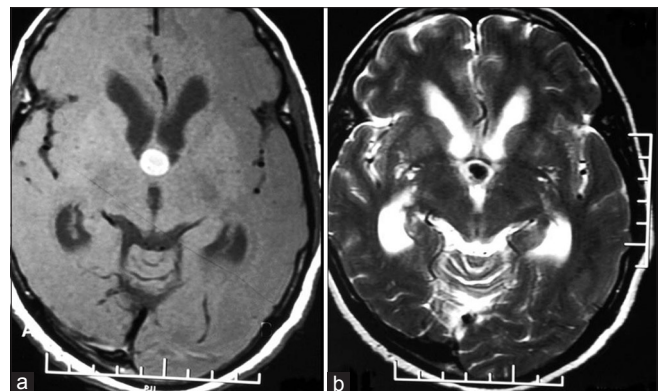


Figure 3: Axial CT (a) and T2-weighted MRI; (b) Large colloid cyst in a young patient with features of obstructive hydrocephalus. Though this tumor was seen at the foramen of Munro, a suprachoroidal approach was required to completely excise the tumor

if the exposure is very close to the thalamostriate vein. The velum can be perforated safely and easily with a curved microdissector, remaining on the surface of the thalamus. After the ventricle is opened laterally and below the internal cerebral veins, the opening can be safely extended posteriorly. Anteriorly, the opening can be extended to a few millimeters posterior to the thalamostriate vein. A good view of the medial and posterior part of the third ventricle can be obtained with

slight retraction of the thalamus laterally and the roof of the ventricle with the internal cerebral veins medially. To observe the anteroinferior portion, the massa intermedia must be retracted posteriorly or dissected. In the third approach via the suprachoroidal route,^[16] the surgeon can displace the choroid plexus down and laterally, and work over the top of plexus and under the fornix into the third ventricle [Figure 3]. After opening the tenia fornices, from the foramen of Monro backwards to the atrium of the lateral ventricle, the superior membrane of the tela choroidea is split and the internal cerebral veins are exposed. The last two layers of the roof of third ventricle, namely the inferior membrane of the tela choroidea and choroid plexus of the third ventricle, are finally opened. In 7 (2.2%) patients the suprachoroidal route was used to excise the tumor.

Complication avoidance

Access to the third ventricle should not be gained by the old technique of dividing one fornix at the foramen of Monro^[17] which can result in memory disturbance particularly if the other fornix has been subject to unrecognized pressure or invasion by the pathological lesion. The use of the transcallosal route in colloid cyst surgery does not result in any serious neurological or psychological consequences.^[18,19] Memory impairment in the postoperative period could be attributable to factors such as damage to fornix or other midline structures, fluid outflow, and hemodynamic disturbances.^[19] Unilateral sacrifice of the thalamostriate vein^[20] can lead to venous infarction of the thalamus. It is important to remember that the normal anatomic relations in this region may be distorted by the presence of tumor. None of the above mentioned approaches, if properly performed, sacrifice any functional neurovascular structures. The variations in the neural and vascular structures can be demonstrated pre-operatively using 3D MRI, magnetic resonance angiography and magnetic resonance venography allowing accurate planning of the surgical procedure. Depending on the location of the anterior septal vein – internal cerebral vein junction, it is possible to gain wide access to the third ventricle, without sacrificing any neural or vascular structures.^[21]

It is not uncommon for the surgeon during transventricular surgery to open into a space filled with CSF without any identifiable anatomic landmarks. This happens if the lateral ventricle has been opened far too anteriorly and in such instances the surgeon should angulate the microscope posteriorly to identify the foramen and the choroid plexus. Injury to small deep veins especially on the contralateral side can occur while pulling the cyst capsule from the roof where it is attached to the tela choroidea.

The transcallosal approach is undoubtedly superior in the presence of normal sized ventricles and is more direct avoiding transgression of cortex. Both the foramen of Monro are equally well exposed and hence, even if the left lateral

ventricle is asymmetrically dilated due to tumor obstructing the left foramen of Monro, a right sided precoronal parasagittal craniotomy will suffice. The transcallosal surgery is especially suitable for masses which present more superiorly and not at the foramen. The interhemispheric approach is also more flexible compared to the transcortical approach. By varying the degree of neck flexion and the angle of microscope, virtually the entire third ventricle can be reached through a limited anterior callosal section. Nevertheless the problems encountered during an interhemispheric transcallosal approach include variable anatomy of the cortical bridging veins, dissection of the pericallosal arteries and the need for callosal sectioning. Even though bridging parasagittal veins may sometimes pose a hindrance, it is usually possible to find a 2 to 3 cm gap between them that is large enough to allow cyst resection. Moreover a small incision in the corpus callosum (1 cm) is usually adequate to excise the cyst.

Even though cyst recurrence is said to be more common after stereotactic aspiration and endoscopic procedures, the fact that 6 patients in our series had a recurrence despite complete excision of the tumor points towards a potential for cyst regrowth. This might be due to microscopic epithelial remnants left behind during initial surgery that retain the ability to regrow. This necessitates continued postoperative clinical and radiological monitoring at progressively longer intervals.

Endoscopic treatment

The use of endoscopy for removing third ventricular colloid cysts has gained popularity in several centers. Neuroendoscopy can be used with sufficient efficacy for the removal of cyst contents and coagulation of the cyst wall. The magnified view provided by the endoscope is particularly well suited for surgery around small delicate structures, such as fornix and deep venous system of the brain. Our experience with endoscopic surgery for colloid cysts is limited. Only eight of the 297 cases had endoscope used during surgery, six of them undergoing endoscopic assisted microsurgery. Our criticism of the endoscopic approach is high incidence of incomplete removal as evidenced by previous literature reports.^[22,23]

Other innovative approaches to colloid cyst include anterior approach through the lamina terminals^[24] and the posterior third ventricle approach by opening the tela choroidea between the pineal and the vein of Galen through a infratentorial supracerebellar approach.^[19]

Conclusion

Open surgery has always been considered the gold standard in the treatment of third ventricular colloid cysts. Endoscopic techniques have evolved over time and are an accepted alternative to microneurosurgery. But the limit of endoscopy is the recognized difficulty in removing the cyst attachment from the roof of the third ventricle thus compromising the radicality

of excision. There is a definite risk of recurrence which continues to be a matter of debate. Our vast experience has led us to believe that these potentially life threatening lesions can be safely removed by the interhemispheric transcallosal transforaminal route and its variants. The possibility for recurrence mandates close clinical and imaging follow-up at progressively longer intervals. The surgeon operating on a colloid cyst should be aware of all the possible approaches to the lesion and should be able to choose the optimal route and develop their personal preferences.

References

- Laidlaw J, Kaye AH. Colloid Cysts. In: Kaye AH, Laws ER Jr (editors): Brain Tumors. New York, Churchill Livingstone; 1995. p.907-19.
- Ho KL, Garcia JH. Colloid cysts of the third ventricle: Ultrastructural features are compatible with endodermal derivation. *Acta Neuropathol (Berl)* 1992;83:605-12.
- de Witt Hamer PC, Versteegen MJ, De Haan RJ, Vandertop WP, Thomeer RT, Mooij JJ, *et al.* High risk of acute deterioration in patients harboring symptomatic colloid cysts of the third ventricle. *J Neurosurg.* 2002;96:1041-5.
- Pollock BE, Schreiner SA, Huston J. A theory on the natural history of colloid cysts of the third ventricle. *Neurosurgery* 2000;46:1077-83.
- Ganti SR, Antunes JL, Louis KM, Hilal SK. Computed tomography in the diagnosis of colloid cysts of the third ventricle. *Radiology* 1981;138:385-91.
- Kachhara R, Das K, Nair S, Gupta AK. Changing characteristics of a colloid cyst of the third ventricle. *Neuroradiology* 1999;41:188-9.
- Dandy WE. Benign tumors of the third ventricle. Diagnosis and Treatment. In: Thomas CC, Editor, Springfield, Baltimore, IL.; 1933.
- Greenwood J Jr. Paraphysial cysts of the third ventricle; with report of eight cases. *J Neurosurg* 1949;6:153-9.
- Bosch DA, Rahn T, Backlund EO. Treatment of colloid cysts of the third ventricle by stereotactic aspiration. *Surg Neurol* 1978;9:15-8.
- Rodziewicz GS, Smith MV, Hodge CJ Jr. Endoscopic colloid cyst surgery. *Neurosurgery* 2000;46:655-62.
- Horn EM, Feiz-Erfan I, Bristol RE, Lekovic GP, Goslar PW, Smith KA, *et al.* Treatment options for third ventricular colloid cysts: Comparison of open microsurgical versus endoscopic resection. *Neurosurgery* 2007;60:613-20.
- Misra BK, Rout D, Padmanabhan J. Transcallosal approach to anterior and mid-third ventricular tumors. A review of 62 cases. *Ann Acad Med Singapore* 1993;22:434-40.
- Symon L, Pell M, Yasargil MG, Sarioglu AC, Adamson TE, Roth P. Surgical techniques in the management of colloid cysts of the third ventricle. *Adv Tech Stand Neurosurg* 1990;17:121-57.
- Apuzzo ML, Chikovani OK, Gott PS, Teng EL, Zee CS, Giannotta SL, *et al.* Transcallosal, interforaminal approaches for lesions affecting the third ventricle: Surgical considerations and consequences. *Neurosurgery* 1982;10:547-54.
- Viale GL, Turtas S. The subchoroidal approach to the third ventricle. *Surg Neurol* 1980;14:71-6.
- Wen HT, Rhoton AL Jr, Oliveira E. Transchoroidal approach to the third ventricle: An anatomic study of the choroidal fissure and its clinical application. *Neurosurgery* 1998;42:1205-19.
- Rhoton AL Jr, Yamamoto I. Operative approaches to the third ventricle. In: Wilkins RH, Rengachary SS, (editors): *Neurosurgery*. 2nd ed, Vol 1. New York, McGraw- Hill; 1996. p. 1435-49.
- Hernesniemi J, Leivo S. Management outcome in third ventricular colloid cysts in a defined population: a series of 40 patients treated mainly by transcallosal microsurgery. *Surg Neurol* 1996;45:2-14.
- Konovalev AN, Pitskhelauri DI. Infratentorial supracerebellar approach to colloid cysts of the third ventricle. *Neurosurgery* 2001;49:1116-23.
- Hirsch JF, Zouanoui A, Renie D, Pierre-Kahn A. A new surgical approach to the third ventricle with interruption of the striothalamic vein. *Acta Neurochir (Wien)* 1979;47:135-47.
- Ture U, Yasargil MG, Al-Mefty O. The transcallosal-transforaminal approach to the third ventricle with regard to the venous variations in this region. *J Neurosurg* 1997;87:706-15.
- Hellwig D, Bauer BL, Schulte M, Gatscher S, Riegel T, Bertalanffy H. Neuroendoscopic treatment for colloid cysts of the third ventricle: The experience of a decade. *Neurosurgery* 2003;52:525-33.
- Horn EM, Feiz-Erfan I, Bristol RE, Lekovic GP, Goslar PW, Smith KA, *et al.* Treatment options for third ventricular colloid cysts: comparison of open microsurgical versus endoscopic resection. *Neurosurgery* 2007;60:613-8.
- Desai KI, Nadkarni TD, Mazumdar DP, Goel AH. Surgical management of colloid cyst of the third ventricle – A study of 105 cases. *Surg Neurol* 2002;57:295-304.

How to cite this article: Nair S, Gopalakrishnan CV, Menon G, Easwer HV, Abraham M. Interhemispheric transcallosal transforaminal approach and its variants to colloid cyst of third ventricle: Technical issues based on a single institutional experience of 297 cases. *Asian J Neurosurg* 2016;11:292-7.

Source of Support: Nil, **Conflict of Interest:** None declared.