

Fluctuation of Hepatic Focal Nodular Hyperplasia Size with Oral Contraceptives Use

Authors' Contribution:
Study Design A
Data Collection B
Statistical Analysis C
Data Interpretation D
Manuscript Preparation E
Literature Search F
Funds Collection G

1,2 ABD **Susumu Fukahori**
1,3 BDE **Tetsuya Kawano**
1 CDEF **Yasushi Obase**
1,2 B **Yasuhiro Umeyama**
1,2 D **Nanae Sugasaki**
1,2 ABF **Akitoshi Kinoshita**
1 BF **Chizu Fukushima**
4 BCDF **Masaki Yamakawa**
5 ACD **Katsuhisa Omagari**
1 CDF **Hiroshi Mukae**

1 Department of Respiratory Medicine, Nagasaki University Graduate School of Biomedical Sciences, Nagasaki City, Nagasaki, Japan
2 Department of Internal Medicine, Nagasaki Prefecture Shimabara Hospital, Shimabara, Nagasaki, Japan
3 Smoking Control Center, Nagasaki University Hospital, Nagasaki City, Nagasaki, Japan
4 Department of Internal Medicine, Nagasaki National Hospital, Nagasaki City, Nagasaki, Japan
5 Department of Nutritional Science, Faculty of Nursing and Nutrition, Siebold Campus, University of Nagasaki, Nagasaki City, Nagasaki, Japan

Corresponding Author: Yasushi Obase, e-mail: obaseya@nagasaki-u.ac.jp
Conflict of interest: None declared

Patient: Female, 44
Final Diagnosis: Focal nodular hyperplasia
Symptoms: Liver masses
Medication: —
Clinical Procedure: CT • MRI • Pathology
Specialty: General and Internal Medicine





Objective: Rare disease
Background: Focal nodular hyperplasia (FNH) of the liver is a rare benign nodular lesion that arises in women of reproductive age. Although a role of female hormones has been suggested, their influence on the course of FNH has remained controversial.

Case Report: A 44-year-old woman with a 12-year history of oral contraceptive use was referred to our hospital for examination of an asymptomatic liver mass (3 cm in diameter) identified by computed tomography. We diagnosed FNH using imaging methods and fine-needle biopsy. Oral contraceptives were discontinued because the mass increased over a period of 21 months. Four months later, the mass had decreased in size, indicating that FNH can spontaneously regress when oral contraceptives are discontinued.

Conclusions: Discontinuation of oral contraceptives use can reduce the size of FNH, as in this case.

MeSH Keywords: Contraceptives, Oral, Hormonal • Focal Nodular Hyperplasia • Gonadal Steroid Hormones

Full-text PDF: <https://www.amjcaserep.com/abstract/index/idArt/916398>

 748  —  5  14



Background

Focal nodular hyperplasia (FNH) of the liver is a rare benign hepatic nodular lesion common in women in reproductive age [1–4]. Although the etiology of FNH is not fully understood, the histopathological findings might be related to an underlying developmental abnormality with a hyperplastic response of liver parenchyma and disorganized hepatocyte and duct growth due to a localized increase in arterial blood flow produced by an extant vascular abnormality [1,5]. The influence of female hormones on the growth and complications of FNH has remained controversial. Female hormone predominance has been suggested to have a crucial role of this disease, because

the age of onset of FNH is relatively young, and 50–75% of women with FNH are oral contraceptive (OC) users [1,2,5–9]. The effect of discontinuation of OC use on the natural history of FNH is still controversial [1–4].

Case Report

A 44-year-old woman with a 6-year history of ulcerative colitis (UC) was referred to our hospital for further examination of a liver mass that was detected by computed tomography (CT) during a routine medical check-up. She had never smoked and had never drunk alcohol. She started to take OC when she was 32 years old. The liver mass had been detected by CT during a routine medical check-up 4 years ago, but she had refused to undergo further examination at that time. Physical findings were unremarkable, and laboratory data, including liver function test and tumor markers, were within normal limits. Hepatitis virus markers, including hepatitis B surface antigen and anti-hepatitis C virus antibody, as well as autoantibodies, including antinuclear antibodies and antimitochondrial antibodies, were all negative. Unenhanced CT images showed a low-density mass with a diameter of 2 cm in the right lobe of the liver (segment 5). Dynamic CT revealed intense early contrast enhancement by the mass, without a typical central scar (Figure 1). Unenhanced T2-weighted magnetic resonance imaging (MRI) revealed slightly higher signal intensity in the peripheral portion of the mass (Figure 2). Superparamagnetic iron oxide (SPIO)-enhanced T2-weighted MRI showed a remarkably decreased signal intensity of the mass (Figure 2). Scintigraphy disclosed high liver uptake of Tc-99 m-sulphur

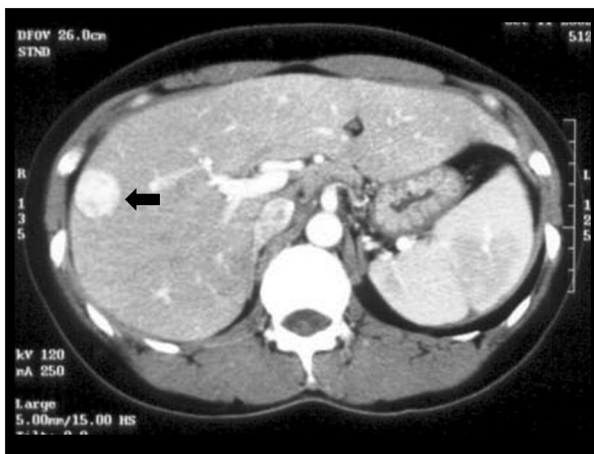

Figure 1. Arterial phase computed tomography (CT) image shows obvious hyper-attenuation of mass with a central scar.

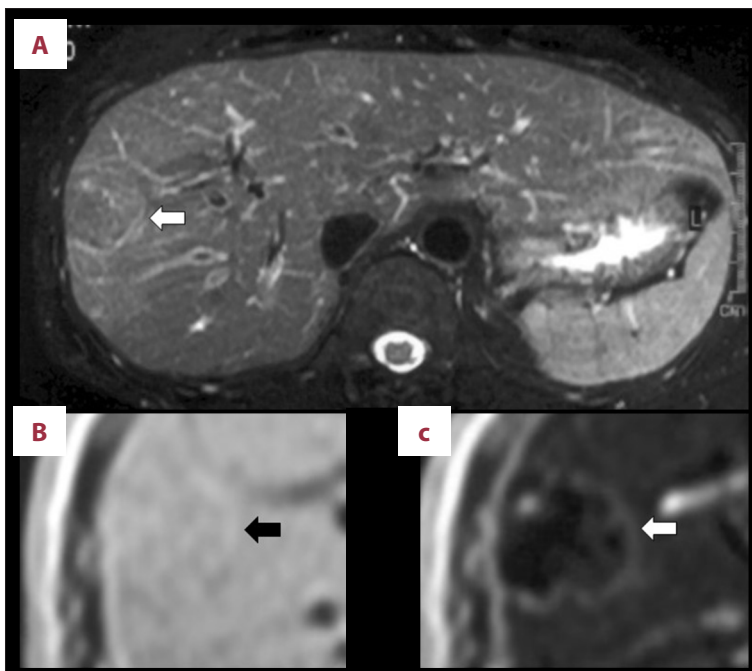


Figure 2. Unenhanced T2-weighted magnetic resonance (MR) image (A) shows slightly elevated signal intensity in peripheral portion of mass. Before (B) and after (C) superparamagnetic iron oxide (SPIO)-enhanced T2-weighted MRI. Signal intensity of mass is obviously decreased.




Figure 3. Tc-99 m-sulphur colloid scintigraphy shows high liver uptake.

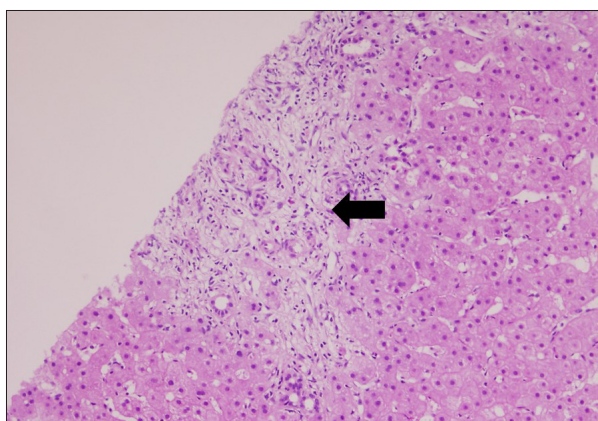


Figure 4. Microphotograph of liver biopsy specimen. Liver tissue is composed of normal hepatocytes and Kupffer cells, but radial arrangement of liver cell trabeculae and lobular architecture are absent. Central scar composed of fibrous tissue, thick-walled artery, and proliferating bile ductules is evident at peripheral portion of specimen. HE staining, $\times 120$.

colloid (Figure 3). An ultrasound-guided needle biopsy specimen showed that the hepatic mass comprised normal hepatocytes, Kupffer cells with a central core composed of fibrous tissue containing a thick-walled artery, and proliferating bile ductules (Figure 4). The imaging and biopsy findings indicated the diagnosis of hepatic FNH. The patient was informed of this diagnosis and consented to undergo conservative follow-up and continued to use OC. After 2 years of follow-up, the diameter of the lesion increased from 2.0 to 3.0 cm on enhanced CT images. Based on the assumption that the FNH was associated with long-term OC use, she stopped taking OC at that time. Four months later, the diameter of the lesion had decreased from 3 to 2.5 cm on enhanced CT images (Figure 5).

Discussion

Observed fluctuation in the size of FNH during the clinical course is extremely rare. Two case reports have described women (one young and one middle-aged) with this phenomenon [10,11]. The FNH mass decreased in our patient after discontinuation of oral contraceptives. Although the precise mechanism of FNH growth is unknown, the change in blood flow to the site of the FNH mass and the impact of female hormones on the site of FNH are thought to be involved in the clinical course. Thrombosis is a classic complication of long-term OC use, and portal vein thrombosis can cause FNH. Portal vein thrombosis caused by OC might have led to a decrease in portal flow to the FNH mass and a compensatory increase in arterial blood flow to the mass, resulting in hemodynamic changes in our patient. Improvements in portal vein thrombosis caused by stopping OC use might have been associated with the decrease in the size of the mass in this patient. Another possibility is that the FNH mass was sensitive to female hormones. Some reports have suggested that high-dose estrogens are associated with enhanced growth and obvious vascular changes in FNH lesions [12,13]. However, another

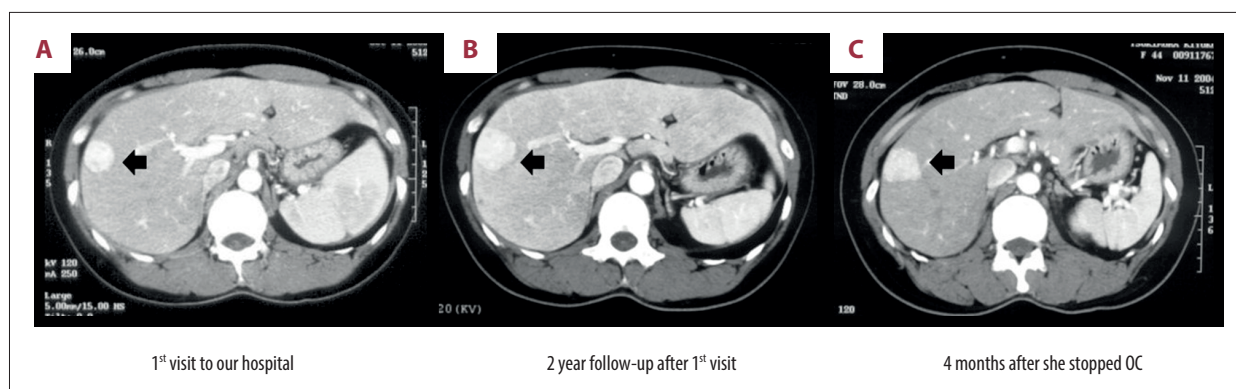


Figure 5. Changes in size of FNH mass during follow-up of this case. Patient continued OC for 2 years after the first visit (A) to our hospital, and OC was stopped 2 years after the first visit (B). The diameter of FNH lesion increased from 2 cm (A) to 3 cm (B). The diameter of the FNH mass decreased from 3 cm (B) to 2.5 cm (C) 4 months after she stopped taking OC.

report refutes any relationship between OC and changes in the size of FNH [14].

Conclusions

In this case, discontinuation of OC use might have reduced the size of the FNH. This case provides additional insight into the pathogenesis of FNH and its relationship with OC.

References:

1. Perrakis A, Vassos N, Grutzmann R, Croner RS: What is changing indications and treatment of focal nodular hyperplasia of the liver. Is there any place for surgery? *Ann Hepatol*, 2017; 16(3): 333–41
2. Torbenson MS: Hamartomas and malformations of the liver. *Semin Diagn Pathol*, 2019; 36(1): 39–47
3. Paradis V, Laurent A, Flejou JF et al: Evidence for the polyclonal nature of focal nodular hyperplasia of the liver by the study of X-chromosome inactivation. *Hepatology*, 1997; 26: 891–95
4. Giannitrapani L, Soresi M, Laspada E et al: Sex hormones and risk of liver tumor. *Ann NY Acad Sci*, 2006; 1089: 228–36
5. Wanless IR, Mawdsley C, Adams R: On the pathogenesis of focal nodular hyperplasia of the liver. *Hepatology*, 1985; 5: 1194–200
6. Cherqui D, Rahmouni A, Charlotte F et al: Management of focal nodular hyperplasia and hepatocellular adenoma in young women: A series of 41 patients with clinical, radiological, and pathological correlations. *Hepatology*, 1995; 22: 1674–81
7. Weimann A, Ringe B, Klempnauer J et al: Benign liver tumors: Differential diagnosis and indications for surgery. *World J Surg*, 1997; 21: 983–90; discussion 990–91
8. Rooks JB, Ory HW, Ishak KG et al: Epidemiology of hepatocellular adenoma. The role of oral contraceptive use. *JAMA*, 1979; 242: 644–48
9. Pain JA, Gimson AE, Williams R et al: Focal nodular hyperplasia of the liver: Results of treatment and options in management. *Gut*, 1991; 32: 524–27
10. Sadowski DC, Lee SS, Wanless IR et al: Progressive type of focal nodule hyperplasia characterized by multiple tumors and recurrence. *Hepatology*, 1995; 21: 970–75
11. Kaji K, Kaneko S, Matsushita E et al: A case of progressive multiple focal nodular hyperplasia with alteration of imaging studies. *Am J Gastroenterol*, 1998; 93: 2568–71
12. Fechner RE: Benign hepatic lesion and orally administered contraceptives. A Report of seven cases and a critical analysis of the literature. *Hum Pathol*, 1977; 8: 255–68
13. Nime F, Pickren JW, Vana J et al: The histology of liver tumors in oral contraceptive users observed during a national survey by the American College of Surgeons Commission on Cancer. *Cancer*, 1979; 44: 1481–89
14. Mathieu D, Kobeiter H, Maison P et al: Oral contraceptive use and focal nodular hyperplasia of the liver. *Gastroenterology*, 2000; 118: 560–64

Department and Institution where work was done

Department of Respiratory Medicine, Nagasaki University Graduate School of Biomedical Sciences, Nagasaki City, Nagasaki, Japan

Conflicts of interest

None.