



Case Report

A case of an elderly female who developed subacute pleuropericarditis following BNT162b2 mRNA COVID-19 vaccination



Tatsuya Mizoguchi (MD), Masashi Yokoi (MD) *, Yasuhiro Shintani (MD), Junki Yamamoto (MD), Kento Mori (MD), Hiroshi Fujita (MD), Tsuyoshi Ito (MD), Tomonori Sugiura (MD), Yoshihiro Seo (MD, FJCC)

Department of Cardiology, Nagoya City University Graduate School of Medical Sciences, Nagoya, Japan

ARTICLE INFO

Article history:

Received 9 February 2022

Received in revised form 9 April 2022

Accepted 30 April 2022

Keywords:

Coronavirus disease 2019

BNT162b2

Pericarditis

Cardiac tamponade

Pleuritis

Case report

ABSTRACT

Despite the established safety of BNT162b2 coronavirus disease 2019 (COVID-19) vaccine, some rare but serious complications have been previously reported. Here, we report a rare case of an elderly female who developed subacute pleuropericarditis after the vaccination. An 88-year-old female experienced weight gain and dyspnea three days after the second dose of BNT162b2 vaccination, and one month later, presented to our hospital due to the exacerbation of the symptoms. Computed tomography showed remarkable pericardial and bilateral pleural effusions, and transthoracic echocardiogram visualized collapse signs of right and left atrium which indicates pre-tamponade. Percutaneous drainages of pericardial and pleural effusions stabilized her vital condition and revealed that all of them were exudative, indicating the presence of pleuropericarditis. Finally, we diagnosed this case as COVID-19 vaccine-associated pleuropericarditis because there were no signs of bacterial/viral infection or any other relevant causes except for the vaccination. When the pericardial and pleural effusions are concurrently found after COVID-19 vaccination, vaccine-associated pleuropericarditis should be considered as a differential diagnosis. The aggressive drainage of pericardial and pleural effusions could be helpful not only for diagnosis but also for treatment in the clinical management of COVID-19 vaccine-associated pleuropericarditis. **Learning objective:** Although the safety and efficacy of BNT162b2 have been widely accepted, it is clinically important to know the potential risk of side effects. When the pericardial and pleural effusions are concurrently found after the vaccination, coronavirus disease 2019 vaccine-associated pleuropericarditis should be considered as a differential diagnosis.

© 2022 Japanese College of Cardiology. Published by Elsevier Ltd. All rights reserved.

Introduction

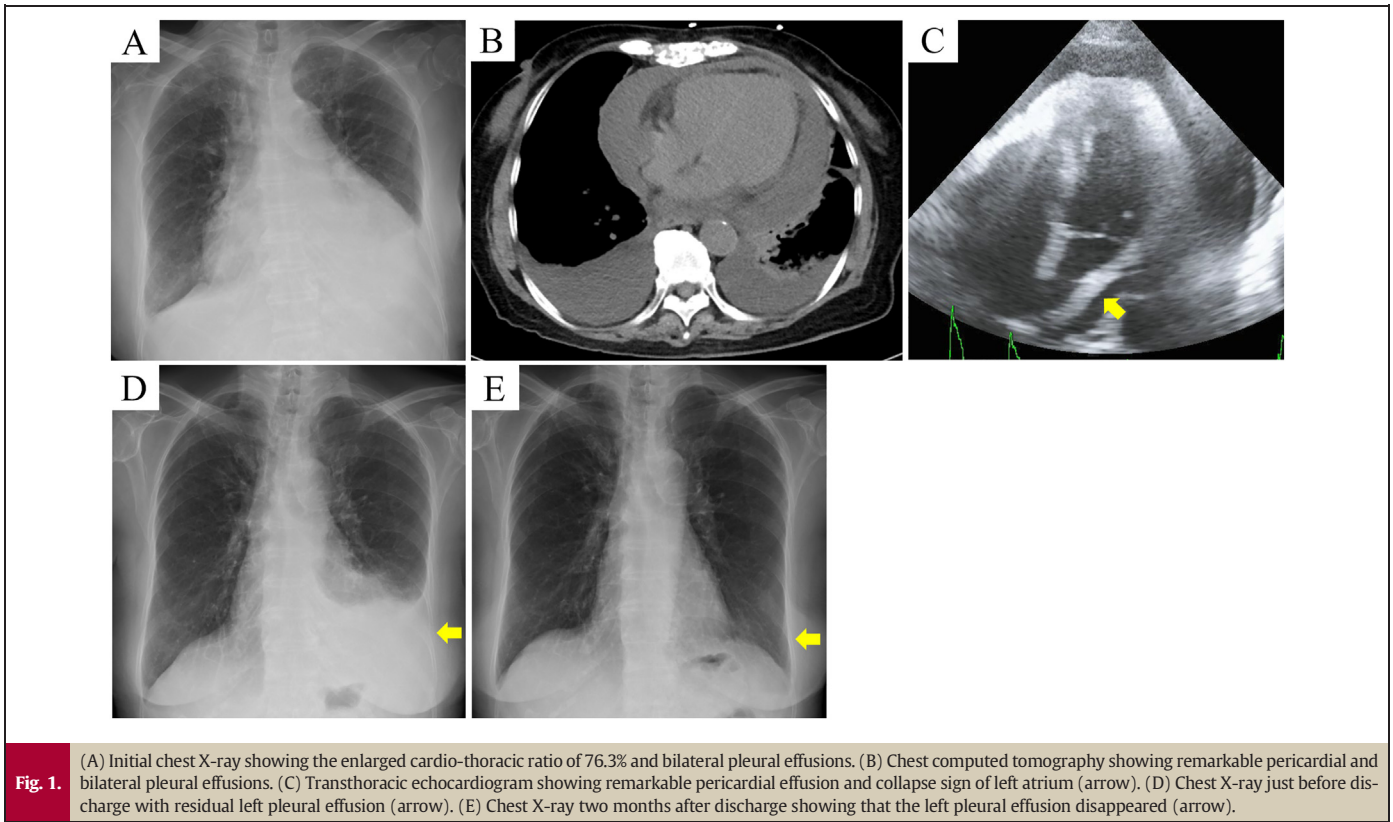
The BNT162b2 mRNA vaccine has been developed to lessen the symptoms, complications, and morbidity associated with coronavirus disease 2019 (COVID-19) [1]. Although the safety and efficacy of BNT162b2 have been widely accepted [2], it is clinically important to know the potential risk of side effects. Myocarditis and pericarditis have been reported as rare but serious complications following BNT162b2 vaccination [3]. However, the concurrent development of pericarditis and bilateral pleuritis, which is known

as pleuropericarditis, after BNT162b2 vaccination has not been reported as far as we know. We herein report a case of an elderly female patient who developed pleuropericarditis following the second dose of BNT162b2 vaccination.

Case report

An 88-year-old Japanese female experienced chest discomfort, dyspnea, and gain of weight three days after the second dose of BNT162b2 vaccination (COMIRNATY®, BioNTech/Pfizer, Mainz, Germany/New York, NY, USA). In the local clinic, although cardiomegaly on chest X-ray and the small amount of pericardial effusion on transthoracic echocardiogram were pointed out, she was observed without any medication. One month later, she was referred to our hospital by the clinic due to the exacerbation of dyspnea. She had no prior history of cardiac disease, pleural disease, hypothyroidism, autoimmune disease, or neoplasm.

* Corresponding author at: Department of Cardiology, Nagoya City University Graduate School of Medical Sciences, 1, Kawasumi, Mizuhocho, Nagoya, Aichi 4678601, Japan.
E-mail address: yokojasmine@gmail.com (M. Yokoi).



Initial vital signs were as follows: a body temperature of 36.3 °C, O₂ saturation of 89% on room air with a respiratory rate of 20 breaths/min, heart rate of 82 beats/min, and blood pressure of 110/60 mm Hg. Physical examination revealed jugular venous distension and bilateral leg edema. The presence of a paradoxical pulse was not apparent, and a pericardial friction rub was not audible. Chest X-ray showed an enlarged

cardio-thoracic ratio of 76% and bilateral pleural effusions (Fig. 1A). Chest computed tomography (CT) scan presented remarkable pericardial and bilateral pleural effusions without any signs of pneumonia, pulmonary tuberculosis, or lung cancer (Fig. 1B). Whole-body CT screening interpreted by radiologists showed no signs of malignant tumors. Electrocardiogram (ECG) showed sinus rhythm, low QRS voltage, slight PR

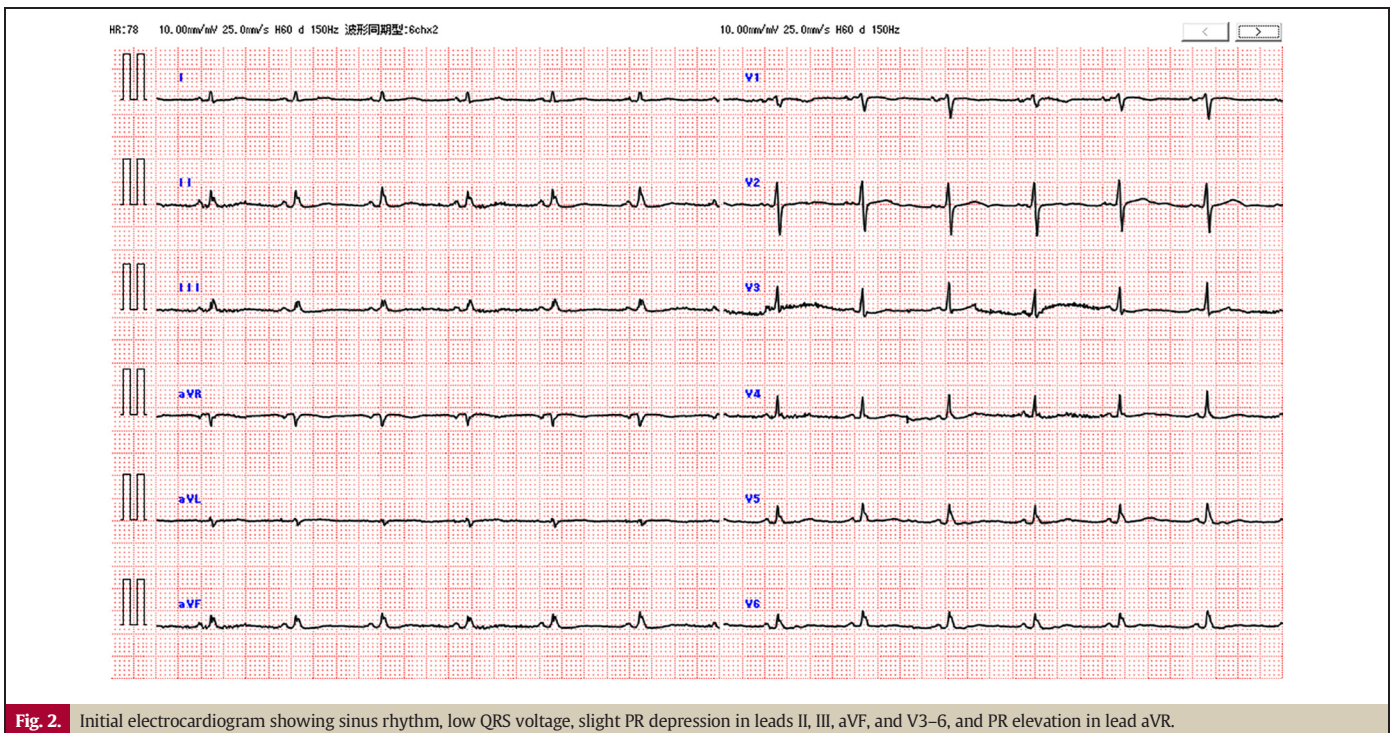


Table 1
Characteristics of pericardial and pleural effusions.

	Serum	Pericardial effusion	Right pleural effusion	Left pleural effusion
Type	–	Exudative	Exudative	Exudative
Appearance	–	Bloody	Cloudy, straw colored	Cloudy, straw colored
Protein (g/dL)	6.4	5	3.5	4
Glucose (mg/dL)	117	108	118	148
LDH (U/L)	241	432	117	163
ADA (U/L)	–	21	7	13
Rheumatoid factor (IU/mL)	<15	<15	<15	<15
CEA (ng/mL)	–	0.9	0.5	0.6
CA19-9 (U/mL)	–	14.4	1.6	2.2
Bacterial culture	–	Negative	Negative	Negative
Mycobacterial culture	–	Negative	Negative	Negative
Cytology	–	Negative	Negative	Negative

ADA, adenosine deaminase; CA19-9, carbohydrate antigen 19-9; CEA, carcinoembryonic antigen; LDH, lactate dehydrogenase.

depression in leads II, III, aVF, and V3–6, and PR elevation in lead aVR, implying the presence of pericarditis (Fig. 2). Transthoracic echocardiogram demonstrated remarkable pericardial effusion and collapse signs of right and left atrium, despite a normal left ventricular ejection fraction of over 60% (Fig. 1C). Blood testing revealed that C-reactive protein (CRP) (3.27 mg/dL) and brain natriuretic peptide (113.5 pg/mL) were elevated whereas other parameters including troponin T (0.009 ng/mL), creatine kinase (CK) (136 U/L), CKMB (7 U/L), white blood cell counts, electrolytes, antinuclear antibodies, and thyroid function were normal. Based on these findings, she was diagnosed with pericarditis and pre-tamponade. The normal ventricular wall motion and myocardial enzyme levels did not show the presence of myocarditis.

After admission, percutaneous pericardial drainage was performed, and her cardiac output recovered from 2.91 L/min to 3.73 L/min by removal of 400 mL of pericardial effusion. Despite the recovery of cardiac function, bilateral pleural effusions remained, and the shortness of breath of the patient was not well improved. Therefore, on the 2nd and 6th day of admission, right and left thoracic percutaneous drainages were performed, respectively. The drained pericardial and bilateral pleural effusions were all exudative and showed no signs of either malignant disease or bacterial infection including *Mycobacterium tuberculosis* (Table 1). The analysis of paired serum did not show a significant elevation of specific viral antibodies. Finally, she was diagnosed with subacute pleuropericarditis probably associated with the COVID-19 vaccination.

After administration of 0.5 mg/day of colchicine was started, CRP level decreased as well as pericardial and pleural effusions. On the 17th day of admission, she was discharged from our hospital with a residual left pleural effusion (Fig. 1D). She had an uneventful course after discharge, and two months later, we confirmed that her pericardial and pleural effusions disappeared (Fig. 1E). The timeline of this case is summarized in Online Fig. 1.

Discussion

To the best of our knowledge, this is the first report of COVID-19 vaccine-associated pleuropericarditis. The US Centers for Disease Control and Prevention reported that myocarditis/pericarditis rates were as rare as 12.6 cases per million doses of second-dose mRNA vaccine among individuals 12 to 39 years of age and that the risk of myocarditis/pericarditis was higher for males than females and for the young than the elderly [3]. Our case of an 88-year-old female patient who presented with pericarditis following BNT162b2 vaccination is relatively rare in terms of sex and age. Moreover, the patient experienced bilateral pleuritis simultaneously with pericarditis, which has not been reported in the literature to date.

Although there are no specific criteria for the diagnosis of COVID-19 vaccine-associated pericarditis, we applied the European Society of Cardiology guideline of pericardial disease, as with most of the previous case reports [4–7]. The diagnosis of acute pericarditis is based on the major findings of chest pain, pericardial friction rub, ECG changes, and

pericardial effusion, and on the additional supporting findings of the elevation of inflammation marker and the imaging evidence of pericardial inflammation [4]. However, in this case, her age of 88-years might have masked typical chest pain, and a large amount of pericardial effusion might have muted the friction rub. Although the clinical course was atypical and subacute, the slight changes in ECG, pericardial effusion, and the elevated CRP level helped the diagnosis. The etiology of acute pericarditis is generally classified as infectious causes such as bacterial, viral, and fungal and non-infectious causes such as autoimmune, neoplastic, metabolic, traumatic, and drug-related including vaccines [4]. In the clinical course of this case, we did not find any signs of infectious or non-infectious causes which can cause pericarditis except for BNT162b2 vaccination. Similarly, the bilateral pleural effusions were both exudative but did not show any signs of infection, neoplasm, or other diseases [8]. Thus, she was diagnosed with COVID-19 vaccine-associated pleuropericarditis.

The bilateral pleural effusions accompanied by pericardial effusion, especially when patients are painless, tend to be considered transudative and often diagnosed as congestive heart failure [9]. However, in our case, the drainage of pericardial and bilateral pleural effusions revealed that all of them were exudative, indicating the presence of concurrent pericarditis and bilateral pleuritis. Although it is difficult to specify its pathophysiology, we can presume two possible explanations: one is the direct spread of inflammation between pericardium and pleura, and the other is a result of systemic inflammation caused by vaccination. Previously, it has been reported that COVID-19 vaccination can induce multi-system inflammation syndrome [10].

Although there is no established treatment, steroids, nonsteroidal anti-inflammatory drugs, and colchicine have been empirically used for COVID-19 vaccine-associated pericarditis in the previous reports [5–7]. In our case, the patient's condition was stabilized after percutaneous drainages of all effusions, and subsequent administration of colchicine was effective for the prevention of recurrence. The aggressive effusion drainage might be useful not only for diagnosis but also for treatment in the clinical management of COVID-19 vaccine-associated pleuropericarditis.

In conclusion, we experienced a rare case of an elderly female who presented with subacute pleuropericarditis following BNT162b2 vaccination. When pericardial and pleural effusions are found after COVID-19 vaccination, even if it is painless, bilateral, and with subacute development, vaccine-associated pleuropericarditis should be considered as a differential diagnosis. Although there is no established treatment, percutaneous drainage and subsequent colchicine administration could be a treatment option for COVID-19 vaccine-associated pleuropericarditis.

Supplementary data to this article can be found online at <https://doi.org/10.1016/j.jccase.2022.04.020>.

Declaration of competing interest

The authors declare that there is no conflict of interest.

Acknowledgments

None.

References

- [1] Walsh EE, Frenck Jr RW, Falsey AR, Kitchin N, Absalon J, Gurtman A, et al. Safety and immunogenicity of two RNA-based Covid-19 vaccine candidates. *N Engl J Med* 2020; 383:2439–50.
- [2] Polack FP, Thomas SJ, Kitchin N, Absalon J, Gurtman A, Lockhart S, et al. Safety and efficacy of the BNT162b2 mRNA Covid-19 vaccine. *N Engl J Med* 2020;383:2603–15.
- [3] Bozukurk B, Kamat I, Hotez PJ. Myocarditis with COVID-19 mRNA vaccines. *Circulation* 2021;144:471–84.
- [4] Adler Y, Charron P, Imazio M, Badano L, Barón-Esquivias G, Bogaert J, et al. 2015 ESC Guidelines for the diagnosis and management of pericardial diseases: the Task Force for the Diagnosis and Management of Pericardial Diseases of the European Society of Cardiology (ESC) endorsed by: the European Association for Cardio-Thoracic Surgery (EACTS). *Eur Heart J* 2015;36:2921–64.
- [5] Mclean K, Johnson TJ. Myopericarditis in a previously healthy adolescent male following COVID-19 vaccination: a case report. *Acad Emerg Med* 2021;28:918–21.
- [6] Ashaari S, Sohaib HA, Bolger K. A case report: symptomatic pericarditis post-COVID-19 vaccination. *Eur Heart J Case Rep* 2021;5:ytab375.
- [7] Lazaros G, Anastassopoulou C, Hatziantoniou S, Kalos T, Soulaïdopoulos S, Lazarou E, et al. A case series of acute pericarditis following COVID-19 vaccination in the context of recent reports from Europe and the United States. *Vaccine* 2021;39:6585–90.
- [8] Porcel JM, Light RW. Diagnostic approach to pleural effusion in adults. *Am Fam Physician* 2006;73:1211–20.
- [9] Natanzon A, Kronzon I. Pericardial and pleural effusions in congestive heart failure—anatomical, pathophysiologic, and clinical considerations. *Am J Med Sci* 2009;338: 211–6.
- [10] Grome HN, Threlkeld M, Threlkeld S, Newman C, Martines RB, Reagan-Steiner S, et al. Fatal multisystem inflammatory syndrome in adult after SARS-CoV-2 natural infection and COVID-19 vaccination. *Emerg Infect Dis* 2021;27:2914–8.