

# Unilateral Biportal Endoscopic Discectomy versus Percutaneous Endoscopic Interlaminar Discectomy for Lumbar Disc Herniation

Wen-Bo Wei<sup>1-3,\*</sup>, Sha-Jie Dang<sup>4,\*</sup>, Hao-Zhe Liu<sup>5</sup>, Da-Peng Duan<sup>1,2</sup>, Ling Wei<sup>6</sup>

<sup>1</sup>Department of Orthopedics, Shaanxi Provincial People's Hospital, Xi'an, Shaanxi, People's Republic of China; <sup>2</sup>Shaanxi Province Key Laboratory of Basic and Clinical Translation for Bone and Joint Diseases, Shaanxi Provincial People's Hospital, Xi'an, Shaanxi, People's Republic of China; <sup>3</sup>State Key Laboratory for Manufacturing Systems Engineering, Xi'an Jiaotong University, Xi'an, Shaanxi, People's Republic of China; <sup>4</sup>Department of Anesthesia, Shaanxi Provincial Cancer Hospital, Xi'an, Shaanxi, People's Republic of China; <sup>5</sup>Department of Surgery, Hancheng Maternal and Child Health Hospital, Hancheng, Shaanxi, People's Republic of China; <sup>6</sup>Department of Pain, The Third Affiliated Hospital of Xi'an Medical University, Xi'an, Shaanxi, People's Republic of China

\*These authors contributed equally to this work

Correspondence: Ling Wei, Department of Pain, The Third Affiliated Hospital of Xi'an Medical University, Xi'an, Shaanxi, People's Republic of China, 710005, Email [sxweiling@126.com](mailto:sxweiling@126.com)

**Background:** As the latest endoscopic spine surgery, percutaneous endoscopic interlaminar discectomy (PEID) and unilateral biportal endoscopic (UBE) discectomy have distinct technical characteristics. This study aimed to evaluate the clinical outcomes of PEID and UBE discectomy in the treatment of single-level lumbar disc herniation (LDH).

**Methods:** Between February 2019 and April 2022, 115 patients with single-level LDH at L4-5 or L5-S1 received PEID or UBE discectomy. The patients were separated into two groups based on the surgical method used: Group 1 (the PEID group) (n = 60) and Group 2 (the UBE group) (n = 55). Various parameters, including operative time, hospitalization time, fluoroscopy frequency, total costs, complications, visual analogue scale (VAS), and Oswestry Disability Index (ODI), were evaluated and compared between the two groups.

**Results:** There were no significant differences in the VAS and ODI scores in 12 months after the operation between two groups ( $P > 0.05$ ). However, the VAS of lower back pain on the first day after the operation in Group 2 ( $2.53 \pm 0.89$ ) was higher than that in Group 1 ( $2.19 \pm 0.74$ ) ( $P < 0.05$ ). There were no significant differences in the operation time and incidence of complications between two groups ( $P > 0.05$ ). But total costs in Group 2 ( $43,121 \pm 4280$ ) were significantly higher than those in Group 1 ( $30,069 \pm 3551$ ) ( $P < 0.05$ ).

**Conclusion:** Both UBE and PEID procedures have similar efficacy in alleviating pain and improving functional ability in patients with LDH. However, UBE surgery results in higher costs than PEID surgery.

**Keywords:** unilateral biportal endoscopic discectomy, percutaneous endoscopic interlaminar discectomy, lumbar disc herniation

## Introduction

Lumbar disc herniation (LDH) is a frequently encountered disease in spinal surgery, characterized by symptoms such as low back pain and sciatica.<sup>1</sup> When conservative treatments have failed to resolve LDH, surgical intervention is often required.<sup>2</sup> Minimally invasive spinal surgery, such as percutaneous endoscopic lumbar discectomy, has the advantages of minimal trauma and fast postoperative recovery.<sup>3</sup> Consequently, Percutaneous Endoscopic Lumbar Discectomy (PELD) has gained widespread recognition among both surgeons and patients, which has increasingly replaced open surgery as the preferred surgical approach for LDH.<sup>4</sup> Based on the different surgical approaches used, percutaneous endoscopic lumbar discectomy can be classified into two main types: percutaneous transforaminal endoscopic discectomy (PTED) and percutaneous endoscopic interlaminar discectomy (PEID).<sup>5</sup> However, PEID has the drawbacks of a small surgical field, low surgical efficiency, long learning curve and difficulty in mastering.<sup>6</sup> Unilateral biportal endoscopic (UBE) discectomy is a combination of open and endoscopic spinal surgery. During the procedure of UBE, one portal is for optical instruments and the saline irrigation system, and the other is for surgical instruments.

This dual-port approach provides greater surgical control for decompression and wider visualization compared to traditional single-portal spine endoscopy.<sup>7</sup>

As the latest endoscopic spine surgery, PEID and UBE discectomy have distinct technical characteristics. The present study aims to compare the efficacy and safety of PEID and UBE discectomy for the treatment of single-segment LDH.

## Methods

### Study Design

A retrospective review was conducted on the medical records of 115 patients treated at the Department of Orthopedics, Shaanxi Provincial People's Hospital between February 2019 and April 2022. The study received approval from the clinical research ethics committee of Shaanxi Provincial People's Hospital (No. 2021-018) and adhered to the Good Clinical Practice guidelines and the principles outlined in the Helsinki Declaration. The study included 60 cases that received PEID (Group 1) and 55 cases that received UBE (Group 2).

### Patients

LDH patients (aged 35 ~ 90 years old, BMI 16 ~ 38 and ASA I-III) undergoing PEID or UBE were screened in this study. The inclusion criteria were: (1) presence of single-level herniated disc at the L4/L5 or L5/S1 levels, (2) ineffective response to conservative treatment for 3 months, (3) patients experiencing low back pain and/or sciatica, and (4) confirmation of signs and symptoms through MRI and CT imaging. Exclusion criteria encompassed: (1) patients with multi-segmental disc herniation, cauda equina syndrome, lumbar spinal stenosis, spinal metastatic disease, or lumbar spondylolisthesis, (2) individuals with psychosis or uncorrectable bleeding tendencies, (3) patients lost to follow-up, and (4) those who had previously undergone lumbar surgery.

### Procedures

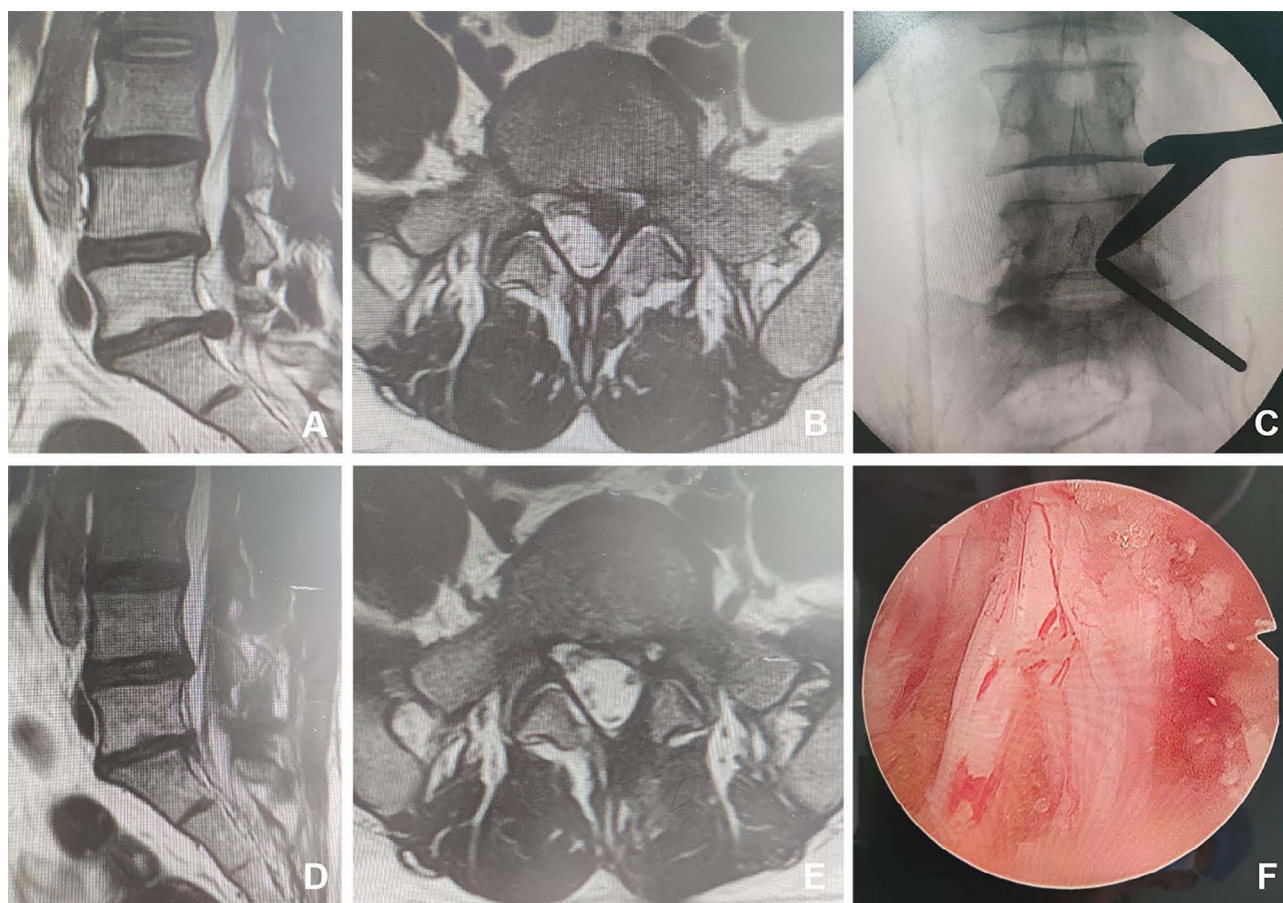
Guided by C-arm fluoroscopy, the patient was positioned in the prone position with U-shaped pillows under the chest and both ilia so that the abdomen was suspended.

#### UBE

In the case of the left side, the target intervertebral space was confirmed using C-arm fluoroscopy. Two incisions were 1.5 cm in the left side to the midline and 3 cm apart from each other, which were centered on the target intervertebral space. The two guide rods were inserted through the incision and met at the junction of the upper vertebral lamina and the lower articular process, which was confirmed by fluoroscopy. Then, used a T-shaped dilator to perform blunt relaxation of the soft tissue. The cranial portal (observational channel) inserted the endoscope (Stryker, Kalamazoo, MI, USA) for view, and the caudal portal (working channel) was used for surgical instruments and radiofrequency (RF) ablation (BONSS, JiangSu, China). Used RF ablation and pituitary forceps to clean the soft tissue in the field of vision, and exposed the upper vertebral lamina and the articular process. Partial laminectomy was performed using a grinding drill (Xishan, Tianjin, China) and Kerrison punches to expose the attachment of ligamentum flavum. The ligamentum flavum was removed using Kerrison punches. Then exposed the dura mater and nerve roots in the spinal canal, the traverse nerve root was gently retracted towards the midline of spinal canal, and discectomy was performed using pituitary forceps. Finally, the absence of residual fragments was confirmed using a neural probing hook. After meticulous hemostasis, the wounds were sutured (Figure 1).

#### PEID

C-arm fluoroscopy was used to locate the target intervertebral segment. The guide needle was placed at the junction of the vertebral plate and the inner edge of the lower articular process, which was 1 cm beside the midline, and the target position was confirmed by fluoroscopy again. Make a 1 cm incision to the target position of the vertebral plate, and inserted the spinal endoscopic operating system. Used RF ablation clean soft tissue and used pituitary forceps to remove a portion of the ligamentum flavum. Exposed the ipsilateral recess, used a grinding drill (Xishan, Tianjin, China) and Kerrison punches to decompress the ipsilateral recess, and fully exposed the shoulder and axilla of the nerve root.



**Figure 1** Male, 34 years old, L5/S1 lumbar disc herniation. (A) Preoperative sagittal MR image showed L5/S1 lumbar disc herniation; (B) Preoperative axial MR image showed herniated lumbar disc compressed nerve root and dural sac; (C) Intraoperative fluoroscopic confirmation of metal rods; (D) Postoperative sagittal MR image revealed the complete decompression of the spinal canal; (E) Postoperative axial MR image showed the complete removal of herniated disc and bony fragment; (F) Intraoperative image after complete neural decompression.

Removed disc through the nerve root shoulder or axillary. The dural sac and lumbar-exiting nerve root being freely movable were observed, removed the working cannula and sutured the skin incision (Figure 2).

### Postoperative treatment

All patients were instructed to wear waist protection after surgery when moving out of bed. Within one month after surgery, patients should avoid weight-bearing activities and engage in moderate lower back muscle function exercises.

### Outcomes

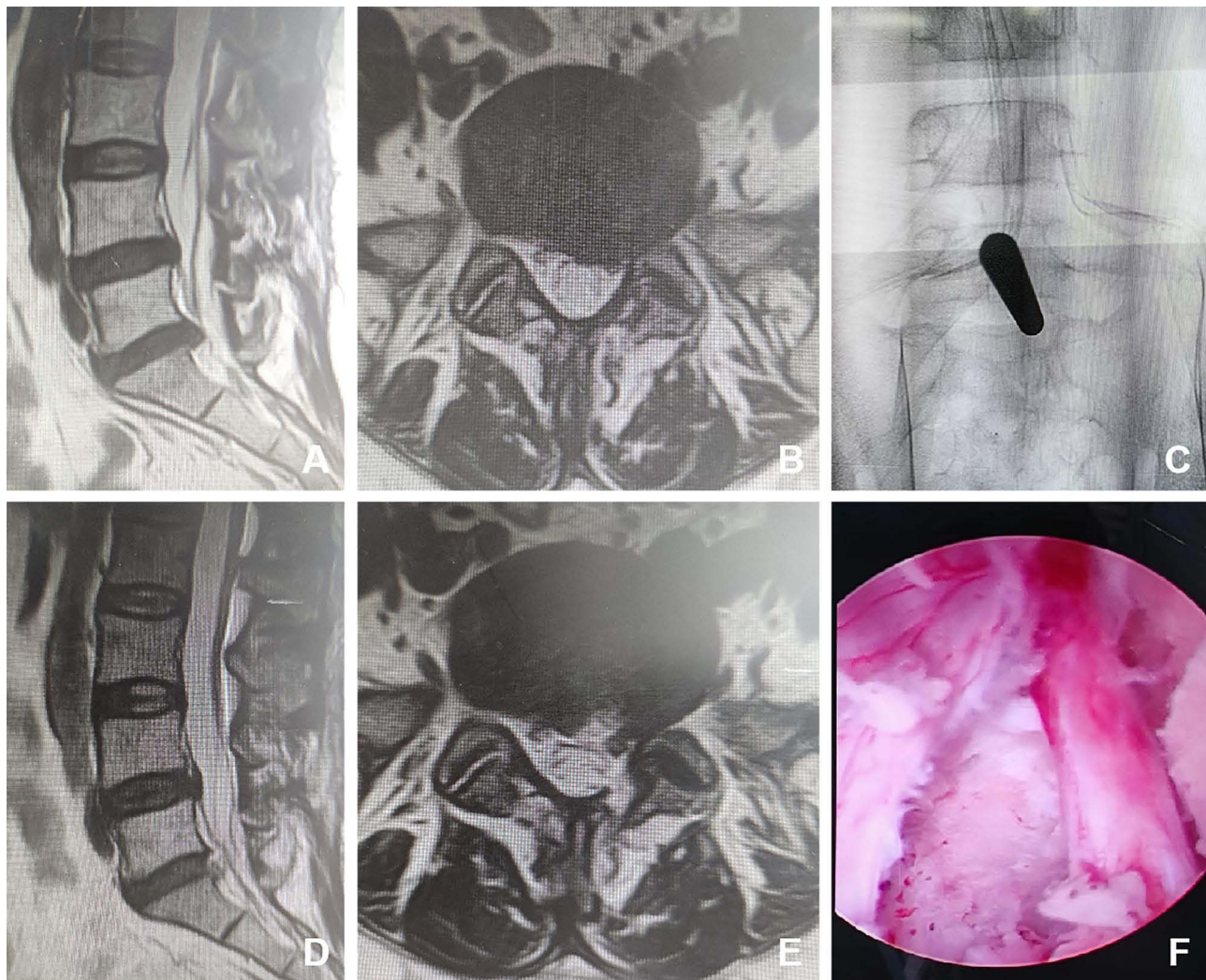
The CTF-classification of LDH<sup>8</sup> was recorded for all patients. The primary outcomes focused on assessing the visual analog scale (VAS) and the Oswestry Disability Index (ODI) scores at multiple time points: before the operation, at 1 day, 1, 3, 6, and 12 months after the operation. The secondary outcomes included several factors: operation time, hospitalization time, fluoroscopy frequency, total costs, and complication.

The VAS score was measured using a 10 cm visual analog scale. It was evaluated from 0 to 10, 0 indicates no pain, and 10 indicates the most severe pain. The ODI assesses low back pain-related disability, the higher the score means the worse the disability.

### Statistical Analysis

The statistical analysis was performed with SPSS 24.0 for Windows (SPSS, Inc., IBM). Measured data were tested for normal distribution and the homogeneity of variance. Numeric variables were expressed as Mean  $\pm$  SD and analyzed by





**Figure 2** Female, 50 years old, L5/S1 lumbar disc herniation. (A) Preoperative sagittal MR image showed L5/S1 lumbar disc herniation; (B) Preoperative axial MR image showed herniated lumbar disc compressed nerve root and dural sac; (C) Intraoperative fluoroscopic confirmation of metal rods; (D) Postoperative sagittal MR image revealed the complete decompression of the spinal canal; (E) Postoperative axial MR image showed the complete removal of herniated disc and bony fragment; (F) Intraoperative image after complete neural decompression.

Independent-Samples *T*-test. Repeated measures of ANOVA (with Bonferroni confidence interval adjustment) tests were conducted for VAS and ODI. Categorical data were expressed by N (%) and were analyzed with the  $\chi^2$  test. The value of  $P < 0.05$  was taken as a significant difference.

## Results

### General information

There were no statistically significant differences observed in terms of sex, age, body mass index (BMI), and disc herniation classification between the two groups ( $P > 0.05$ ). There were no significant differences in the operation time, hospitalization time, fluoroscopy frequency and incidence of complications among the two groups. But total costs in Group 2 were significantly higher than those in Group 1 ( $P < 0.05$ ).

None of the patients in any of the two groups experienced severe complications such as spinal injury or paraplegia. One case experienced nerve root injury in Group 1, while 1 case experienced dural puncture in Group 2. The complications were reversible and resolved within 3 months. The complication rate during follow-up had no significant difference between the two groups ( $P > 0.05$ ) (Table 1).

**Table 1** Comparison of General Data Between Group 1 and Group 2

		Group 1 (n = 60)	Group 2 (n = 55)	t/( $\chi^2$ )	P
Male/female		23/37	19/36	0.178	0.637
Age (years)		57.19±14.25	56.89±15.01	-0.090	0.928
BMI (kg/m <sup>2</sup> )		27.06±4.93	26.88±4.13	-0.045	0.927
Disc herniation classification	Protrusion	43	41	0.121	0.728
	Extrusion	14	14		
Hospitalization time (days)		7.18±2.30	7.50±2.12	0.639	0.525
Operation time (min)		54.34±10.15	56.74±10.57	1.032	0.305
Complication		1 (1.7%)	1 (1.8%)	(0.004)	0.950
Total costs (yuan)		30,069±3551	43,121±4280	14.841	<0.001*
Fluoroscopy frequency		3.28±0.66	3.51±0.63	1.293	0.241

**Notes:** Numeric data were expressed as Mean ± SD and analyzed by Independent-Samples T-test. Categorical data were expressed by the number of patients (%) and were analyzed with the  $\chi^2$  test. Group 1: PEID group; Group 2: UBE group. \* $P < 0.05$ , Group 1 vs Group 2.

**Abbreviations:** BMI, body mass index; PEID, percutaneous endoscopic interlaminar discectomy; UBE, unilateral biportal endoscopic.

## Comparison of VAS

There was no significant difference in the VAS of the low back pain and sciatica before the operation between the two groups ( $P > 0.05$ ). The VAS of the low back pain and sciatica at each observation point after the operation were significantly decreased compared with that before the operation in both groups ( $P < 0.05$ ). On the first day after the operation, the VAS of lower back pain in Group 2 was higher than that in Group 1 ( $P < 0.05$ ), and there was no statistical difference in the VAS of sciatica between the two groups ( $P > 0.05$ ). There was no statistical difference in the VAS of the low back pain and sciatica in 1, 3, 6 and 12 months after the operation between the two groups ( $P > 0.05$ ) (Table 2).

## Comparison of ODI

There was no significant difference in the ODI scores before the operation between the two groups ( $P > 0.05$ ). The ODI scores at each observation point after the operation were significantly decreased compared with that before the operation in both groups ( $P < 0.05$ ). There was no statistical difference in the ODI at 1 day, 1, 3, 6 and 12 months after the operation between the two groups ( $P > 0.05$ ) (Table 3).

**Table 2** Comparison of VAS Between Group 1 and Group 2 at Different Time

Group		Pre-Operatively	Post-Operatively				
			1 day	1 month	3 months	6 months	12 months
Group 1 (n=60)	low back pain	7.88±0.80	2.19±0.74*	1.86±0.75*	1.57±0.63*	1.19±0.71*	0.62±0.65*
	sciatica	7.83±0.99	2.24±0.69*	1.69±0.87*	1.48±0.74*	1.19±0.70*	0.66±0.65*
Group 2 (n=55)	low back pain	7.67±0.79	2.53±0.89*#	2.11±0.76*	1.68±0.66*	1.18±0.83*	0.68±0.59*
	sciatica	7.53±0.98	2.28±0.78*	1.79±0.97*	1.58±0.79*	1.18±0.76*	0.58±0.60*
Time F, P	low back pain	1033.296, <0.001					
	sciatica	755.833, <0.001					
Group F, P	low back pain	2.257, 0.057					
	sciatica	1.047, 0.397					
Time * Group F, P	low back pain	13.380, 0.539					
	sciatica	16.817, 0.266					

**Notes:** Data are presented as mean ± SD. The groups were compared by repeated measures analysis of variance (ANOVA). Bonferroni correction was used to correct multiple comparisons. Group 1: PEID group; Group 2: UBE group; \* $P < 0.05$ , post-operatively vs pre-operatively in the same group; # $P < 0.05$ , Group 2 vs Group 1 in the same time.

**Abbreviations:** VAS, visual analog scale; PEID, percutaneous endoscopic interlaminar discectomy; UBE, unilateral biportal endoscopic.

**Table 3** Comparison of ODI Between Group 1 and Group 2 at Different Time

Group	Pre-Operatively	Post-Operatively				
		1 day	1 month	3 months	6 months	12 months
Group 1 (n=60)	82.62±7.15	25.88±5.71*	21.86±5.12*	19.79±5.75*	17.31±5.11*	10.52±3.84*
Group 2 (n=55)	79.13±6.77	24.32±6.52*	21.24±5.31*	19.58±5.71*	16.15±4.82*	10.79±3.81*
Time F, P		1407.187, <0.001				
Group F, P		1.136, 0.349				
Time * Group F, P		21.733, 0.162				

**Notes:** Data are presented as mean ± SD. The groups were compared by repeated measures analysis of variance (ANOVA). Bonferroni correction was used to correct multiple comparisons. Group 1: PEID group; Group 2: UBE group; \*P < 0.05, post-operatively vs pre-operatively in the same group.

**Abbreviations:** ODI, Oswestry Disability Index; PEID, percutaneous endoscopic interlaminar discectomy; UBE, unilateral biportal endoscopic.

## Discussion

LDH is a prevalent cause of both low back pain and sciatica, significantly impacting the daily lives of patients.<sup>1</sup> Therefore, there is an urgent need to alleviate the pain and enhance the quality of life for these patients.<sup>2</sup> Minimally invasive surgery is often preferred by patients due to their potential for quicker postoperative recovery.<sup>3</sup> This retrospective study demonstrated that PEID and UBE discectomy can achieve equivalent and satisfactory outcomes in the 12 months follow-up. The VAS of lower back pain on the first day after the operation and total costs in Group 2 were higher than that in Group 1.

As a minimally invasive surgery, percutaneous endoscopic lumbar discectomy is superior to conventional open surgery due to its lower bleeding volume, minimal soft tissue damage, and faster return to work.<sup>4</sup> Compared to the steep learning curve of PLED, the learning curve of PEID is relatively flat.<sup>6</sup> PEID aligns more closely with surgeons' established surgical practices and exhibits a shorter learning curve.<sup>9</sup> A high iliac crest, a limited disc space, and overuse of radiography examinations of the lateral transforaminal approach might all be avoided by using PEID.<sup>10</sup> But it also has drawbacks, such as a small surgical field, low efficiency of surgical instruments, and limited decompression range.<sup>11</sup> It is difficult for the central type LDH, when to remove the intervertebral disc that deviates from the midline, it is often necessary to rotate the catheter to compress the nerves and dura sac to the opposite side, which may lead to postoperative numbness in the perineal area or weakness in dorsalis pedis extension.<sup>12</sup> It should be emphasized that percutaneous endoscopic requires specialized equipment, which imposes a substantial financial burden on many healthcare institutions. Therefore, not all hospitals, not all LDH patients, are suitable for PEID.

Unilateral biportal endoscopic (UBE) discectomy is a combination of open and endoscopic spinal surgery.<sup>7</sup> UBE shared the same interlaminar approach with open spinal surgery. This enables the use of a wide range of conventional instruments, including curettes, Kerrison punches, osteotomes, high-speed drills, and conventional forceps. Moreover, it is worth noting that UBE utilizes an arthroscopic system, which is already owned by the majority of hospitals, so the instruments required for UBE are more readily available and comparatively less expensive. By integrating the observational and operational channels, the instrument gains a wider range of movement, enabling a superior decompression range and enhanced exploration capability compared to percutaneous endoscopic techniques.<sup>13</sup> The learning curve of this technique is relatively shorter than that of percutaneous endoscopic.<sup>14</sup> Based on the aforementioned advantages, the utilization of UBE has gained significant popularity and has been increasingly adopted for the treatment of lumbar disc herniation and lumbar spinal stenosis. Our results indicate that the VAS and ODI scores at each observation point after the operation were significantly decreased compared with that before the operation in both groups. It means both surgical methods are effective in treating intervertebral disc herniation. On the first day after the operation, the VAS of lower back pain in Group 2 was higher than that in Group 1, this may be related to UBE needs to create a cavity outside the spinal canal, it causes greater damage to the paraspinal muscles than PEID. Paraspinal muscle integrity is believed to play a critical role in low back pain (LBP) and numerous spinal deformity diseases and other pain pathologies. A number of studies have demonstrated an association between paravertebral muscle injury and worse postoperative outcomes.<sup>15</sup>

In this study, the hospitalization time in both groups was very short, which means that patients receiving PEID or UBE can achieve rapid mobilization, recovery, and prompt resumption of their daily activities. Our study revealed that patients undergoing UBE discectomy incurred higher costs compared to those treated with the PEID technique. This discrepancy in costs may be attributed to the utilization of two radiofrequency (RF) ablations during UBE surgery. Despite the utilization of open instruments with improved efficiency in UBE, the requirement of an extraspinal cavity offsets any significant difference in surgical time compared to PEID.

Among the recorded complications, 1 case experienced nerve root injury in Group 1, while 1 case experienced dural puncture in Group 2. Previous research has indicated that a dural tear is the most common complication associated with UBE.<sup>16</sup> Several risk factors have been identified, including instrument or radiofrequency-induced damage to the dura mater, adhesion in the spinal canal, presence of giant disc fragments, and loosened dura.<sup>17,18</sup> Therefore, meticulous dissection of the meningo-vertebral ligament is of particular importance. PEID group showed nerve root injury is often attributed to nerve rotation and compression caused by the cannula in the spinal canal, and these symptoms typically improve within three months. Therefore, before rotating the cannula during PEID, the medial edge of the articular process should be removed to release the superior mesentery of the nerve root. Additionally, finer cannula selection and an appropriate operative route are advised to minimize nerve damage.

Our research has several limitations that should be acknowledged. Firstly, this was a retrospective study. Therefore, there may be inherent bias associated with patient selection and missing patient information. Secondly, the study was performed in only one hospital with limited patients enrolled, a larger scale clinical trial with multiple centers is needed in the future.

## Conclusion

Both the UBE and PEID procedures have demonstrated comparable efficacy in alleviating pain and improving functional ability in patients with LDH. However, UBE surgery is associated with higher costs compared to PEID surgery. Clinicians should cautiously control surgical indications and choose the most effective surgical operation that is reasonable to obtain the most satisfactory clinical curative effect.

## Abbreviations

PEID, percutaneous endoscopic interlaminar discectomy; UBE, unilateral biportal endoscopic; ASA, American Society of Anesthesiologists.

## Data Sharing Statement

The authors will allow the sharing of participant data. The data will be available to anyone who wishes to access them for any purpose. The data will be accessible from immediately the following publication to 6 months after publication, and contact should be made via the first author by email.

## Ethics Approval and Consent to Participate

This study was approved by the clinical research ethics committee of Shannxi Provincial People's Hospital (No. 2021-018). This study followed the Good Clinical Practice guidelines and the guidelines of the Helsinki Declaration. Written informed consent was obtained from all individual participants included in the study.

## Acknowledgment

The authors would like to thank all the study participants.

## Author Contributions

All authors made a significant contribution to the work reported, whether that is in the conception, study design, execution, acquisition of data, analysis and interpretation, or in all these areas; took part in drafting, revising or critically reviewing the article; gave final approval of the version to be published; have agreed on the journal to which the article has been submitted; and agree to be accountable for all aspects of the work.



## Funding

This work was supported by the Innovation Ability Strong Base Plan-Medical Research Project of Xi'an Science and Technology Bureau in 2022 (No.: 22YXYJ0155).

## Disclosure

The authors report no conflicts of interest in this work.

## References

1. Benzakour T, Igoumenou V, Mavrogenis AF, Benzakour A. Current concepts for lumbar disc herniation. *Int Orthop*. 2019;43(4):841–851. doi:10.1007/s00264-018-4247-6
2. Chen BL, Guo JB, Zhang HW, et al. Surgical versus non-operative treatment for lumbar disc herniation: a systematic review and meta-analysis. *Clin Rehabil*. 2018;32(2):146–160. doi:10.1177/0269215517719952
3. Momin AA, Steinmetz MP. Evolution of minimally invasive lumbar spine surgery. *World Neurosurg*. 2020;140:622–626. doi:10.1016/j.wneu.2020.05.071
4. Gadraj PS, Harhangi BS, Amelink J, et al. Percutaneous transforaminal endoscopic discectomy versus open microdiscectomy for lumbar disc herniation: a systematic review and meta-analysis. *Spine*. 2021;46(8):538–549. doi:10.1097/BRS.0000000000003843
5. Ahn Y. Endoscopic spine discectomy: indications and outcomes. *Int Orthop*. 2019;43(4):909–916. doi:10.1007/s00264-018-04283-w
6. Hsu HT, Chang SJ, Yang SS, et al. Learning curve of full-endoscopic lumbar discectomy. *Eur Spine J*. 2013;22(4):727–733. doi:10.1007/s00586-012-2540-4
7. Lin GX, Huang P, Kotheeranurak V, et al. A systematic review of unilateral biportal endoscopic spinal surgery. *Prelimin Clini Resu Compl World Neurosurg*. 2019;125:425–432.
8. Fardon DF. Nomenclature and classification of lumbar disc pathology. *Spine*. 2001;26(5):461–462. doi:10.1097/00007632-200103010-00007
9. Son S, Ahn Y, Lee SG, Kim WK. Learning curve of percutaneous endoscopic interlaminar lumbar discectomy versus open lumbar microdiscectomy at the L5-S1 level. *PLoS One*. 2020;15(7):e0236296. doi:10.1371/journal.pone.0236296
10. Fukuhara D, Ono K, Kenji T, Majima T. A narrative review of full-endoscopic lumbar discectomy using interlaminar approach. *World Neurosurg*. 2022;168:324–332. doi:10.1016/j.wneu.2022.08.080
11. Hong YH, Kim SK, Suh DW, Lee SC. Novel instruments for percutaneous biportal endoscopic spine surgery for full decompression and dural management: a comparative analysis. *Brain Sci*. 2020;10(8):516. doi:10.3390/brainsci10080516
12. Wasinpongwanich K, Pongpirul K, Lwin KMM, Kesornsak W, Kuansongtham V, Ruetten S. Full-endoscopic interlaminar lumbar discectomy: retrospective review of clinical results and complications in 545 international patients. *World Neurosurg*. 2019;132:e922–e928. doi:10.1016/j.wneu.2019.07.101
13. He D, Cheng X, Zheng S, et al. Unilateral biportal endoscopic discectomy versus percutaneous endoscopic lumbar discectomy for lumbar disc herniation: a systematic review and meta-analysis. *World Neurosurg*. 2023;173:e509–e520. doi:10.1016/j.wneu.2023.02.087
14. Xu J, Wang D, Liu J, et al. Learning curve and complications of unilateral biportal endoscopy: cumulative sum and risk-adjusted cumulative sum analysis. *Neurospine*. 2022;19(3):792–804. doi:10.14245/ns.2143116.558
15. He K, Head J, Mouchtouris N, et al. The implications of paraspinous muscle atrophy in low back pain, thoracolumbar pathology, and clinical outcomes after spine surgery: a review of the literature. *Global Spine J*. 2020;10(5):657–666. doi:10.1177/2192568219879087
16. Ju CI, Lee SM. Complications and management of endoscopic spinal surgery. *Neurospine*. 2023;20(1):56–77. doi:10.14245/ns.2346226.113
17. Chen Z, Zhou H, Wang X, Liu Z, Liu W, Luo J. Complications of unilateral biportal endoscopic spinal surgery for lumbar spinal stenosis: a meta-analysis and systematic review. *World Neurosurg*. 2023;170:e371–e379. doi:10.1016/j.wneu.2022.11.019
18. Zhou C, Zhang G, Panchal RR, et al. Unique complications of percutaneous endoscopic lumbar discectomy and percutaneous endoscopic interlaminar discectomy. *Pain Physician*. 2018;21(2):E105–E112.

Journal of Pain Research

Dovepress

Publish your work in this journal

The Journal of Pain Research is an international, peer reviewed, open access, online journal that welcomes laboratory and clinical findings in the fields of pain research and the prevention and management of pain. Original research, reviews, symposium reports, hypothesis formation and commentaries are all considered for publication. The manuscript management system is completely online and includes a very quick and fair peer-review system, which is all easy to use. Visit <http://www.dovepress.com/testimonials.php> to read real quotes from published authors.

Submit your manuscript here: <https://www.dovepress.com/journal-of-pain-research-journal>