

CASE REPORT

Open Access



Plasmodium malariae infections as a cause of febrile disease in an area of high *Plasmodium falciparum* transmission intensity in Eastern Uganda

Daniel Ayo¹, Bakar Odongo¹, Joseph Omara¹, Chiara Andolina², Ole Mulder², Sarah G. Staedke³ and Teun Bousema^{2,4*} 

Abstract

Background: *Plasmodium falciparum* is responsible for the vast majority of (severe) clinical malaria cases in most African settings. Other *Plasmodium* species often go undiagnosed but may still have clinical consequences.

Case presentation: Here, five cases of *Plasmodium malariae* infections from Eastern Uganda (aged 2–39 years) are presented. These infections were all initially mistaken for *P. falciparum*, but *Plasmodium* schizonts (up to 2080/μL) were identified by microscopy. Clinical signs included history of fever and mild anaemia.

Conclusion: These findings highlight the importance of considering non-falciparum species as the cause of clinical malaria. In areas of intense *P. falciparum* transmission, where rapid diagnostic tests that detect only *P. falciparum* antigens are commonly used, non-falciparum malaria cases may be missed.

Keyword: *Plasmodium malariae*, *P. falciparum*, Diagnosis, Misdiagnosis, Schizonts, Microscopy

Background

In 2019, an estimated 229 million cases and 409,000 deaths due to malaria were reported globally [1]. Most of these occurred in sub-Saharan Africa, and were caused by *Plasmodium falciparum*. Thus, it is not surprising that *P. falciparum* remains the focus of malaria control programmes and most malaria research in Africa. Other *Plasmodium* species are endemic in sub-Saharan Africa, including *Plasmodium ovale*, *Plasmodium vivax* and *Plasmodium malariae* [2]. These non-falciparum species also cause clinical symptoms, and lead sometimes to severe consequences. Chronic infections with *P. malariae*

may last for years, and can cause severe complications in approximately 3% of cases, including nephrotic syndrome, splenomegaly and anaemia [3, 4]. Moreover, *P. malariae* infections have been observed following treatment of *P. falciparum* infections with artemisinin-based combination therapy (ACT) [5, 6].

Different *Plasmodium* species can be differentiated by microscopy but this requires laboratory infrastructure and technical expertise. Infections with *P. malariae* are typically characterized by low parasitaemia [7] and the presence of rosette schizonts (daisy heads) and other parasite life-stages in the peripheral blood [8]. *Plasmodium malariae* is often missed or misdiagnosed by microscopy [9, 10]. However, polymerase chain reaction (PCR) suggests a non-negligible prevalence of *P. malariae* infection, either alone or mixed with other species, in population

*Correspondence: teun.bousema@radboudumc.nl; Teun.Bousema@ishtm.ac.uk

² Department of Medical Microbiology, Radboud University Nijmegen Medical Centre, Nijmegen, The Netherlands
Full list of author information is available at the end of the article



surveys in African countries, where prevalence of up to 12% has been reported [11, 12].

Rapid diagnostic tests (RDTs), which are simple to use and require minimal training, are increasingly being used to diagnose malaria. In Africa, most RDTs detect histidine-rich protein 2 (HRP2), an antigen that is specific for *P. falciparum*; use of these HRP2 RDTs is likely to contribute further to under-diagnosis of *P. malariae* infections.

Here, five cases are presented of symptomatic, uncomplicated *P. malariae*. These cases were coming from an area of intense *P. falciparum* transmission in Eastern Uganda and were initially misdiagnosed as *P. falciparum* by microscopy.

Case presentation

Patients described in this case report presented at either Masafu General Hospital or Nagongera Health Centre IV. Masafu General Hospital is a district referral facility in Busia District, an area in south-eastern Uganda that borders Kenya and Lake Victoria, where transmission of *P. falciparum* is perennial and intense [13]. Nagongera Health Centre IV is located in Nagongera sub-county in Tororo district. Nagongera sub-county is predominantly a rural setting, with traditionally very high malaria transmission [14]. Between 2019 and 2020 the total Outpatient Department treatment (OPD) attendance in Masafu General Hospital was 40,471, whilst in Nagongera Health Centre IV 18,624 [15].

In both settings, hospital and health centre, malaria diagnosis is routinely performed by HRP-2 based rapid diagnostic test (Standard Q Malaria Pf Ag, SD Biosensor, South Korea). However, as part of a research study on *P. falciparum*, clinic technicians all received formal microscopy training and thick and thin blood films were used for malaria diagnosis, instead of RDTs. Haemoglobin measurements were performed by Hemocue™ (haemoglobinometer, Angelholm, Sweden).

Case-patient 1

On January 30th 2020, a 15-year-old male presented to the OPD with history of fever, headache and joint pain for 3 days with no evidence of severe malaria or danger signs. At initial presentation, he had an axillary temperature of 36.8 °C and his physical examination was within normal limits. Malaria parasites were reported on the thick and thin blood film. By thick blood smear, total parasite count was 896 parasites/μL; malaria schizonts were observed at 176 parasites/μL (and included in the total parasite density estimate). Haemoglobin concentration was 12.3 g/dL. The patient was diagnosed with *P. falciparum* malaria.

Case-patient 2

On February 19th 2020, a 20-year-old female presented to the OPD with history of fever for 3 days and headache, weakness and joint pain for 2 days. Her temperature on admission was 37.2 °C and her physical examination did not show abnormalities. After reading the thick blood film, malaria infection was diagnosed with a total of 2288 parasites/μL (2080 schizonts/μL). Mild anaemia was detected with haemoglobin of 10.8 g/dL. The patient was diagnosed with *P. falciparum* malaria.

Case-patient 3

On February 27th 2020, a 39-year-old female presented to the OPD with history of fever and joint pain for 2 days and headache, weakness and low back pain for 4 days. Her axillary temperature on admission was 37.0 °C and she was diagnosed with uncomplicated *P. falciparum* malaria based on a thick blood film with 336 parasites/μL (272 schizonts/μL). Mild anaemia was detected with haemoglobin of 9.5 g/dL.

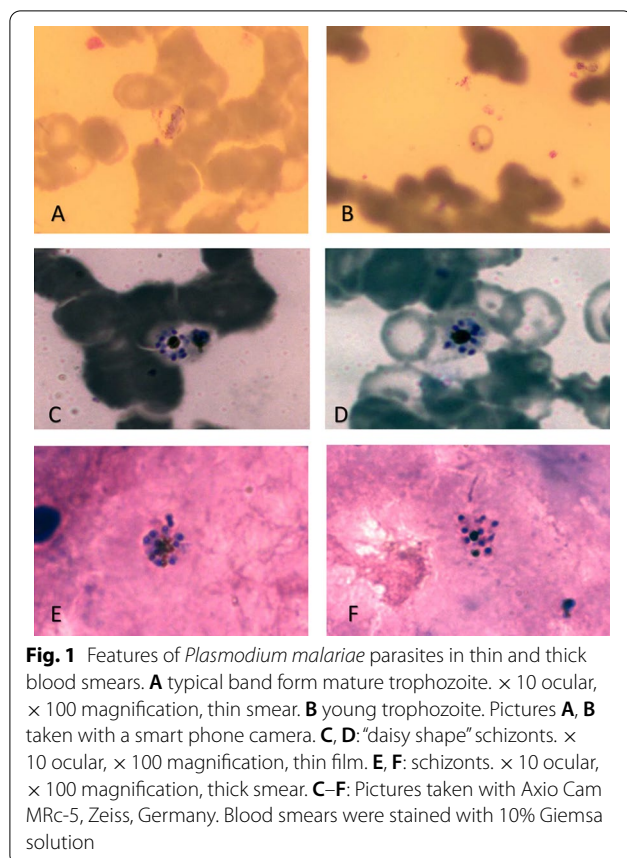
Case-patient 4

On March 3rd 2020, a 2-year-old boy presented to the outpatient department with persistent vomiting, anorexia and headache. He had an axillary temperature of 38.3 °C. Microscopy slides were interpreted as *P. falciparum/P. malariae* mixed infection based on presence of 32 ring-stage parasites/μL and 520 schizonts/μL for *P. falciparum* and one trophozoite “band form” for *P. malariae*. Haemoglobin was 7.8 g/dL. The patient was diagnosed with uncomplicated mixed species malaria infection.

Case-patient 5

On April 29th 2020, a 14-year-old male with mild symptoms of fever, headache, joint pain and anorexia presented to Nagongera Health Center IV, Tororo district. He had an axillary temperature of 37.4 °C. Malaria was diagnosed by microscopy with 4016 parasites/μL (96 schizonts/μL). Haemoglobin was 11.1 g/dL. The patient was diagnosed with uncomplicated *P. falciparum* malaria.

All five cases were treated for uncomplicated *P. falciparum* infection according to national Ugandan treatment guidelines with artemether lumefantrine 20 mg/120 mg twice per day for 3 days and discharged home [16]. Although there are some reports of persisting *P. malariae* parasites after artemether-lumefantrine [5, 17], suggestive of reduced treatment efficacy for this species, most available data support the use of artemether-lumefantrine for *P. malariae* [18, 19]. Thick and thin smears were re-read by expert microscopists and representative images taken (Fig. 1). Parasite DNA was extracted from fixed Giemsa-stained thick and thin smears using a



modified protocol for isolating genomic DNA from dried blood spots (QIAamp[®] DNA Micro kit, cat numb. 56304) [20]. *Plasmodium* speciation was performed using modified methods described by Snounou et al. [21]. *Plasmodium malariae* parasite DNA was detected in material

from all slides; *P. falciparum* was also detected for case 4 (Table 1).

Discussion and conclusions

In these five symptomatic malaria cases, *P. malariae* was the most likely cause of the clinical symptoms. All cases were classified as uncomplicated malaria, although they presented with anaemia, a condition that is often associated with chronic infection with *P. malariae* [3, 4]. In four cases, *P. falciparum* infection was initially diagnosed. Only after an expert microscopist reviewed the blood slides was *P. malariae* identified as the infecting species. The presence of symptomatic *P. malariae* mono-infections has implications for the use of HRP-2 RDTs. In both of the study settings, HRP-2 RDTs are routinely used to diagnose malaria. Since non-falciparum *Plasmodium* species do not express HRP-2 antigen, at least four of these cases would presumably have been missed in routine practice and would not have received malaria treatment.

The cases presented here all reported to the health facilities within a relatively short 13-week period. No effort is made to systematically investigate for non-falciparum malaria among individuals presenting with suspected malaria under standard care. This suggests that a considerable number of patients may present with uncomplicated non-falciparum malaria in this setting. The *P. malariae* cases reported here were older than typical *P. falciparum* cases in the area [22], which could be the consequence of a lower force of infection of non-falciparum malaria, older age at first infection, and higher average age at clinical presentation. However, other studies found *P. malariae* infections predominantly in children [23, 24], further highlighting the need for research into the clinical burden of non-falciparum malaria in African settings.

Table 1 Patient characteristics at presentation

Case	Age	Gender	Temperature (°C)	Symptoms	Haemoglobin (g/dL)	Trophozoite (rings) count ^a	Schizont count ^a	Diagnosis by microscopy	Diagnosis by 18S qPCR
1	15	Male	36.8	Headache 3d, joint pain 2d, fever	12.3	720	176	Pf	Pm
2	20	Female	37.2	Headache 2d, general body weakness and joint pain 3d, fever 3d	10.8	208	2080	Pf	Pm
3	39	Female	37.0	Fever and joint pain 2d, general body weakness, headache, backache 4d	9.5	64	272	Pf	Pm
4	2	Male	38.3	Persistent vomiting, anorexia, fever, headache	7.8	32	520	Pf + Pm	Pm/Pf
5	14	Male	37.4	Headache, fever 3d, joint pain, anorexia	11.1	3920	96	Pf	Pm

^a Density per microlitre of blood

Identifying the species of *Plasmodium* infections using molecular diagnostic techniques is needed to quantify the burden of malaria in areas where multiple species may be present.

Abbreviations

HRP2: Histidine-rich protein 2; OPD: Outpatient department treatment; PCR: Polymerase chain reaction; RDTs: Rapid diagnostic tests.

Acknowledgements

We thank the patients who participated in this study. We further thank Kjerstin Lanke for molecular assays and Marga de Vegte-Bolmer for support in microscopy.

Authors' contributions

DA, BO, JO read the blood smears and counted the parasites; OM, DA, CA wrote the draft of the manuscript; SGS and TB conceived and prepared the manuscript. All authors read and approved the final manuscript.

Funding

This is supported by the National Institute of Allergy and Infectious Diseases (NIAID) as part of the International Centers of Excellence in Malaria Research (ICEMR) program (U19AI089674) and the Bill & Melinda Gates Foundation (INDIE OPP1173572). Under the grant conditions of the Foundation, a Creative Commons Attribution 4.0 Generic License has already been assigned to the Author Accepted Manuscript version that might arise from this submission. TB and CA are further supported by a European Research Council-Consolidator Grant to TB (ERC-CoG 864180; QUANTUM).

Availability of data and materials

Not applicable. All data are included in the manuscript.

Declarations

Ethics approval and consent to participate

Data was collected under a protocol that was approved by the School of Biomedical Sciences Research and Ethics Committee Makerere University College of Health Sciences (SOM-REC IRB; Protocol # SBS-363), UNCST (Number HS-2110), the Human Research Protection Program Institutional Review Board of the University of California-San Francisco (IRB # 16-2056), the London School of Hygiene & Tropical Medicine and the Liverpool School of Tropical Medicine (15-025).

Consent for publication

All authors have given their consent for this publication.

Competing interests

The authors have declared that no competing interests exist.

Author details

¹Infectious Diseases Research Collaboration, Kampala, Uganda. ²Department of Medical Microbiology, Radboud University Nijmegen Medical Centre, Nijmegen, The Netherlands. ³Department of Clinical Research, London School of Hygiene and Tropical Medicine, London, UK. ⁴Department of Immunology and Infection, London School of Hygiene and Tropical Medicine, London, UK.

Received: 16 August 2021 Accepted: 20 October 2021

Published online: 29 October 2021

References

1. WHO. World malaria report 2020: 20 years of global progress and challenges. Geneva: World Health Organization; 2020.
2. Jamison DT, Feachem RG, Makgoba MW, Bos ER, Baingana FK, Hofman KJ, et al. Disease and mortality in sub-Saharan Africa. 2nd ed. Washington (DC): The International Bank for Reconstruction and Development/The World Bank; 2006.
3. Langford S, Douglas NM, Lampah DA, Simpson JA, Kenangalem E, Sugiarto P, et al. *Plasmodium malariae* infection associated with a high burden of anemia: a hospital-based surveillance study. *PLoS Negl Trop Dis*. 2015;9: e0004195.
4. Vinetz JM, Li J, McCutchan TF, Kaslow DC. *Plasmodium malariae* infection in an asymptomatic 74-year-old Greek woman with splenomegaly. *N Engl J Med*. 1998;338:367–71.
5. Betson M, Sousa-Figueiredo JC, Atuhaire A, Arinaitwe M, Adriko M, Mwesigwa G, et al. Detection of persistent *Plasmodium* spp. infections in Ugandan children after artemether-lumefantrine treatment. *Parasitology*. 2014;141:1880–90.
6. Lubis IND, Wijaya H, Lubis M, Lubis CP, Beshir KB, Staedke SG, et al. Recurrence of *Plasmodium malariae* and *P. falciparum* following treatment of uncomplicated malaria in North Sumatra with dihydroartemisinin-piperazine or artemether-lumefantrine. *Open Forum Infect Dis*. 2020;7: ofaa116.
7. Oriero EC, Amenga-Etego L, Ishengoma DS, Amambua-Ngwa A. *Plasmodium malariae*, current knowledge and future research opportunities on a neglected malaria parasite species. *Crit Rev Microbiol*. 2021;47:44–56.
8. Collins WE, Jeffery GM. *Plasmodium malariae*: parasite and disease. *Clin Microbiol Rev*. 2007;20:579–92.
9. Bharti PK, Chand SK, Singh MP, Mishra S, Shukla MM, Singh R, et al. Emergence of a new focus of *Plasmodium malariae* in forest villages of district Balaghat, central India: implications for the diagnosis of malaria and its control. *Trop Med Int Health*. 2013;18:12–7.
10. Savargaonkar D, Shah N, Das MK, Srivastava B, Valecha N. *Plasmodium malariae* infection: a case of missed diagnosis. *J Vector Borne Dis*. 2014;51:149–51.
11. Noland GS, Graves PM, Sallau A, Eigege A, Emukah E, Patterson AE, et al. Malaria prevalence, anemia and baseline intervention coverage prior to mass net distributions in Abia and Plateau States, Nigeria. *BMC Infect Dis*. 2014;14:168.
12. Doctor SM, Liu Y, Anderson OG, Whitesell AN, Mwandagaliwa MK, Muwonga J, et al. Low prevalence of *Plasmodium malariae* and *Plasmodium ovale* mono-infections among children in the Democratic Republic of the Congo: a population-based, cross-sectional study. *Malar J*. 2016;15:350.
13. Kajubi R, Ochieng T, Kakuru A, Jagannathan P, Nakalembe M, Ruel T, et al. Monthly sulfadoxine-pyrimethamine versus dihydroartemisinin-piperazine for intermittent preventive treatment of malaria in pregnancy: a double-blind, randomised, controlled, superiority trial. *Lancet*. 2019;393:1428–39.
14. Nankabirwa JI, Arinaitwe E, Rek J, Kilama M, Kizza T, Staedke SG, et al. Malaria transmission, infection, and disease following sustained indoor residual spraying of insecticide in Tororo, Uganda. *Am J Trop Med Hyg*. 2020;103:1525–33.
15. Ministry of Health. Annual health sector performance report 2019-2020 FY-1. Kampala, Uganda. <https://www.health.go.ug/cause/annual-health-sector-performance-report-financial-year-2019-20/>.
16. Ministry of Health. Uganda clinical guidelines 2016—National guidelines for management of common conditions. Kampala, Uganda. 2016.
17. Calleri G, Balbiano R, Caramello P. Are artemisinin-based combination therapies effective against *Plasmodium malariae*? *J Antimicrob Chemother*. 2013;68:1447–8.
18. Visser BJ, Wieten RW, Kroon D, Nagel IM, Belard S, van Vugt M, et al. Efficacy and safety of artemisinin combination therapy (ACT) for non-falciparum malaria: a systematic review. *Malar J*. 2014;13:463.
19. Groger M, Veletzky L, Lalremruata A, Cattaneo C, Mischlinger J, Zoleko-Manego R, et al. Prospective clinical trial assessing species-specific efficacy of artemether-lumefantrine for the treatment of *Plasmodium malariae*, *Plasmodium ovale*, and mixed *Plasmodium* malaria in Gabon. *Antimicrob Agents Chemother*. 2018;62:e01758-e1817.
20. Cnops L, Van Esbroeck M, Bottieau E, Jacobs J. Giemsa-stained thick blood films as a source of DNA for *Plasmodium* species-specific real-time PCR. *Malar J*. 2010;9:370.
21. Snounou G, Viriyakosol S, Zhu XP, Jarra W, Pinheiro L, do Rosario VE, et al. High sensitivity of detection of human malaria parasites by the use of nested polymerase chain reaction. *Mol Biochem Parasitol*. 1993;61:315–20.

22. Zehner N, Adrama H, Kakuru A, Andra T, Kajubi R, Conrad M, et al. Age-related changes in malaria clinical phenotypes during infancy are modified by sickle cell trait. *Clin Infect Dis*. 2021. <https://doi.org/10.1093/cid/ciab245>.
23. Lo E, Nguyen K, Nguyen J, Hemming-Schroeder E, Xu J, Etemesi H, et al. *Plasmodium malariae* prevalence and *csp* gene diversity, Kenya, 2014 and 2015. *Emerg Infect Dis*. 2017;23:601–10.
24. Roucher C, Rogier C, Sokhna C, Tall A, Trape JF. A 20-year longitudinal study of *Plasmodium ovale* and *Plasmodium malariae* prevalence and morbidity in a West African population. *PLoS ONE*. 2014;9: e87169.

Publisher's Note

Springer Nature remains neutral with regard to jurisdictional claims in published maps and institutional affiliations.

Ready to submit your research? Choose BMC and benefit from:

- fast, convenient online submission
- thorough peer review by experienced researchers in your field
- rapid publication on acceptance
- support for research data, including large and complex data types
- gold Open Access which fosters wider collaboration and increased citations
- maximum visibility for your research: over 100M website views per year

At BMC, research is always in progress.

Learn more biomedcentral.com/submissions

