

Extracranial Internal Carotid Artery Aneurysm – Challenges in the Management: A Case Report and Review Literature

Abstract

Extracranial internal carotid artery aneurysms (EICA) are rare. Incidence is <1% of all an arterial aneurysm. This aneurysm being rare but is important because it is associated with a high risk of neurological thromboembolic events, cranial nerve compression, and rupture. The causes of the EICA are congenital, trauma leading to the pseudoaneurysm, atherosclerosis, infections, and fibromuscular dysplasia. Here, we describe a case report of a 69-year-old female with progressive enlargement of the right neck mass accompanied by dyspnea on exertion. The patient had been diagnosed as right EICA and underwent the endovascular procedure as parent vessel occlusion 4 years ago. There was still enlargement of the size of the right neck mass and was causing troublesome to the patient. We performed selective embolization of the various feeders to the mass, but after this also, it was still enlarging. Three-dimensional reconstruction of the computed tomography scan showed fusiform dilatation of the right proximal EICA. We made the diagnosis of the thrombosed EICA and hence we planned to undergo surgical management. We performed removal of the intraluminal thrombus and ligation of the EICA. The size of the swelling decreased significantly.

Keywords: Endovascular; extracranial internal carotid aneurysm, management, rare case

Introduction

The first surgery for the ligation of the common carotid artery (CCA) was performed by Sir Astley Cooper in 1805. Surgery was successful, but the patient had mortality after 40 h.^[1] Later, after 150 years, Dimtza performed the first successful carotid aneurysm excision in 1952 using an end-to-end anastomosis.^[2] Beall *et al.* were the first to report the use of a prosthetic graft to replace the carotid for aneurysmal disease in 1959.^[3] Extracranial internal carotid artery aneurysms (EICA) are rare and account for <1% of all arterial aneurysms. Aneurysms of the extracranial carotid artery (ECCA) are rare, with a reported incidence of 0.2%–5% of all carotid artery surgeries.^[4] Schechter elucidated 853 cases of EICA in 820 patients, in a literature review spanning the period 1687–1977.^[5] The most common locations of an aneurysm in ECCA are the CCA near the bifurcation followed by mid-to-distal internal carotid artery (ICA).^[6] There are various causes of the ECCA aneurysm (ECAA). Most common cause is atherosclerosis which is seen

among elderly patients. Other causes are congenital, trauma, and infections.^[7] Most frequently, they present with neurological signs (cerebrovascular accidents [CVAs], transient ischemic attacks [TIAs], or Horner's syndrome) or a simple neck swelling and other presentation may be hemorrhage and compression due to massive aneurysms. There are multiple diagnostic modalities for the assessment of the adequacy of the collateral cerebral circulation through the circle of Willis. The preferred method of treatment is surgical, and the aim is to resect an aneurysm and repair the vessel while maintaining cerebral blood flow.^[8] Treatment by ligation of the ICA is accompanied with a risk of stroke up to 30%.^[9] Carotid endarterectomy (CEA) is one of the most frequently performed operations in vascular surgery.^[10] Despite the increasing role of endovascular therapy in treating vascular disease, we believe that open surgical repair, although challenging, remains the most appropriate approach for ECCA. There are various case reports illustrated regarding EICA, but the need of multiple treatments required to manage an aneurysm is not enlisted much in the literature.

This is an open access journal, and articles are distributed under the terms of the Creative Commons Attribution-NonCommercial-ShareAlike 4.0 License, which allows others to remix, tweak, and build upon the work non-commercially, as long as appropriate credit is given and the new creations are licensed under the identical terms.

For reprints contact: reprints@medknow.com

**Rajan Kumar Sharma^{1,2},
Ahmed Mohammed Asiri³,
Yasuhiro Yamada²,
Tsukasa Kawase²,
Yoko Kato²**

¹Department of Neurosurgery, National Academy of Medical Sciences, Bir Hospital, Kathmandu, Nepal,

²Department of Neurosurgery, Fujita Health University, Banbuntane Hotokukai Hospital, Nagoya, Japan,

³Department of Neurosurgery, King Faisal Medical City, Abah, Saudi Arabia

Address for correspondence:

Dr. Rajan Kumar Sharma,
Department of Neurosurgery,
National Academy of Medical
Sciences, Bir Hospital,
Kathmandu, Nepal.

E-mail: rajanktm58@gmail.com

Access this article online

Website: www.asianjns.org

DOI: 10.4103/ajns.AJNS_292_18

Quick Response Code:



How to cite this article: Sharma RK, Asiri AM, Yamada Y, Kawase T, Kato Y. Extracranial internal carotid artery aneurysm – Challenges in the management: A case report and review literature. Asian J Neurosurg 2019;14:970-4.

Case Report

A 69-year-old right-handed female was admitted to our hospital because of a pulsatile mass at the right side of the neck, below the angle of the mandible. The patient reported that she had noticed the mass for the first time 13 years ago and has been followed up regularly. There was no history of any infective lesion, trauma, or any family history of aneurysm disease. There was no palpable lymphadenopathy. Initially, she has treated conservatively and due to the appearance of the symptoms such as enlargement of the size of the mass and dyspnea on exertion. She had been managed with endovascular treatment as parent vessel occlusion 4 years ago [Figure 1]. There was shrinkage of the size of the mass and improvement of the symptoms. Over the past 6 months, the size has again started to enlarge and also the appearance of the symptoms and its pulsatile nature became more evident. Clinical examination showed a pulsatile mass on the right side of the neck. No neurologic symptoms occurred in the patient. Examination of the cranial nerves showed no anomalies. A computed tomography (CT) angiography followed, verifying the presence of a fusiform giant aneurysm of the right ICA, measuring 5 cm in diameter. To further define the right EICA and the remaining cerebral circulation, CT angiography was performed with three-dimensional (3D) reconstruction. The 3D reconstruction confirmed a fusiform aneurysm arising from the proximal right EICA [Figure 2]. Despite the patient had undergone endovascular management 4 years ago in the

form of parent vessel occlusion, we could see the minimal flow in the EICA which may be due to recanalization. No intracranial aneurysmal disease was identified. The aneurysm measurements were 25 mm × 30 mm, with a cranial-caudal length of 50 mm and a wide neck. An aneurysm extended from 2 cm after the carotid bifurcation nearly to the base of the skull. The patient elected for surgical correction, as she was finding her symptoms troublesome and was keen for a “definitive” solution. Since the patient had undergone endovascular management and still there was enlargement of an aneurysm and causing symptoms, the plan of surgical exploration was made. The procedure was performed under general anesthesia through an incision in the neck along the anterior border of the sternocleidomastoid muscle. The arterial wall was atherosclerotic, and there was a large intraluminal thrombus. She underwent arteriotomy and evacuation of the thrombus and ligation of the EICA [Figure 3]. Postoperative recovery was uneventful without neurologic dysfunction. Postoperative neurologic examination was without anomalies. Surgical pathology of the specimen confirmed the hyalinized thrombus. The biopsy from the wall showed intimal fibromuscular dysplasia which is compatible with the aneurysmal wall and CD34 immunohistochemistry showed the vasa vasorum [Figure 4].

Discussion

Aneurysms of the EICA are infrequent lesions, accounting for 1% of peripheral aneurysms. The most common underlying cause of ECCA is atherosclerosis which is seen

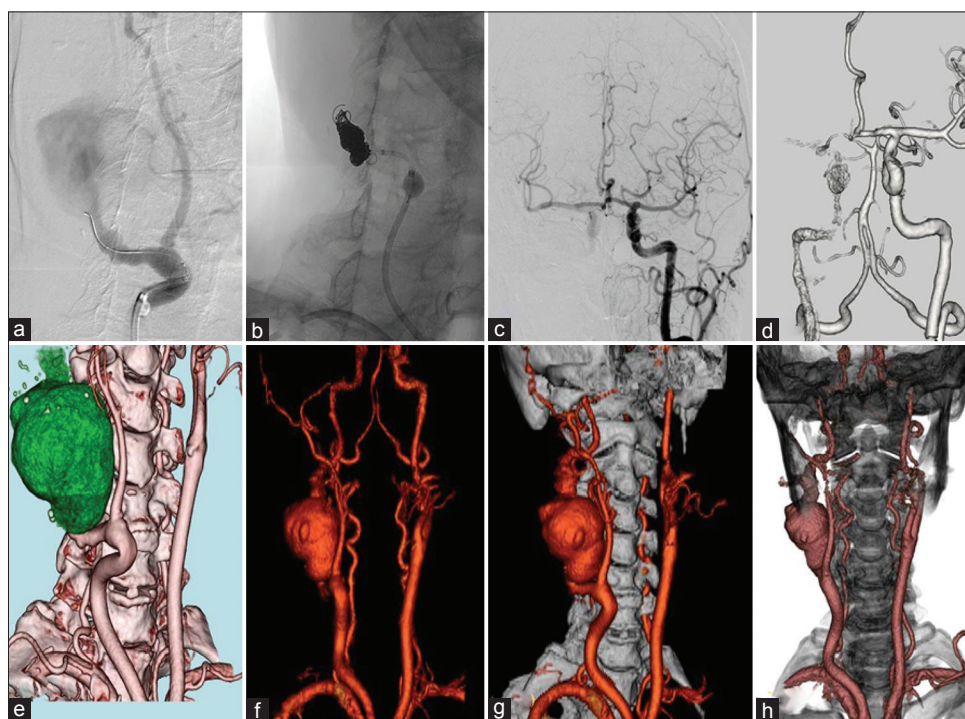


Figure 1: Endovascular management (parent vessel occlusion of the right internal carotid artery) done 4 years ago and the computed tomography angiography with three-dimensional reconstruction images for the diagnosis. (a-c) Intraoperative figure showing the endovascular management as parent vessel occlusion of the right internal carotid artery. (d) Computed tomography angiography showing the occlusion of the right internal carotid artery with the coils. (e-h) Computed tomography angiography with three-dimensional reconstruction before the endovascular management

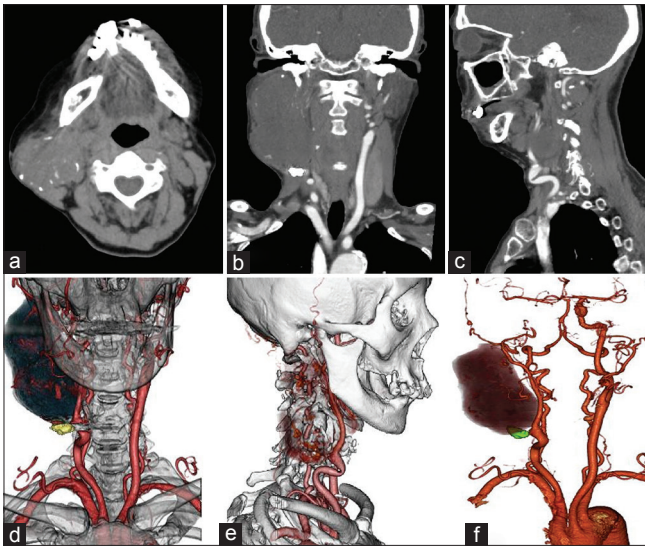


Figure 2: Computed tomography angiography and three-dimensional reconstruction images of the patient before surgery. (a-c) Axial, coronal, and sagittal section showing the aneurysm in the right extracranial internal carotid artery. (d-f) Computed tomography angiography with three-dimensional reconstruction

in 37%–42% of aneurysms followed by trauma which is the second most common cause of ECCA (35%–51%)^[11,12] whereas pseudoaneurysms arising at prior endarterectomy sites have accounted for 26%–57% of aneurysms in other series.^[13] If the young patients have ECAA, then the infective etiology should be looked at like tuberculosis or human immunodeficiency virus. Mycotic aneurysms usually are caused by *Salmonella* or syphilis. Other etiologies are collagen vascular disease, fibromuscular dysplasia, irradiation, Behcet's disease, Takayasu's arteritis, or Cogan syndrome. Connective diseases that can affect the carotid arteries include Marfan syndrome, Ehlers–Danlos syndrome, osteogenesis imperfecta, and pseudoxanthoma elasticum.^[14] Atherosclerotic aneurysms are usually found in elderly patients. They are usually fusiform and involve the bifurcation more frequently than other sites.^[15] The most common clinical presentation is pulsatile cervical mass and local pain, but if an aneurysm is in distal ECCA, it can cause dysfunction of postganglionic sympathetic nerve fibers and cranial nerves due to compression or distension leading to swallowing difficulties, hoarseness or even Horner syndrome.^[16] For the diagnosis of the ECCA, we can perform the Doppler ultrasound, which has the advantage of being relatively inexpensive, noninvasive, and does not expose the patient to ionizing radiation. The gold standard diagnostic tool for this is conventional digital subtraction angiography. CT angiography has been routinely done diagnosis tool which provides extravascular anatomical details which may be utilized to plan the surgical approach. Magnetic resonance angiography (MRA) is another useful diagnostic tool as well, which has the advantage that it avoids exposure to ionizing radiation and iodinated contrast. We also need to investigate the

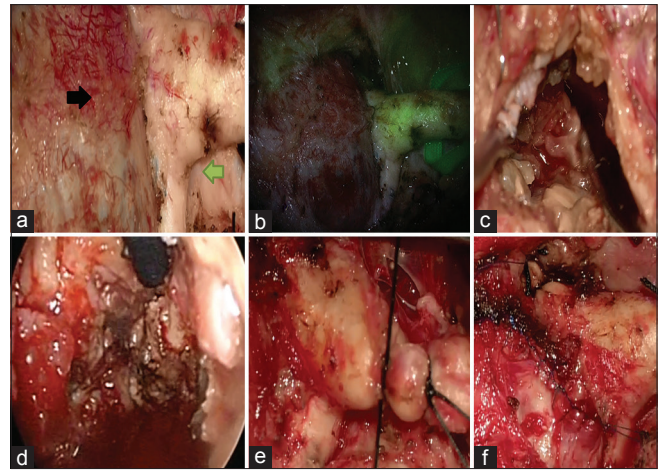


Figure 3: Intraoperative pictures (a) showing the aneurysm of the extracranial internal carotid artery and the common carotid artery. The black arrow shows the fusiform aneurysm of the extracranial internal carotid artery and Green arrow shows the extracranial internal carotid artery. (b) Showing the dual image video angiography. (c) Showing the intraluminal thrombus of the extracranial internal carotid artery aneurysm. (d) Showing the endoscopic view of intraluminal thrombus of extracranial internal carotid artery aneurysm. (e) Ligation of the extracranial carotid artery. (f) After the closure of the aneurysm sac

patient for the adequacy of cerebral circulation. It can be done by simple external digital compression of the carotid artery with neurologic monitoring (Matas test) or can be combined with a radiological study like MRA for enhancing accuracy.^[17] Conventional angiography with temporary balloon occlusion is an invasive option that has reasonable accuracy, although 10%–25% of those who passed this test still had a CVA with carotid artery ligation. Ninety percent of patients who have cerebral blood flow of <30 mls/100 g/h will have CVAs after carotid artery ligation.^[18]

Five different types of ECCA were defined based on the anatomy of an aneurysm:^[19] Type I: Isolated and short aneurysms of the ICA above the carotid bulb; Type II: Long aneurysms of the ICA, ranging from the carotid bulb up to the line of Blaisdell (the line between the mastoid process and angle of the mandible); Type III: Aneurysms of the proximal ICA and the carotid bifurcation; Type IV: Aneurysms involving the CCA and ICA as Type III, but extending far more distally and proximally; and Type V: Isolated aneurysms of the CCA.

de Jong *et al.* suggested an ECCA should be diagnosed when the diameter of the carotid bulb was 1.5 times that of the CCA.^[20] This definition is based on a study from Williams and Nicolaidis demonstrated that the diameter of the carotid bulb is on average 1.2 times larger than that of the CCA.^[21] The goal of any surgical intervention is to eliminate the risk of thromboembolic complications and/or rupture of an aneurysm. The first extracranial carotid aneurysm was described by Astley Cooper in 1836 and he performed ligation of the carotid artery. Hence, for a long-period ligation of the carotid artery was the method

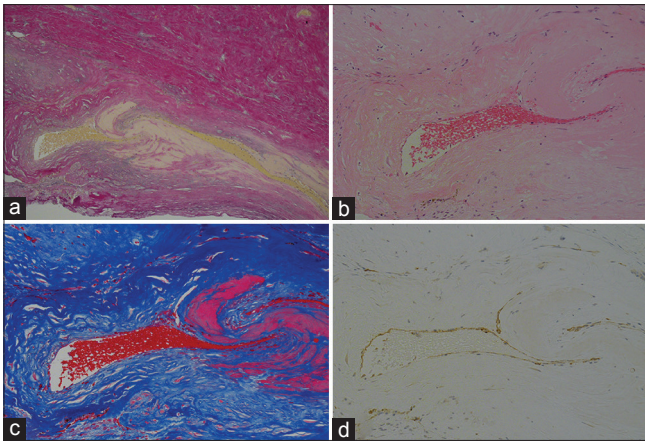


Figure 4: Histopathology pictures. (a-c) H and E stain and Elastica Masson is a stain section showing fragmentation of the internal elastic lamina, intramural hemorrhage, and neovascularization in the aneurysmal wall. (d) Immunohistochemistry with CD34 showing vasa vasorum

of choice until the early 1950s, in which a high stroke risk of approximately 30% was reported. By the 1970s, reconstruction of the carotid vessels had replaced ligation as a treatment option. Currently, surgical reconstructions and endovascular aneurysm exclusion are the two preferred treatments, and ligation is reserved for particular cases. The choice of a particular operative procedure is determined by the aneurysm size, location, and cause. Conservative management of EICA aneurysms has resulted in a mortality of nearly 71%.^[22] While rupture does occur, although rarely, the rationale for surgical intervention is based on brain preservation from thromboembolism, leading to disabling stroke and possible death. The tendency of small (3 cm) EICA aneurysms to embolize intraoperatively is low.^[23] The methods have obviously changed, but even with the increasing availability of endovascular options, open surgical repair remains a viable option. Garg *et al.* point out the five basic options of surgical management of the ECCA as aneurysm clipping, excision with primary anastomosis, excision with interposition graft, extracranial–intracranial bypass, and carotid ligation.^[12] Garg *et al.* reported a series with a 0% rate of stroke and death at 30 days and 7% rate of cranial nerve injuries. Li *et al.*^[24] reviewed 113 studies involving 224 patients submitted to endovascular repair of ECAA and reported a stroke rate of 1.8%, a cranial nerve injury rate of 0.5%, and an in-hospital mortality rate of 4.1%. Aneurysmectomy with the restoration of arterial continuity is the treatment of choice. In most cases, mobilization of the elongated and sometimes dilated arterial tree allows resection of an aneurysm with direct end-to-end anastomosis.^[25] Another modality of management is endovascular. The main goal of endovascular management is to exclude an aneurysm from the circulation with subsequent thrombosis within the sac while maintaining intra-arterial blood flow. Endovascular proximal occlusion methods are considered less invasive than carotid ligation and the two methods are regarded as equally useful.

Endovascular proximal occlusions were formerly performed with detachable balloons, but because of problems such as premature detachment, balloon rupture, early deflation, and distal migration indications for the use of balloons are now limited.^[26] During parent artery coil occlusion, both distal thromboembolic complications and distal migration of the coils can occur. Reintervention after repair of ECCAs has not been well reported. Srivastava *et al.* reported 10-year institutional experience with primary patency of 90% at 30 months.^[11] One patient presented at 4 months with TIAs and was found to have stenosis at the distal anastomosis that was treated with carotid angiography and stenting. Rosset *et al.* demonstrated one late occlusion at 14 months, which did not require an intervention.^[27] In this patient, we had to do the open surgical management of evacuation of the intraluminal thrombus by doing CEA and then ligation of the CCA as this patient has already undergone parent vessel occlusion by endovascular management, and the size of an aneurysm was growing despite the treatment and also the patient has good collateral circulation from the contralateral side.

Conclusion

EICA is uncommon and may be manifested with varying or no symptoms. All segments of the carotid artery are susceptible. Safety and long-term reliability of appropriate surgical treatment warrant broad surgical indication because of the risk of embolization and rupture of these aneurysms. Surgical treatment is feasible, with an acceptable rate of stroke and cranial nerve injuries, especially when an aneurysm is located on the CCA and carotid bulb. Endovascular therapy should be considered when treating aneurysms located in the distal ICA and in patients who are not good candidates for open surgery. In this article, we presented the case of a 69-year-old female with a proximal EICA aneurysm, successfully treated with surgical resection and ligation. Surgical repair is safe and can be undertaken with very acceptable perioperative complication rate and excellent long-term results.

Declaration of patient consent

The authors certify that they have obtained all appropriate patient consent forms. In the form the patient(s) has/have given his/her/their consent for his/her/their images and other clinical information to be reported in the journal. The patients understand that their names and initials will not be published and due efforts will be made to conceal their identity, but anonymity cannot be guaranteed.

Financial support and sponsorship

Nil.

Conflicts of interest

There are no conflicts of interest.

References

1. Brock RC. Astley cooper and carotid artery ligation. *Guys Hosp Rep* 1968;117:219-24.
2. Dimtza A. Aneurysms of the carotid arteries; report of two cases. *Angiology* 1956;7:218-27.
3. Beall AC Jr., Crawford ES, Cooley DA, Debakey ME. Extracranial aneurysms of the carotid artery. Report of seven cases. *Postgrad Med* 1962;32:93-102.
4. Liapis CD, Gugulakis A, Misiakos E, Verikokos C, Dousaitou B, Sechas M. Surgical treatment of extracranial carotid aneurysms. *Int Angiol* 1994;13:290-5.
5. Schechter DC. Cervical carotid aneurysms: Part I. *N Y State J Med* 1979;79:892-901.
6. Rittenhouse EA, Radke HM, Sumner DS. Carotid artery aneurysm. Review of the literature and report of a case with rupture into the oropharynx. *Arch Surg* 1972;105:786-9.
7. van Sambeek MR, Segeren CM, van Dijk LC, van Essen JA, Dippel DW, van Urk H. Endovascular repair of an extracranial internal carotid artery aneurysm complicated by heparin-induced thrombocytopenia and thrombosis. *J Endovasc Ther* 2000;7:353-8.
8. Bakoyiannis CN, Georgopoulos SE, Tsekouras NS, Klonaris CN, Skrapari IC, Papalambros EL, *et al.* Surgical management of extracranial internal carotid aneurysms by cervical approach. *ANZ J Surg* 2006;76:612-7.
9. Konno A, Togawa K, Iizuka K. Analysis of factors affecting complications of carotid ligation. *Ann Otol Rhinol Laryngol* 1981;90:222-6.
10. Cao P, Giordano G, De Rango P, Zannetti S, Chiesa R, Coppi G, *et al.* Eversion versus conventional carotid endarterectomy: Late results of a prospective multicenter randomized trial. *J Vasc Surg* 2000;31:19-30.
11. Srivastava SD, Eagleton MJ, O'Hara P, Kashyap VS, Sarac T, Clair D. Surgical repair of carotid artery aneurysms: A 10-year, single-center experience. *Ann Vasc Surg* 2010;24:100-5.
12. Garg K, Rockman CB, Lee V, Maldonado TS, Jacobowitz GR, Adelman MA, *et al.* Presentation and management of carotid artery aneurysms and pseudoaneurysms. *J Vasc Surg* 2012;55:1618-22.
13. El-Sabroun R, Cooley DA. Extracranial carotid artery aneurysms: Texas heart institute experience. *J Vasc Surg* 2000;31:702-12.
14. Royce PM, Steinmann BU. *Connective Tissue and its Heritable Disorders: Molecular, Genetic, and Medical Aspects.* New York: Wiley-Liss; 1993.
15. Zwolak RM, Whitehouse WM Jr., Knake JE, Bernfeld BD, Zelenock GB, Cronenwett JL, *et al.* Atherosclerotic extracranial carotid artery aneurysms. *J Vasc Surg* 1984;1:415-22.
16. McCollum CH, Wheeler WG, Noon GP, DeBakey ME. Aneurysms of the extracranial carotid artery. Twenty-one years' experience. *Am J Surg* 1979;137:196-200.
17. Hori M, Okubo T, Aoki S, Ishigame K, Araki T, Nukui H. The magnetic resonance matas test: Feasibility and comparison with the conventional intraarterial balloon test occlusion with SPECT perfusion imaging. *J Magn Reson Imaging* 2005;21:709-14.
18. Witt JP, Yonas H, Jungreis C. Cerebral blood flow response pattern during balloon test occlusion of the internal carotid artery. *AJNR Am J Neuroradiol* 1994;15:847-56.
19. Attigah N, Kulkens S, Zausig N, Hansmann J, Ringleb P, Hakimi M, *et al.* Surgical therapy of extracranial carotid artery aneurysms: Long-term results over a 24-year period. *Eur J Vasc Endovasc Surg* 2009;37:127-33.
20. de Jong KP, Zondervan PE, van Urk H. A new method of quantifying extracranial carotid artery aneurysms. *J Vasc Surg* 1989;10:103-4.
21. Williams MA, Nicolaides AN. Predicting the normal dimensions of the internal and external carotid arteries from the diameter of the common carotid. *Eur J Vasc Surg* 1987;1:91-6.
22. Jong KP, Rutherford RB, Tilson MD, Shah DM, Hollier L, Stanley JC. Suggested standards for reporting on arterial aneurysms. *Eur J Vasc Surg* 1989;3:557-62.
23. Ghilardi G, Massetto N, Cattalini C, Odero A, De Monti M, Gobatti D, *et al.* Brain involvement in extracranial internal carotid artery aneurysms. *Vasa* 2001;30:37-41.
24. Li Z, Chang G, Yao C, Guo L, Liu Y, Wang M, *et al.* Endovascular stenting of extracranial carotid artery aneurysm: A systematic review. *Eur J Vasc Endovasc Surg* 2011;42:419-26.
25. Kaupp HA, Haid SP, Jurayi MN, Bergan J, Trippel OH. Aneurysms of the extracranial carotid artery. *Surgery* 1972;72:946-52.
26. Serbinenko FA, Filatov JM, Spallone A, Tchurilov MV, Lazarev VA. Management of giant intracranial ICA aneurysms with combined extracranial-intracranial anastomosis and endovascular occlusion. *J Neurosurg* 1990;73:57-63.
27. Rosset E, Albertini JN, Magnan PE, Ede B, Thomassin JM, Branchereau A. Surgical treatment of extracranial internal carotid artery aneurysms. *J Vasc Surg* 2000;31:713-23.