

Atypical *Rickettsia japonica* Infection Involving Critical Illness Diagnosed by Metagenomic Next-Generation Sequencing: A Case Report

Zheng Yang, Zhanli Shi, Kun Fang, Danhong Ren

Department of Intensive Care Unit, Hangzhou Red Cross Hospital, Hangzhou, Zhejiang Province, 310003, People's Republic of China

Correspondence: Danhong Ren, Department of Intensive Care Unit, Hangzhou Red Cross Hospital, Hangzhou, Zhejiang Province, 310003, People's Republic of China, Email rendanhong330@zcmu.edu.cn

Background: *Rickettsia japonica* infection is a rare disease, it is rare to report critical and severe case caused by this disease in Zhejiang Province, China.

Patient Concerns: We report a patient who initially sought medical attention due to fever and developed coma and convulsions during treatment. The patient did not develop typical eschar and rash. Eventually, the patient needed to be treated in the intensive care unit due to acute respiratory failure.

Diagnoses: The patient was diagnosed with *Rickettsia japonica* bloodstream infection by metagenomic next-generation sequencing (mNGS).

Outcomes: Due to the critical illness, the patient was transferred to the intensive care unit, received doxycycline and other treatments, and rapidly recovered and discharged.

Conclusion: The patient developed a critical illness after being infected with *Rickettsia*, when the medical history is unclear and clinical symptoms and signs are atypical, it is necessary to use mNGS examination for diagnosis.

Keywords: rickettsia japonica, rickettsiosis, infection, metagenomic next-generation sequencing, critical illness

Introduction

Rickettsioses are infectious diseases caused by obligate intracellular gram-negative bacteria. They are classified into four groups: the spotted fever group (SFG), typhus group (TG), transitional group (TRG), and ancestral group (AG).¹ Japanese spotted fever (JSF; a SFG rickettsiosis), caused by *Rickettsia japonica*, first reported in Tokushima Prefecture, Japan, in 1984.^{2,3} This bacterium is a vector borne pathogen that is transmitted to humans through tick bites. *Rickettsia japonica* may not be easily detected by nucleic acid detection, especially when anti-rickettsial antibodies appear. In addition, there are some differences between the clinical characteristics of the onset in different regions. Therefore, various factors may lead to misdiagnosis, delay in starting treatment, and even lead to poor prognosis.^{4,5} Here, we report a case of atypical JSF diagnosed by metagenomic next-generation sequencing (mNGS)⁶ examination with severe complications.

Case Report

On April 19, 2022, an 83-year-old woman walked in the mountains and forests. On day three, she developed a high fever (maximum temperature 39.2°C), accompanied by chills, chest tightness, shortness of breath, cough, and fatigue. She did not pay attention at that time, did not seek medical attention, and the above symptoms did not alleviate. On April 22, 2022, she visited the fever clinic of a local hospital. Laboratory studies had shown normal white blood cells and thrombocytopenia. Her level of hs-CRP was 83.1mg/L. Cardiac troponin I was negative. The attending doctor considered pulmonary infection, an empirical therapy of ceftazidime was administered intravenously. However, the patient

complained that her temperature still fluctuated, and she developed cough symptoms and increased shortness of breath. On April 28, 2022, the patient had no choice but to go to the emergency department of our hospital.

The chest CT of the patient was suggestive of interstitial pneumonia, a small right pleural effusion. Subsequently, she was admitted to the respiratory department of our hospital. After admission, the attending physician conducted a general physical examination of the patient, but no abnormality was found. Due to the lack of evidence of pathogenic bacteria, respiratory doctors gave the patient positive attention, but the condition did not improve. On April 30, 2022, the patient underwent oral tracheal intubation due to deterioration of consciousness and acute respiratory failure, and was transferred to the ICU for continued treatment after intubation.

The patient had a brief convulsion during admission to the intensive care unit, that night, we received the results of the mNGS test indicating that the patient was infected with *Rickettsia japonica*, nevertheless, exanthemata and eschar were not found throughout the patient's body. We gave the patient doxycycline (100mg/day) orally. The next day, her fever and other symptoms started to decline and subsided without any complications, after evaluation, the empirical anti-infection treatment plan was gradually reduced. During ICU treatment, she was in septic shock causing multiorgan failure, she required intravenous catecholamine for shock state, artificial ventilation for respiratory failure, and hemodialysis for acute kidney injury. Intravenous cefoperazone/sulbactam was used for targeted treatment of multidrug resistant *Acinetobacter baumannii* pneumonia. After active treatment, the patient left the ICU on May 23, 2022. Additional adjunctive therapies are presented in Figures 1 and 2.

The patient was successfully discharged from the hospital and expressed her gratitude to the doctors and nurses of the treatment team. No abnormalities were observed during follow-up.

The mNGS Test Methods

Specimens (3 mL) used for mNGS were collected in sterile containers, which were then sealed and placed in a foam box containing an ice pack. Specimens were then immediately transported to a commercial laboratory (Vision Medicals) for pathogen testing. Once the laboratory received the specimens, sample processing, nucleic acid extraction, DNA library preparation, high-throughput sequencing, bioinformatics analysis, and the interpretation of mNGS data were performed according to the laboratory's standard operating procedures. To detect the pathogens as much as possible, DNA and RNA sequencing were performed simultaneously. Finished libraries were quantified by real-time PCR (KAPA) and pooled. Shotgun sequencing was carried out on illumina Nextseq. Approximately 20 million of 50bp single-end reads were generated for each library. Bioinformatic analysis was conducted as described in a previous report. Briefly, sequences of human origin were filtered (GRCh38.p13) and the remaining reads were aligned to a reference database (NCBI nt, GenBank and in-house curated genomic database) to identify the microbial species and read count. For each sequencing run, a negative control (culture medium containing 104 Jurkat cells/mL) was included.

mNGS Reporting Criteria

Microbial reads identified from a library were reported if: 1) the sequencing data passed quality control filters (library concentration > 50 pM, Q20 > 85%, Q30 > 80%); 2) negative control (NC) in the same sequencing run does not contain

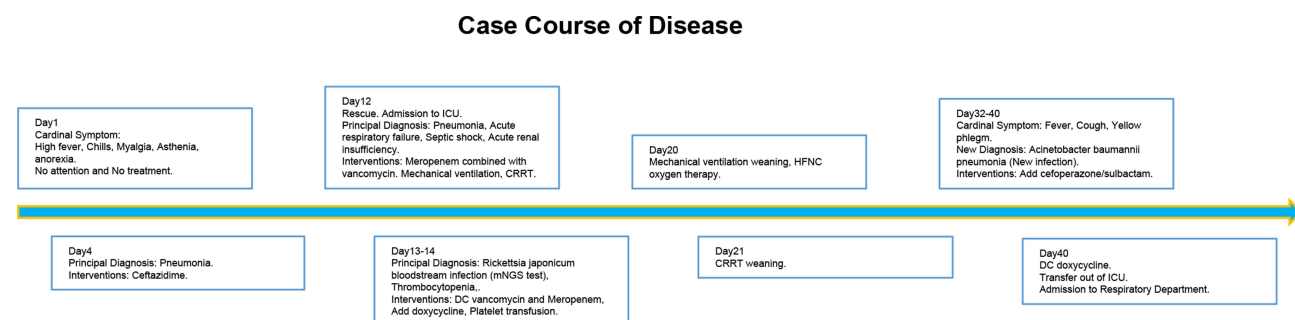


Figure 1 Course of Disease.

Abbreviations: DC, discontinue; CRRT, continuous renal replacement therapy; ICU, intensive care units; mNGS, metagenomic next-generation sequencing; HFNC, high-flow nasal cannula.

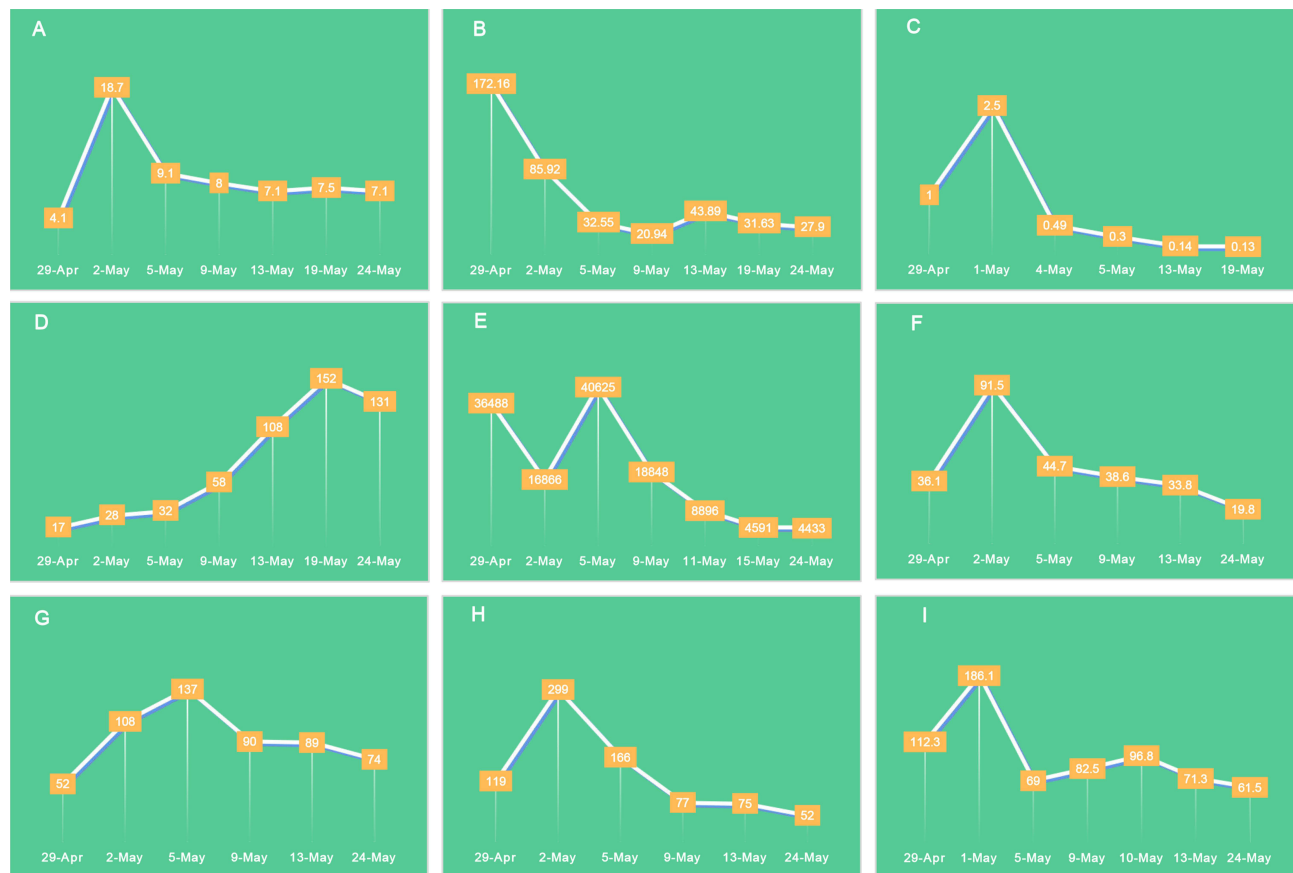

Figure 2 (A) The tendency of white blood cell value ($10^9/L$) during hospital stays. (B) The tendency of high-sensitivity C-reactive protein value (mg/L) during hospital stays. (C) The tendency of procalcitonin value (ng/mL) during hospital stays. (D) The tendency of platelet value ($10^9/L$) during hospital stays. (E) The tendency of D-dimer value ($\mu g/L$) during hospital stays. (F) The tendency of total bilirubin value ($\mu mol/L$) during hospital stays. (G) The tendency of alanine aminotransferase value (U/L) during hospital stays. (H) The tendency of aspartate aminotransferase value (U/L) during hospital stays. (I) The tendency of serum creatinine value ($\mu mol/L$) during hospital stays.

the species or the RPM (sample) / RPM (NC) ≥ 5 , which was determined empirically according to previous studies as a cutoff for discriminating true-positives from background contaminations.

Discussion

Our case was believed to be a severe infection caused by JSF, with convulsions and confusion. In most cases, JSF only causes mild symptoms, however, we have found that if JSF was not promptly recognized and effective antimicrobial was not initiated early, serious manifestations may occur. As we reported, patient developed severe illness requiring treatment in the intensive care unit, and was not diagnosed in a timely manner in the early stages of the disease. The diagnosis and treatment of patient was a challenge for doctors, especially when the patient did not have typical exanthema and eschar.

The clinical manifestation of human infection with JSF is similar to that of scrub typhus.² It is mainly caused by the bite of tick-carrying *Rickettsia japonica*, and the onset is seasonal, usually from early summer to autumn.⁴ JSF typically exhibits high fever, erythema, eschar, elevated levels of white blood cells, C-reactive protein, liver enzymes, and thrombocytopenia can be observed in laboratory tests.⁷⁻⁹ Individual cases of disseminated intravascular coagulation (DIC) and multiple organ dysfunction caused by JSF have been reported in the past.^{4,5} A case series had reported six severe cases of rapid progression to DIC and multiple organ failure, including one fatal case and two cases of fulminant purpura.⁵ Therefore, early diagnosis and treatment are necessary. The patient we reported failed to receive diagnosis and treatment at the earliest stage of the disease, and subsequently obtained good prognosis after rapid mNGS examination to identify the pathogenic bacteria and active treatment. After discussion, our team believes that when the patient's pathogenic evidence is unclear and the condition progresses rapidly after standardized anti-infection treatment, especially when considering special pathogen infections (such as *rickettsia*), relevant mNGS testing should be sent for testing as soon as possible.

To our knowledge, only 11 cases of JSF involving the central nervous system have been described as aseptic meningoenkephalitis. All of the 11 patients developed consciousness disorders or loss of consciousness, and 5 of them also developed convulsions. All patients developed central nervous system symptoms before starting to use antimicrobial drugs to treat JSF. The existing imaging results show that except for 2 patients who were found to have cerebrovascular accidents, other patients have no abnormalities.^{10,11} Our patient was similar to previous cases in that she experienced loss of consciousness and convulsions. Unfortunately, we did not test the patient's cerebrospinal fluid.

Correct identification and treatment of rickettsial disease can effectively prevent critical illness and unnecessary deaths,³ while reducing the use of broad-spectrum antibacterial drugs, especially beta-lactam antibiotics, which are ineffective against rickettsial infection.¹² Doxycycline, minocycline hydrochloride, and fluoroquinolone are effective treatments for JSF.¹³ Early clinical diagnosis is crucial for preventing disease progression. The therapeutic effect of doxycycline used in our case is also significant, and has been confirmed in several case reports.

Conclusion

Rickettsia japonica is a neglected zoonotic pathogen that can be life-threatening if not effectively treated. When receiving patients with fever of unknown origin, and the medical history is unclear and clinical symptoms and signs are atypical, it is necessary to use mNGS examination for diagnosis.

Data Sharing Statement

The datasets generated during and/or analyzed during the current study are available from the corresponding author on reasonable request.

Ethics Statement

The studies involving human participant was reviewed and approved by Medical Ethics Committee of Hangzhou Red Cross Hospital. The patient/participant provided their written informed consent to participate in this study.

Acknowledgments

We are grateful to the patient and her families for their invaluable contributions to this study. We wish to thank the help given by the physicians who participated in this study and the professionals involved in sample collection and culture maintenance.

Author Contributions

All authors made a significant contribution to the work reported, whether that is in the conception, study design, execution, acquisition of data, analysis and interpretation, or in all these areas; took part in drafting, revising or critically reviewing the article; gave final approval of the version to be published; have agreed on the journal to which the article has been submitted; and agree to be accountable for all aspects of the work.

Funding

This work was supported by Guiding project of Hangzhou Science and Technology Bureau (No. 20220919Y033).

Disclosure

The authors declare that the research was conducted in the absence of any commercial or financial relationships that could be construed as a potential conflict of interest.

References

1. Helminiak L, Mishra S, Kim HK. Pathogenicity and virulence of rickettsia. *Virulence*. 2022;13(1):1752–1771. doi:10.1080/21505594.2022.2132047
2. Mahara F, Koga K, Sawada S, et al. わが国初の紅斑熱リケツチア感染症[The first report of the rickettsial infections of spotted fever group in Japan: three clinical cases]. *Kansenshogaku Zasshi*. 1985;59(11):1165–1171. Japanese. doi:10.11150/kansenshogakuzasshi1970.59.1165

3. Li H, Zhang PH, Du J, et al. Rickettsia japonica infections in Humans, Xinyang, China, 2014–2017. *Emerg Infect Dis.* 2019;25(9):1719–1722. doi:10.3201/eid2509.171421
4. Nakata R, Motomura M, Tokuda M, et al. A case of Japanese spotted fever complicated with central nervous system involvement and multiple organ failure. *Intern Med.* 2012;51(7):783–786. doi:10.2169/internalmedicine.51.6214
5. Gao S, Li L, Zhou X, et al. Fatal rickettsia japonica infection complicating disseminated intravascular coagulation in Yichang, China. *Infect Drug Resist.* 2022;15:6613–6623. doi:10.2147/IDR.S383917
6. Gu W, Miller S, Chiu CY. Clinical metagenomic next-generation sequencing for pathogen detection. *Annu Rev Pathol.* 2019;14:319–338. doi:10.1146/annurev-pathmechdis-012418-012751
7. Lu Q, Yu J, Yu L, et al. Rickettsia japonica Infections in Humans, Zhejiang Province, China, 2015. *Emerg Infect Dis.* 2018;24(11):2077–2079. doi:10.3201/eid2411.170044
8. Seki M, Ikari N, Yamamoto S, et al. Severe Japanese spotted fever successfully treated with fluoroquinolone. *Intern Med.* 2006;45(22):1323–1326. doi:10.2169/internalmedicine.45.1831
9. Noguchi M, Oshita S, Yamazoe N, Miyazaki M, Takemura YC. Important clinical features of Japanese Spotted Fever. *Am J Trop Med Hyg.* 2018;99(2):466–469. doi:10.4269/ajtmh.17-0576
10. Araki M, Takatsuka K, Kawamura J, Kanno Y. Japanese spotted fever involving the central nervous system: two case reports and a literature review. *J Clin Microbiol.* 2002;40(10):3874–3876. doi:10.1128/JCM.40.10.3874-3876.2002
11. Wada T, Mori H, Kida K, Shindo K. Japanese spotted fever with post-infectious encephalitis. *IDCases.* 2023;31:e01658. doi:10.1016/j.idcr.2022.e01658
12. Huemer M, Mairpady SS, Brugger SD, Zinkernagel AS. Antibiotic resistance and persistence—Implications for human health and treatment perspectives. *EMBO Rep.* 2020;21(12):e51034. doi:10.15252/embr.202051034
13. Tai K, Iwasaki H, Ikegaya S, et al. Significantly higher cytokine and chemokine levels in patients with Japanese spotted fever than in those with Tsutsugamushi disease. *J Clin Microbiol.* 2014;52(6):1938–1946. doi:10.1128/JCM.03238-13

Infection and Drug Resistance

Dovepress

Publish your work in this journal

Infection and Drug Resistance is an international, peer-reviewed open-access journal that focuses on the optimal treatment of infection (bacterial, fungal and viral) and the development and institution of preventive strategies to minimize the development and spread of resistance. The journal is specifically concerned with the epidemiology of antibiotic resistance and the mechanisms of resistance development and diffusion in both hospitals and the community. The manuscript management system is completely online and includes a very quick and fair peer-review system, which is all easy to use. Visit <http://www.dovepress.com/testimonials.php> to read real quotes from published authors.

Submit your manuscript here: <https://www.dovepress.com/infection-and-drug-resistance-journal>