



HHS Public Access

Author manuscript

Lab Invest. Author manuscript; available in PMC 2011 July 01.

Published in final edited form as:

Lab Invest. 2011 January ; 91(1): 138–146. doi:10.1038/labinvest.2010.137.

Development of thyroid gland and ultimobranchial body cyst is independent of p63

Takashi Ozaki^{1,2}, Kunio Nagashima³, Takashi Kusakabe^{1,4}, Kennichi Kakudo², and Shioko Kimura^{1,*}

¹Laboratory of Metabolism, National Cancer Institute, National Institutes of Health, Bethesda, MD 20892, USA

²Department of Pathology, Wakayama Medical University, Wakayama City, Wakayama 641-8509, Japan

³Advanced Technology Program, SAIC-Frederick, INC., NCI-Frederick, Frederick, MD 21702-1201, USA

Abstract

The ultimobranchial body (UBB) and thyroid primordium are the origins of the thyroid gland that fuse around embryonic day 14.5 of mouse gestation, ultimately giving rise to calcitonin-producing C cells and thyroglobulin-producing follicular cells, respectively. A homeodomain transcription factor NKX2-1 is expressed both in the UBB and the thyroid primordium, and is critical for development of the thyroid gland. In the present study, the role of p63 in development of UBB and the thyroid gland was investigated by histological, immunohistochemical, and electron microscopic analyses using mice with various combinations of *Nkx2-1* and *p63* wild-type, heterozygous, and null alleles. In the absence of p63, a normal thyroid gland develops, as revealed by expression of thyroglobulin and calcitonin, thus demonstrating that p63 is not required for thyroid development. However, in mice carrying the *Nkx2-1*-null allele, the UBB remains as a cystic vesicular structure and/or in nested patterns consisting of p63-positive cells surrounding the vesicle and undifferentiated immature cells with occasional cilia lying inside. The cystic UBB was present even in the *Nkx2-1;p63* double-null mice. The structure and p63 expression pattern of the UBB cyst strikingly resemble the solid cell nest (SCN). These results demonstrate that in the absence of NKX2-1, UBB becomes cystic independent of p63, which is likely the origin of SCN.

Keywords

NKX2-1; solid cell nest; knockout mouse; undifferentiated cells; histochemical analysis; electron microscopy

Users may view, print, copy, download and text and data- mine the content in such documents, for the purposes of academic research, subject always to the full Conditions of use: http://www.nature.com/authors/editorial_policies/license.html#terms

*Address all correspondence to: Shioko Kimura, Ph.D., Laboratory of Metabolism, National Cancer Institute, Building. 37, Room 3106, Bethesda, MD 20892, Tel: 301-496-0958, Fax: 301-496-8419, kimuras@mail.nih.gov.

⁴Current address: Department of Pathology, Aizu Chuo Hospital, the Onchikai Foundation, Aizu-wakamatsu, Fukushima 965-8611, Japan

DISCLOSURE/CONFLICT OF INTEREST

The authors declare no conflict of interest.

INTRODUCTION

The thyroid gland of mammals has two distinct cell types: follicular cells and C cells.¹⁻⁴ The follicular cells are derived from the thyroid primordium, outpocketing of the foregut endoderm that loses its connection to the foregut tube and subsequently descends in front of the pharyngeal gut as a bilobed diverticulum. The follicular cells eventually synthesize and secrete thyroid hormones. On the other hand, C cells, or parafollicular cells are derived from the ultimobranchial body (UBB) that migrates from the fourth pharyngeal pouch to which neural crest cells have invaded. The UBB fuses with the thyroid primordium around mouse embryonic day (E) 14.5, and the cellular components of the UBB disseminate within the thyroid, ultimately giving rise to the calcitonin-producing C cells.¹⁻⁵ From the analogy to chick ultimobranchial C cells in the ultimobranchial gland which express neuronal markers⁶ and extend long neurite-like processes when cultured⁷, it is generally believed that the C cells in mammals also originate from the neural crest cells. However, it was recently demonstrated that murine thyroid C cells are derived from the endodermal epithelial cells of the fourth pharyngeal pouch that expresses E-cadherin and do not originate from the neural crest cells⁸.

NKX2-1 (TTF1, TITF1, T/EBP, NKX2.1)^{9, 10} is a homeodomain transcription factor that is critical for the genesis of the thyroid, lung and ventral forebrain.¹¹ It is also essential for the regulation of lung and thyroid-specific expression of genes, the latter of which includes those encoding thyroglobulin and thyroid peroxidase.^{2, 12} NKX2-1 is expressed in the thyroid primordium and it is required for the maintenance of ordered architecture and function of the differentiated thyroid.¹³ NKX2-1 is also expressed in the UBB rudiment,^{5, 11, 14, 15} and is responsible for the survival of the UBB cells and their dissemination into the thyroid diverticulum.⁵ In *Nkx2-1*-null mice, the thyroid primordium starts degenerating around E10.5 before the commencement of its caudal migration¹⁶ while the UBB remains as a cystic vesicular structure after NKX2-1-positive cells disintegrate.⁵ This vesicular structure is lined by a monolayer of p63-negative cells, surrounded by a cluster and/or single layer of p63-positive cells.⁵ The vesicular structure resembles the solid cell nests (SCN) described in humans that contain both solid cell proliferation and follicular-like structures, and has been considered to be the embryonic remnants of the UBB.¹⁷⁻²⁰ SCNs are reported to be found in normal human fetal thyroid with approximately 32.5 % in multi-step sections and 87.5 % in serial sections.²¹

P63 is a member of the p53 tumor suppressor family, which consists of several isoforms having full-length (TAp63) and N-terminal truncated forms (Np63) as well as having three alternative splicing at the C-terminus (α , β , γ).²² TAp63 α is the predominant isoform expressed in human thyroid cancer specimens and cell lines, while normal human thyroids do not express p63.²³⁻²⁵ P63 is used as a marker for the main cells of the solid cell nests (SCN) in humans.^{18-20, 24} P63 is also expressed in a subset of papillary thyroid carcinomas and/or Hashimoto's thyroiditis, often associated with SCN, suggesting a possible link between p63 expression, papillary thyroid cancer, Hashimoto's thyroiditis and SCN.^{18, 25-27}

In the present study, the role of p63 in thyroid development and the nature of UBB cysts were examined using embryos with various combinations of *p63* and *Nkx2-1* alleles (wild-type, heterozygous, and null) by histological and immunohistochemical methods, and electron microscopy. The results demonstrated that p63 is not required for thyroid development and the UBB rudiment remains as a cystic and/or vesicular structure even without *Nkx2-1* nor *p63* alleles, which consists of one layer of cells that appear to be very poorly differentiated.

MATERIALS AND METHODS

Animals

p63(+/-);*Nkx2-1*(+/-) mice (C57BL/6J background) were established by crossing *Nkx2-1*(+/-) mice¹¹ with *p63*(+/-) mice, both of which had been backcrossed 6 times to C57BL/6J mice. The *p63*(+/-) mice were produced by mating *p63*(*fl/fl*) mice (kindly provided by Dr. Alea Mills²⁸) with EIIa-Cre transgenic mice.²⁹ Animals were maintained under conditions outlined in the “Guide for the Care and Use of Laboratory Animals” by the National Institutes of Health. Different genotypes of embryos in nine combinations were obtained at embryonic day (E) 12.5, 14.5, 17.5, and 18.5 by intercrossing *Nkx2-1*(+/-);*p63*(+/-) mice. A noon of the day when a vaginal plug was observed was considered as E 0.5. The genotypes of embryos used in this study were as follows (tentative name shown in the parenthesis); *p63*(+/+);*Nkx2-1*(+/+) (wild-type), *p63*(+/+);*Nkx2-1*(+/-) (*Nkx2-1*-Ht), *p63*(+/+);*Nkx2-1*(-/-) (*Nkx2-1*-null), *p63*(+/-);*Nkx2-1*(+/+) (*p63*-Ht), *p63*(+/-);*Nkx2-1*(+/-) (*p63*; *Nkx2-1*-dHt), *p63*(+/-);*Nkx2-1*(-/-) (*p63*-Ht; *Nkx2-1*-null), *p63*(-/-);*Nkx2-1*(+/+) (*p63*-null), *p63*(-/-);*Nkx2-1*(+/-) (*p63*-null; *Nkx2-1*-Ht), and *p63*(-/-);*Nkx2-1*(-/-) (*p63*; *Nkx2-1*-d null).

Genotyping was performed by PCR using DNAs isolated from yolk sacs or tails with the following conditions: 1 cycle for 3 min at 94°C, 30 cycles for 30 sec at 94°C, 15 sec at 60°C, 15 sec at 72°C, and 1 cycle for 5 min at 72°C. The primers used were 5'-GGC GAG CGG CAT GAA TAT GA-3' (forward) and 5'-TCT TGT AGC GGT GGT TCT GGA-3' (reverse) for *Nkx2-1* wild-type allele, and 5'-TCG CCT TCT ATC GCC TTC TTG A-3' was paired with the reverse primer for the detection of the *Nkx2-1* targeted allele. The primers for detection of *p63*(+/-) allele were 5'-CAG AGG AGG CAA CAC AGG ATA GA-3' and 5'-CCG GGG GAT CCG AAT TCA TCG A-3'.²⁸ The loxP sites of *p63*(*fl/fl*) allele flank exons in the DNA-binding domain of p63, thus rendering all isotypes of p63 inactive in the presence of active Cre recombinase.²⁸

Histopathological examination

Histological analysis was carried out using at least three embryos or adult thyroids from each genotype and/or developmental stage. A whole embryo or a cervical region of an adult mouse containing the thyroid, larynx and trachea was dissected, fixed in 4% paraformaldehyde in 0.1 M phosphate buffered saline (PBS) at 4°C overnight, dehydrated, and embedded in paraffin. Serial sections of 3 μm thickness were prepared, which were treated with xylene and graded ethanol, and were stained with hematoxyline and eosin (H&E). Disruption of the *p63* gene was confirmed by the presence of aplastic skin in *p63*(-/-) mice from E14.5 to post partum as described.³⁰

Immunohistochemistry

Sections were treated with 1% hydrogen peroxide in methanol for 30-45 minutes to block endogenous peroxidase activity, followed by rinsing three times for 10 min each with PBS. Epitope retrieval was carried out by heating sections at 100°C for 3 minutes, 5 times using a microwave oven in 10 mM citrate buffer, pH 6.0, followed by cooling for 30 minutes at room temperature, and washing in PBS. Sections were then treated with 5% skim milk in PBS for 15 minutes to block nonspecific protein binding. Incubation with primary antibody was carried out overnight at 4°C in a humidified chamber using the following antibodies: anti-p63 antibody (mouse monoclonal, 1:1,000 dilution; BD Biosciences, San Diego, CA), anti-TTF-1 antibody (mouse monoclonal, 1:1,000 dilution; DAKO, Carpinteria, CA), anti-SOX10 antibody (rabbit polyclonal, 1:1,000 dilution; Abcam, Cambridge, MA), anti-Nestin antibody (rabbit polyclonal, 1:1,000 dilution; Abcam), anti-NSE antibody (goat polyclonal, 1:200 dilution, DAKO), anti-S-100 antibody (mouse monoclonal, 1:3,000 dilution, Abcam) and anti-calcitonin antibody (rabbit polyclonal, 1:1,000 dilution, ICN, Irvine, CA). After washing in 0.01 M PBS, the sections were treated using labeled streptavidin-biotin method (LSAB2 System-HRP, ready-to-use, DAKO) or the ABC method with commercially available kit (Vector Laboratories, Burlingame, CA) according to the manufacturer's instructions. Immunocomplexes were visualized with 3,3'-diaminobenzidine tetrahydrochloride (Sigma, St Louis, MO, USA).

Electron microscopy (EM)

The tissue sample preparation for the EM analysis has been described in a great detail. 31 Briefly, mouse tissue was fixed in formaldehyde (4%) and glutaraldehyde (2%) in cacodylate buffer (0.1M, pH 7.4) (Tousimis, Rockville, MD) followed by a post fixation in 1% osmium in same buffer. The tissue was *en bloc* stained in 0.5% uranyl acetate in acetate buffer (0.1M pH 4.5) and dehydrated in a graded ethanol (35%, 50%, 70%, 95%, and 100%) and propylene oxide. The infiltration was done in an equal mixture of epoxy resin (Embed 812, Electron Microscope Sciences, Fort Washington, PA) and propylene oxide overnight. The tissue was embedded in a pure epoxy resin and cured in 55°C oven. Thin sections were mounted on copper grids and stained in uranyl acetate and lead citrate. The grids were examined in the EM (Hitachi H7600, Tokyo, Japan) operated at 80kV and digital images were taken by CCD camera (AMT, Danvers, MA).

RESULTS

We previously demonstrated using *Nkx2-1*-null mice that the thyroid primordium disintegrates in the absence of NKX2-1.11, 16 Because p63 is used as a marker for the solid cell nest (SCN) in humans that is considered to be embryonic remnant of UBB,^{19, 20, 23} the role of p63 in development of UBB and/or thyroid was examined using mice with various combinations of *p63* and *Nkx2-1* alleles (wild-type, Ht, and null). The presence of UBB was confirmed in all genotyped mice at E12.5 (Figure 1). The UBB was composed of columnar cells having high nucleus/cytoplasm ratio, which configured the tubular or cystic patterns. At this gestational stage, the size of UBB was not significantly different among wild-type (Figure 1a), *Nkx2-1*-Ht (Figure 1d) and *Nkx2-1*-null mice (Figure 1g) as previously described.⁵ Similarly, p63 did not seem to have a significant effect on the size of UBB

(Figure 1a-f). In contrast, the UBB appeared to look slightly smaller in *p63* and *Nkx2-1*-double null mutants (Figure 1i). All the UBBs were histologically indistinguishable. These results indicate that the development of UBB does not require either NKX2-1 or *p63*.

By E14.5 of mouse gestation, thyroid primordium cells meet with UBB cells, forming the thyroid gland.¹⁻⁵ Indeed, both wild-type and *Nkx2-1*-Ht mice formed a thyroid gland composed of cells in trabecular or microfollicular patterns, regardless of the presence of the *p63* allele (Figure 2a-f). As gestation proceeded, the thyroids from six different combinations of *Nkx2-1* (wild-type and Ht) and *p63* alleles (wild-type, Ht, and null) further increased in size, and by E18.5, many immature follicles of small and/or various sizes were clearly visible, in which colloid was present (Figure 3a-f). No significant histological differences in terms of size, follicle formation, and the presence of C-cells were found among these six different genotype thyroids. Since the thyroid primordium of *Nkx2-1*-null mice starts degenerating around E10.5,¹⁶ no thyroid with follicular forming cells and C-cells was found in mice carrying *Nkx2-1*-null allele. Instead, the UBB remained in tubular or cystic patterns, which was found even in the *p63*;*Nkx2-1*-double null mutants (Figure 2g-i, 3g-l). By E18.5, the UBB consisted of increased number of cells (Figure 3g-i vs. j-l), which appeared dilated with monolayer of cells in tubular structure in the *p63*;*Nkx2-1*-double null embryos (Figure 3i). Occasionally ciliated cells were found in the UBB cysts (Figure 3g-l). These results demonstrate that *p63* is not required for the development of thyroid gland and further suggest that cells in the *p63*;*Nkx2-1*-double null UBB cyst resemble to those found in the SCN having occasional cilia.¹⁸⁻²⁰

In order to examine whether *p63* plays any role in the function of thyroid, E17.5 embryonic thyroids from wild-type, *p63*-Ht and *p63*-null mice were subjected to immunohistochemistry for thyroglobulin and calcitonin (Figure 4). Thyroid starts producing thyroid hormone around E15.2, ¹² Thyroglobulin was highly expressed in the thyroids of wild-type, and *p63*-Ht and null mice at similar immunohistochemical intensity. (Figure 4a-c). Further, calcitonin was clearly detected in parafollicular cells of all three thyroids at similar extent (Figure 4d-f). These results demonstrate that *p63* may not be essential for the function of thyroid.

In order to further characterize the UBB cysts, expression of *p63* was next examined. It was reported that NKX2-1 is strongly expressed in the UBB of normal mouse embryos at E11.5-13.5,^{5, 11, 14, 15} while *p63*-positive cells are scarce.⁵ In *Nkx2-1*-null mice, *p63* expression was detected in a very small number of cells in E12.5 UBB (Figure 5a), while the expression was found in more cells as the gestational age increased (Figure 5b, c, e, f). At later gestational ages, the *p63*-expressing cells were located either at the outer layer surrounding the vesicular structure (Figure 5b, c, e, f) or uniformly situated in the cystic structure (Figure 5e). This compartmentalized *p63* staining is strikingly similar to those found in the SCN.¹⁸⁻²⁰ No expression of *p63* was observed in the UBB cysts in mice carrying *p63*-null allele as expected (Figure 5d, g). Note that low levels of *p63* expression were found in normal mouse thyroids (Figure 5h). This was in contrast to humans, in which no expression of *p63* was reported.²³⁻²⁵

In order to further characterize the *p63*;*Nkx2-1*-double null UBB cysts, immunohistochemistry was next carried out using antibodies for NSE (neuron-specific

enolase) and S100 as neuron-specific markers, Oct 4 as a stem cell marker, nestin and SOX10 as a neural crest marker, and vimentin as a mesenchymal marker. Positive staining was not found with any of the antibodies examined in E12.5, 14.5, and 17.5 embryos (data not shown). When E14.5 *p63;Nkx2-1*-double null UBB was subjected to electron microscopic examination, irregular shaped cells with scarce cytoplasm and fairly modestly electron dense nucleus were found (Figure 6b). Further, no clear intracellular organelles nor adhesion structures were found. This was in sharp contrast to wild-type thyroid follicular cells, in which mitochondria, rough endoplasmic reticulum, tight junction and desmosome were clearly observed. (Figure 6a). These results demonstrate that cells in the *p63;Nkx2-1*-double null UBB are very poorly developed.

DISCUSSION

In this study, we demonstrated using mice with various combinations of *p63* and *Nkx2-1* alleles, that *p63* is not required for thyroid development and function. Further, UBB remains as a tubular structure even without *Nkx2-1* and *p63* alleles, whose cells are poorly developed as demonstrated by electron microscope. This indicates that UBB consists of three types of cells; those expressing NKX2-1 and *p63*, and immature cells not expressing either gene. Since calcitonin is expressed in *p63*-null mouse thyroids, NKX2-1-positive UBB cells may be the origin of C cells. In fact, the expression of NKX2-1 was previously reported in C cells.³² Sometimes, ciliated cells are found in the UBB cells. In the presence of *p63* as found in the *Nkx2-1*-null and *p63-Ht;Nkx2-1*-null mice, the cystic structure of UBB is surrounded by *p63*-positive outer layer of cells, which sometimes continued to *p63*-positive cells in nested pattern. This compartmentalized *p63*-positive structure strikingly resembles the SCN in humans. The SCN is present in most human thyroids.²¹ It contains both solid cell proliferation and cyst-like structures, having strong *p63*-positive cells at the periphery with centrally located *p63*-negative cells of unknown phenotype.¹⁸⁻²⁰ The occasional presence of ciliated cells is noted.¹⁸⁻²⁰ Furthermore, the presence of second kind of follicle in so-called mixed follicles has been known for decades in normal rats and mice.³³ This second kind of follicle is characterized by a nonhomogeneous or foamy colloid and the presence of occasional ciliated cells,³³ and is thought to originate from the UBB.³⁴ Taken together, the *p63;Nkx2-1*-double null UBB cyst may indeed be the origin of SCN in humans and the second kind of follicles in rats and mice.

The *p63;Nkx2-1*-double null UBB cells appeared to be undifferentiated at least when examined at E14.5 by electron microscope. In particular, the presence of scarce narrow cytoplasm (high ratio of nucleus/cytoplasm) and moderately electron dense nucleus with clumps of nuclear heterochromatin is reported for immature cells and undifferentiated ES cells.³⁵⁻³⁷ This could be the reason that no positive immunoreactivity was obtained with the antibodies examined (NSE, S100, Oct 4, nestin, SOX10, and vimentin). Thus, the *p63;Nkx2-1*-double null UBB cells may represent immature stem-like cells. If they are stem-like cells, one may expect the expression of Oct 4. However, Oct 4 expression was not detected in the *p63;Nkx2-1*-double null UBB cells by immunohistochemistry. Oct 4 protein is expressed in embryonic/primordial germ and embryonic stem cells. Although some reports have described Oct 4 expression in adult normal stem cells and tumors, they are mainly

determined by RT-PCR, but not by detection of protein such as immunohistochemistry or western blotting.^{38, 39}

The undifferentiated UBB cells may correspond to cells found in SCN that were described by Burstein, et al as centrally located p63-negative cells of unknown phenotype.¹⁸ Previously, electron microscopic study demonstrated that many desmosomes and hemidesmosomes are present in SCN, however these cell adhesion structures and their cytoplasmic organelle are poorly developed.⁴⁰ Since p63 is used as a marker for the solid cell nests (SCN),^{18-20, 24} it seems that the undifferentiated UBB cells are always associated with the p63-positive cells. In this regard, it is interesting to note that p63 is expressed in the basal/stem cells of several types of epithelia such as skin, esophagus, urethra, and secretory epithelial tissues including lacrimal, mammary, and prostate glands.⁴¹⁻⁴⁶ Based on these studies together with those of p63-null mice,^{41, 42} it was proposed that p63 plays a role in commitment, maintenance, and differentiation of epithelial cells. It was reported that a subset of papillary thyroid carcinoma and Hashimoto's thyroiditis are often associated with the SCN and express high levels of p63.^{18, 22, 25-27} Further, ciliated cells are occasionally identified in some histological types of follicular cell neoplasms.⁴⁷ Whether the basal/stem cell characteristics of p63-expressing cells together with the associated undifferentiated cells play any role in the pathogenesis of SCN-associated lesions such as papillary thyroid carcinoma and Hashimoto's thyroiditis requires further experimentation.

Based on the fact that almost all normal human fetal thyroids have SCN,²¹ at least two questions arise. Why and for what purpose do the SCN originating from cystic UBB cells remain in the thyroid, and whether they stay dormant throughout adult life or disintegrate at some point, most notably after birth. What is the nature of the undifferentiated UBB cells? Additional studies are required to address these questions and firmly establish correlations with development of thyroid lesions if there are any.

ACKNOWLEDGEMENTS

We would like to thank Drs. Alea Mills (Cold Spring Harbor Laboratory) for providing us *p63(fl/fl)* mice and Frank Gonzalez (NCI) for his critical review of the manuscript.

Sources of support: Intramural Research Program of the National Cancer Institute, Center for Cancer Research

Abbreviations

UBB	ultimobranchial body
SCN	solid cell nest
E	embryonic day
Ht	heterozygous
EM	Electron microscopy

REFERENCES

1. Biddinger PW, Ray M. Distribution of C cells in the normal and diseased thyroid gland. *Pathol Annu.* 1993; 28:205–229. [PubMed: 8416138]
2. Di Lauro, R.; De Felice, M. *Thyroid gland: anatomy and development.* Saunders; Philadelphia: 2001.
3. Kaufman, M.; Bard, J. *The anatomical bases of mouse development.* Academic Press; London: 1999.
4. Manley NR, Capecchi MR. Hox group 3 paralogs regulate the development and migration of the thymus, thyroid, and parathyroid glands. *Dev Biol.* 1998; 195:1–15. [PubMed: 9520319]
5. Kusakabe T, Hoshi N, Kimura S. Origin of the ultimobranchial body cyst: T/ebp/Nkx2.1 expression is required for development and fusion of the ultimobranchial body to the thyroid. *Dev Dyn.* 2006; 235:1300–1309. [PubMed: 16342117]
6. Kameda Y. Immunocytochemical localization and development of multiple kinds of neuropeptides and neuroendocrine proteins in the chick ultimobranchial gland. *J Comp Neurol.* 1991; 304:373–386. [PubMed: 1708788]
7. Miura M, Kameda Y. Neuronal properties in cultured ultimobranchial C cells of chick embryos: process outgrowth and expression of TuJ1 and enkephalin. *Brain Res.* 2001; 905:1–11. [PubMed: 11423073]
8. Kameda Y, Nishimaki T, Chisaka O, et al. Expression of the epithelial marker E-cadherin by thyroid C cells and their precursors during murine development. *J Histochem Cytochem.* 2007; 55:1075–1088. [PubMed: 17595340]
9. Mizuno K, Gonzalez FJ, Kimura S. Thyroid-specific enhancer-binding protein (T/EBP): cDNA cloning, functional characterization, and structural identity with thyroid transcription factor TTF-1. *Mol Cell Biol.* 1991; 11:4927–4933. [PubMed: 1922026]
10. Guazzi S, Price M, De Felice M, et al. Thyroid nuclear factor 1 (TTF-1) contains a homeodomain and displays a novel DNA binding specificity. *EMBO J.* 1990; 9:3631–3639. [PubMed: 1976511]
11. Kimura S, Hara Y, Pineau T, et al. The T/ebp null mouse: thyroid-specific enhancer-binding protein is essential for the organogenesis of the thyroid, lung, ventral forebrain, and pituitary. *Genes Dev.* 1996; 10:60–69. [PubMed: 8557195]
12. De Felice M, Di Lauro R. Thyroid development and its disorders: genetics and molecular mechanisms. *Endocr Rev.* 2004; 25:722–746. [PubMed: 15466939]
13. Kusakabe T, Kawaguchi A, Hoshi N, et al. Thyroid-specific enhancer-binding protein/NKX2.1 is required for the maintenance of ordered architecture and function of the differentiated thyroid. *Mol Endocrinol.* 2006; 20:1796–1809. [PubMed: 16601074]
14. Mansouri A, Chowdhury K, Gruss P. Follicular cells of the thyroid gland require Pax8 gene function. *Nat Genet.* 1998; 19:87–90. [PubMed: 9590297]
15. Kameda Y, Ito M, Nishimaki T, et al. FRS2alpha is required for the separation, migration, and survival of pharyngeal-endoderm derived organs including thyroid, ultimobranchial body, parathyroid, and thymus. *Dev Dyn.* 2009; 238:503–513. [PubMed: 19235715]
16. Kimura S, Ward JM, Minoo P. Thyroid-specific enhancer-binding protein/thyroid transcription factor 1 is not required for the initial specification of the thyroid and lung primordia. *Biochimie.* 1999; 81:321–327. [PubMed: 10401665]
17. Cameselle-Teijeiro J, Varela-Duran J, Sambade C, et al. Solid cell nests of the thyroid: light microscopy and immunohistochemical profile. *Hum Pathol.* 1994; 25:684–693. [PubMed: 7517912]
18. Burstein DE, Nagi C, Wang BY, et al. Immunohistochemical detection of p53 homolog p63 in solid cell nests, papillary thyroid carcinoma, and hashimoto's thyroiditis: A stem cell hypothesis of papillary carcinoma oncogenesis. *Hum Pathol.* 2004; 35:465–473. [PubMed: 15116328]
19. Reis-Filho JS, Preto A, Soares P, et al. p63 expression in solid cell nests of the thyroid: further evidence for a stem cell origin. *Mod Pathol.* 2003; 16:43–48. [PubMed: 12527712]
20. Preto A, Cameselle-Teijeiro J, Moldes-Boullosa J, et al. Telomerase expression and proliferative activity suggest a stem cell role for thyroid solid cell nests. *Mod Pathol.* 2004; 17:819–826. [PubMed: 15044923]

21. Harach HR, Vujanic GM, Jasani B. Ultimobranchial body nests in human fetal thyroid: an autopsy, histological, and immunohistochemical study in relation to solid cell nests and mucoepidermoid carcinoma of the thyroid. *J Pathol.* 1993; 169:465–469. [PubMed: 7684778]
22. Malaguarnera R, Vella V, Vigneri R, et al. p53 family proteins in thyroid cancer. *Endocr Relat Cancer.* 2007; 14:43–60. [PubMed: 17395974]
23. Malaguarnera R, Mandarino A, Mazzon E, et al. The p53-homologue p63 may promote thyroid cancer progression. *Endocr Relat Cancer.* 2005; 12:953–971. [PubMed: 16322335]
24. Reimann JD, Dorfman DM, Nose V. Carcinoma showing thymus-like differentiation of the thyroid (CASTLE): a comparative study: evidence of thymic differentiation and solid cell nest origin. *Am J Surg Pathol.* 2006; 30:994–1001. [PubMed: 16861971]
25. Unger P, Ewart M, Wang BY, et al. Expression of p63 in papillary thyroid carcinoma and in Hashimoto's thyroiditis: a pathobiologic link? *Hum Pathol.* 2003; 34:764–769. [PubMed: 14506636]
26. Cameselle-Teijeiro J, Abdulkader I, Perez-Becerra R, et al. BRAF mutation in solid cell nest hyperplasia associated with papillary thyroid carcinoma. A precursor lesion? *Hum Pathol.* 2009; 40:1029–1035. [PubMed: 19269016]
27. Asioli S, Erickson LA, Lloyd RV. Solid cell nests in Hashimoto's thyroiditis sharing features with papillary thyroid microcarcinoma. *Endocr Pathol.* 2009; 20:197–203. [PubMed: 19809803]
28. Mills AA, Qi Y, Bradley A. Conditional inactivation of p63 by Cre-mediated excision. *Genesis.* 2002; 32:138–141. [PubMed: 11857801]
29. Lakso M, Pichel JG, Gorman JR, et al. Efficient in vivo manipulation of mouse genomic sequences at the zygote stage. *Proc Natl Acad Sci U S A.* 1996; 93:5860–5865. [PubMed: 8650183]
30. Koster MI, Kim S, Mills AA, et al. p63 is the molecular switch for initiation of an epithelial stratification program. *Genes Dev.* 2004; 18:126–131. [PubMed: 14729569]
31. Hayat, MA. Principles and techniques of electron microscopy, Biological applications. Vol. 1. Van Nostrand Reinhold Company; New York: 1970.
32. Suzuki K, Kobayashi Y, Katoh R, et al. Identification of thyroid transcription factor-1 in C cells and parathyroid cells. *Endocrinology.* 1998; 139:3014–3017. [PubMed: 9607813]
33. Wollman SH, Neve P. Ultimobranchial follicles in the thyroid glands of rats and mice. *Recent Prog Horm Res.* 1971; 27:213–234. [PubMed: 4946131]
34. Wollman SH, Hilfer SR. Embryologic origin of the various epithelial cell types in the second kind of thyroid follicle in the C3H mouse. *Anat Rec.* 1978; 191:111–121. [PubMed: 646134]
35. Ngwenya LB, Rosene DL, Peters A. An ultrastructural characterization of the newly generated cells in the adult monkey dentate gyrus. *Hippocampus.* 2008; 18:210–220. [PubMed: 18058825]
36. Nabarra B, Mulotte M, Casanova M, et al. Ultrastructural study of the FVB/N mouse thymus: presence of an immature epithelial cell in the medulla and premature involution. *Dev Comp Immunol.* 2001; 25:231–243. [PubMed: 11164888]
37. Sathananthan AH, Nottola SA. Digital imaging of stem cells by electron microscopy. *Methods Mol Biol.* 2007; 407:21–41. [PubMed: 18453246]
38. Looijenga LH, Stoop H, de Leeuw HP, et al. POU5F1 (OCT3/4) identifies cells with pluripotent potential in human germ cell tumors. *Cancer Res.* 2003; 63:2244–2250. [PubMed: 12727846]
39. Trosko JE. From adult stem cells to cancer stem cells: Oct-4 Gene, cell-cell communication, and hormones during tumor promotion. *Ann N Y Acad Sci.* 2006; 1089:36–58. [PubMed: 17261754]
40. Kakudo K, Kitamura H, Miyauchi A, et al. Squamous metaplasia of human thyroid gland - an electron microscopic study of solid cell nest - *Med J Osaka Univ.* 1977; 28:33–38. [PubMed: 614494]
41. Mills AA, Zheng B, Wang XJ, et al. p63 is a p53 homologue required for limb and epidermal morphogenesis. *Nature.* 1999; 398:708–713. [PubMed: 10227293]
42. Yang A, Schweitzer R, Sun D, et al. p63 is essential for regenerative proliferation in limb, craniofacial and epithelial development. *Nature.* 1999; 398:714–718. [PubMed: 10227294]
43. Di Como CJ, Urist MJ, Babayan I, et al. p63 expression profiles in human normal and tumor tissues. *Clin Cancer Res.* 2002; 8:494–501. [PubMed: 11839669]

44. Reis-Filho JS, Schmitt FC. Taking advantage of basic research: p63 is a reliable myoepithelial and stem cell marker. *Adv Anat Pathol.* 2002; 9:280–289. [PubMed: 12195217]
45. Kurita T, Medina RT, Mills AA, et al. Role of p63 and basal cells in the prostate. *Development.* 2004; 131:4955–4964. [PubMed: 15371309]
46. McKeon F. p63 and the epithelial stem cell: more than status quo? *Genes Dev.* 2004; 18:465–469. [PubMed: 15037544]
47. Ando M, Nakanishi Y, Asai M, et al. Mucoepidermoid carcinoma of the thyroid gland showing marked ciliation suggestive of its pathogenesis. *Pathol Int.* 2008; 58:741–744. [PubMed: 18844942]

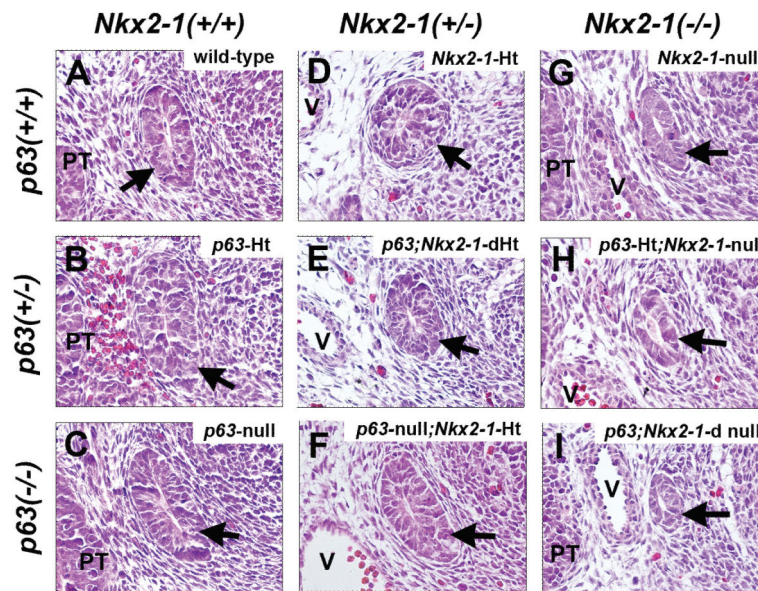


Figure 1. UBB of E12.5 mouse embryos. Transverse sections are shown. (a-i) Each panel shows representative UBB (indicated by an arrow) from mice with various combinations of *p63* and *Nkx2-1* alleles as indicated. PT: parathyroid, V: vessel. Magnification: x400.

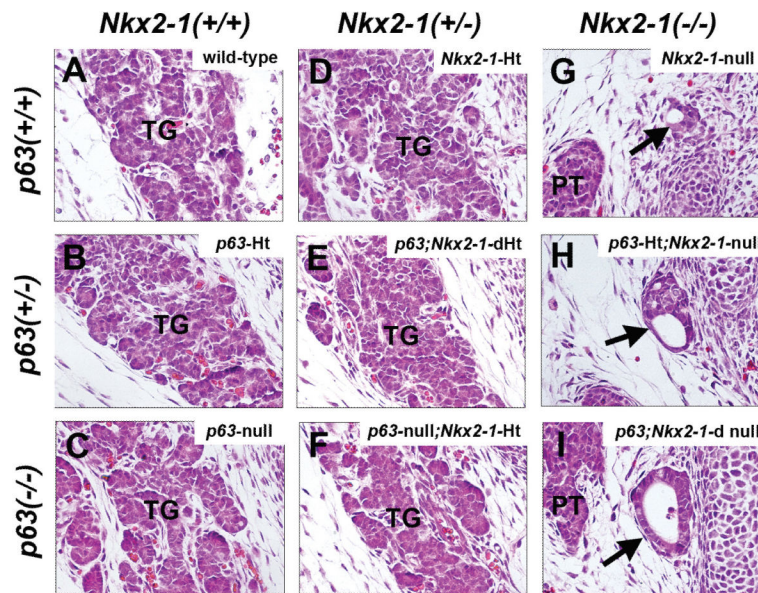


Figure 2. Thyroid gland and UBB of E14.5 mouse embryos. Frontal sections are shown. (a-f) Each panel shows representative thyroid (TG) from mice with various combinations of *p63* and *Nkx2-1* wild-type or Ht alleles as shown. (g-i) Each panel shows representative UBB cyst (indicated by an arrow) from mice with three different combinations of *p63* and *Nkx2-1*-null alleles as shown. PT: parathyroid. Note that each size of UBB appears to be different due to section's orientation. Magnification: x400.

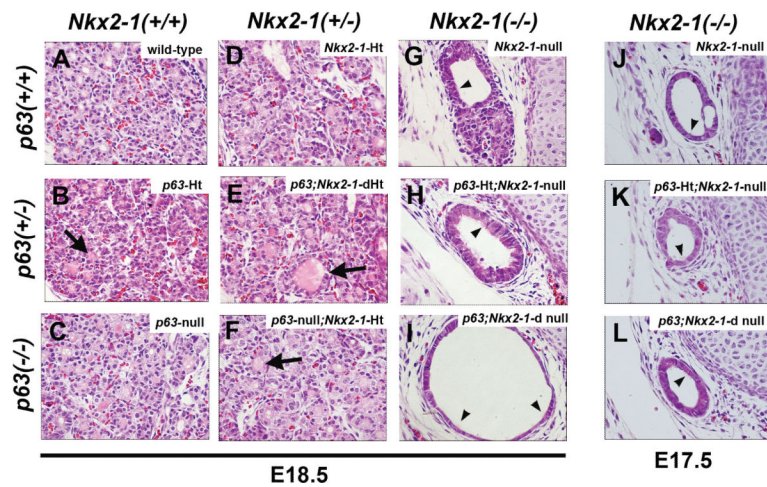


Figure 3.

Thyroid and/or UBB cyst of mouse embryos at E17.5 and E18.5. Frontal sections are shown. (a-f) Each panel shows a representative thyroid from E18.5 mice with various combinations of *p63* and *Nkx2-1* wild-type or Ht alleles as shown. Many small follicles are present, some of which contain colloid (seen in pink color, indicated by an arrow). (g-l) Each panel shows representative UBB cyst from E18.5 (g-i) and E17.5 (j-l) mice with three different combinations of *p63* and *Nkx2-1*-null alleles as shown. Inside cysts, occasional ciliated cells are found (indicated by an arrowhead). Magnification: x400.

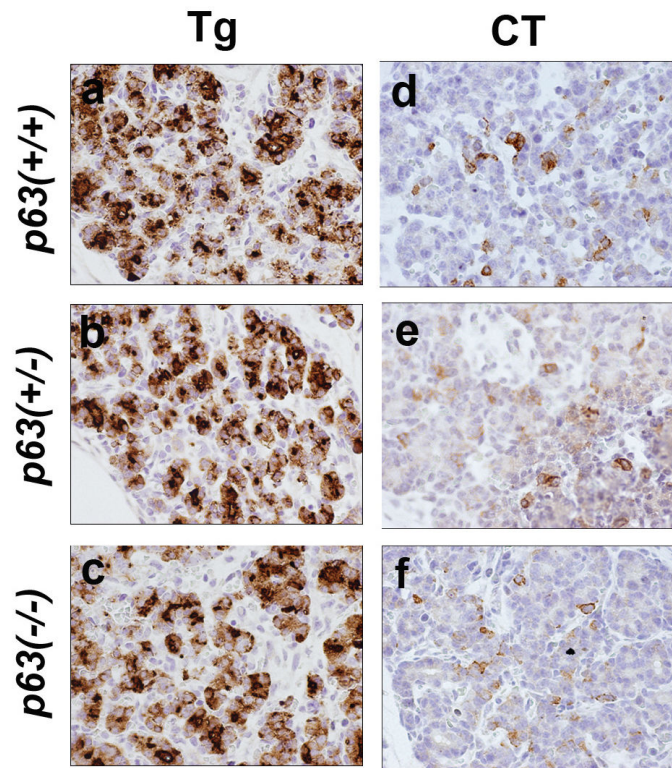


Figure 4. Thyroglobulin and calcitonin expression in E17.5 thyroid from mice with three different *p63* alleles. *Nkx2-1* allele is wild-type. Both thyroglobulin (Tg, a-c) and calcitonin (CT, d-f) expression are found equally in distribution and intensity in three different genotype mouse thyroids by immunohistochemistry. Positives are shown in brown color. Magnification: x400.

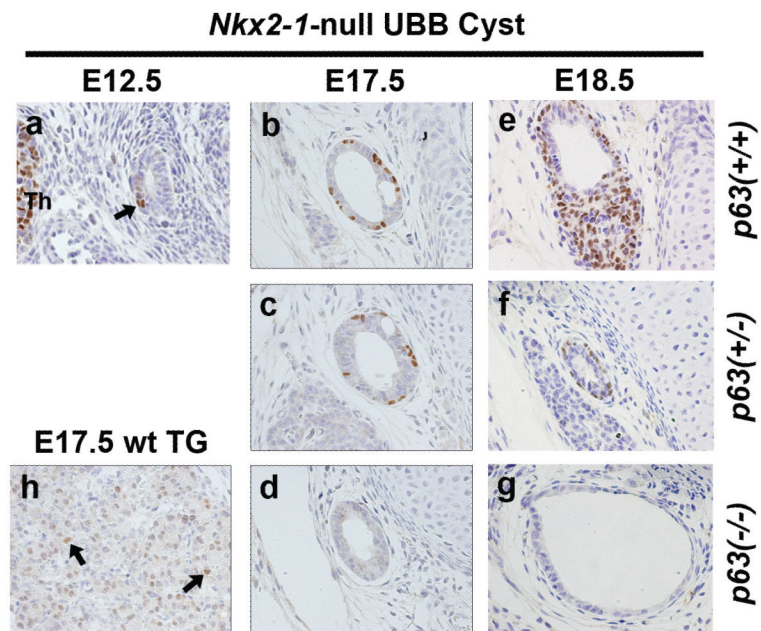


Figure 5. p63 expression in the *Nkx2-1*-null mouse UBB cyst. p63 positive cells in UBB of E12.5 *Nkx2-1*-null mouse (**a**) and E17.5 normal mouse thymoid (**h**, TG) are shown by an arrow. Thm: thymus. p63 positive cells in E17.5 (**b-d**) and E18.5 (**e-g**) *Nkx2-1*-null mouse UBBs with various p63 genotypes are observed outside of vesicular structure (**b**, **c**, **e**, **f**) or solid cystic pattern of cells (**e**). Note that the size of UBB appears to look smaller in **f** due to orientation of the section. Magnification: x400.

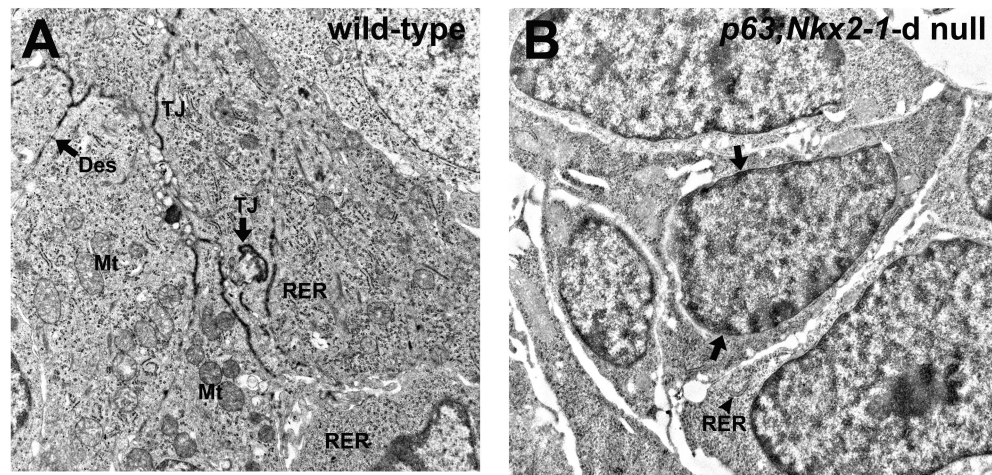


Figure 6. Electron microscopic analysis. Representative electron microscopic images of E14.5 wild-type thyroid (**a**) and *p63;Nkx2-1-d* null mouse UBB cyst (**b**) are shown. (**a**) Many intracellular organelles and cell attachments are clearly seen as dense membranes. Numerous cytoplasmic organella are well developed in the immature follicular cells at this embryonic stage. No colloid formation is shown but surrounded by well developed tight junctions. A few microvilli are seen. Des: desmosome, Mt: mitochondria, RER: rough endoplasmic reticulum, TJ: tight junction. (**b**) Very scant intracellular organella is seen. RER are minimally found (shown by an arrowhead). Clumps of nuclear heterochromatin are indicated by arrows. Magnification: x3000.