



A Rare Root Canal Configuration of a Maxillary Second Molar with Fused C-shaped Buccal Root and Five Canals: A Case Report and Review of literature

Dan Liu^a , Lihong Qiu^a , Jingtao Yu^{a*}

^a Department of Endodontics, School of Stomatology, China Medical University, Shenyang, Liaoning 110002, P.R. China

ARTICLE INFO

Article Type: Case Report

Received: 03 Jan 2019

Revised: 03 May 2019

Accepted: 19 May 2019

Doi: 10.22037/iej.v14i3.23900

*Corresponding author: Jingtao Yu, Department of Endodontics, School of Stomatology, China Medical University, Shenyang, Liaoning 110002, P.R. China.

Tel: +13-840 552899;

E-mail: 824692105@qq.com



© The Author(s). 2018 Open Access This work is licensed under the terms of the Creative Commons Attribution-NonCommercial-ShareAlike 4.0 International.

ABSTRACT

Having a thorough knowledge of root canal configuration is essential for a successful endodontic treatment. Clinicians should always pay attention to the unusual canal configuration so as to avoid missing extra canals. This paper describes a non-surgical retreatment of a maxillary second molar with two missing root canals; diagnosed by cone-beam computed tomographic (CBCT) imaging. The tooth had three roots and five canals: a C-shaped buccal root fused by mesiobuccal (MB) and distobuccal (DB) roots with three canals (CBCT scanning showed that the second MB canal was closer to the palatal than the buccal side), a mesiopalatal root with one canal, and a distopalatal root with one canal. The purpose of this case report is to remind clinicians of the importance of anatomical variations, and thus, detection of extra canals.

Keywords: Maxillary Second Molar; C-shaped Canal; Cone-Beam Computed Tomography

Introduction

A successful root canal treatment depends on a clear understanding of the root canal system with its frequent variations [1]. Conversely, insufficient understanding of the root canal configuration and undetected extra root canals are the major cause of treatment failure [2]. So, clinicians should always consider possible unusual canal configuration in order to avoid missing extra canals.

Maxillary second molars have a complex root canal anatomy. They generally have three separate roots [mesiobuccal (MB), distobuccal (DB) and palatal (P)], each with a single canal [3]. Zeng *et al.* [4] have reported a C-shaped MB root with two canals (MB1 and MB2) in a maxillary second molar. Singla and Aggarwal [5] reported a C-shaped palatal root with two canals (P1 and P2) in a maxillary second molar. However, a maxillary second molar with a fused C-shaped buccal root with three canals (MB1, MB2 and DB) and two separate palatal roots is a

rare dental anatomy which has never been reported in literature. Variations in the root canal configuration of maxillary second molars reported by various authors have been represented in Table 1 [4-42].

Arora *et al.* [19], Zhao *et al.* [28] and Ozcan *et al.* [33] reported five canals; showing three canals in the MB root. Several authors have reported the existence of a second palatal root. Chawla *et al.* [12] observed three palatal roots [mesiopalatal (MP), palatal (P), and distopalatal (DP)] in a maxillary second molar. Case reports with a single root/canal have also been reported [13, 24, 27, 42].

This study reports an unusual root canal configuration of a maxillary second molar with three roots and five canals; a C-shaped buccal root fused by MB and DB root with three canals, and two separate palatal roots with one canal in each root. With the assist of cone-beam computed tomography (CBCT) and an operating microscope, two extra canals, which were previously untreated, were identified.

Table 1. Variations reported in root canal configuration in maxillary second molars

Year	Authors	Root configuration	No. of canals	# MB	#DB	#P
2017	Jain <i>et al.</i> [6]	4 roots	4	1	1	2
2017	Subbiya <i>et al.</i> [7]	4 roots	4	1	1	2
2017	Suresh <i>et al.</i> [8]	Single root or fused roots	6	3	2	1
2017	Jeevanandan [9]	2 roots	2	1	0	1
2016	Zeng <i>et al.</i> [4]	4 roots	5	2 (C-shaped)	2	1
2015	Nabavizadeh <i>et al.</i> [10]	3 roots	4	1	1	2
2015	Beshkenadze and Chipashvili (2 cases) [11]	2 roots	2	1		1
2015	Chawla <i>et al.</i> [12]	3 roots	6	2	1	3
2015	Jaikrishan <i>et al.</i> [13]	1 root	1	Single canal		
2014	Ashraf <i>et al.</i> [14]	2 roots	4	2M 2D		
2014	Pawar and Kokate[15]	4 roots	4	1	1	2
2013	Fakhari and Shokraneh[16]	4 roots	4	1	1	2
2013	Paul <i>et al.</i> [17]	4 roots	4	1	1	2
2013	Simsek <i>et al.</i> [18]	2 roots	4	2M 2D		
2013	Arora <i>et al.</i> [19]	3 roots	5	3	1	1
2013	Shojaeian <i>et al.</i> [20]	4 roots	4	1	1	2
2012	Eskandarinekhad and Ghasemi[21]	4 roots	4	1	1	2
2012	Badole <i>et al.</i> [22]	4 roots	4	1	1	2
2012	Patel and Patel[23]	4 roots	4	1	1	2
2011	Ioannidis <i>et al.</i> [24]	1 root	1	Single canal		
2011	Scarpato <i>et al.</i> [25]	3 roots or 4 roots	4	1	1	2
2011	Zhu and Zhao[26]	4 roots	5	2	1	2
2011	Wang <i>et al.</i> [27]	1 root	1	Single canal		
2011	Zhao <i>et al.</i> [28]	4 roots	5	3	1	1
2010	Zhang <i>et al.</i> [29]	4 roots	4	1	1	2
2010	Prashanth <i>et al.</i> [30]	4 roots	4	1	1	2
2010	Singla <i>et al.</i> [5]	3 roots	3	1	1	1(C-shaped)
2010	Kottoor <i>et al.</i> [31]	5 roots	5	2	1	2
2009	Qun <i>et al.</i> [32]	4 roots	4	1	1	2
2009	Ozcan et al[33]	3 roots	5	3	1	1
2008	Ghoddusi <i>et al.</i> [34]	4 roots	4	1	1	2
2008	Kim <i>et al.</i> [35]	4 roots	6	2	2	2
2007	Ulusoy and Görgül[36]	4 roots	4	1	1	2
2007	Prakash <i>et al.</i> [37]	3 roots	4	2	1	1
2007	Pasternak Junior <i>et al.</i> [38]	3 roots	5	1	1	3
2007	Shin <i>et al.</i> (2 cases)[39]	4 roots	4	1	1	2
2006	Jafarzadeh <i>et al.</i> [40]	4 roots	4	2	1	1
2003	Alani [41]	4 roots	4	1	1	2
2000	Fava <i>et al.</i> [42]	1 root	1	Single canal		

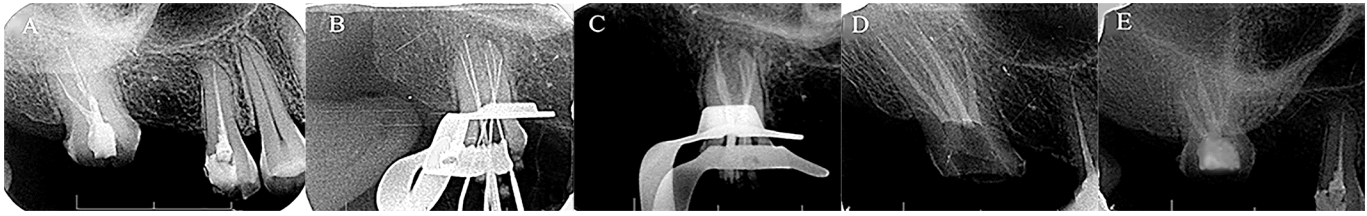


Figure 1. A) A pre-operative periapical radiograph of tooth #17; B and C) The working length and master apical cone periapical radiographs; D) The obturation periapical radiograph; E) One-month follow-up

Case Report

A 58-year-old female patient was referred to the Department of Endodontics, School of Stomatology, China Medical University, Shenyang, China; with a chief complaint of pain in the right maxillary second molar. The patient stated that she had undergone a root canal treatment two years ago. Since then, she had experienced persistent pain in the tooth, exaggerated by cold and hot stimuli. The patient's medical history was noncontributory.

Clinical examination showed the presence of a composite resin restoration and severe sensitivity to percussion. Sensibility testing of the right second molar with the cold (ethyl chloride) and heat (heated gutta-percha) tests caused a severe lingering pain, whereas electric pulp stimulation (Kerr, Analytic Technology Corp, Redmond, WA, USA) resulted in a premature response. Periodontal pockets and tooth mobility were within normal limits. Radiographic examination showed incomplete root canal fillings in the three obturated canals of the second molar. Moreover, the MB canal was not in the center of the corresponding root and therefore extra canals were suspected (Figure 1A). To confirm the unusual root canal configuration and locate additional canals, a CBCT scan was recommended. Informed consent was obtained from the patient, and a CBCT scan (NewTom 3G, QR Srl, Verona, Italy) of the maxilla was performed with a tube voltage of 110 kVp and a tube current of 7.18 mAs. CBCT scanning images (Figure 2A to C) and 3D reconstruction images (Figure 2D to H) were taken. They showed the presence of three roots and five canals; a fused C-shaped buccal root with 3 canals and two separate palatal roots with a single canal in each root, which meant that there were two more non-treated root canals. The CBCT images revealed that there were inappropriate root canal fillings in MB1, DB and DP canals in previous treatment, whereas MB2 and DP canals had been left untreated. Analysis of the clinical and radiographic findings, a diagnosis of symptomatic apical periodontitis with residual pulpitis was made for tooth #17. A non-surgical endodontic retreatment was planned, and the patient consented.

After the administration of local anaesthesia, using 4% articaine containing 1:100000 epinephrine (Primacaine; Acteon Group, Merignac Cedex, France), a rubber dam was placed on the tooth. Access opening was performed and three obturated root canals (MB1, DB and DP) were revealed. During examination with a dental operating microscope (Leica AG, Heerbrugg, Switzerland), a MP orifice was observed. With the help of CBCT images and P5 ultrasonic unit (Satelec, Merignac, France), a fifth root canal orifice (MB2) was located which was closer to MP.

Removal of gutta-percha was achieved by retreatment files (VDW, Munich, Germany) and Hedstrom files (Dentsply, Maillefer, Ballaigues, Switzerland). Working length was determined with the use of an apex locator (Raypex 2; VDW, Munich, Germany) and confirmed radiographically. Radiographic examination revealed the presence of five canals in tooth #17 (Figure 1B). Then, the root canals were cleaned and shaped with ProTaper Next nickel-titanium rotary instruments (Dentsply, Maillefer, Ballaigues, Switzerland) using a crown-down technique. The MB2 canal was instrumented up to X2 with ProTaper Next file, whereas the other four canals were instrumented up to ProTaper Next X3 to the working length (Figure 3A).

Irrigation was performed with 2.5% sodium hypochlorite and 17% Ethylene-di-amine-tetra-acetic acid (EDTA). Afterwards, ultrasonic irrigation was performed and 2% chlorhexidine gluconate was used as the final irrigant. After drying the canals with paper points, all canals were medicated with calcium hydroxide and sealed with Cavit (ESPE, Seefeld, Germany). After one week, the patient was not painful to percussion. Under rubber dam, and after rinsing and drying, the canals were obturated with warm gutta-percha vertical condensation technique using the EndoPilot motor (Schlumbohm, Brokstedt, Germany). AH-Plus (Dentsply DeTrey GmbH, Konstanz, Germany) was used as the sealer (Figure 1C, 1D and 3B). The tooth was then restored with composite resin (P60; 3M Dental Products, St Paul, MN, USA). The patient was asymptomatic at one-month follow-up (Figure 1E).

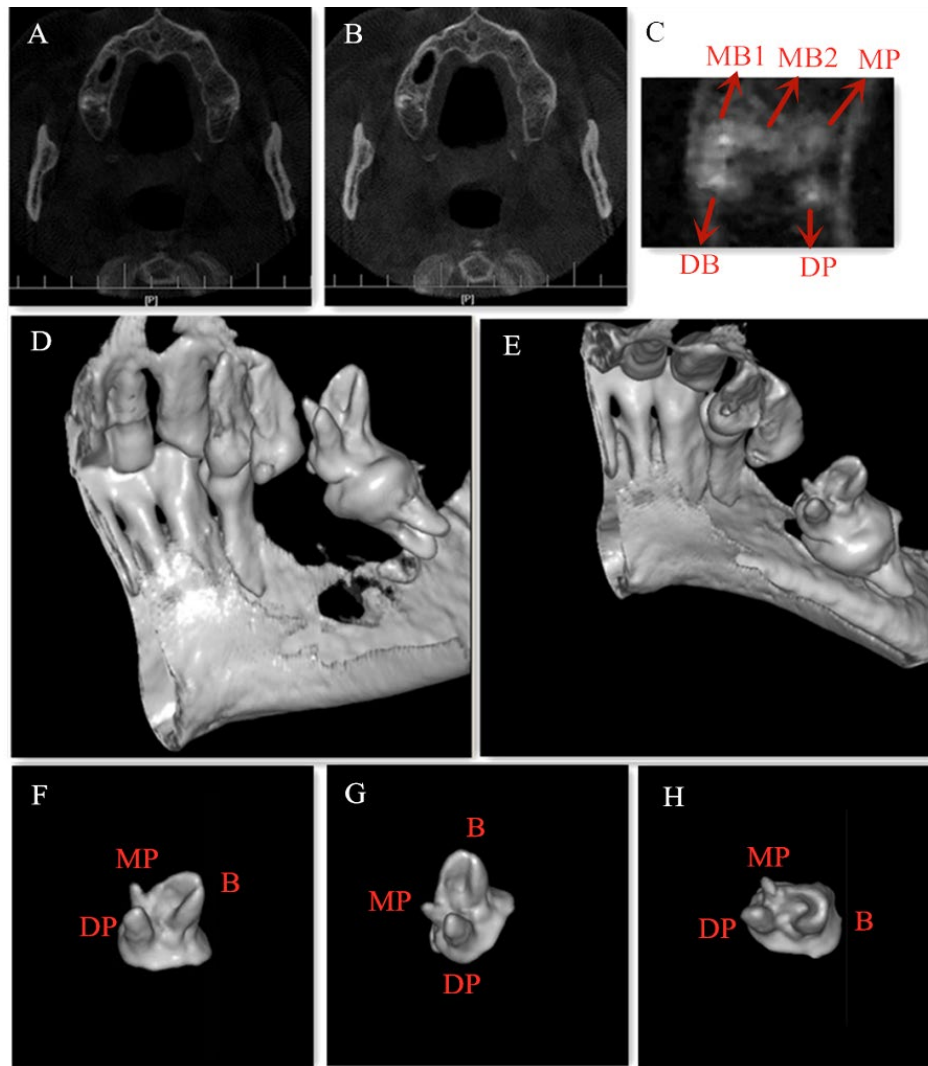


Figure 2. CBCT scanning images and 3D reconstruction of tooth #17. A and B) The different CBCT scanning levels of tooth #17; C) An enlarged picture of tooth #17 showing five canals: MB1, MB2, DB, MP and DP; D-H) The 3D reconstruction of tooth #17 showing three roots: one C-shaped buccal root, one MP root and one DP root

Discussion

Based on the current report and corresponding literature, it is evident that adequate knowledge of morphological variations is critically important in the success of an endodontic treatment. Abnormalities in root canal anatomy commonly occur in maxillary molars, especially in maxillary second molars, where it can be diagnostically and technically challenging [43, 44]. In the presented case, CBCT images helped clinicians better evaluate the complex root canal morphology and facilitate the location of extra canals. Although conventional intraoral radiographs are commonly employed in endodontic treatments, the main disadvantage of such radiographs is that it only provides 2-dimensional (2D) images of a 3-dimensional (3D) object, an image which can not reveal the actual number of roots

and canals [45]. In this study, CBCT cross-sectional images clearly showed the presence of five canals in tooth #17 with two missing canals (MB2 and MP). However, 3D reconstructions demonstrated a C-shaped buccal root fused by MB and DB roots and two separate palatal roots (Figure 2).

Rodríguez *et al.* [46] suggested that more diagnostic information could be gained from pre-operative CBCT scans, and the obtained information could directly influence a clinician's judgment. They reported that the examiners modified their clinical treatment plan after viewing CBCT images in 27.3% of the cases. The application of CBCT could be considered as an option for complex endodontic cases. According to the 'American Association of Endodontists' (AAE) and 'American Academy of Oral and Maxillofacial Radiology' (AAOME) Joint Position Statement published in 2015 [47], application areas for the use of

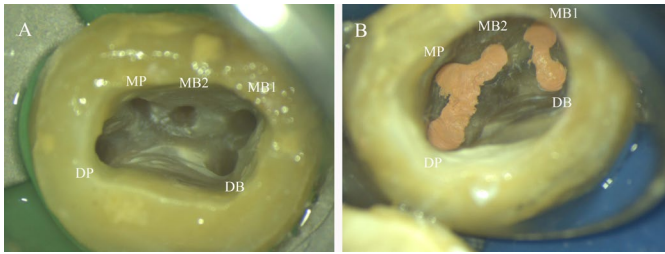


Figure 3. Microscopic images of the five root canals: MB1, MB2, DB, MP and DP. A) After preparation; B) After root canal filling

limited field of view (FOV) CBCT in endodontics include extra canals, calcified canals, immediate postoperative imaging, vertical root fractures, alveolar or tooth traumas and root resorptions. However, CBCT should not be considered as a replacement for conventional intraoral/panoramic radiographs except for certain patients [48].

Root canal variations in maxillary second molars could be divided into a) number variations of canals and b) anatomical variations of roots. To date, the number of canals in maxillary second molars has been reported to range from one to six. Tian *et al.* [49] evaluated the CBCT images of 1539 maxillary second molars from Chinese patients. They concluded that 3.2% had one canal, 6.1% had two canals, 66.4% had three canals, 22.9% had four canals and 1.4% had five canals. The incidence of 6 canals is a rare variation and there was no occurrence in the above report.

The most common variation in maxillary second molars is the MB2 root canal. The incidence of MB2 is 42.2% [50] and 58.7% [51] in a Korean population, 58% in an Irish population [3] and 79.3% (left) and 87.5% (right) in a Brazilian population [52].

The incidence of more than one palatal canal varied from 0.45% [53] to 14% [54] in maxillary second molars in different studies. Kim *et al.* [51] reported that extra canals were found in 34.39% of the MB roots, 0.30% of the midbuccal roots, 0.30% of the DB roots, and 1.82% of the P roots in 3- or 4-rooted maxillary second molars. Studies have revealed that Chinese population possesses a high prevalence of root fusion compared with other ethnic groups. The incidence of fused roots in maxillary second molars from a native Chinese population has been reported to be as high as 23.9% and 42.25% in two articles [49, 55]. The C-shaped root is one type of root fusion which has to exhibit the following three features: (i) fused roots; (ii) a longitudinal groove on the lingual or buccal surface of the root; (iii) at least one cross-section of the canal belonging to C1, C2 or C3 configuration [56]. The C-shaped root of tooth #17 in the present report was a fusion of MB and DB roots. The C-shaped buccal root has a longitudinal

groove on the lingual side of the root surface and its cross-sections assume a C3 configuration.

Failure to identify and treat extra canals is a major cause of unsuccessful treatments [57]. Aside from the anatomic complexity of maxillary second molars, the posterior location of the teeth and their superimposition over another canal or bony structures -such as maxillary tuberosity on radiographs- make it difficult to detect extra canals [58]. To detect morphological variations of maxillary second molars, a careful evaluation of x-rays is essential. X-rays with an appearance of an eccentric root canal always indicate additional canals [59]. In our study, the MB canal was not in the center of MB root on the radiograph, which suggested more than one canal in this root. Moreover, an abnormal coronal morphology usually suggests a complex internal anatomy [21]. Furthermore, it is widely reported that the introduction of CBCT has greatly decreased the rate of missing canals [60-62].

Once extra canals are suspected, an enlarged access cavity is suggested. With the increase in use of dental operating microscope, locating extra orifices has become easier. Exploring along the developmental groove on the pulp chamber floor with ultrasonic tips and DG 16 endodontic probe is also required to find canal orifices [63]. In this case, the detection of the fourth and fifth canals in tooth #17 depended on careful pre-operative analysis with CBCT and proficiency in ultrasonic equipment and dental microscope. In addition, the clinicians' patience and carefulness played a major role in the detection of extra canals.

In our case, the right maxillary second molar presented a C-shaped buccal root with three canals and two separate palatal roots with a single canal in each root. Similar case reports of maxillary second molars with five canals (2 MB, 1 DB and 2P canals) have only been reported by Zhu *et al.* [26] and Kottoor *et al.* [31]. In literature, and to the best of our knowledge, we never came across a case report that documented the presence of a C-shaped buccal root with three canals in a maxillary second molar. According to Betancourt *et al.* [64], the average distance between the center of MB1 and MB2 canals was 2.2 ± 0.54 mm (range 2.1-2.3 mm) in maxillary second molars. Nevertheless, in this case, CBCT imaging revealed that the MB2 canal was closer to the palatal side rather than the buccal side (MB1-MB2: 3.25 mm). The findings of this study represented the diagnosis and retreatment of a rare case with undetected extra canals and therefore could remind dental practitioners of the significance of grasping the anatomic variations and minding extra canals during their treatments.

Conclusion

The possibility of a C-shaped buccal root -with three canals- and two separate palatal roots -with two separate canals- should be considered in the second maxillary molars. Though anatomic variations are complex in the second maxillary molars, dentists should have thorough knowledge of root canal configuration and develop awareness of avoiding missing canals.

Acknowledgement

The authors deny any conflicts of interest. This research did not receive any specific grants from funding agencies in the public, commercial, or non-profit sectors.

Conflict of Interest: 'None declared'.

References

1. Badole GP, Warhadpande MM, Shenoi PR, Lachure C, Badole SG. A rare root canal configuration of bilateral maxillary first molar with 7 root canals diagnosed using cone-beam computed tomographic scanning: a case report. *J Endod.* 2014;40(2):296-301.
2. Cantatore G, Berutti E, Castellucci A. Missed anatomy: frequency and clinical impact. 2006;15(1):3-31.
3. al Shalabi RM, Omer OE, Glennon J, Jennings M, Claffey NM. Root canal anatomy of maxillary first and second permanent molars. *Int Endod J.* 2000;33(5):405-14.
4. Zeng C, Shen Y, Guan X, Wang X, Fan M, Li Y. Rare Root Canal Configuration of Bilateral Maxillary Second Molar Using Cone-beam Computed Tomographic Scanning. *J Endod.* 2016;42(4):673-7.
5. Singla M, Aggarwal V. C-Shaped palatal canal in maxillary second molar mimicking two palatal canals diagnosed with the aid of spiral computerized tomography. *Oral Surg Oral Med Oral Pathol Oral Radiol Endod.* 2010;109(6):e92-5.
6. Jain P, Patni P, Yogesh P, Anup V. Endodontic management of maxillary third molar with MB2 (Vertucci type IV) canal configuration diagnosed with Cone Beam Computed Tomography - a case report. *Clujul Med.* 2017;90(4):459-63.
7. Subbiya A, Mitthra S, Banu S, Malarvizhi D. Radix Distolingualis: A Case Report, Review and Endodontic Treatment Guidelines. *J Clin Diagn Res.* 2017;11(6):Zd10-zd3.
8. Suresh M, Karthikeyan K, Mahalaxmi S. Maxillary Second Molar with Fused Root and Six Canals- A Case Report. *J Clin Diagn Res.* 2017;11(4):Zd35-zd7.
9. Jeevanandan G. Obturation of a Retained Primary Maxillary Second Molar Using Biodentine(TM): A Case Report. *J Clin Diagn Res.* 2017;11(1):Zd34-zd6.
10. Nabavizadeh M, Abbaszadegan A, Mirhadi H, Ghahramani Y. Root Canal Treatment of a Maxillary Second Molar with Two Palatal Canals: a Case Report. *J Dent (Shiraz).* 2015;16(4):371-3.
11. Beshkenadze E, Chipashvili N. The maxillary second molar - anatomical variations (case report). *Georgian Med News.* 2015(238):35-8.
12. Chawla A, Sujlana A, Dixit A. Re-treating a maxillary second molar with 6 root canals assisted by cone beam computed tomography. *Gen Dent.* 2015;63(2):e14-6.
13. Jaikrishnan S, Kottoor J, Mathew J, Kumar SR, George S, Hari K. Evaluation and endodontic management of a patient with 6 single-rooted molars: a case report. *Gen Dent.* 2015;63(5):e35-7.
14. Ashraf H, Dianat O, Hajrezai R, Paymanpour P, Azadnia S. Endodontic treatment of a double-rooted maxillary second molar with four canals: a case report. *Iran Endod J.* 2014;9(4):304-6.
15. Pawar AM, Kokate SR. Contemporary endodontic management of four rooted maxillary second molar using waveOne. *Contemp Clin Dent.* 2014;5(1):130-3.
16. Fakhari E, Shokraneh A. A maxillary second molar with two separate palatal roots: a case report. *J Dent (Shiraz).* 2013;14(2):87-9.
17. Paul B, Dube K. Endodontic treatment of a maxillary second molar with two separate palatal roots: a case report. *J Clin Diagn Res.* 2013;7(12):3127.
18. Simsek N, Keles A, Bulut ET. Unusual root canal morphology of the maxillary second molar: a case report. *Case Rep Dent.* 2013;2013:138239.
19. Arora A, Acharya SR, Saraswathi MV, Sharma P, Ather A. Dilemmas pertaining to three canals in the mesiobuccal root of a maxillary second molar: a case report. *Restor Dent Endod.* 2013;38(3):172-7.
20. Shojaeian S, Ghodduji J, Hajian S. A case report of maxillary second molar with two palatal root canals and a furcal enamel pearl. *Iran Endod J.* 2013;8(1):37-9.
21. Eskandarinezhad M, Ghasemi N. Nonsurgical endodontic retreatment of maxillary second molar with two palatal root canals: a case report. *J Dent Res Dent Clin Dent Prospects.* 2012;6(2):75-8.
22. Badole GP, Bahadure RN, Warhadpande MM, Kubde R. A rare root canal configuration of maxillary second molar: a case report. *Case Rep Dent.* 2012;2012:767582.
23. Patel S, Patel P. Endodontic management of maxillary second molar with two palatal roots: a report of two cases. *Case Rep Dent.* 2012;2012:590406.
24. Ioannidis K, Lambrianidis T, Beltes P, Besi E, Malliari M. Endodontic management and cone-beam computed tomography evaluation of seven maxillary and mandibular molars with single roots and single canals in a patient. *J Endod.* 2011;37(1):103-9.
25. Scarparo RK, Pereira L, Moro D, Grundling G, Gomes M, Grecca FS. Morphologic variations of maxillary molars palatal root and the importance of its knowledge for endodontic practice: a case series. *J Contemp Dent Pract.* 2011;12(2):138-42.
26. Zhu Z, Zhao SL. [Maxillary second molar with five root canals: a case report]. *Shanghai Kou Qiang Yi Xue.* 2011;20(2):219-21.
27. Wang Y, Hui X, Huang DM. Maxillary second molar with curved single root and single canal: a case report. *Hua Xi Kou Qiang Yi Xue Za Zhi.* 2011;29(1):104-5.
28. Zhao J, Li Y, Yang ZW, Wang W, Meng Y. Three-dimensional computed topography analysis of a patient with an unusual anatomy of the maxillary second and third molars. *Int J Oral Sci.* 2011;3(4):225-8.
29. Zhang TT, Qiu W, Ming CX. [Maxillary second molar with two palatal root canals: a case report]. *Hua Xi Kou Qiang Yi Xue Za Zhi.* 2010;28(6):678-9.
30. Prashanth MB, Jain P, Patni P. Maxillary right second molar with two palatal root canals. *J Conserv Dent.* 2010;13(2):94-6.

31. Kottoor J, Hemamalathi S, Sudha R, Velmurugan N. Maxillary second molar with 5 roots and 5 canals evaluated using cone beam computerized tomography: a case report. *Oral Surg Oral Med Oral Pathol Oral Radiol Endod.* 2010;109(2):e162-5.
32. Qun L, Longing N, Qing Y, Yuan L, Jun W, Qingyue D. A case of asymmetric maxillary second molar with double palatal roots. *Quintessence Int.* 2009;40(4):275-6.
33. Ozcan E, Aktan AM, Ari H. A case report: Unusual anatomy of maxillary second molar with 3 mesiobuccal canals. *Oral Surg Oral Med Oral Pathol Oral Radiol Endod.* 2009;107(1):e43-6.
34. Ghoddsi J, Mesgarani A, Gharagozloo S. Endodontic re-treatment of maxillary second molar with two separate palatal roots: a case report. *Iran Endod J.* 2008;3(3):83-5.
35. Kim JR, Choi SB, Park SH. A maxillary second molar with 6 canals: a case report. *Quintessence Int.* 2008;39(1):61-4.
36. Ulusoy OI, Gorgul G. Endodontic treatment of a maxillary second molar with 2 palatal roots: a case report. *Oral Surg Oral Med Oral Pathol Oral Radiol Endod.* 2007;104(4):e95-7.
37. Prakash R, Bhargavi N, Rajan J, Joseph R, Velmurugan N, Kandaswamy D. MB2 in maxillary second molar. *Indian J Dent Res.* 2007;18(1):38-40.
38. Pasternak Junior B, Teixeira CS, Silva RG, Vansan LP, Sousa Neto MD. Treatment of a second maxillary molar with six canals. *Aust Endod J.* 2007;33(1):42-5.
39. Shin SJ, Park JW, Lee JK, Hwang SW. Unusual root canal anatomy in maxillary second molars: two case reports. *Oral Surg Oral Med Oral Pathol Oral Radiol Endod.* 2007;104(6):e61-5.
40. Jafarzadeh H, Javidi M, Zarei M. Endodontic retreatment of a maxillary second molar with three separate buccal roots. *Aust Endod J.* 2006;32(3):129-32.
41. Alani AH. Endodontic treatment of bilaterally occurring 4-rooted maxillary second molars: case report. *J Can Dent Assoc.* 2003;69(11):733-5.
42. Fava LR, Weinfeld I, Fabri FP, Pais CR. Four second molars with single roots and single canals in the same patient. *Int Endod J.* 2000;33(2):138-42.
43. Kottoor J, Velmurugan N, Surendran S. Endodontic management of a maxillary first molar with eight root canal systems evaluated using cone-beam computed tomography scanning: a case report. *J Endod.* 2011;37(5):715-9.
44. Peikoff MD, Christie WH, Fogel HM. The maxillary second molar: variations in the number of roots and canals. *Int Endod J.* 1996;29(6):365-9.
45. Patel S, Dawood A, Whaites E, Pitt Ford T. New dimensions in endodontic imaging: part I. Conventional and alternative radiographic systems. *Int Endod J.* 2009;42(6):447-62.
46. Rodriguez G, Abella F, Duran-Sindreu F, Patel S, Roig M. Influence of Cone-beam Computed Tomography in Clinical Decision Making among Specialists. *J Endod.* 2017;43(2):194-9.
47. Patel S, Horner K. The use of cone beam computed tomography in endodontics. *Int Endod J.* 2009;42(9):755-6.
48. Vandenberghe B, Jacobs R, Yang J. Diagnostic validity (or acuity) of 2D CCD versus 3D CBCT-images for assessing periodontal breakdown. *Oral Surg Oral Med Oral Pathol Oral Radiol Endod.* 2007;104(3):395-401.
49. Tian XM, Yang XW, Qian L, Wei B, Gong Y. Analysis of the Root and Canal Morphologies in Maxillary First and Second Molars in a Chinese Population Using Cone-beam Computed Tomography. *J Endod.* 2016;42(5):696-701.
50. Lee JH, Kim KD, Lee JK, Park W, Jeong JS, Lee Y, Gu Y, Chang SW, Son WJ, Lee WC, Baek SH, Bae KS, Kum KY. Mesiobuccal root canal anatomy of Korean maxillary first and second molars by cone-beam computed tomography. *Oral Surg Oral Med Oral Pathol Oral Radiol Endod.* 2011;111(6):785-91.
51. Kim Y, Lee SJ, Woo J. Morphology of maxillary first and second molars analyzed by cone-beam computed tomography in a Korean population: variations in the number of roots and canals and the incidence of fusion. *J Endod.* 2012;38(8):1063-8.
52. Reis AG, Graziotin-Soares R, Barletta FB, Fontanella VR, Mahl CR. Second canal in mesiobuccal root of maxillary molars is correlated with root third and patient age: a cone-beam computed tomographic study. *J Endod.* 2013;39(5):588-92.
53. Rwenyonyi CM, Kutesa AM, Muwazi LM, Buwembo W. Root and canal morphology of maxillary first and second permanent molar teeth in a Ugandan population. *Int Endod J.* 2007;40(9):679-83.
54. Singh S, Pawar M. Root canal morphology of South Asian Indian maxillary molar teeth. *Eur J Dent.* 2015;9(1):133-44.
55. Zhang Q, Chen H, Fan B, Fan W, Gutmann JL. Root and root canal morphology in maxillary second molar with fused root from a native Chinese population. *J Endod.* 2014;40(6):871-5.
56. Fan B, Cheung GS, Fan M, Gutmann JL, Bian Z. C-shaped canal system in mandibular second molars: Part I-Anatomical features. *J Endod.* 2004;30(12):899-903.
57. Wolcott J, Ishley D, Kennedy W, Johnson S, Minnich S. Clinical investigation of second mesiobuccal canals in endodontically treated and retreated maxillary molars. *J Endod.* 2002;28(6):477-9.
58. Libfeld H, Rotstein I. Incidence of four-rooted maxillary second molars: literature review and radiographic survey of 1,200 teeth. *J Endod.* 1989;15(3):129-31.
59. Nosrat A, Verma P, Hicks ML, Schneider SC, Behnia A, Azim AA. Variations of Palatal Canal Morphology in Maxillary Molars: A Case Series and Literature Review. *J Endod.* 2017;43(11):1888-96.
60. Baratto Filho F, Zaitter S, Haragushiku GA, de Campos EA, Abuabara A, Correr GM. Analysis of the internal anatomy of maxillary first molars by using different methods. *J Endod.* 2009;35(3):337-42.
61. Rodriguez G, Patel S, Duran-Sindreu F, Roig M, Abella F. Influence of Cone-beam Computed Tomography on Endodontic Retreatment Strategies among General Dental Practitioners and Endodontists. *J Endod.* 2017;43(9):1433-7.
62. Weller RN, Hartwell GR. The impact of improved access and searching techniques on detection of the mesiolingual canal in maxillary molars. *J Endod.* 1989;15(2):82-3.
63. Sujith R, Dhananjaya K, Chaurasia VR, Kasigari D, Veerabhadrapa AC, Naik S. Microscope magnification and ultrasonic precision guidance for location and negotiation of second mesiobuccal canal: An in vivo study. *J Int Soc Prev Community Dent.* 2014;4 (Suppl 3):S209-12.
64. Betancourt P, Navarro P, Cantin M, Fuentes R. Cone-beam computed tomography study of prevalence and location of MB2 canal in the mesiobuccal root of the maxillary second molar. *Int J Clin Exp Med.* 2015;8(6):9128-34.

Please cite this paper as: Liu D, Qiu L, Yu J. A Rare Root Canal Configuration of a Maxillary Second Molar with Fused C-shaped Buccal Root and Five Canals: A Case Report and Review of the Literature. *Iran Endod J.* 2019;14(3): 225-31. Doi: 10.22037/iejv14i3.23900.