

# Upregulation of Interleukin 8 by Oxygen-deprived Cells in Glioblastoma Suggests a Role in Leukocyte Activation, Chemotaxis, and Angiogenesis

By Isabelle Desbaillets, Annie-Claire Diserens, Nicolas de Tribolet, Marie-France Hamou, and Erwin G. Van Meir

---

*From the Laboratory of Tumor Biology and Genetics, Neurosurgery Department, University Hospital (CHUV), 1011 Lausanne, Switzerland*

## Summary

Leukocyte infiltration and necrosis are two biological phenomena associated with the development of neovascularization during the malignant progression of human astrocytoma. Here, we demonstrate expression of interleukin (IL)-8, a cytokine with chemotactic and angiogenic properties, and of IL-8-binding receptors in astrocytoma. IL-8 expression is first observed in low grade astrocytoma in perivascular tumor areas expressing inflammatory cytokines. In glioblastoma, it further localizes to oxygen-deprived cells surrounding necrosis. Hypoxic/anoxic insults on glioblastoma cells in vitro using anaerobic chamber systems or within spheroids developing central necrosis induced an increase in IL-8 messenger RNA (mRNA) and protein expression. mRNA for IL-8-binding chemokine receptors CXCR1, CXCR2, and the Duffy antigen receptor for chemokines (DARC) were found in all astrocytoma grades by reverse transcription/PCR analysis. In situ hybridization and immunohistochemistry localized DARC expression on normal brain and tumor microvascular cells and CXCR1 and CXCR2 expression to infiltrating leukocytes. These results support a model where IL-8 expression is initiated early in astrocytoma development through induction by inflammatory stimuli and later in tumor progression increases due to reduced microenvironmental oxygen pressure. Augmented IL-8 would directly and/or indirectly promote angiogenesis by binding to DARC and by inducing leukocyte infiltration and activation by binding to CXCR1 and CXCR2.

Astrocytomas are the most common and lethal human primary brain tumors and can be subdivided into low grade astrocytoma (WHO grade II), anaplastic astrocytoma (grade III), and glioblastoma (grade IV) according to cellularity, cellular pleomorphism, degree of neovascularization, and the presence of necrosis (1). Glioblastoma can occur de novo or as the recurrence of a grade II or III astrocytoma. Little is known about the molecular mediators inducing the biological changes occurring during this progression. Here we address two interesting biological features of these tumors: development of tumor-induced neovascularization and the use of this vascular network by lymphoid/myeloid cells for tumor infiltration.

As for other tumor types, the progression of astrocytoma is dependent on the development of new blood supply (2, 3). New blood vessels appear in low grade astrocytoma; these vessels are anatomically indistinguishable from those found in the surrounding normal brain. In the malignant phase of the disease, vessel density increases and the neovessels acquire an abnormal architecture, becoming extensively convoluted with the formation of vascular glom-

eruli, showing lumen occlusion, and displaying hyperplasia of the smooth muscle/pericyte and endothelial cell layers (1, 3). Maximal vessel density is reached in glioblastoma which is among the most vascularized tumors (4). Paradoxically, this increase in vessels is accompanied by the development of necrosis, the pathognomonic criterion that distinguishes glioblastoma from anaplastic astrocytoma (1, 3). The precise mechanism(s) at the origin of this tissue death are unresolved, but at least two factors are believed to contribute to its genesis. One is the outgrowth of blood supply by a rapidly growing tumor leading to tissue hypoxia/anoxia. The second is thrombotic occlusion of vessels, conducive to tissue ischemia (1).

Parallel to vessel development, astrocytomas are often infiltrated with numerous lymphoid/myeloid cells extravasating from newly formed tumor vessels. These are predominantly macrophages and CD8 T lymphocytes, but, B cells, NK cells, and CD4 T cells are also present (5, 6). It is unclear whether these infiltrates participate in an antitumor response or contribute indirectly to tumor expansion by secretion of growth factors or cytokines. Clearly, they are in-

efficient at eradicating tumor growth and do not appear to relate to a favorable prognosis (7, 8). The precise mechanism leading to infiltration in astrocytoma is unknown, but it is likely to involve both adhesion molecules (9, 10) and chemoattractants (11, 12).

IL-8 is a candidate molecule that may play a role in both of these processes. Belonging to the subfamily of chemokines blueprinted by a C-X-C amino acid cystein motif (see review in reference 13), IL-8 is secreted by many different cell types and is a chemoattractant for neutrophils, T lymphocytes, and basophils (14–19). Furthermore, recent work has demonstrated that IL-8 is a mediator of angiogenesis. IL-8 induces endothelial cell chemotactic and proliferative activity (20–22) and mediates neovascularization in rat and rabbit corneas in the absence of inflammation (23–24), as well as in the rat mesenteric window assay (25). IL-8 is secreted by a variety of tumor cells (see review in reference 13), promotes growth of bronchogenic carcinoma (26) and nonsmall cell lung cancer (22), and correlates with metastatic potential of human melanoma cells in nude mice (27).

Three IL-8-binding receptors participate in the biological responses mediated by this cytokine: C-X-C chemokine receptor 1 (CXCR1/IL-8RA), C-X-C chemokine receptor 2 (CXCR2/IL-8RB), and the Duffy antigen receptor for chemokines (DARC).<sup>1</sup> Although IL-8 is the only chemokine known to bind to CXCR1, CXCR2 is shared with all C-X-C chemokines carrying the amino acid motif E-L-R-C-X-C. DARC is a promiscuous receptor for many C-X-C and C-C chemokines and serves as a site of anchorage for infection by malaria parasite *Plasmodium vivax* (28, 29).

We previously demonstrated that IL-8 is synthesized *in vivo* during all stages of astrocytoma progression (12). Here we examine which physiological mechanisms regulate IL-8 expression during the progression of human astrocytoma, and elucidate whether this secretion mediates a biological response in these tumors. We demonstrate that two mechanisms are likely to be involved in IL-8 secretion: early induction by the presence of inflammatory signals such as IL-1 and TNF, and late induction by a change in the physiology of the tumor, namely, a decrease in oxygen levels due to ischemia/hypoxia. Expression of IL-8 receptors CXCR1 and CXCR2 on a subset of infiltrating leukocytes and of DARC on tumor microvasculature supports a role for IL-8 in leukocyte attraction, activation, and angiogenesis.

## Materials and Methods

**Cell Culture, Spheroid Formation, and Anoxic Treatments.** Human glioblastoma cell lines U87MG (endogenous WTp53, tumorigenic in immunocompromised mice), LN-229 (mutant p53, tumorigenic), LN-Z308 (p53-null, tumorigenic), and T98G (mutant p53, nontumorigenic) were grown as previously described (30). To

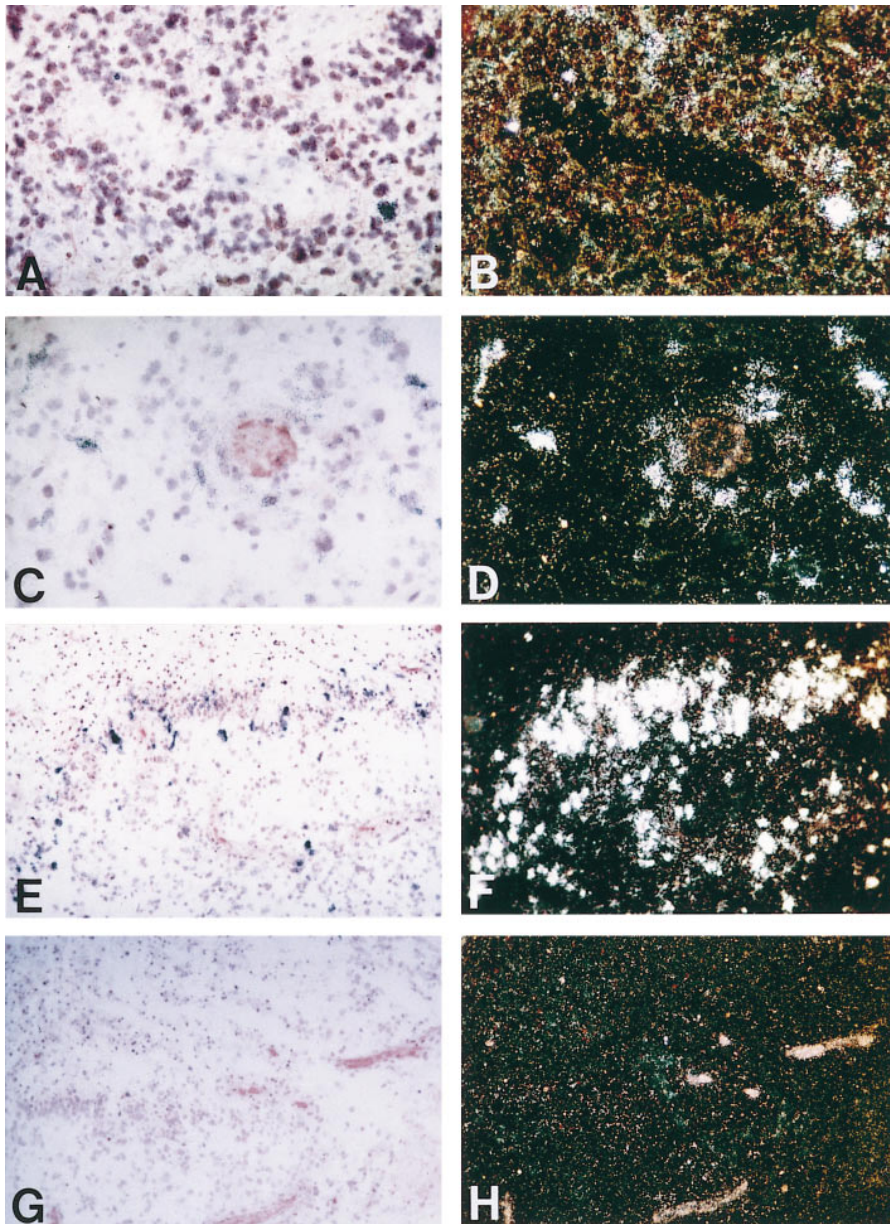
induce anoxia, cells were incubated in an Oxoid gas generating anaerobic system chamber (Unipath Ltd., Hamshire, UK) using hydrogen, CO<sub>2</sub>, and a palladium catalyst to remove all traces of oxygen (final anoxic conditions: 93% hydrogen, 7% CO<sub>2</sub>). Cells (1.5 × 10<sup>6</sup>) were plated in tissue culture dishes 48 h before anoxic induction. When the cultures reached 80% confluence, fresh culture medium (DMEM–5% FCS) was added and dishes were incubated under normoxic or anoxic conditions for different times. To allow spheroid formation, LN-229 cells were trypsinized and 2 × 10<sup>4</sup> cells were seeded in 0.5% agar-coated wells (GIBCO BRL, Gaithersburg, MD). Culture medium was changed every 2 d and spheroids were incubated for 4–11 d until necrosis formation. Spheroids were then embedded in Tissue-Tek OCT4583 (Miles Inc., Elkhart, IN) and snap frozen in liquid nitrogen. Serial sections of 5-μm thickness were then processed for *in situ* hybridization or immunohistochemistry.

**Preparation of Conditioned Media for Measurement of IL-8 Production by ELISA.** Culture supernatants of LN-229 were collected after 4, 12, and 24 h under normoxic or hypoxic conditions, centrifuged at 1,000 *g*, aliquoted, and stored at –80°C until tested. ELISA was done in duplicate using a commercially available assay system according to the manufacturer's instructions (R&D Sys. Inc., Minneapolis, MN). The minimal detection limit was 3 pg/ml of recombinant human IL-8 in the culture medium.

**Tissue Specimens and Immunohistochemistry.** Astrocytoma specimens and nontumoral brain tissue from pharmacoresistant epilepsy patients were snap frozen in refrigerated isopentane and stored at –80°C. Cyostat tissue or spheroid sections were incubated with optimal concentrations of the following primary antibodies: anti-IL-8 hybridoma 46E5 (31), anti-CXCR1/IL-8RA hybridoma 5A12-5, anti-CXCR2/IL-8RB hybridoma 6C6-1C (18), anti-DARC polyclonal antibody 6615 and corresponding rabbit preimmune serum (32), and purified monoclonal antibody preparations against glial fibrillary acidic protein (GFAP) clone 6F2 (Dako, Copenhagen, Denmark), T cell marker CD3 clone SK7 (Becton Dickinson, Basel, Switzerland), and isotype-matched mouse immunoglobulins as negative controls (Dako). The sections were then incubated for 25 min with a biotinylated anti-mouse IgG horse antibody (Vector Labs., Burlingame, CA), followed by a 25-min incubation with peroxidase-labeled avidin. The chromogens used were 3-amino-9-ethylcarbazole (Sigma Chemical Co., St. Louis, MO) or 3,3'-diaminobenzidine (Fluka Chemie AG, Buchs, Switzerland). Counterstaining was done with hematoxylin for 30 s.

**RNA Extraction and Reverse Transcriptase/PCR.** Total RNA from resected human astrocytomas (5 grade II, 7 grade III, and 12 grade IV) and from four cell lines (LN-229, T98G, LN-Z308, and U87MG) were extracted with TRIzol Reagent as described by the manufacturer (GIBCO BRL). The reverse transcription (RT)/PCR was done with 1 μg of total RNA as previously described (11). The following primer pairs were used; annealing temperatures, MgCl<sub>2</sub> concentrations, and amplicon sizes are indicated in brackets. For IL-8: 5' primer (5' ATG ACT TCC AAG CTG GCC GTG 3'), and 3' primer (5' CTC TTC AAA AAC TTC TCC CGA CTC TTA AGT ATT 3') [65°C, 1.5 mM, 298 bp]; for CXCR1: primer A (5' GAG GTT GTG TGT GGA AGG TG 3'), and primer B (5' AGG TTG ATG TTT TGG CAG TG 3') [64°C, 1 mM, 476 bp]; for CXCR2: primer A (5' GCT CTA GAG CTG GGC AAC AAT ACA GCA AACT 3') and primer B (5' CCA TCG ATG GGC ACT TAG GCA GGA GGT CTTA 3') [60°C, 1.5 mM, 493 bp]. RT controls included reactions without mouse Moloney leukemia virus (MMLV) reverse transcriptase and without RT product.

<sup>1</sup>Abbreviations used in this paper: DARC, Duffy antigen receptor for chemokines; GFAP, glial fibrillary acidic protein; mRNA, messenger RNA; RT, reverse transcription; VEGF, vascular endothelial growth factor.



**Figure 1.** Detection of IL-8 mRNA in glioblastoma sections by in situ hybridization. (A-F) Antisense IL-8 cRNA probe, (G and H) sense IL-8 cRNA probe (negative control). Sections were derived from glioblastoma No. 921 for A and C (bright field) and B and D (dark field), and glioblastoma No. 882 for E and G (bright field) and F and H (dark field). (A and B) were also used for immunohistochemistry with an anti-GFAP antibody (A, red filaments; B, green filaments). (E-H) Pseudopalisading cells separate a necrotic tumor area with numerous dying cells with pyknotic nuclei (top) from a viable richly vascularized tumor area (bottom). Bright areas in H are tumor vessels.

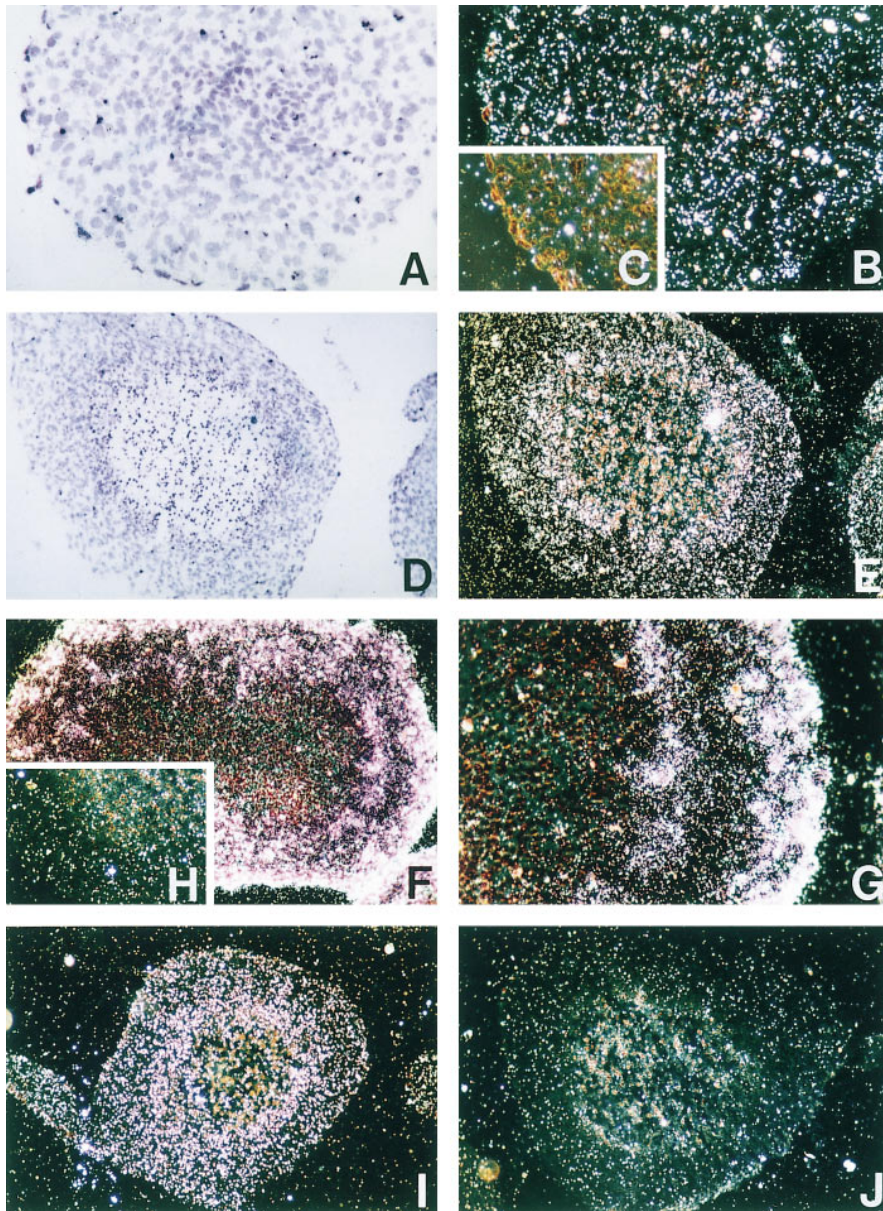
**Northern Blot Analysis.** 10  $\mu$ g of RNA/sample were electrophoresed through a 1% agarose formaldehyde gel and blotted onto a nitrocellulose membrane (Hybond N; Amersham, Aylesbury, UK) as previously described (11). The blots were hybridized with the following probes labeled by random primed DNA labeling kit (Boehringer Mannheim, Indianapolis, IN): a 298-bp PCR fragment of IL-8 cDNA (see above), a 500-bp EcoRI-BamHI fragment of human vascular endothelial growth factor (VEGF) cDNA (plasmid pBluescript KS-VEGF), a 1,100-bp PstI fragment of  $\beta$  actin cDNA (plasmid pAL41), and a 280-bp EcoRI fragment of the bovine 28S ribosomal DNA gene.

**In Situ Hybridization.** In situ hybridization was performed as previously described (11) using the following cRNA sense and antisense probes labeled with  $^{35}$ S-UTP during in vitro transcription reactions with T3 or T7 RNA polymerase: a 240-bp PstI-EcoRI fragment of the IL-8 cDNA, a 477-bp EcoRI-XhoI CXCR1 cDNA fragment (33), a 1,510-bp EcoRI-XhoI CXCR2

cDNA fragment (34), and, as a positive control, a BamHI-EcoRI VEGF<sub>165</sub> cDNA fragment.

## Results

Previous work established that IL-8 is produced in patients with all grades of astrocytoma progression. Interestingly, immunohistochemistry showed predominant IL-8 localization on tumor cells or macrophages in perivascular areas with leukocytic infiltrates and on pseudopalisading cells surrounding necrosis (12), a spatial pattern that is compatible with a role in chemotaxis and/or angiogenesis. However, localization of cytokine secretion sites on this basis may be misleading and be the result of cytokine sequestration rather than production. To unequivocally identify the

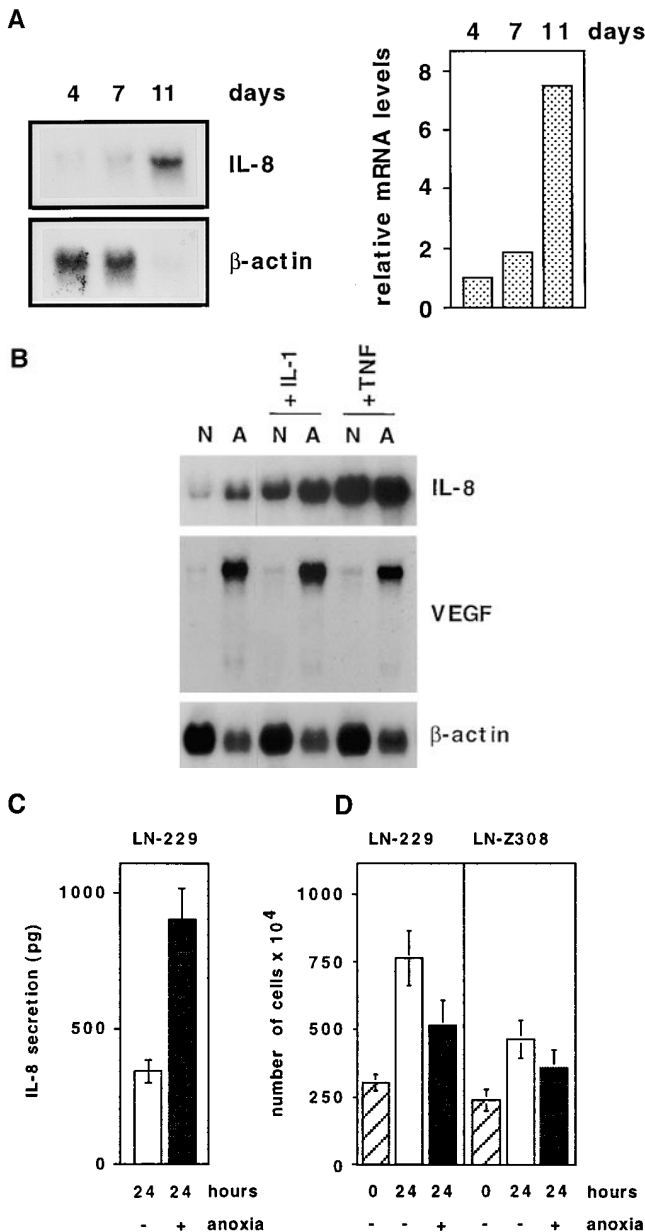


**Figure 2.** Detection of IL-8 and VEGF mRNAs on spheroid sections of glioblastoma cell line LN-229 by in situ hybridization. (A, B, and D–G) Antisense IL-8 cRNA probe, (C and H) sense IL-8 cRNA probe (negative control). Green area in H corresponds to necrosis. (J) Antisense VEGF cRNA probe. (K) VEGF cRNA probe (negative control). (A–C) 4-d-old spheroid, magnification of 20; (D–J) 10-d-old spheroids with central necrosis, magnification of 10. Spheroid in F and G was incubated for 24 h with TNF (100 U/ml) before sectioning.

IL-8 producer cells in these areas, we performed in situ hybridization with sense and antisense IL-8 cRNA probes on ex vivo glioblastoma samples. IL-8 messenger RNA (mRNA) was found in areas surrounding blood vessels, both in those showing a lumen (Fig. 1, A and B) and in those with glomeruloid microvascular proliferation (Fig. 1, C and D) characteristic of glioblastoma (1). This confirms the spatial pattern of expression observed previously with in situ immunodetection (12). Moreover, elevated IL-8 mRNA levels were observed in cells surrounding necrosis (Fig. 1, E and F). These cells form a particular structure called pseudopalisade and are believed to undergo severe stress due to oxygen deprivation (1). Controls with sense probes on adjacent sections were negative (Fig. 1, G and H). Staining of these sections (Fig. 1 A) or adjacent sections (not shown) with an antibody against GFAP, a glial lineage marker, suggested

that the cells expressing IL-8 mRNA were either of glial origin (astrocytoma cells or reactive astrocytes) or cells infiltrating the tumor in areas with intricate patterns of GFAP expression.

The correlation of IL-8 expression and tumor cell proximity to necrosis prompted us to investigate whether there was a causal relationship. Therefore, we used an experimental model system in which necrosis forms at the center of a multicellular tumor spheroid (35, 36). These spheroids can be easily manipulated in vitro, the appearance of necrosis is dependent on spheroid size (150–300  $\mu\text{M}$  diameter), and measurement of oxygen content in the necrotic region showed that it was anoxic (35). Another advantage of this model is that it allows examination of inducing events linked to necrosis formation without the in vivo complications linked to the presence of nontumoral cells (microvessel

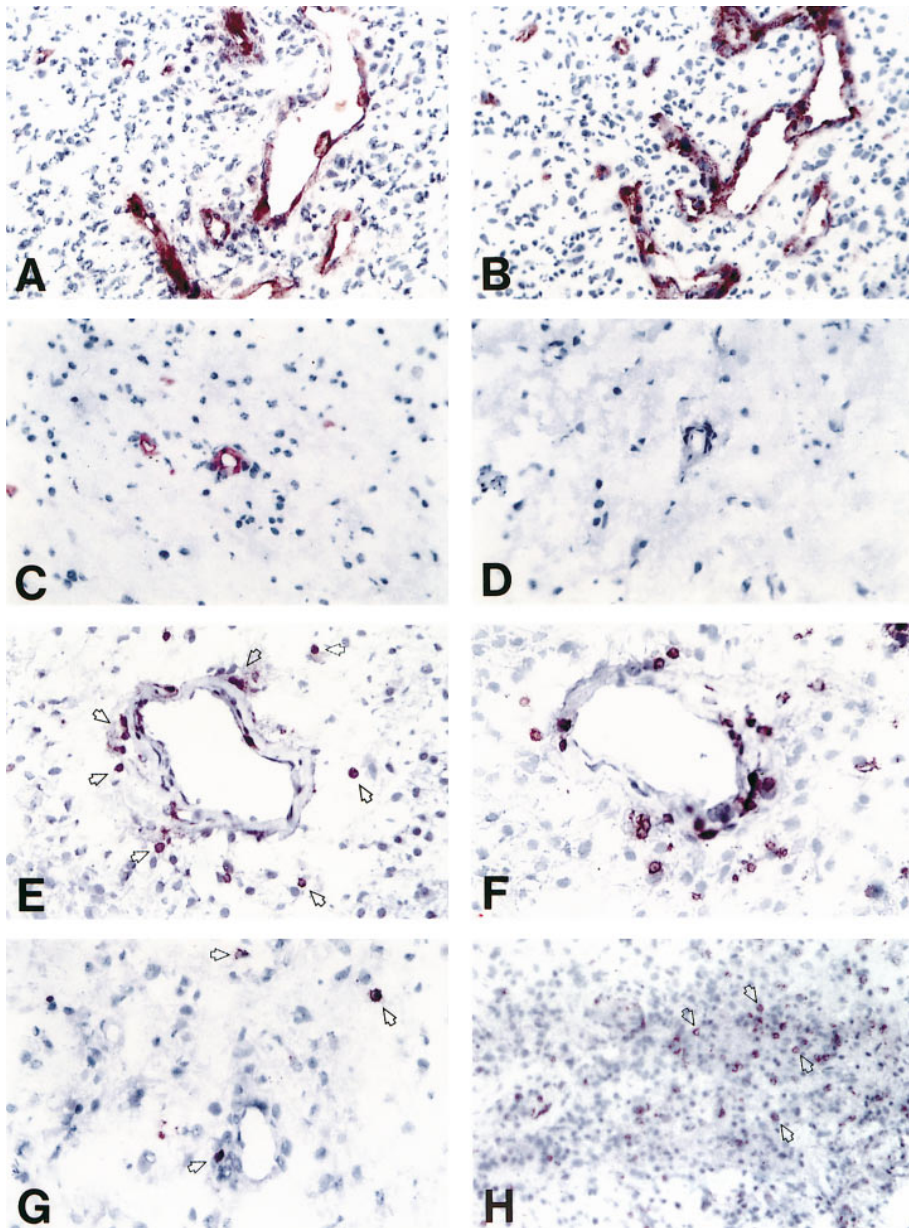


**Figure 3.** Measurement of IL-8 mRNA and protein levels in glioblastoma cells exposed to anoxia. (A) Time course of IL-8 mRNA levels in LN-229 glioblastoma cell spheroids by Northern blotting (left) and graphical display of relative mRNA levels (right). 10  $\mu$ g of total RNA extracted from 4-, 7-, and 11-d-old spheroids is displayed in each lane. (This normalizes for cell content in spheroids.) (B) Northern blot with RNA extracted from LN-229 glioblastoma cells, incubated for 24 h in an anoxia-generating chamber system. N, normoxia; A, anoxia; IL-1, simultaneous IL-1 $\beta$  treatment at 10 U/ml for 24 h; TNF, TNF- $\alpha$  treatment at 100 U/ml for 24 h. (C) Measurement of IL-8 by ELISA (picogram per milligram of total cellular protein) in conditioned media of LN-229 cells after 24 h of normoxic (white column) or anoxic (black column) treatment. Standard deviations (vertical bars) of triplicates were calculated. (D) Analysis of cell number and viability of glioblastoma cell lines upon anoxic treatment. LN-229 (left) and LN-Z308 (right) glioblastoma cells were stained with trypan blue and counted before (hatched columns) and after a 24-h treatment under normoxic (white columns) or anoxic (black columns) conditions. Standard deviations of triplicates (vertical bars) were calculated. The amount of cells permeable to trypan blue was insignificant and is not presented in the graph.

cells, microglia, and infiltrating leukocytes). Spheroids were produced from glioblastoma cells and analyzed for IL-8 mRNA expression by in situ hybridization and Northern blotting before and after appearance of central necrosis. Slight constitutive IL-8 mRNA expression was found in small spheroids without necrosis (diameter of <150  $\mu$ m) under the culture conditions used (Fig. 2, A and B); this likely reflects serum stimulation of IL-8 expression as previously shown in monolayer cultures (12). In larger spheroids (>10 d old) with central necrosis, a ring-like augmentation of IL-8 mRNA levels was observed (Fig. 2, D and E). This increase in IL-8 mRNA could be the result of an inductive event in the stressed cells lining necrosis or an inhibition of IL-8 mRNA expression in the peripheral cell layer at the contact of culture medium. To discriminate between these two possibilities, we incubated the spheroids with TNF- $\alpha$ , an inflammatory cytokine known to induce IL-8 mRNA production. Increase of IL-8 mRNA was now observed both in the cells lining necrosis and in those at the periphery of the spheroid (Fig. 2, F and G), showing that the peripheral cells have not become refractory to an IL-8-inducing stimulus. In situ hybridization of these spheroids with a VEGF antisense probe (Fig. 2 J) showed that the mRNA increases observed for both IL-8 and VEGF were similar in both intensity and perinecrotic localization. Control sense cRNA probes for IL-8 (Fig. 2, C and H) and VEGF (Fig. 2 J) were negative.

To obtain a quantitative estimate of the increase in IL-8 mRNA production as a result of necrosis development over time, we performed Northern blotting on 10  $\mu$ g total RNA (thus normalizing for differences in cell numbers between young and old spheroids) extracted from 4-, 7-, and 11-d-old spheroids. Total IL-8 mRNA content of spheroids increased significantly from days 4 to 7 by 2-fold, and from days 4 to 11 by 7.5-fold (Fig. 3 A). These results demonstrate that establishment of a necrotic area in glioblastoma spheroids is sufficient to generate an increase in IL-8 mRNA steady state levels in glioblastoma cells, and that this induction is not dependent on nontumoral accessory cells.

Induction of IL-8 expression could be the direct result of physiological conditions of minimal oxygen supply or related to the presence of factors produced either by dying cells or liberated by cell lysis during necrosis. To discriminate between these possibilities, we placed monolayer glioblastoma cell cultures under experimental conditions of oxygen deprivation using anaerobic chambers (see Materials and Methods). These chambers generate complete anoxia within a time frame of 6–8 h due to oxygen consumption by a palladium catalyst. Using this system we were able to demonstrate an increase in IL-8 mRNA levels, as do IL-1 or TNF treatments, in glioblastoma cell lines LN-229 (Fig. 3 B), U87MG, LN-Z308, and T98G (not shown), a panel representative of the genetic and biological heterogeneity of glioblastoma (37). IL-8 mRNA peaked between 12 and 24 h after induction (not shown) and resulted in augmentation of secreted IL-8 in culture medium as measured by ELISA (Fig. 3 C). Similar results were obtained in cells in-

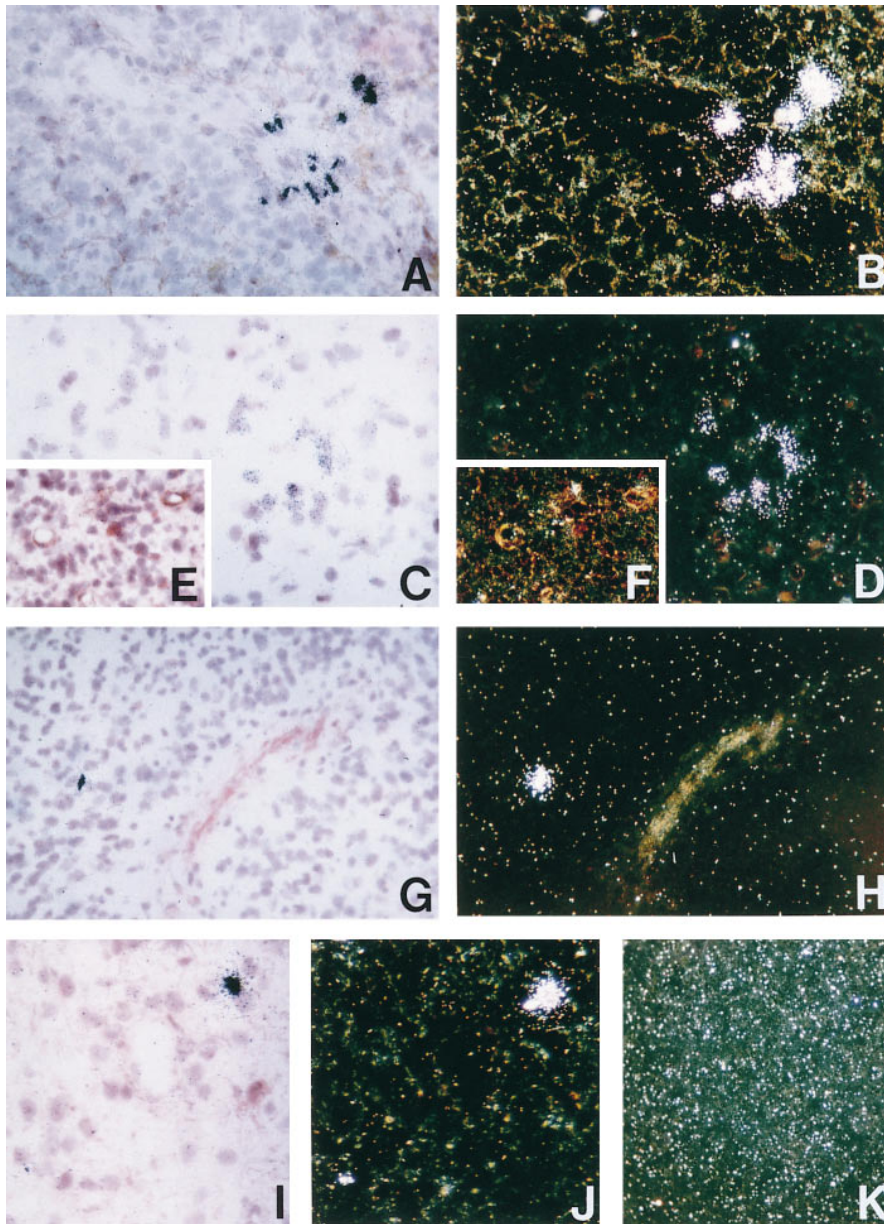


**Figure 4.** Detection of IL-8-binding receptors in glioblastoma by immunohistochemistry. DARC (A) and factor VIII (B) expression on microvascular cells of glioblastoma No. 1069. DARC (C) and preimmune serum (D) staining on nontumoral brain No. T265CN. CXCR1 (E) and CD3 (F) staining on glioblastoma No. 906. CXCR2 staining on sections with vessels (G) or in a perinecrotic region (H) of glioblastoma No. 842. Examples of positive cells are shown by arrows.

cubated under a gas mixture composed of 95% N<sub>2</sub> and 5% CO<sub>2</sub> (not shown). Cell counting before and after the 24-h anoxic treatment showed moderate reduction in cell numbers (by 20–30%) as compared to untreated cells (Fig. 3 D), due to a reduced proliferation rate under anoxia. Examination of morphology and membrane integrity by exclusion of trypan blue did not show loss of cell viability and there was no cell detachment from the monolayer. This demonstrates that IL-8 induction is not due to cell products released from lysing cells, but rather a biological response to anoxic stress. Furthermore, the induction was obtained irrespective of the endogenous wild-type or mutant p53 gene status of the cell lines analyzed (37), suggesting that it was not linked to hypoxia-induced p53 (38). This is particularly relevant since consensus binding sites for the p53

transcription factor (39) are present in the IL-8 gene. To directly evaluate whether WTp53 could increase IL-8 mRNA levels, we used a clone of glioblastoma cell line T98G in which WTp53 expression can be conditionally induced by dexamethasone (40). No difference in IL-8 mRNA content was found in p53-induced and noninduced cells by Northern blotting (not shown).

The biological relevance of IL-8 expression in glioblastoma depends on the presence of cells with receptors capable of binding IL-8. Therefore, we evaluated whether IL-8 might have autocrine and/or paracrine functions in vivo. First, we examined CXCR1, CXCR2, and DARC mRNA expression by RT/PCR. CXCR1 mRNA was found in 5 of 5 grade II, 1 of 7 grade III, and 8 of 12 grade IV astrocytoma. CXCR2 mRNA was found in 5 of 5 grade II, 6 of 7



**Figure 5.** Detection of IL-8-binding receptors CXCR1 and CXCR2 mRNAs in glioblastoma sections by in situ hybridization. (A–D) Antisense CXCR1 cRNA probe, (E and F) negative control sense CXCR1 cRNA probe, (G–J) antisense CXCR2 cRNA probe, (K) negative control sense CXCR2 cRNA probe. Sections were derived from glioblastoma No. 921 for A and G (bright field) and B and H (dark field), glioblastoma No. 892 for C and E (bright field) and D and F (dark field), and glioblastoma No. 882 for I (bright field), J and K (dark field). Immunohistochemistry with an anti-GFAP antibody was used for sections A and B (A, red filaments, and B, green-brown filaments) and with an anti-smooth muscle actin antibody for E and F.

grade III, and 11 of 12 grade IV. DARC mRNA was found in 3 of 5 grade II, 5 of 7 grade III, and 10 of 12 grade IV (results not shown). This suggested that IL-8 may serve a biological function during the progression of human astrocytoma in vivo, either on tumor cells or on accessory cells. Next, we examined which cell types expressed IL-8-binding receptors in vivo by immunohistochemistry (representative stainings are shown in Fig. 4). Very interestingly, DARC was specifically expressed by microvascular cells in 5 of 6 grade II, 5 of 6 grade III, and 14 of 19 grade IV astrocytomas (Fig. 4 A) with a staining pattern similar to the one obtained for factor VIII, a microvascular marker (Fig. 4 B). DARC expression was also present on 5 of 5 nontumoral brains (Fig. 4 C). Control stainings with preimmune serum was negative on all samples (Fig. 4 D). In contrast,

for both CXCR1 and CXCR2, isolated positive cells were found surrounding blood vessels. For CXCR1, 2 of 9 grade II, 1 of 3 grade III, and 5 of 18 grade IV were positive (Fig. 4 E), and for CXCR2, 1 of 9 grade II, 0 of 3 grade III, and 5 of 18 grade IV (Fig. 4 G). Staining of adjacent sections for CD3, a specific marker of T lymphocytes (Fig. 4 F), and CD15, a macrophage marker (not shown), showed infiltrates in these areas, suggesting expression by a subset of T lymphocytes and/or macrophages. Unfrequently, numerous CXCR2 positive cells were found close to necrosis (Fig. 4 H).

To confirm the CXCR1- and CXCR2-expressing cells detected by immunohistochemistry, we performed in situ hybridization on three glioblastomas. Specific signals for both CXCR1 (Fig. 5, A–D) and CXCR2 (Fig. 5, G–J)

mRNAs were found on small isolated cells surrounding vessels, with a morphology compatible with lymphoid or myeloid infiltrates. Double staining with an anti-GFAP antibody failed to associate these cells with GFAP filaments (Fig. 5 A). Control with sense probes for CXCR1 (Fig. 5, E and F) and CXCR2 (Fig. 5 K) were negative. These data are consistent with expression by infiltrating leukocytes and confirm immunostaining results.

## Discussion

Morphological examination of the malignant progression of astrocytoma shows that the transition to the most malignant form (glioblastoma) is defined by the appearance of necrosis (1). It is intriguing that a decrease in physiological oxygen pressure, ultimately lethal to tumor cells, coincides with maximal tumor aggressiveness. This raises the question as to whether the hypoxic/ischemic conditions increasing at this stage are a consequence or a cause of increased malignancy. The appearance of necrosis is also closely associated with the ultimate changes in the angiogenic phenotype of glioblastoma. The mRNA for VEGF, an endothelial-specific angiogenic mitogen, is upregulated by hypoxia in glioma cells *in vitro* and is overexpressed in cells lining necrotic areas *in vivo* (41, 42, 36). VEGF receptor type 2 mRNA is upregulated on endothelial cells in glioblastoma, and studies with animal models of glioma have shown that vessel development and tumor growth were partially inhibited by anti-VEGF antibodies (43), overexpression of a dominant negative VEGF receptor mutant (44), or antisense VEGF gene constructs (45, 46). These results demonstrate that hypoxic regulation of VEGF is of biological consequence for the angiogenic phenotype associated with the transition to the most malignant form of astrocytoma. The factors inducing neovascularization in the early phases of astrocytoma development are less well characterized (3). The presence of residual tumor upon anti-VEGF treatment further suggests that more than one factor ensures angiogenic supply to support astrocytoma growth.

Finally, because astrocytoma cells also secrete angiogenic inhibitors (47) and cytokines such as IL-6 (30) or leukemia inhibitory factor (LIF) (our unpublished results) with anti-angiogenic properties (48), the final angiogenic response will be determined by the balance between positive and negative regulators (2).

Here we demonstrate that IL-8, another soluble biological mediator with angiogenic and chemotactic properties, is upregulated in cells surrounding necrosis in glioblastoma and that IL-8-binding receptors are concomitantly expressed *in vivo*. IL-8 is the best studied member of the chemokines, a class of cytokines extensively analyzed for their ability to attract and activate leukocytes during inflammation (see review in reference 13). It has previously been demonstrated that upon induction by inflammatory cytokines IL-1 and TNF astrocytoma cells release a variety of cytokines *in vitro*, including biologically active IL-8 (see review in reference 49). *In vivo*, it was unclear whether cytokine expression resulted from indirect induction by tu-

mor-related inflammatory responses or was directly linked to tumor growth and progression.

We now confirm the presence of IL-8 expression in astrocytoma and show that it is likely to occur by two distinct mechanisms during the progression of astrocytoma. Initial upregulation may be mediated by stimulatory signals such as proinflammatory cytokines (e.g., IL-1 or TNF), which induce IL-8 in astrocytoma cells *in vitro* and can be present in glioma, in glioma-associated cyst fluid, and in cerebrospinal fluid derived from glioma patients (see review in reference 49). Later in disease progression, strong IL-8 upregulation is observed in cells surrounding necrotic areas in glioblastoma, suggesting further induction by hypoxia/ischemia. This hypothesis was sustained by increased IL-8 mRNA and protein expression upon *in vitro* exposure of glioblastoma cells to anoxia as monolayer cultures or in the central necrosis of three-dimensional spheroids. These experiments further showed that this increase was not dependent on nontumoral accessory cells or on stimulation by factors released by dying tumor cells. Thus, IL-8 increase in late stage astrocytoma is most likely to be due to physiological changes in oxygen pressure occurring during tumor growth, although we cannot exclude participation of accessory cells such as macrophages, microglia, or reactive astrocytes *in vivo*.

The influence of altered oxygen concentrations on IL-8 expression has previously been demonstrated in the context of ischemia reperfusion. Human umbilical vein endothelial cells were shown to upregulate IL-8 during hypoxia (50) as were monocytes during reoxygenation (51). Here, we show that similar IL-8-inducing events may occur in the pathologic process of cancer. Tumor cells and/or tumor-infiltrating macrophages or microglia upregulate IL-8 expression which may play important functions in tumor angiogenesis and tumor immune interactions through paracrine stimulation of cognate receptors. Upregulation of IL-8 in tumor endothelial cells was not observed in astrocytoma, and may reflect differences in endothelial subtypes, the abnormal structure of the tumor endothelium, as well as tissue environment (12) or rapid internalization after binding to DARC (52).

IL-8 induction is relevant to the biology of the tumor since we detected the expression of IL-8 receptor mRNA and protein. Tumor cells did not express IL-8 receptors *in vivo* demonstrating that IL-8 does not participate in an autocrine growth regulatory loop mediated by any of these three receptors. However, IL-8 receptor expression pattern suggests two functions for IL-8 in astrocytoma.

First, the constitutive expression of the DARC receptor on normal brain and tumor microvasculature supports an angiogenic function for IL-8 in astrocytoma. This is sustained by a recent report in which the angiogenic factors present in the supernatant of glioma cell lines were evaluated in an *in vitro* angiogenic assay using human microvascular endothelial cells. The authors showed with antibody neutralization assays that the angiogenic response was primarily due to IL-8 or the combination of VEGF and bFGF, depending on the cell line analyzed (53). Clearly,



further in vivo studies will have to establish whether IL-8 and other angiogenic chemokines are essential contributors to the angiogenic response seen in astrocytoma, whether this response is mediated by DARC, and whether they act in synergy with VEGF or represent alternative angiogenic routes. This is, to our knowledge, the first report of DARC expression on tumor vasculature. The presence of DARC on normal endothelial cells lining postcapillary venules in kidney, spleen, lung, and brain (32, 29, 54), cells potentially constitutively responsive to IL-8, may implicate DARC in early tumor angiogenesis. It is noteworthy that this vascular staining is not the result of vessel cell or extracellular matrix binding of DARC released from erythrocytes, since this staining was maintained in individuals lacking erythroid DARC gene expression, due to a mutation disrupting a binding site for the GATA1 erythroid transcription factor in the DARC gene promoter (52, 55). Furthermore, these results designate DARC as a prime candidate endothelial receptor to explain endothelial cell binding and direct angiogenic responses mediated by IL-8 (20–22, 56, 57). This should stimulate the deciphering of the downstream effector mechanisms, likely the demonstration that DARC elicits an intracellular signal upon ligand binding in microvascular cells. Lastly, due to the promiscuous nature of the DARC receptor, a variety of C-C and C-X-C chemokines expressed by astrocytoma (see review in reference 49) may bind tumor microvascular cells. The convergence of a large panel of potentially angiogenic cytokines (58) in the use of a single microvascular receptor, might designate DARC as a target of choice for therapeutic interference at what might become the “Achilles’ heel” of chemokine redundancy.

Second, the expression of CXCR1 and CXCR2 on a subset of infiltrating lymphoid and/or myeloid cells is compatible with a role for IL-8 as chemotactic and activating agent for leukocytes in astrocytoma, as suggested in other systems (14, 15, 17–19). It will be of interest to further characterize this leukocyte subset and to study its function

in the tumor immune system relationship and as an indirect elicitor of angiogenesis through cytokine release (59, 60). It should also be mentioned that if IL-8 chemoattracts T lymphocytes, other astrocytoma-expressed leukocyte chemoattractants, such as MCP-1 (11, 61) are certainly involved, since CXCR1 and CXCR2 expression was found on only a fraction of leukocytic infiltrates. The reasons for the rare occurrence of neutrophils in astrocytoma/glioblastoma despite functional IL-8 inducing signals are unknown and were previously discussed (12). Additional hypotheses include inappropriate expression of homing signals, such as specific selectins (62), potential killing of Fas-expressing neutrophils (63) by Fas ligand expressed by tumor cells (64, 65), disappearance/physiological downregulation by receptor desensitization (66), excessive release of IL-8 in circulation leading to saturation (67), or inactivation of chemoattractant ability due to cleavage by aminopeptidase N (CD13) (68).

In conclusion, our results support a model where early in astrocytoma development tumor-related inflammatory responses trigger IL-8 and VEGF release. This would elicit direct and/or indirect angiogenic responses through binding of IL-8 to the DARC receptor expressed constitutively on brain microvascular cells and CXCR1 and CXCR2 receptors on leukocytes. Chemoattracted leukocytes infiltrate the tumor and their activation induces release of cell products/cytokines with angiogenic potential. VEGF release induced by inflammatory signals might exert its first action when VEGFR1 expression appears in low grade astrocytoma (3). Later in astrocytoma progression and in de novo glioblastoma, induction of IL-8 and VEGF production by reduced oxygen pressure and appearance of expression of VEGFR2 (3) would further contribute, besides other factors, to the florid microvascular proliferation characteristic of glioblastoma. The understanding of the molecular mechanisms at the origin of tumor neovascularization, especially at early disease stages, should permit the development of new therapeutic modalities targeted at specific angiogenic effectors.

---

We would like to thank Drs. M. Buckingham, J.F. Brunet, W.E. Holmes, H. Marti, P.M. Murphy, A.O. Pogo, S.X. Qin, M. Sticherling, and H. Weich for plasmids, antibodies, and nontumoral brain samples. We would also like to show our appreciation to Drs. P.-Y. Dietrich, M. Gassmann, R. Kessler, M. Pepper, A.O. Pogo, E. Reichmann, and P.R. Walker for helpful advice and reading the manuscript.

This work was supported by Swiss National Science Foundation grants no. 31-39634.93 (to N. de Tribolet), 31-39356, and 4037-044729 (to E.G. Van Meir), by the Swiss Cancer Research Foundation grant KFS172-9-1995 (to E.G. Van Meir), by the Swiss and Vaud Anti-Cancer Leagues grants FOR254 and SKL116-7-1995 (to N. de Tribolet) and the San Salvatore Foundation (to E.G. Van Meir).

Address correspondence to Erwin G. Van Meir, Laboratory of Tumor Biology and Genetics, Neurosurgery Department, University Hospital (CHUV), 1011 Lausanne, Switzerland. Phone: +41-21-314-2582; FAX: +41-21-314-2587; E-mail: [evanmeir@hola.hospvd.ch](mailto:evanmeir@hola.hospvd.ch)

*Received for publication 6 May 1997 and in revised form 23 July 1997.*

## References

1. Kleihues, P., P.C. Burger, and B.W. Scheithauer. 1995. Histological typing of tumors of the central nervous system. Springer-Verlag, Berlin. 11–14.
2. Hanahan, D., and J. Folkman. 1996. Patterns and emerging mechanisms of the angiogenic switch during tumorigenesis. *Cell*. 86:353–364.
3. Plate, K.H., and W. Risau. 1995. Angiogenesis in malignant gliomas. *Glia*. 15:339–347.
4. Brem, S., R. Cotran, and J. Folkman. 1972. Tumor angiogenesis: a quantitative method for histological grading. *J. Natl. Cancer Inst.* 48:347–356.
5. Paine, J.T., H. Handa, T. Yamasaki, J. Yamashita, and S. Miyatake. 1986. Immunohistochemical analysis of infiltrating lymphocytes in central nervous system tumors. *Neurosurgery (Baltim.)*. 18:766–772.
6. Kuppner, M.C., M.F. Hamou, and N. de Tribolet. 1988. Immunohistological and functional analyses of lymphoid infiltrates in human glioblastomas. *Cancer Res.* 48:6926–6932.
7. Rossi, M.L., N.R. Jones, E. Candy, J.A. Nicoll, J.S. Compton, J.T. Hughes, M.M. Esiri, T.H. Moss, F.F. Cruz Sanchez, and H.B. Coakham. 1989. The mononuclear cell infiltrate compared with survival in high-grade astrocytomas. *Acta Neuropathol.* 78:189–193.
8. Stavrou, D., A.P. Anzil, W. Weidenbach, and H. Rodt. 1977. Immunofluorescence study of lymphocytic infiltration in gliomas. Identification of T-lymphocytes. *J. Neurol. Sci.* 33:275–282.
9. Kuppner, M.C., M.-F. Hamou, and N. de Tribolet. 1990. Activation and adhesion molecule expression on lymphoid infiltrates in human glioblastomas. *J. Neuroimmunol.* 29:229–238.
10. Rosenman, S.J., P. Shrikant, L. Dubb, E.N. Benveniste, and R.M. Ransohoff. 1995. Cytokine-induced expression of vascular cell adhesion molecule-1 (VCAM-1) by astrocytes and astrocytoma cell lines. *J. Immunol.* 154:1888–1899.
11. Desbaillets, I., M. Tada, N. de Tribolet, A.C. Diserens, M.F. Hamou, and E.G. Van Meir. 1994. Human astrocytomas and glioblastomas express monocyte chemoattractant protein-1 (MCP-1) in vivo and in vitro. *Int. J. Cancer.* 58:240–247.
12. Van Meir, E.G., M. Ceska, F. Effenberger, A. Walz, E. Grouzmann, I. Desbaillets, K. Frei, A. Fontana, and N. de Tribolet. 1992. Interleukin-8 is produced in neoplastic and infectious diseases of the human central nervous system. *Cancer Res.* 52:4297–4305.
13. Baggolini, M., B. Dewald, and B. Moser. 1994. Interleukin-8 and related chemotactic cytokines—CXC and CC chemokines. *Adv. Immunol.* 55:97–179.
14. Larsen, C.G., A.O. Anderson, E. Appella, J.J. Oppenheim, and K. Matsushima. 1989. The neutrophil-activating protein (NAP-1) is also chemotactic for T lymphocytes. *Science (Wash. DC)*. 243:1464–1466.
15. Leonard, E.J., A. Skeel, T. Yoshimura, K. Noer, S. Kutvirt, and D. Van Epps. 1990. Leukocyte specificity and binding of human neutrophil attractant/activation protein-1. *J. Immunol.* 144:1323–1330.
16. Wilkinson, P.C., and I. Newman. 1992. Identification of IL-8 as a locomotor attractant for activated human lymphocytes in mononuclear cell cultures with anti-CD3 or purified protein derivative of *Mycobacterium tuberculosis*. *J. Immunol.* 149:2689–2694.
17. Babi, L.F.S., B. Moser, M.T.P. Soler, R. Moser, P. Loetscher, B. Villiger, K. Blaser, and C. Hauser. 1996. The interleukin-8 receptor B and CXC chemokines can mediate transendothelial migration of human skin homing T cells. *Eur. J. Immunol.* 26:2056–2061.
18. Qin, S.X., G. Larosa, J.J. Campbell, H. Smithheath, N. Kasam, X.J. Shi, L. Zeng, E.C. Butcher, and C.R. Mackay. 1996. Expression of monocyte chemoattractant protein-1 and interleukin-8 receptors on subsets of T cells—correlation with transendothelial chemotactic potential. *Eur. J. Immunol.* 26:640–647.
19. Ross, J.S., K. Mistry, K.B. Bacon, and R.D. Camp. 1991. Characterisation of the in vitro responsiveness of lymphocyte subsets to locomotor stimuli by immunocytochemical methods. *J. Immunol. Methods.* 140:219–225.
20. Koch, A.E., P.J. Polverini, S.L. Kunkel, L.A. Harlow, L.A. Di Pietro, V.M. Elner, S.G. Elner, and R.M. Strieter. 1992. Interleukin-8 as a macrophage-derived mediator of angiogenesis. *Science (Wash. DC)*. 258:1798–1801.
21. Szekanecz, Z., M.R. Shah, L.A. Harlow, W.H. Pearce, and A.E. Koch. 1994. Interleukin-8 and tumor necrosis factor- $\alpha$  are involved in human aortic endothelial cell migration. The possible role of these cytokines in human aortic aneurysmal blood vessel growth. *Pathobiology.* 62:134–139.
22. Arenberg, D.A., S.L. Kunkel, P.J. Polverini, M. Glass, M.D. Burdick, and R.M. Strieter. 1996. Inhibition of interleukin-8 reduces tumorigenesis of human non-small cell lung cancer in SCID mice. *J. Clin. Invest.* 97:2792–2802.
23. Strieter, R.M., S.L. Kunkel, V.M. Elner, C.L. Martonyi, A.E. Koch, P.J. Polverini, and S.G. Elner. 1992. Interleukin-8. A corneal factor that induces neovascularization. *Am. J. Pathol.* 141:1279–1284.
24. Hu, D.E., Y. Hori, and T.P. Fan. 1993. Interleukin-8 stimulates angiogenesis in rats. *Inflammation.* 17:135–143.
25. Norrby, K. 1996. Interleukin-8 and de novo mammalian angiogenesis. *Cell Prolif.* 29:315–323.
26. Smith, D.R., P.J. Polverini, S.L. Kunkel, M.B. Orringer, R.I. Whyte, M.D. Burdick, C.A. Wilke, and R.M. Strieter. 1994. Inhibition of interleukin 8 attenuates angiogenesis in bronchogenic carcinoma. *J. Exp. Med.* 179:1409–1415.
27. Singh, R.K., M. Gutman, R. Radinsky, C.D. Bucana, and I.J. Fidler. 1994. Expression of interleukin 8 correlates with the metastatic potential of human melanoma cells in nude mice. *Cancer Res.* 54:3242–3247.
28. Premack, B.A., and T.J. Schall. 1996. Chemokine receptors: gateways to inflammation and infection. *Nat. Med.* 2:1174–1178.
29. Horuk, R., A. Martin, J. Hesselgesser, T. Hadley, Z.H. Lu, Z.X. Wang, and S.C. Peiper. 1996. The Duffy antigen receptor for chemokines: structural analysis and expression in the brain. *J. Leukocyte Biol.* 59:29–38.
30. Van Meir, E.G., Y. Sawamura, A.-C. Diserens, M.-F. Hamou, and N. de Tribolet. 1990. Human glioblastoma cells release interleukin 6 in vivo and in vitro. *Cancer Res.* 50:6683–6688.
31. Sticherling, M., J.M. Schroder, and E. Christophers. 1989. Production and characterization of monoclonal antibodies against the novel neutrophil activating peptide NAP/IL-8. *J. Immunol.* 143:1628–1634.
32. Chaudhuri, A., S. Nielsen, M.-L. Elkjaer, V. Zbrzezna, F. Fang, and A.O. Pogo. 1997. Detection of duffy antigen in the plasma membranes and caveolae of vascular endothelial and epithelial cells of nonerythroid organs. *Blood.* 89:701–712.

33. Holmes, W.E., J. Lee, W.J. Kuang, G.C. Rice, and W.I. Wood. 1991. Structure and functional expression of a human interleukin-8 receptor. *Science (Wash. DC)*. 253:1278–1280.
34. Murphy, P.M., and H.L. Tiffany. 1991. Cloning of complementary DNA encoding a functional human interleukin-8 receptor. *Science (Wash. DC)*. 253:1280–1283.
35. Mueller-Klieser, W.F., and R.M. Sutherland. 1982. Oxygen tensions in multicell spheroids of two cell lines. *Br. J. Cancer*. 45:256–264.
36. Shweiki, D., M. Neeman, A. Itin, and E. Keshet. 1995. Induction of vascular endothelial growth factor expression by hypoxia and by glucose deficiency in multicell spheroids: implications for tumor angiogenesis. *Proc. Natl. Acad. Sci. USA*. 92:768–772.
37. Van Meir, E.G., T. Kikuchi, M. Tada, H. Li, A.C. Diserens, B.E. Wojcik, H.-J.S. Huang, T. Friedmann, N. de Tribolet, and W.K. Cavenee. 1994. Analysis of the p53 gene and its expression in human glioblastoma cells. *Cancer Res*. 54:649–652.
38. Graeber, T.G., C. Osmanian, T. Jacks, D.E. Housman, C.J. Koch, S.W. Lowe, and A.J. Giaccia. 1996. Hypoxia-mediated selection of cells with diminished apoptotic potential in solid tumours. *Nature (Lond.)*. 379:88–91.
39. Kern, S.E., K.W. Kinzler, A. Bruskin, D. Jarosz, P. Friedman, C. Prives, and B. Vogelstein. 1991. Identification of p53 as a sequence-specific DNA-binding protein. *Science (Wash. DC)*. 252:1708–1711.
40. Mercer, W.E., M.T. Shields, M. Amin, G.J. Sauve, E. Appella, J.W. Romano, and S.J. Ullrich. 1990. Negative growth regulation in a glioblastoma tumor cell line that conditionally expresses human wild-type p53. *Proc. Natl. Acad. Sci. USA*. 87:6166–6170.
41. Plate, K.H., G. Breier, H.A. Weich, and W. Risau. 1992. Vascular endothelial growth factor is a potential tumour angiogenesis factor in human gliomas in vivo. *Nature (Lond.)*. 359:845–848.
42. Shweiki, D., A. Itin, D. Soffer, and E. Keshet. 1992. Vascular endothelial growth factor induced by hypoxia may mediate hypoxia-initiated angiogenesis. *Nature (Lond.)*. 359:843–845.
43. Kim, K.J., B. Li, J. Winer, M. Armanini, N. Gillett, H.S. Phillips, and N. Ferrara. 1993. Inhibition of vascular endothelial growth factor-induced angiogenesis suppresses tumour growth in vivo. *Nature (Lond.)*. 362:841–844.
44. Millauer, B., L.K. Shawver, K.H. Plate, W. Risau, and A. Ullrich. 1994. Glioblastoma growth inhibited in vivo by a dominant-negative Flk-1 mutant. *Nature (Lond.)*. 367:576–579.
45. Cheng, S.Y., H.J.S. Huang, M. Nagane, X.D. Ji, D.G. Wang, C. Shih, W. Arap, C.M. Huang, and W.K. Cavenee. 1996. Suppression of glioblastoma angiogenicity and tumorigenicity by inhibition of endogenous expression of vascular endothelial growth factor. *Proc. Natl. Acad. Sci. USA*. 93:8502–8507.
46. Saleh, M., S.A. Stacker, and A.F. Wilks. 1996. Inhibition of growth of C6 glioma cells in vivo by expression of antisense vascular endothelial growth factor sequence. *Cancer Res*. 56:393–401.
47. Van Meir, E.G., P.J. Polverini, V.R. Chazin, H.-J.S. Huang, N. de Tribolet, and W.K. Cavenee. 1994. Release of an inhibitor of angiogenesis upon induction of wild type p53 expression in glioblastoma cells. *Nat. Genet*. 8:171–176.
48. Pepper, M.S., S.J. Mandriota, J.-D. Vassalli, L. Orci, and R. Montesano. 1996. Angiogenesis-regulating cytokines: activities and interactions. *In Current Topics in Microbiology and Immunology*. U. Günthert and W. Birchmeier, editors. Springer-Verlag, Berlin. 31–67.
49. Van Meir, E.G., 1995. Cytokines and tumors of the central nervous system. *Glia*. 15:264–288.
50. Karakurum, M., R. Shreenivas, J. Chen, D. Pinsky, S.D. Yan, M. Anderson, K. Sunouchi, J. Major, T. Hamilton, K. Kuwabara et al. 1994. Hypoxic induction of interleukin-8 gene expression in human endothelial cells. *J. Clin. Invest*. 93:1564–1570.
51. Metinko, A.P., S.L. Kunkel, T.J. Standiford, and R.M. Strieter. 1992. Anoxia-hyperoxia induces monocyte-derived interleukin-8. *J. Clin. Invest*. 90:791–798.
52. Peiper, S.C., Z.X. Wang, K. Neote, A.W. Martin, H.J. Showell, M.J. Conklyn, K. Ogborne, T.J. Hadley, Z.H. Lu, J. Hesselgesser, and R. Horuk. 1995. The Duffy antigen/receptor for chemokines (DARC) is expressed in endothelial cells of Duffy negative individuals who lack the erythrocyte receptor. *J. Exp. Med*. 181:1311–1317.
53. Wakabayashi, Y., T. Shono, M. Isono, S. Hori, K. Matsu-shima, M. Ono, and M. Kuwano. 1995. Dual pathways of tubular morphogenesis of vascular endothelial cells by human glioma cells: vascular endothelial growth factor/basic fibroblast growth factor and interleukin-8. *Jpn. J. Cancer Res*. 86:1189–1197.
54. Hadley, T.J., Z.H. Lu, K. Wasniowska, A.W. Martin, S.C. Peiper, J. Hesselgesser, and R. Horuk. 1994. Postcapillary venule endothelial cells in kidney express a multispecific chemokine receptor that is structurally and functionally identical to the erythroid isoform, which is the Duffy blood group antigen. *J. Clin. Invest*. 94:985–991.
55. Tournamille, C., Y. Colin, J.P. Cartron, and C. Le Van Kim. 1995. Disruption of a GATA motif in the Duffy gene promoter abolishes erythroid gene expression in Duffy-negative individuals. *Nat. Genet*. 10:224–228.
56. Rot, A., E. Hub, J. Middleton, F. Pons, C. Rabeck, K. Thierer, J. Wintle, B. Wolff, M. Zsak, and P. Dukor. 1996. Some aspects of IL-8 pathophysiology. III: Chemokine interaction with endothelial cells. *J. Leukocyte Biol*. 59:39–44.
57. Schonbeck, U., E. Brandt, F. Petersen, H.-D. Flad, and H. Loppnow. 1995. IL-8 specifically binds to endothelial but not to smooth muscle cells. *J. Immunol*. 154:2375–2383.
58. Strieter, R.M., P.J. Polverini, S.L. Kunkel, D.A. Arenberg, M.D. Burdick, J. Kasper, J. Dzuiba, J. Van Damme, A. Walz, D. Marriott et al. 1995. The functional role of the ELR motif in CXC chemokine-mediated angiogenesis. *J. Biol. Chem*. 270:27348–27357.
59. Brogi, E., T. Wu, A. Namiki, and J.M. Isner. 1994. Indirect angiogenic cytokines upregulate VEGF and bFGF gene expression in vascular smooth muscle cells, whereas hypoxia upregulates VEGF expression only. *Circulation*. 90:649–652.
60. Ryuto, M., M. Ono, H. Izumi, S. Yoshida, H.A. Weich, K. Kohno, and M. Kuwano. 1996. Induction of vascular endothelial growth factor by tumor necrosis factor  $\alpha$  in human glioma cells. Possible roles of SP-1. *J. Biol. Chem*. 271:28220–28228.
61. Takeshima, H., J. Kuratsu, M. Takeya, T. Yoshimura, and Y. Ushio. 1994. Expression and localization of messenger RNA and protein for monocyte chemoattractant protein-1 in human malignant glioma. *J. Neurosurg*. 80:1056–1062.
62. Moynagh, P.N., D.C. Williams, and L.A. O'Neill. 1994. Activation of NF- $\kappa$  B and induction of vascular cell adhesion molecule-1 and intracellular adhesion molecule-1 expression

- in human glial cells by IL-1. Modulation by antioxidants. *J. Immunol.* 153:2681–2690.
63. Liles, W.C., P.A. Kiener, J.A. Ledbetter, A. Aruffo, and S.J. Klebanoff. 1996. Differential expression of Fas (CD95) and Fas ligand on normal human phagocytes: implications for the regulation of apoptosis in neutrophils. *J. Exp. Med.* 184:429–440.
  64. Saas, P., P.R. Walker, M. Hahne, A.-L. Quiquerez, V. Schnuriger, G. Perrin, L. French, E.G. Van Meir, N. de Tribolet, J. Tschopp, and P.-Y. Dietrich. 1997. Fas ligand expression by astrocytoma in vivo: maintaining immune privilege in the brain? *J. Clin. Invest.* 99:1173–1178.
  65. Gratas, C., Y. Tohma, E.G. Van Meir, M. Klein, M. Tenan, N. Ishii, O. Tachibana, P. Kleihues, and H. Ohgaki. 1997. Fas ligand expression in glioblastoma cell lines and primary astrocytic brain tumors. *Brain Pathol.* 7:863–869.
  66. Sabroe, I., T.J. Williams, C.A. Hebert, and P.D. Collins. 1997. Chemoattractant cross-desensitization of the human neutrophil IL-8 receptor involves receptor internalization and differential receptor subtype regulation. *J. Immunol.* 158: 1361–1369.
  67. Simonet, W.S., T.M. Hughes, H.Q. Nguyen, L.D. Trebasky, D.M. Danilenko, and E.S. Medlock. 1994. Long-term impaired neutrophil migration in mice overexpressing human interleukin-8. *J. Clin. Invest.* 94:1310–1319.
  68. Kanayama, N., Y. Kajiwara, J. Goto, E. el Maradny, K. Mae-hara, K. Andou, and T. Terao. 1995. Inactivation of interleukin-8 by aminopeptidase N (CD13). *J. Leukocyte Biol.* 57: 129–134.