Original Article

Comparative analysis of use of porous orbital implant with mucus membrane graft and dermis fat graft as a primary procedure in reconstruction of severely contracted socket

Kasturi Bhattacharjee, Harsha Bhattacharjee[1], Ganesh Kuri, Jayanta Kr Das, Debleena Dey

Purpose: The purpose of our study is to present a surgical technique of primary porous orbital ball implantation with overlying mucus membrane graft (MMG) for reconstruction of severely contracted socket and to evaluate prosthesis retention and motility in comparison to dermis fat graft (DFG). **Study Design:** Prospective comparative study. **Materials and Methods:** A total of 24 patients of severe socket contracture (Grade 2-4 Krishna's classification) were subdivided into two groups, 12 patients in each group. In Group I, DFG have been used for reconstruction. In Group II, porous polyethylene implant with MMG has been used as a primary procedure for socket reconstruction. In Group I DFG was carried out in usual procedure. In case of Group II, vascularized scar tissues were separated 360° and were fashioned into four strips. A scleral capped porous polyethylene implant was placed in the intraconal space and four strips of scar tissue were secured to the scleral cap and extended part overlapped the implant to make a twofold barrier between the implant and MMG. Patients were followed-up as per prefixed proforma. Prosthesis motility and retention between the two groups were measured. **Results:** In Group I, four patients had recurrence of contracture with fall out of prosthesis. In Group II stable reconstruction was achieved in all the patients. In terms of prosthesis motility, maximum in Group I was 39.2% and Group II, was 59.3%. The difference in prosthesis retention (P = 0.001) and motility (P = 0.004) between the two groups was significant. **Conclusion:** Primary socket reconstruction with porous orbital implant and MMG for severe socket contracture is an effective method in terms of prosthesis motility and prosthesis retention.

Access this article online
Website: www.ijo.in
DOI: 10.4103/0301-4738.128593
Quick Response Code:

Key words: Contracted socket, dermis fat graft, porous orbital implant, reconstruction

Patients with contracted socket experience a number of functional anomalies in addition to significant psychological morbidity due to cosmetic aberrations.[1] These problems needed to be addressed by meticulous and effective reconstructive socket surgery thereby providing appropriate fitting of a cosmetically acceptable prosthetic eye along with adequate functions of eyelids.

Although the reconstruction of mild to moderate socket contracture was carried out successfully earlier, in severe socket contracture cases, very often it became difficult to regain acceptable cosmesis and was not possible to fit or retain the prosthesis as any aggressive measure would have had only made it worse.

Successful reconstruction of a contracted socket requires the implantation of an allograft or auto graft. The conventional auto grafts are: mucus membrane graft (MMG),[2,3] skin graft,[4] hard palate graft,[5,6] temporalis fascia,[7] muscle flap[8] and dermis fat graft (DFG).[9] Among them, DFG is most preferable as it can expand the contracted socket both in terms of volume and surface area. However, a major drawback of autogenous tissue lies in the process of harvesting the graft, which requires additional instruments, surgical skills and surgical intervention involving other sites of the patient.[10]

To overcome the drawbacks of autogenous tissues many surgeons in the recent years have used various allografts for socket reconstruction, like using special types of conformers.[11,12] Silicon fixative implants (with Kirschner wire fixed to periostium)[12] and using hydrogel expansible materials.[13]

Thus the search for a perfect implant for socket reconstruction whether allograft or auto graft, still continues to persist. Herein, the authors presented a novel technique of combined use of both the allograft and the auto graft in the management of severely contracted socket by primary implantation of porous polyethylene orbital implant along with MMG. The authors hypothesized that adding tissues in the form of mucous membrane would act as a conjunctival replacement, as most of the severely contracted socket has deficient conjunctiva.

The study evaluated the efficacy of single stage procedure of primary orbital implant (allograft) and MMG (auto graft) for reconstruction of severe socket contracture and compared its effectiveness with that of the DFG in the management of severely contracted socket.

Materials and Methods

This was a prospective comparative interventional case series involving 24 patients with severe socket contracture undergoing socket reconstruction, operated between March 2002 and 2006. Clearance of Medical Ethics Committee of

Departments of Orbit, Ophthalmic Plastic and Reconstructive Surgery, and [1]Department of Comprehensive Ophthalmology, Sri Sankaradeva Nethralaya, Beltola, Guwahati, Assam, India

Correspondence to: Dr. Kasturi Bhattacharjee, Department of Orbit, Ophthalmic Plastic and Reconstructive Surgery, Sri Sankaradeva Nethralaya, 96 Basistha Road, Beltola, Guwahati - 781 028, Assam, India. E-mail: kasturibhattacharjee44@hotmail.com

Manuscript received: 21.09.12; **Revision accepted:** 23.07.13

the Institution taken. All procedures complied with tenets of Declaration of Helsinki on human studies. Patients were subdivided into two groups. In Group I, DFG had been used for socket reconstruction in 12 patients. In Group II porous polyethylene orbital implant with MMG had been used as the primary procedure of socket reconstruction in 12 patients. All participants were randomly allocated to either of the treatment arm through computer generated random number sequence and minimized it to 12 in each.

Grading of the socket contracture was done based on Krishna's grading in 1980.[14] The inclusion criteria incorporated patients >8 years of age with acquired anophthalmic contracted socket of Grades 2-4. The exclusion criteria incorporated Grade 5 contracted socket, post-irradiated contracted socket, severely mutilated and traumatized socket, congenital anophthalmic socket, infected socket and patients <8 years of age.

Patients' demographics, detailed evaluation of the socket, superior sulcus deformity, palpebral aperture, associated lid anomalies, cicatrisation of conjunctiva and lid, presence of scarred tissue in socket and signs of infections were noted. The fornicial depth was measured with a transparent ruler while doing which, the patient was asked to look down while measuring the superior fornix and to look up while measuring the inferior fornix.[10]

The infective status of each socket was ascertained by the procedure as reported by Bajaj *et al*.[10] Conjunctival swab from the inferior fornix was sent for bacteriological culture and sensitivity, a week prior to surgery and the socket was treated with antibiotic eye drops. The patients were scheduled for surgery only when the socket was found free of any infection as per the bacteriological culture report. In patients of Group II, the oral hygiene was ascertained and they were advised antiseptic mouth wash 3 times daily, a week prior to the date of the surgery.

All cases have been done under general anesthesia. An initial canthotomy and lateral cantholysis were done to increase the horizontal palpebral aperture as severely contracted socket are often associated with reduced length of horizontal palpebral fissure and sometimes with horizontal palpebral phimosis. This was followed by a horizontal incision made at the center of the socket extending from the medial to the lateral canthus. The conjunctiva was then separated from the underlying subcutaneous tissues. Conjunctiva and subcutaneous tissues were dissected up to the fornix, both superiorly and inferiorly. The fibrous tissues were dissected posteriorly up to the intraconal fat layer. Four strips of vascularized socket tissues were fashioned with the subcutaneous tissues along with the fibrosed tenons, posterior orbital tissues and remnants of rectus muscle and stitched either to the DFG or to the orbital implant, with cardinal sutures at 12-, 3-, 6- and 9-o'clock positions, in order to impart prosthesis motility post-operatively.

In Group I, DFG was harvested from the outer third of the thigh. Precaution was taken while removing the epidermis without damaging the dermis. The harvested graft was precisely fitted into the socket. The vascularized scar tissue stripes were stitched to the four cardinal positions of the dermal edge of the composite graft, followed by suturing the tenons and the surrounding conjunctiva to the graft, which left the central part of the dermis, exposed allowing a reepithelization later by secondary intention. Finally, the fornix forming sutures were given and the conformer placed [Fig. 1].

In Group II, the vascularized scar tissue flaps were fashioned such that they could be aligned to and overlapped over the implant. The appropriate implant size was measured with sizer and the size reduced by 2 mm due to scarring of fibrous tissue [Fig. 2a]. An alcohol preserved scleral cap was fashioned and sutured with 5-0 prolene to the implant and placed in the intraconal space within the four strips of vascularized scarred tissues. Horizontal mattress sutures were given to secure the tissue bands of the four strips to the scleral cap of the orbital implant in the four cardinal positions and the extended portion of the strips were made to overlap and double breast over the implant without any tension. The diameter of the extended areas of vascularized scarred tissue strips, covering the implant, was measured both vertically and horizontally and MMG was harvested from the lower lip of an area 25% larger than that of the measured recipient area with due care taken not to damage the frenulum. The harvested mucus membrane from the lower lip was soaked in an antibiotic solution prior to its application and was placed over the vascularized scarred tissue which covered

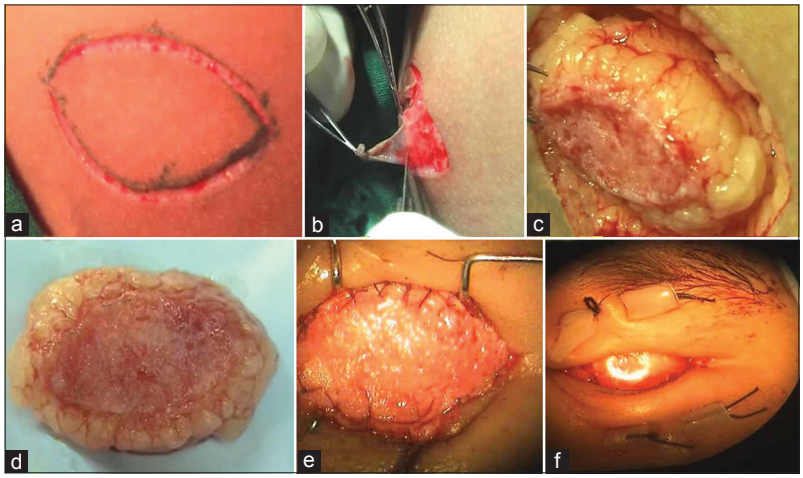

Figure 1: Socket reconstruction with dermis fat graft (DFG). (a) Harvesting of DFG, (b) epidermis removal, (c) DFG in vivo, (d) DFG in vitro, (e) DFG sutured in the socket, (f) reconstructed socket after placement of fornix forming suture and conformer

the anterior surface of the implant. It was then sutured to the superior and inferior forniceal conjunctiva, the lateral and the medial sub conjunctival tissues with interrupted 6-0 polyglactin sutures. This created a twofold barrier consisting the scleral patch graft and the superimposed soft tissues of the vascularized scarred stripes of the socket, between the anterior implant surface and the MMG. Fornix forming sutures, two each in the superior and inferior fornices, were stitched and befitting conformer was placed [Fig. 2b-d]. Temporary tarsorrhaphy was done and the patch applied. The mucosa of the lower lip was preferably used as the donor site since it could provide adequate tissues. All patients were instructed to maintain appropriate oral hygiene 3 days prior to the date of surgery. After obtaining the adequate graft, bleeding of the donor area was controlled with cautery and absorbable hemostats was applied, which was then bandaged for 48 h. From 3rd post-operative day onwards daily dressing of the donor site was done with broad spectrum antibiotic ointment and was made to reepithelize by secondary intention.

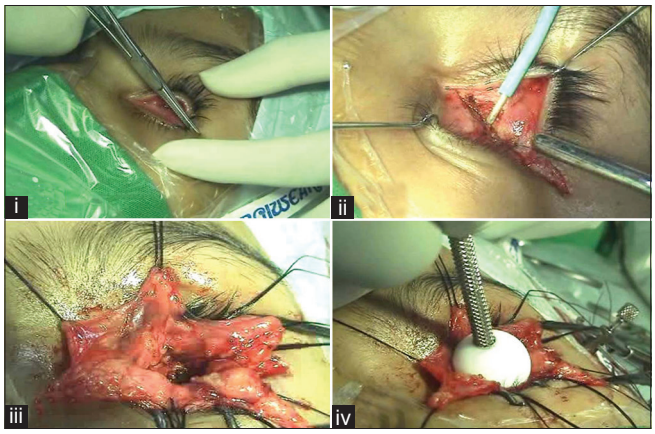

Figure 2a: Socket reconstruction with porous orbital implant and mucus membrane graft (MMG), (i) lateral canthotomy and cantholysis, (ii) horizontal incision, from medial to lateral canthus of socket, (iii) fashioning of four strips of vascularised socket tissue, (iv) measurement of implant size with sizer

Post-operatively injectable antibiotic was given on the day of surgery followed by oral antibiotic and anti-inflammatory drugs for 1 week. Irrigation of the reconstructed socket was done daily with 5% povidone iodine and temporary tarsorrhaphy released after a week.

Patients were followed-up on day 1, daily for a week, 2 weeks, 1 month, 3 months, 6 months and annually thereafter. The fornix forming sutures were released after 1 month and a custom designed artificial eye was placed 6 weeks post-operatively. During the follow-up period the graft status was assessed in both the groups in relation to its acceptance and complications - such as graft contracture, necrosis, atrophy and ulceration and graft failure. Moreover, the status of the orbital implant in Group II in relation to implant migration, exposure and extrusion was assessed. Comparison between the two groups was done in relation to prosthesis motility and retention and formation of the reconstructed fornices.

Implant motility was measured by a software graphic tool named Perfect Screen Ruler that allows accurate on screen measurement.[15] The program displays measures of the vertical (X) and horizontal (Y) distances between two points in pixel and then converts the graphic distance to millimeters [Figs. 3 and 4]. Herein the reference lines [green line and yellow line in Figs. 5 and 6] passing horizontally and vertically through the center of the pupil in the normal eye and the midpoint of the artificial pupil in the prosthetic eye were measured with the patient in straight gaze and four

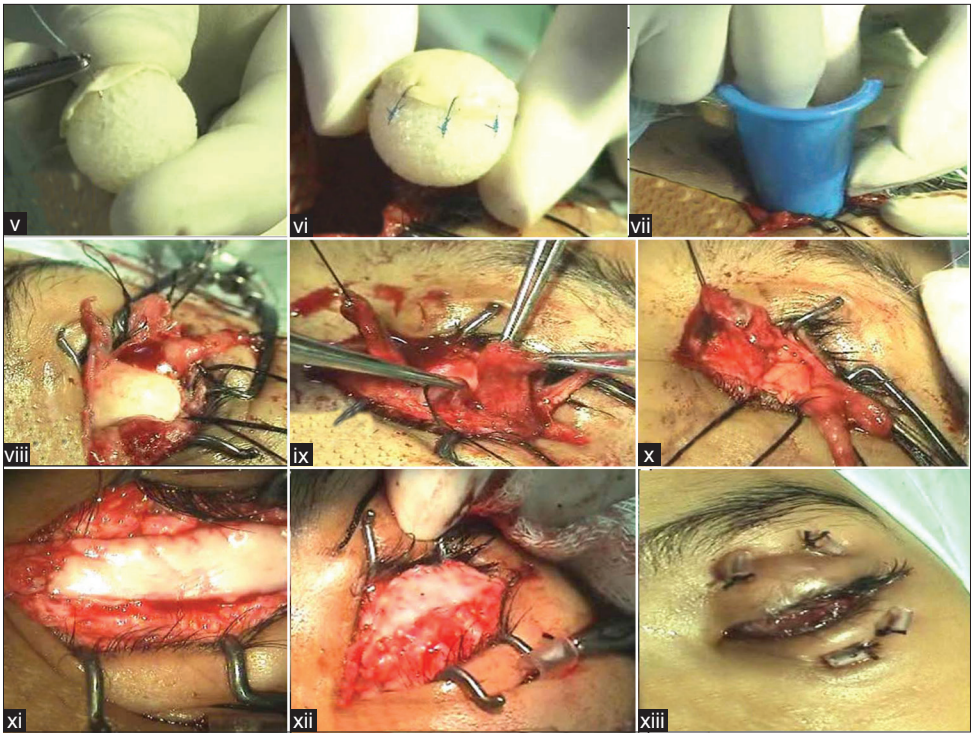

Figure 2b: (v and vi) Scleral cap on implant, (vii) intraconal implant placement, (viii) implant within vascularised tissue strips, (ix) suturing four tissue strips to scleral cap, (x) extended tissue strips on implant, (xi) MMG on implant, (xii) fornix forming suture, (xiii) conformer *in situ*

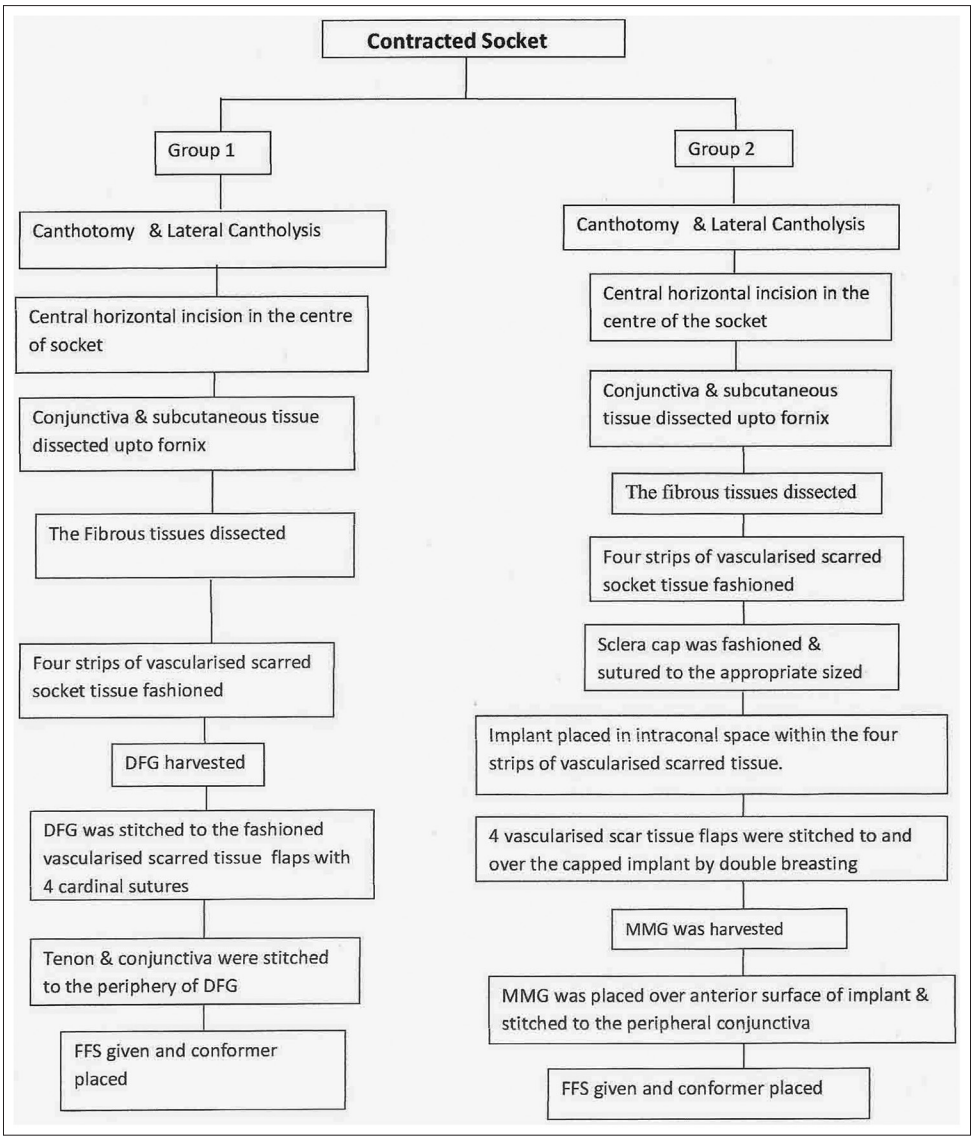

Figure 2c: Line diagram showing the surgical steps of socket reconstruction with dermis fat graft (Group I) and with porous orbital implant and MMG (Group II)

cardinal gazes, i.e., superior, inferior, medial and lateral gaze. The distance between the two lines gave the measurement of maximum prosthesis motility. The percentage of distance was measured as the ratio of the distance moved by the prosthetic eye (P) to that of the normal eye (N) [Figs. 6 and 7]. The results were statistically analyzed by Students *t*-test.

Results

A total of the 24 patients operated for severe socket contracture; there were 14 males and 10 females. The age ranged from 8 to 55 years (average 25 years ± 2.2 standard deviation [SD]). In two patients had a history of evisceration and 22 patients had histories of enucleation done in their early childhood [Tables 1 and 2]. None of the 24 patients had any prosthesis in the socket at the time of presentation. In 10 patients, there was no history of placement of a conformer or an artificial eye in the socket following the surgery till the time of presentation. However, in the rest 14 patients the interval between the patient's inability to retain an artificial eye and presentation varied from 15 to 24 months. The follow-up ranged from 1 to 5 years with an average of 3.2 years ± 1.8 SD. Age gender and cause and duration of the contracted socket were put in a multivariate model and were not found to be significantly associated with the outcome.

In both groups, the pre-operative forniceal depth of lower lid ranged from 0 to 1.2 mm (mean 0.5 mm) and that of the upper lid ranged from 0 to 1.5 mm (mean 0.62 mm). However, the forniceal depth at 1 year post-operative follow-up period in both groups ranged from 3 to 8.2 mm (mean 6.5 mm) in lower lid ($P < 0.5$) and from 3 to 7.5 mm (mean 6.2 mm) ($P < 0.5$) in the upper lid. Though there was gross superior sulcus deformity in all 24 sockets at time of presentation, this was corrected in eight patients of Group I and 11 patients of Group II. The mean pre-operative horizontal palpebral aperture was 18 mm (16-22 mm) and the mean post-operative horizontal diameter was 28 mm (26-30 mm).

Out of the 12 patients in Group I undergoing DFG, a good and stable reconstructed socket was found in eight sockets

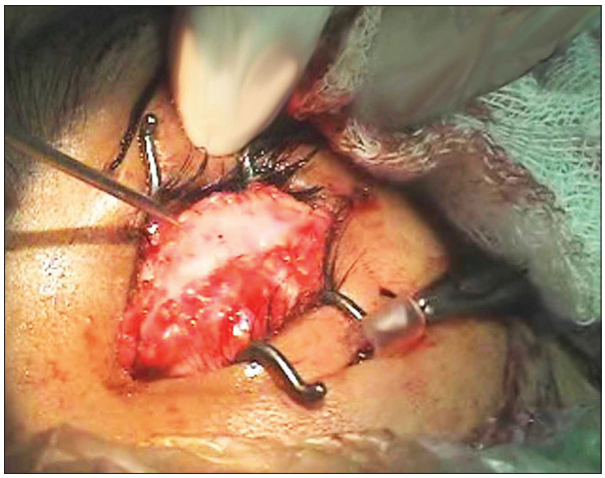

Figure 2d: Close up photo of the MMG in situ after suturing into socket (Group II)

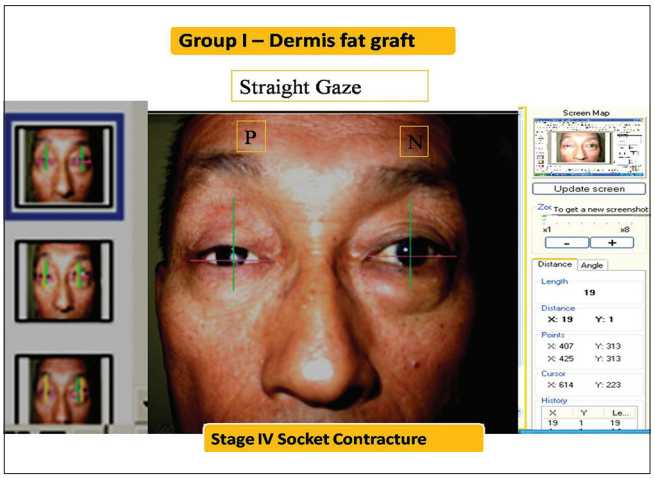

Figure 3: Case 2 of Group I showing the measurement of prosthesis motility in perfect screen ruler in straight gaze, where P is the prosthetic eye and N is the normal eye

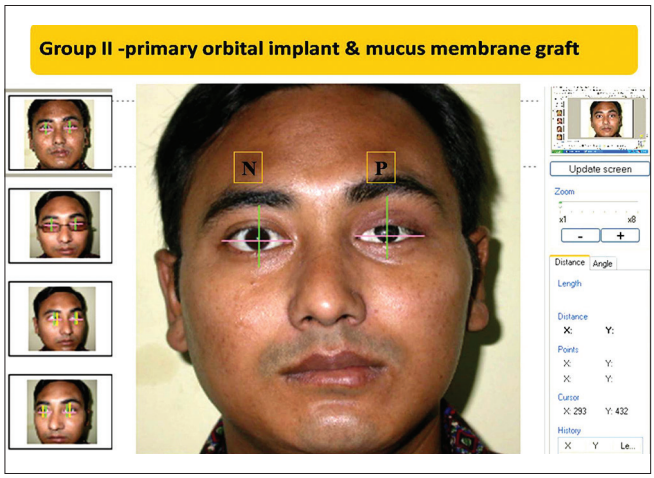

Figure 4: Case 4 of Group II showing the measurement of prosthesis motility in perfect screen ruler in straight gaze, where P is the prosthetic eye and N is the normal eye

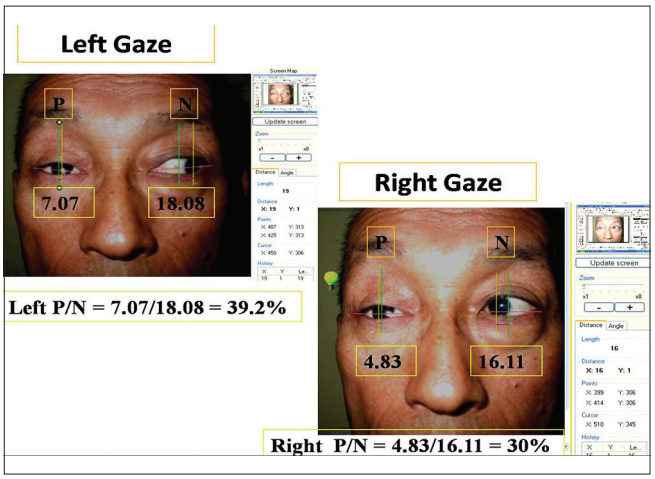

Figure 5: Case 2 of Group I showing the two reference lines, green and yellow for measurement of prosthesis motility. The percentage of implant motility is a ratio of P/N

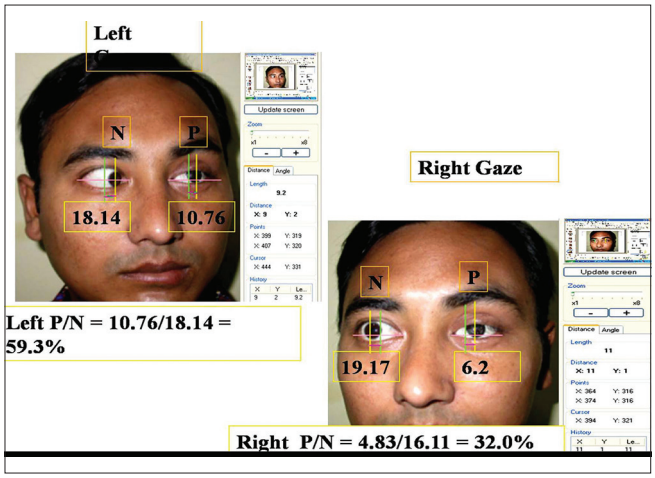

Figure 6: Case 4 of Group II showing the two reference lines, green and yellow for measurement of prosthesis motility. The percentage of implant motility is a ratio of P/N

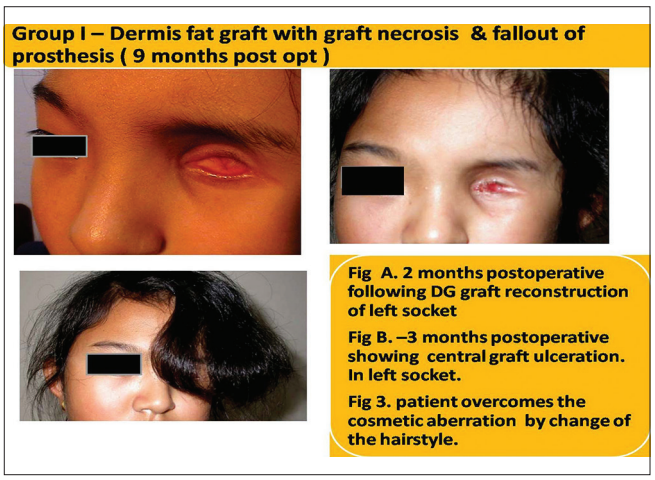

Figure 7: Case 5 of Group I showing graft necrosis and fall out of prosthesis, resulting in change of hairstyle due to cosmetic aberration

during the post-operative follow-up period. However, four patients showed recurrence of socket contracture with fall out of prosthesis. The main cause of recurrence was large graft ulceration in two patients [Fig. 7], graft necrosis in one patient and severe graft shrinkage and contracture in one patient. The graft ulceration and necrosis was managed very aggressively with debridement of the ulcer edges under cover of topical and oral systemic antibiotics. Though there was early initial response to the treatment, it progressed necessating repeat socket reconstruction with DFG in all the three patients of Group I. The patient with post-operative graft contracture had a sunken socket along with fat atrophy and further surgery in the form of temporalis muscle transfer to the socket had to be done in this patient after 9 months of the initial reconstruction [Fig. 8].

Table 1: The demographic profile, previous surgery done, interval between the initial surgery and time of presentation, grade of contracted socket in group I

Patient no.	Age	Sex	Eye	Previous surgery	Time elapsed from surgery (Years)	Contracted socket (Grades)
1	37	M	RE	Enucleation	12	3
2	53	M	RE	Enucleation	20	4
3	42	F	LE	Enucleation	15	4
4	44	M	RE	Evisceration	10	3
5	14	F	LE	Enucleation	5	3
6	27	F	RE	Enucleation	13	3
7	35	M	RE	Enucleation	22	4
8	55	M	LE	Enucleation	29	3
9	21	F	LE	Enucleation	13	2
10	27	M	RE	Enucleation	14	3
11	39	M	LE	Enucleation	24	4
12	49	M	RE	Enucleation	30	4

LE: Left eye, RE: Right eye

Table 2: The demographic profile, previous surgery done, interval between the initial surgery and time of presentation, grade of contracted socket in group II

Patient no.	Age	Sex	Eye	Previous surgery	Time elapsed from surgery (Years)	Contracted socket (Grades)
1	32	F	RE	Enucleation	19	4
2	36	M	RE	Enucleation	19	4
3	31	F	RE	Enucleation	23	3
4	29	M	LE	Enucleation	13	4
5	43	F	LE	Enucleation	28	3
6	24	M	RE	Enucleation	7	2
7	10	F	LE	Enucleation	3	3
8	33	M	LE	Evisceration	5	2
9	40	M	RE	Enucleation	21	4
10	38	F	LE	Enucleation	20	3
11	26	F	LE	Enucleation	14	3
12	44	M	RE	Enucleation	28	4

LE: Left eye, RE: Right eye

In Group II, stable reconstruction was achieved in all the patients following the surgical procedure with adequate retention of prosthesis in the post-operative follow-up period. Conjunctival granuloma formation was noted in one case leading to slight misalignment of prosthesis noted 4 months following surgery. However, it could be successfully managed with surgical excision. Mild posterior lamellar contracture with eyelashes directed towards the ocular prosthesis was found in one patient involving the upper lid and two patients involving the lower lid. The prosthesis was well fitted with good retention. None of the patients had implant exposure or extrusion. Acceptable implant motility could be achieved in all the patients [Figs. 9-11].

The prosthesis motility in Group I ranged from 30% to a maximum of 39.2%. However, the prosthesis motility in Group II ranged from 32% to a maximum of 59.3% [Fig. 12]. The difference in prosthesis retention ($P = 0.001$) and motility ($P = 0.004$) between the two groups was statistically significant.

Discussion

The main objective of a successful socket reconstruction is establishing stable retention of a cosmetically acceptable prosthesis along with adequate prosthesis motility. Though this could be achieved in mild to moderate socket contracture, it does pose multiple problems in severely contracted sockets.

In earlier published literature many surgeons have offered various classifications of contracted sockets and possible reconstructive surgeries.[2,16,17] However, Krishna classification of contracted socket appears to be the most suitable for clinical studies.[14] Herein, Grade 1, shallow or shelved lower fornix; Grade 2, loss of both upper and lower fornices, preventing retention of artificial eye; Grade 3, included loss of all four fornices; Grade 4, loss of all fornices along with reduction of palpebral aperture and Grade 5 included severely contracted socket with recurrence of contracture following repeated trials of reconstruction.

The pathophysiology of the contracted socket in post-surgical anophthalmic patients has been a subject of debate.[18,19] Changes in the orbital blood flow along with changes of metabolic activities and disturbance of spatial architecture are the causes of socket contracture. Kaltreider *et al*. in their study have reported that only the superficial soft-tissues are avascular while the vascularity of posterior and orbital apical tissues is not affected.[19]

Though there are many hypothesis regarding socket vascularity, Kronish *et al*. used ophthalmic artery angiography and reported similar caliber of major orbital blood vessels in normal and anophthalmic orbits.[20,21] Moreover, with use of radioactive microsphere in animal studies, he had reported comparable capillary flow between normal and anophthalmic socket per weight of orbital tissue.[20,21]

Thus the authors of the present study have utilized the vascularized posterior scar tissues and fashioned them into four stripes to hold the porous orbital implant and to give anterior

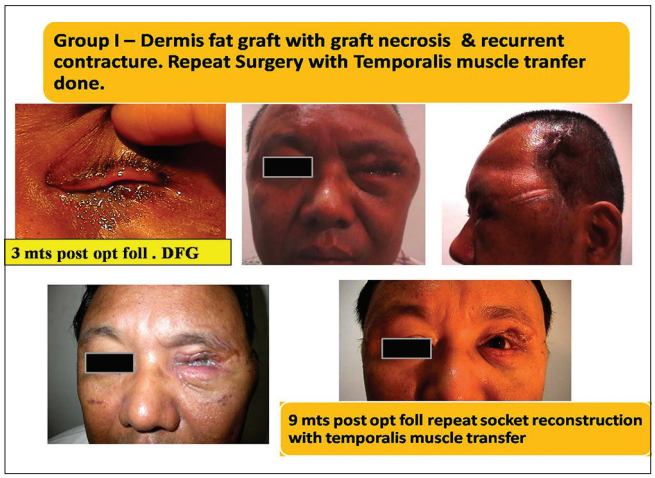

Figure 8: Case 8 of Group I showing graft necrosis and recurrent contracture and further surgery in the form of temporalis muscle transfer to the socket

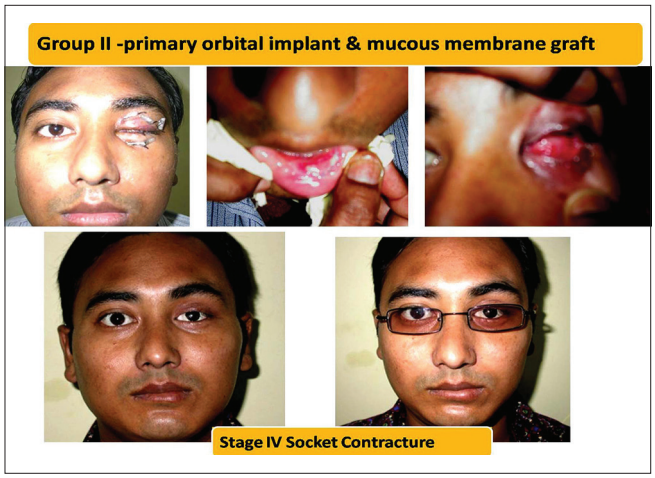

Figure 9: Case 4 of Group II showing reconstructed socket, donor site of mucus membrane graft, post-operative socket status and acceptable cosmesis after placement of prosthesis

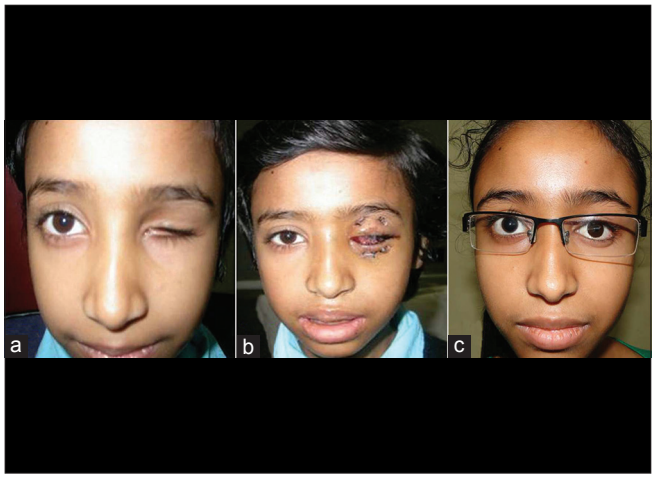

Figure 10: Case 7 of Group II showing (a) pre-operative, (b) day 1 post-operative and (c) 4 years post-operative pictures with good retention of implant and prosthesis

surface coverage to the implant. The deficient conjunctiva was then replaced by MMG. Labial mucosa provided effective and adequate mucus membrane covering to the recipient site. The donor area was made to heal by secondary intension with granulation tissue formation. The presence of viable tissue (like the granulation tissue) into an open wound allowed effective epithelialization with migration of surrounding epithelial cells across the new tissue site. Epithelial cell migration is best enhanced by a moist environment. Hence daily dressing of the donor area with antibiotic ointment provided a moist environment and rapid wound epithelization and healing.

Use of orbital implant for socket reconstruction can be traced to 1884 when Mules was the first to implant a hollow glass sphere, which he named artificial vitreous.[22] Mazzoli *et al*. in 2004 reported the use of hydrogel expansile materials for expanding the contracted sockets in the congenitally anophthalmic orbit.[23] The implants are placed in the sockets in their dry state and then they gradually expand, producing up to a 10-fold increase in volume.

Recent trend is to implant a ball made of porous high density polyethylene. Rapid fibro vascular ingrowth within the implant not only anchors the implant biologically to the orbital tissues but also minimizes implant migration and extrusion.[24] Moreover, once the implant gets vascularized the chances of infection and extrusion decreases because of the straightforward admittance of the host immune defenses to the implant.[25] The fibro vascular ingrowths also prevent capsule formation and help in stabilizing the implant.

Amongst the autogenous tissues, DFG is most commonly used for socket reconstruction due to its immense advantage of providing a larger volume and surface area. However, DFG has many post-operative complications such as central graft necrosis, central pitting, graft failure, central graft ulceration, graft shrinkage with orbital volume loss and socket infection.[9] One of the major problems associated with DFG is the limited prosthesis motility along with progressive post-operative volume deficit.

In this present series, the authors reported 24 cases of reconstructed socket wherein DFG was given to 12 patients and primary orbital ball implant with autogenous MMG was done in 12 patients. From the results, it was seen that in Group I, 4 out of 12 cases had recurrence of contracted socket with fallout of prosthesis. Central graft ulceration was observed in two patients and graft necrosis was observed in one. This must have occurred due to inadequate graft re-epithelization and failure of the conjunctiva to resurface the bare surface of DFG in a timely manner. This is in concordance to the study reported by Shore *et al*.[26] Repeat reconstruction surgery with repeat DFG had to be done in three patients and temproalis muscle transfer in one patient in Group I of the present study.

No such graft related complication was reported in Group II. One patient had conjunctiva granuloma formation with slight misalignment which was then managed surgically. All patients in Group II, had well fitted prothesis with good retention and acceptable prosthesis motility. There was no implant exposure or extrusion in Group II. This could be attributed to the meticulous surgical procedure having a twofold barrier of scleral patch graft and the overlying strips

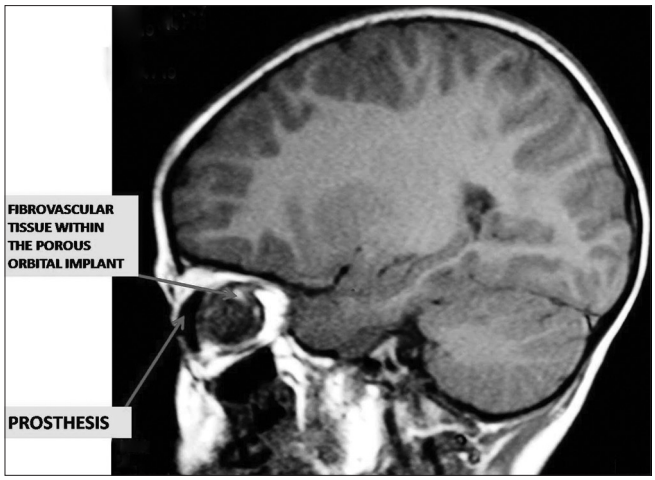

Figure 11: Magnetic resonance imaging picture of a patient of Group II showing fibrovascular tissue proliferation within the porous orbital implant

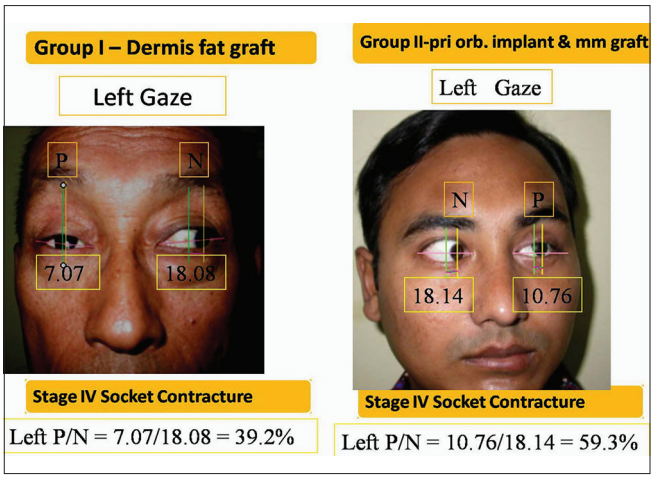

Figure 12: Comparison of prosthesis motility between Group I and Group II in left gaze showing better motility in Group II

of posterior vascularized scar tissues of the socket, between the anterior implant surface and MMG. This modified wrapping technique had provided a scaffold for epithelialization that resisted contractile forces during healing of wound. Deep socket placement of the orbital implant with introducer having a gliding surface had prevented the "Cactus syndrome." Quaranta-Leoni reported the so called "Cactus syndrome" as a cause of implant exposure occurring due to incorrect surgical technique wherein there is a forced ball superficial placement of the implant thus dragging the fat deep to the socket causing fat atrophy and late tissue decompensation.[27]

The authors hypothesized that the placement of deep socket orbital implant along with fibro vascular tissue ingrowth within the implant and with two-fold implant barrier prevented its extrusion. The attachment of the four posterior vascularized strips of socket tissue had enhanced the post-operative implant and its overlying prosthesis motility.

Thus use of porous orbital implant with MMG as a primary reconstructive procedure in severely contracted sockets represent an effective approach to successfully reconstructing ocular cul-de-sac and stabilizing retention of orbital implant with good prosthesis motility.

References

1. Hornblass A, Biesman BS, Eviatar JA. Current techniques of enucleation: A survey of 5,439 intraorbital implants and a review of the literature. Ophthal Plast Reconstr Surg 1995;11:77-86.
2. Molgat YM, Hurwitz JJ, Webb MC. Buccal mucous membrane-fat graft in the management of the contracted socket. Ophthal Plast Reconstr Surg 1993;9:267-72.
3. Bowen Jones EJ, Nunes E. The outcome of oral mucosal grafts to the orbit: A three-and-a-half-year study. Br J Plast Surg 2002;55:100-4.
4. Tsur H, Kaplan H, Shafir R, Rosner M, Orenstein A, Rosen N. Repair of the severely contracted socket with meshed skin graft and semi-rigid conformer. Ophthalmic Surg 1991;22:269-73.
5. Holck DE, Foster JA, Dutton JJ, Dillon HD. Hard palate mucosal grafts in the treatment of the contracted socket. Ophthal Plast Reconstr Surg 1999;15:202-9.
6. Lee AC, Fedorovich I, Heinz GW, Kikkawa DO. Socket reconstruction with combined mucous membrane and hard palate mucosal grafts. Ophthalmic Surg Lasers 2002;33:463-8.
7. Foster JA, Castro E, Papay FA. Reconstruction of the irradiated contracted socket with an expanded superficial temporalis fascial flap. Am J Ophthalmol 1999;127:621-2.
8. Li D, Jie Y, Liu H, Liu J, Zhu Z, Mao C. Reconstruction of anophthalmic orbits and contracted eye sockets with microvascular radial forearm free flaps. Ophthal Plast Reconstr Surg 2008;24:94-7.
9. Aguilar GL, Shannon GM, Flanagan JC. Experience with dermis-fat grafting: An analysis of early postoperative complications and methods of prevention. Ophthalmic Surg 1982;13:204-9.
10. Bajaj MS, Pushker N, Singh KK, Chandra M, Ghose S. Evaluation of amniotic membrane grafting in the reconstruction of contracted socket. Ophthal Plast Reconstr Surg 2006;22:116-20.
11. Karesh JW, Putterman AM. Reconstruction of the partially contracted ocular socket or fornix. Arch Ophthalmol 1988;106:552-6.
12. Mavrikakis I, Malhotra R, Shelley MJ, Sneddon KJ. Surgical management of the severely contracted socket following reconstruction. Orbit 2006;25:215-9.
13. Bacskulin A, Vogel M, Wiese KG, Gundlach K, Hingst V, Guthoff R. New osmotically active hydrogel expander for enlargement of the contracted anophthalmic socket. Graefes Arch Clin Exp Ophthalmol 2000;238:24-7.
14. Krishna G. Contracted sockets – I (aetiology and types). Indian J Ophthalmol 1980;28:117-20.
15. Styopkin AG. Perfect screen ruler software, C 2001-2010. Available from: http://www.styopkin.com/perfect screen ruler.html. (Last accessed 15 September 2012)
16. Guyuron B. The role of flaps in the management of contracted eye sockets. Adv Ophthalmic Plast Reconstr Surg 1992;9:143-57.
17. Bonavolontà G. Temporalis muscle transfer in the treatment of the severely contracted socket. Adv Ophthalmic Plast Reconstr Surg 1992;9:121-9.
18. Soll DB. The anophthalmic socket. Ophthalmology 1982;89:407-23.
19. Kaltreider SA, Wallow IH, Gonnering RS, Dortzbach RK. The anatomy and histology of the anophthalmic socket – Is the myofibroblast present? Ophthal Plast Reconstr Surg 1987;3:207-30.
20. Kronish JW, Gonnering RS, Dortzbach RK, Rankin JH, Reid DL, Phernetton TM. The pathophysiology of the anophthalmic socket. Part I. Analysis of orbital blood flow. Ophthal Plast Reconstr Surg 1990;6:77-87.
21. Kronish JW, Gonnering RS, Dortzbach RK, Rankin JH, Reid DL, Phernetton TM, *et al*. The pathophysiology of the anophthalmic

socket. Part II. Analysis of orbital fat. Ophthal Plast Reconstr Surg 1990;6:88-95.

22. Mules PH. Evisceration of the globe, with artificial vitrious. Trans Ophthalmol Soc U K 1885;5:200-6.
23. Mazzoli RA, Raymond WR 4th, Ainbinder DJ, Hansen EA. Use of self-expanding, hydrophilic osmotic expanders (hydrogel) in the reconstruction of congenital clinical anophthalmos. Curr Opin Ophthalmol 2004;15:426-31.
24. Rubin PA, Popham JK, Bilyk JR, Shore JW. Comparison of fibrovascular ingrowth into hydroxyapatite and porous polyethylene orbital implants. Ophthal Plast Reconstr Surg 1994;10:96-103.
25. Choi HY, Lee JE, Park HJ, Oum BS. Effect of synthetic bone glass particulate on the fibrovascularization of porous polyethylene orbital implants. Ophthal Plast Reconstr Surg 2006;22:121-5.
26. Shore JW, McCord CD Jr, Bergin DJ, Dittmar SJ, Maiorca JP, Burks WR. Management of complications following dermis-fat grafting for anophthalmic socket reconstruction. Ophthalmology 1985;92:1342-50.
27. Quaranta-Leoni FM. Treatment of the anophthalmic socket. Curr Opin Ophthalmol 2008;19:422-7.

Cite this article as: Bhattacharjee K, Bhattacharjee H, Kuri G, Das JK, Dey D. Comparative analysis of use of porous orbital implant with mucus membrane graft and dermis fat graft as a primary procedure in reconstruction of severely contracted socket. Indian J Ophthalmol 2014;62:145-53.

Source of Support: Nil. **Conflict of Interest:** None declared.