

Rhabdomyolysis After Coadministration of Atorvastatin and Sacubitril/Valsartan (EntrestoTM) in a 63-Year-Old Woman

Eve S. Faber¹ · Madhavi Gavini¹ · Ronald Ramirez¹ · Richard Sadovsky¹

Published online: 2 November 2016

© The Author(s) 2016. This article is published with open access at Springerlink.com

Abstract A 63-year-old woman previously stable on a regimen of atorvastatin 40 mg daily, carvedilol 25 mg twice daily, digoxin 0.125 mg daily, furosemide 40 mg daily, spironolactone 25 mg daily, rivaroxaban 15 mg daily, and enalapril 20 mg twice daily for heart failure developed rhabdomyolysis 26 days after enalapril was stopped and sacubitril/valsartan (EntrestoTM) started. The patient received sacubitril/valsartan at 24/26 mg twice daily for heart failure; however, after 26 days she developed muscle and skin pain. Investigations revealed elevated creatine kinase and liver function tests, and rhabdomyolysis with raised transaminases was diagnosed. Sacubitril/valsartan and atorvastatin were discontinued and the patient was hydrated. She returned to baseline in 23 days and has not had any reoccurrence of rhabdomyolysis and elevated transaminases for 46 days. A Naranjo assessment score of 5 was obtained, indicating a probable relationship between the patient's rhabdomyolysis and her use of sacubitril/valsartan. The Drug Interaction Probability Scale score was 3, consistent with a possible interaction as a cause for the reaction, with sacubitril/valsartan as the precipitant drug and atorvastatin as the object drug.

Key Points

Sacubitril/valsartan is a combination of a neprilysin inhibitor and an angiotensin II receptor blocker, indicated to decrease the risk of cardiovascular death and hospitalization for heart failure in patients with chronic heart failure.

A patient previously stable on atorvastatin developed severe rhabdomyolysis and an elevation of transaminases within 26 days of initiation of sacubitril/valsartan.

Introduction

Rhabdomyolysis is a syndrome characterized by skeletal muscle cell damage, leading to elevated creatine kinase (CK), lactate dehydrogenase (LDH), and aspartate aminotransferase (AST), which can result in severe sequelae, including renal failure, cardiac arrhythmia, hyperthermia and death [1]. Associated elevations in transaminases may be seen, even in the absence of significant liver injury [2]. Clinically, rhabdomyolysis classically presents with muscle pain, weakness and dark, red or tea-colored urine; however, less than 10% of patients will demonstrate all three components of this triad [3]. Rhabdomyolysis may be triggered by hereditary and/or acquired mechanisms, with approximately 75% of initial episodes being a result of acquired causes [3]. In particular, a large number of prescription drugs and drugs of abuse can cause rhabdomyolysis, with statins being one of the top three prescription drugs most commonly responsible for rhabdomyolysis for

✉ Eve S. Faber
Eve.faber@downstate.edu

¹ Department of Family Medicine, SUNY-Downstate Medical Center, 450 Clarkson Avenue, Suite B, Brooklyn, NY 11203, USA

this syndrome [4]. Myopathy and myositis have been reported in conjunction with all of the currently available statins and are considered to be a class effect of these medications. In addition, it has been recognized that statin-associated muscle complaints are dose-related and drug–drug interactions that cause an elevation of statin levels have been identified. Subgroups of patients at greater risk of statin-associated muscle pathology have been identified and include age >70 years, impaired renal function, and impaired hepatic function [5].

Entresto™ is a combination of sacubitril, a neprilysin inhibitor, and valsartan, an angiotensin II receptor blocker (ARB), indicated to decrease the risk of cardiovascular death and hospitalization for heart failure in patients with chronic heart failure (New York Heart Association [NYHA] class II–IV) and reduced ejection fraction. Sacubitril/valsartan is usually administered in conjunction with other heart failure drug regimens instead of an angiotensin-converting enzyme inhibitor (ACEi) or another ARB. The commonly occurring ($\geq 5\%$) adverse reactions reported are hypotension, hyperkalemia, cough, dizziness, and renal failure [6, 7]. Sacubitril/valsartan has not been associated with rhabdomyolysis and is commonly used in patients who are also receiving statin therapy.

Case Report

A 63-year-old Guyanese woman with hypertension, hyperlipidemia, congestive heart failure (CHF), atrial fibrillation, and peripheral vascular disease presented to her primary care provider’s office with a complaint of an episode of weakness at home associated with general malaise. She was receiving atorvastatin 40 mg daily, carvedilol 25 mg twice daily, digoxin 0.125 mg daily, furosemide 40 mg daily, spironolactone 25 mg daily, rivaroxaban 15 mg daily, and sacubitril/valsartan 24/26 mg twice daily. She was initiated on sacubitril/valsartan 22 days before her clinical presentation and had been on all of her other concurrent medications for more than 1 year. On the review of systems, the patient reported generalized weakness, pain in her knees, and an ill-defined stinging pain in the skin of her arms and legs. Her physical examination was non-focal, with no muscle weakness or tenderness of either the skin or muscles noted. Laboratory tests performed on presentation were significant for elevated AST/alanine aminotransferase (ALT) of 351 u/L/131 u/L. At the time she was believed to be having a reaction to her statin therapy prescribed for hyperlipidemia and therefore the atorvastatin was withheld. She was scheduled to return in 4 days for repeat laboratory testing and re-evaluation.

When the patient returned in 4 days, she complained of dark urine, generalized weakness, and increased muscle

and skin pain throughout her body. She was then found to have rhabdomyolysis, with CK at 58,349 u/L ($>50\times$ the upper limit of normal). She was admitted to hospital where she was hydrated and monitored. Her electrolytes were normal on admission and remained so throughout her stay. Sacubitril/valsartan was stopped at this time as it was the only new medication in her regimen. The CK level decreased steadily and her symptoms resolved over the course of a 5-day hospitalization (Fig. 1). Her renal function was preserved throughout and her bilirubin and transaminases briefly increased and also subsequently steadily decreased (Figs. 2, 3). During her hospital stay, the patient was tested for Epstein–Barr virus, hepatitis A, herpes simplex virus, HIV, and cytomegalovirus (CMV).

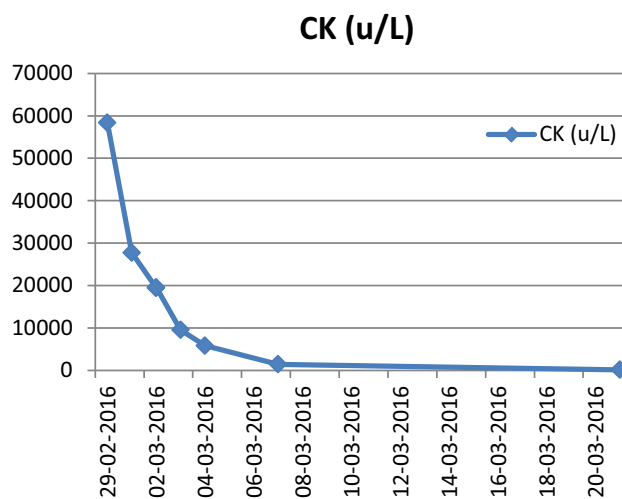


Fig. 1 Creatine kinase values during and post hospitalization. CK creatine kinase

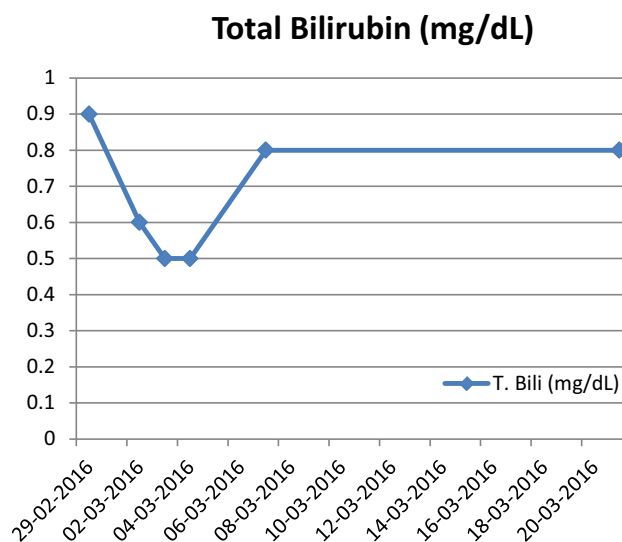


Fig. 2 Total bilirubin values during and post hospitalization. T. Bili total bilirubin

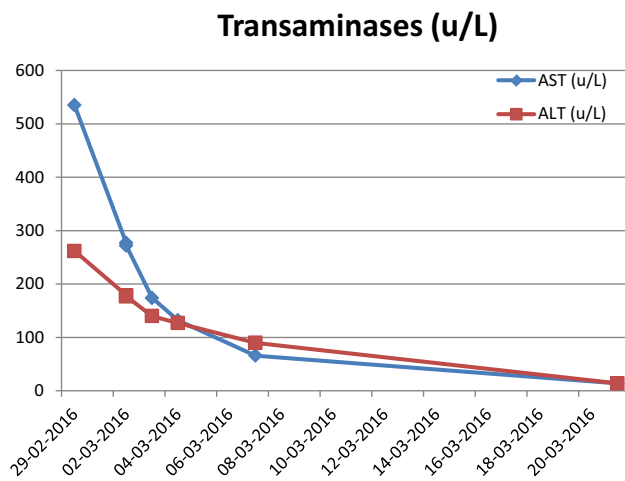


Fig. 3 Transaminase values during and post hospitalization. *AST* aspartate aminotransferase, *ALT* alanine aminotransferase

She was found to be immune to hepatitis A, Epstein–Barr virus, and herpes simplex virus, and had negative hepatitis A and B, HIV, HSV, and CMV tests.

By 23 days after her initial presentation, the patient no longer had any muscle or skin pain and her CK and liver function test (LFT) levels were completely normalized. The patient has not had any reoccurrence of rhabdomyolysis and elevated transaminases for 46 days, and her bilirubin and transaminase levels also returned to normal (Figs. 2, 3). One week later, the patient was started on an alternate statin at a low dose (rosuvastatin 5 mg) and the CK levels and LFTs have remained stable. There are no plans to restart sacubitril/valsartan.

Discussion

This patient had been on a variety of statins for more than 7 years, including atorvastatin, simvastatin, and rosuvastatin. Her baseline CK and LFTs were normal prior to the initiation of sacubitril/valsartan. She had previously experienced two transient elevations in CK, to a maximum of 1608 u/L, while hospitalized for an implantable defibrillator infection and explanation complicated by an acute CHF exacerbation and a recurrent CHF exacerbation in the 3 years prior to the current admission. Her CK levels returned to normal after her acute illnesses, without change in her LFTs. In this case, the immediate cause of her rhabdomyolysis was unknown, but the new medication in her profile seemed to be the likely trigger. Due to the severity of her rhabdomyolysis, the decision was made to not re-initiate sacubitril/valsartan. The Naranjo Adverse Drug Reaction Probability Scale score was 5, making it probable that the adverse drug reaction was precipitated by sacubitril/valsartan [8]. The Drug Interaction Probability

Scale score was 3, consistent with a possible interaction as a cause for the reaction, with sacubitril/valsartan as the precipitant drug and atorvastatin as the object drug [9].

Of note, one of the concurrent medications, carvedilol, is a P-glycoprotein inhibitor that may increase the serum concentration of atorvastatin, a P-glycoprotein substrate; however, the patient was stable on this combination for 7 years before sacubitril/valsartan was initiated. None of the other medications taken by this patient are known to cause rhabdomyolysis or an elevation in transaminases.

A literature search regarding a drug interaction between sacubitril and statins yielded no reports of rhabdomyolysis with statins. As per a recent study, coadministration of sacubitril/valsartan with atorvastatin led to a twofold increase in the maximum concentration (C_{max}) of atorvastatin and its metabolites [10]. In addition, the US and Canadian package inserts of sacubitril/valsartan cite in vitro data showing sacubitril inhibiting organic anion transporting polypeptides (OATP) 1B1 and 1B3, resulting in increased C_{max} and area under the curve (AUC) of atorvastatin with coadministration of sacubitril/valsartan [6, 7]. The Canadian version of the product insert further states that sacubitril/valsartan may increase the systemic exposure of OATP1B1 and OATP1B3 substrates, such as statins. Sacubitril/valsartan increases the C_{max} of atorvastatin and its metabolites by up to twofold, and AUC by up to 1.3-fold. The Canadian insert recommends that sacubitril/valsartan must be coadministered cautiously with statins, especially simvastatin, a sensitive OATP1B1/1B3 substrate, and a decrease in dose of simvastatin and atorvastatin may be considered when coadministered with sacubitril/valsartan [7]. The interaction between atorvastatin and sacubitril is mentioned in the US product package insert as a theoretical possibility. There is currently no recommendation to increase monitoring or empirically decrease the dose of any statin on initiation of sacubitril/valsartan.

A number of medications are known to inhibit OATPs and have been shown to increase statin plasma concentrations [11]. Many single nucleotide polymorphisms (SNPs) have been found within the *SLCO1B1* and/or *SLCO1B3* genes encoding OATP1B1 and OATP1B3 proteins, respectively, and were shown to effect the pharmacokinetics and/or pharmacodynamics of statins [12, 13]. The clinical consequences of the drug interactions may vary based on the genetic variation in OATP-encoding genes and inhibition of OATP function. The *SLCO1B1*1B* haplotype appears to be associated with enhanced hepatic uptake and reduced plasma concentrations of OATP1B1 substrates [14].

Discontinuation of the statin alone did not result in a decrease in the patient's LFTs. It was not until sacubitril/valsartan was also discontinued, and treatment for

rhabdomyolysis was initiated, that the patient's symptoms began to improve and her CK and LFTs returned to baseline. This could be due to either a direct effect of sacubitril/valsartan or the increased serum concentration of atorvastatin, as described in the literature. Because of the above-stated pharmacodynamics, we believe that the more likely mechanism is the increased serum concentration of atorvastatin.

Currently, there is no recommendation regarding the initiation or continuation of statins in patients with NYHA class II–IV heart failure as there is insufficient information on which to base recommendations for or against statin treatment. In these patients, the choice of statin dose, and using a statin for cardiovascular risk reduction benefit, must be weighed against adverse effects, drug–drug interactions, precautions and contraindications to statin therapy [15]. We would have liked to have arranged SLCOB testing for the patient but were unable to. Further research will be useful in identifying patients at risk for this adverse reaction, and will likely include genetic testing.

Conclusions

This case of severe rhabdomyolysis should stimulate further investigation of the potential negative effects of the initiation of sacubitril/valsartan in patients receiving statin therapy. Since sacubitril/valsartan is targeted for patients with heart failure, we predict that this would comprise a large number of the candidates for treatment. We recommend consideration of obtaining baseline CK levels and LFTs and close observation of patients. In this case, rhabdomyolysis developed within 3 weeks of initiation of sacubitril/valsartan and evaluation within a shorter time frame may be appropriate. Future reports of this reaction may help to define high-risk patients, but it should be noted that our patient had no known high-risk characteristics for the development of rhabdomyolysis, except for prior mild elevations of CK during hospitalizations for CHF exacerbations. We encourage the reporting of any similar reactions to the US FDA, the manufacturer, and the medical community.

Compliance with Ethical Standards

Funding No sources of funding were used in the preparation of this report.

Conflict of interest Eve S. Faber, Madhavi Gavini, Ronald Ramirez and Richard Sadosky declare that they have no conflicts of interest that are directly relevant to the content of this report.

Consent Written informed consent was obtained from the patient for publication of this case report. A copy of the written consent may be requested for review from the corresponding author.

Open Access This article is distributed under the terms of the Creative Commons Attribution-NonCommercial 4.0 International License (<http://creativecommons.org/licenses/by-nc/4.0/>), which permits any noncommercial use, distribution, and reproduction in any medium, provided you give appropriate credit to the original author(s) and the source, provide a link to the Creative Commons license, and indicate if changes were made.

References

- Giannoglou GD, Chatzizisis YS, Misirli G. The syndrome of rhabdomyolysis: pathophysiology and diagnosis. *Eur J Intern Med.* 2007;18:90–100.
- Weibrecht K, Dayno M, Darling C, et al. Liver aminotransaminases are elevated with rhabdomyolysis in the absence of significant liver injury. *J Med Toxicol.* 2010;6:294–300.
- Zutt R, van der Kooij AJ, Linthorst GE, et al. Rhabdomyolysis: review of the literature. *Neuromuscul Disord.* 2014;24:651–90.
- Melli G, Chaudhry V, Cornblath DR. Rhabdomyolysis: an evaluation of 475 hospitalized patients. *Medicine (Baltimore).* 2005;84:377.
- Thompson PD, Clarkson PM, Rosenson RS. An assessment of statin safety by muscle experts. *Am J Cardiol.* 2006;97(8A):69C–76C.
- Entresto™ [package insert]. East Hanover: Novartis Pharmaceuticals Corporation; 2015. <https://www.pharma.us.novartis.com/product/pi/pdf/entresto.pdf>. Accessed 26 March 2016.
- Product monograph for Entresto™. Dorval, QC H9S 1A9. Novartis Pharmaceuticals Canada, Inc.; 2015.
- Naranjo CA, Busto U, Sellers EM, et al. A method for estimating the probability of adverse drug reactions. *Clin Pharmacol Ther.* 1981;30:239–45.
- Horn JR, Hansten PD, Chan LN. Proposal for a new tool to evaluate drug interaction cases. *Ann Pharmacother.* 2007;41:674–80.
- Ayalaomayajula, S., Pan, W., Han, Y. et al. Assessment of drug–drug interaction potential between atorvastatin and LCZ696, a novel angiotensin receptor neprilysin inhibitor, in healthy Chinese male subjects. *Eur J Drug Metab Pharmacokinet.* doi:10.1007/s13318-016-0349-y (Epub 31 May 2016).
- Niemi M, Pasanen MK, Neuvonen PJ. Organic anion transporting polypeptide 1b1: a genetically polymorphic transporter of major importance for hepatic drug uptake. *Pharmacol Rev.* 2011;63:157–81.
- He YJ, Zhang W, Chen Y, Guo D, Tu JH, Xu LY, et al. Rifampicin alters atorvastatin plasma concentration on the basis of SLCO1B1 521T>C polymorphism. *Clin Chim Acta.* 2009;405:49–52.
- Romaine SP, Bailey KM, Hall AS, Balmforth AJ. The influence of SLCO1B1 (OATP1B1) gene polymorphisms on response to statin therapy. *Pharmacogenomics J.* 2010;10:1–11.
- Kalliokoski A, Niemi M. Impact of OATP transporters on pharmacokinetics. *Br J Pharmacol.* 2009;158(3):693–705.
- Stone NJ, Robinson J, Lichtenstein AH, et al. 2013 ACC/AHA guideline on the treatment of blood cholesterol to reduce atherosclerotic cardiovascular risk in adults: a report of the American College of Cardiology/American Heart Association Task Force on Practice Guidelines. *J Am Coll Cardiol.* 2014;63:2889–934.