



## Case Report

# Life-Threatening, Bleeding Pseudoaneurysm of the External Iliac Artery in the Setting of an Infected Total Hip Arthroplasty from *Pasteurella multocida*

Cory D. Smith, MD, Michael S. Sridhar, MD\*

Department of Orthopedic Surgery, Prisma Health – Upstate, Greenville, SC, USA

## ARTICLE INFO

## Article history:

Received 7 February 2020

Received in revised form

24 June 2020

Accepted 29 June 2020

Available online xxx

## Keywords:

Hip arthroplasty

Infection

*Pasteurella*

Pseudoaneurysm

Vascular complication

External iliac pseudoaneurysm

## ABSTRACT

We present a bleeding, infected (mycotic) pseudoaneurysm from the organism *Pasteurella multocida*. The patient presented septic from an infected total hip arthroplasty and was treated with surgical debridement, component retention, and antibiotics. She re-presented with hip pain and a marked hemoglobin decrease. Vascular studies revealed a pseudoaneurysm of the external iliac artery and large hematoma secondary to contiguous spread of her hip infection. The pseudoaneurysm was treated with an endovascular stent before further debridement surgery to avoid exsanguinating hemorrhage with surgical release of her tamponade. This case demonstrates the utmost importance of recognizing and treating vascular pathology in a patient with an infected prosthetic hip, large hematoma, and decreased hemoglobin.

© 2020 The Authors. Published by Elsevier Inc. on behalf of The American Association of Hip and Knee Surgeons. This is an open access article under the CC BY-NC-ND license (<http://creativecommons.org/licenses/by-nc-nd/4.0/>).

## Introduction

*Pasteurella multocida* (*P. multocida*) is a gram-negative coccobacillus which is often isolated from the mouths of animals and even humans. *Pasteurella* infections in humans are often zoonotic in nature, resulting from dog and cat bites or scratches, and have been documented to cause pneumonia, cellulitis, and even septic arthritis [1–3]. Studies have shown that 50%–65% of healthy dogs and cats have *Pasteurella* in their nasal secretions [4,5]. Infection of total hip arthroplasty (THA) and total knee arthroplasty with *Pasteurella* is rare but can be clinically significant.

Pseudoaneurysm of the external iliac artery is a well-described complication after THA with several documented case reports and series in the literature [6–34]. The most common proposed causes of these pseudoaneurysms are a malpositioned retractor, migration of acetabular cups, and even migrated cement fragmentation after placement of a cemented femoral stem [21,24,25,30]. Another cause could be a long anterior and superomedially directed

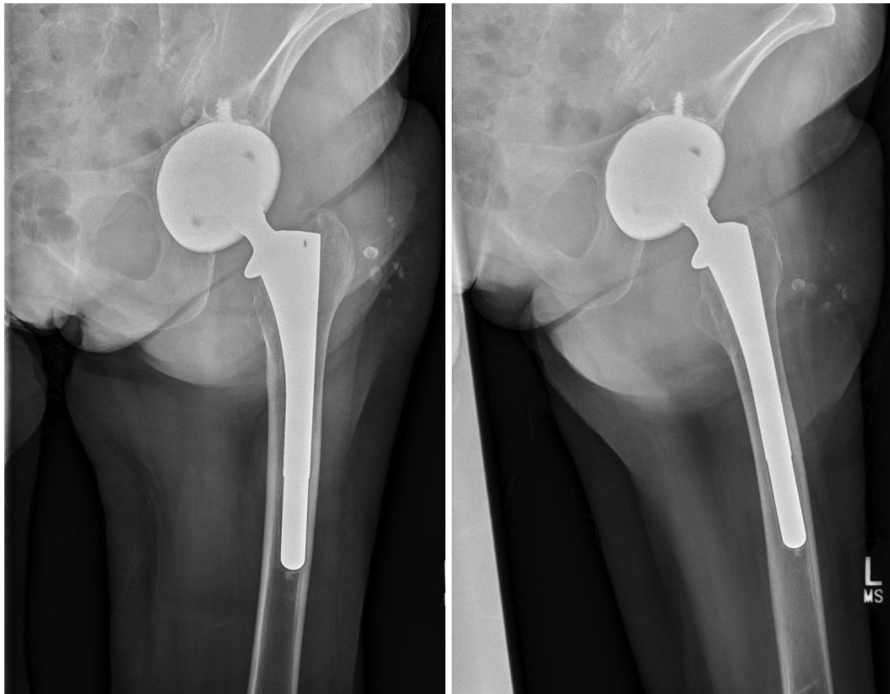
acetabular screw. These false aneurysms can be treated with coiling, stents, and, in some cases, bypass surgery.

## Case history

We present a 63-year-old nondiabetic female with a history of hypertension, coronary artery disease, peripheral vascular disease, chronic back pain, and depression, who initially presented to an outside hospital with complaints of left hip pain after a fall 1 to 2 weeks prior; she denied antecedent pain or fevers. Her peripheral vascular disease history includes studies to evaluate vascular claudication with significant occlusive disease only of her left posterior tibial artery. Her proximal arteries, including through her anterior pelvis, had normal flow. She underwent a left THA for primary osteoarthritis approximately 20 years prior and subsequently underwent 3 revisions secondary to recurrent dislocations with her most recent one 6 years prior (Fig. 1). She was discharged, continued to have pain, and re-presented approximately 1 week later to the outside hospital febrile and tachycardic. She had a peripheral white blood cell count of 31 cells/cm<sup>3</sup>, elevated inflammatory markers with an erythrocyte sedimentation rate (ESR) of 52 mL/hr, and a C-reactive protein (CRP) of 287 mg/L. Her physical examination was only significant for cellulitis around her left hip,

\* Corresponding author. 701 Grove Road, Greenville, SC 29605, USA. Tel.: +1 864-455-7878.

E-mail address: [Michael.sridhar@prismahealth.org](mailto:Michael.sridhar@prismahealth.org)



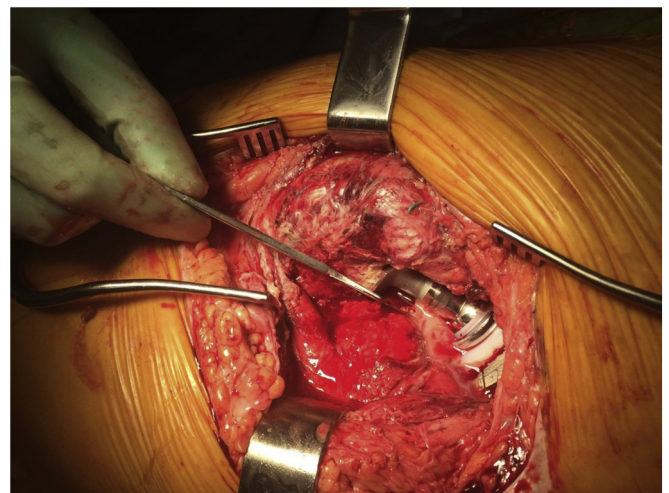
**Figure 1.** Anteroposterior and lateral left hip radiographs showing a press-fit, revision THA.

and broad-spectrum antibiotics were begun. A computed tomography scan of her pelvis revealed abscesses surrounding her left hip with proximal extension into her internal iliac fossa and distal extension from within her gluteal muscles down her thigh. An intra-articular hip aspiration retrieved frank purulence with more than 500,000 white blood cells/cm<sup>3</sup> and 94% neutrophils. At this point, approximately 2 to 3 weeks since her increased pain began, she was transferred to our tertiary-care, academic institution for further care because of the concern for sepsis from periprosthetic infection. She was urgently taken to the operating room for debridement and irrigation of her left hip. Frank purulence was evacuated, and the broken locking ring of her acetabular component (which was unanticipated by the on-call team) was removed. Her blood cultures remained negative.

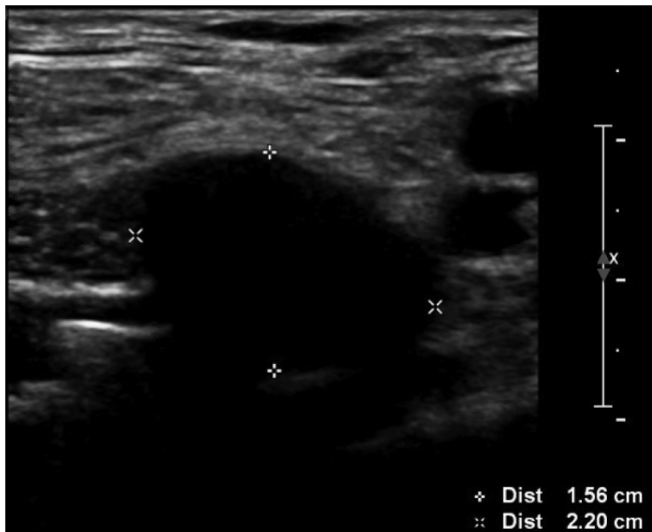On further discussion with the patient, she noted she had been bitten on the left ankle by her cat a few weeks prior and was treated with a 10-day course of doxycycline. She denied prior left hip or lumbar infection. Cultures from her initial hip aspiration grew *P. multocida*, and infectious disease described the organism as “pan-sensitive” including to their recommended antibiotic course of intravenous (IV) Unasyn® (Pfizer Inc., New York, NY) for 6 weeks with eventual transition to indefinite oral suppression with doxycycline. Two days after initial debridement, the patient was taken back for another debridement of the left hip joint and index debridement of her left hemipelvis. At her internal iliac fossa, hematoma instead of frank purulence was found. During the posterior approach to the hip, we encountered further purulence (Fig. 2), particularly with careful dissection along her posterior column. We evaluated her components, and they appeared well-fixed without obvious polyethylene wear or metallosis. We elected to neither dislocate nor consider exchange or explant of her components, given the patient was still actively septic and not hemodynamically optimized for lengthy surgery and/or increased blood loss, not to mention her atypical (yet stable) articulation (Fig. 2). At her internal iliac fossa and hip, we used gentamicin-loaded acrylic cement

beads (Palacos® R-G, Zimmer Orthopaedic Surgical Products, Dover, OH) impregnated with 4 grams of vancomycin and 3 grams of Unasyn® powder (Pfizer Inc., New York, NY). There was no plan to return to the operating room to remove the nonresorbable beads. The wounds were definitively closed and protected with topical negative-pressure wound therapy. Postoperatively, we allowed full weight-bearing. The patient clinically improved rapidly and was discharged to a skilled nursing facility 2 weeks later.

She did not follow-up with orthopaedics as an outpatient but did follow-up once with infectious disease at which time her IV Unasyn® (Pfizer Inc., New York, NY) was transitioned to oral doxycycline for indefinite suppression. Five months later, she



**Figure 2.** Intraoperative photograph during her second washout during her first admission. The freer elevator is showing copious purulence flowing from her “tripolar” revision articulation.

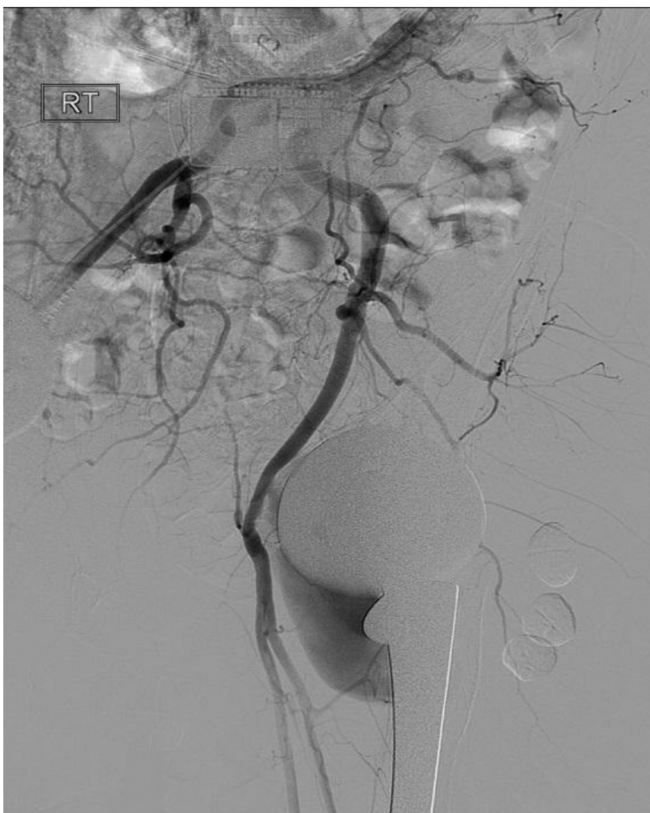

**Figure 3.** Ultrasound image depicting a large pseudoaneurysm emanating from the external iliac artery.

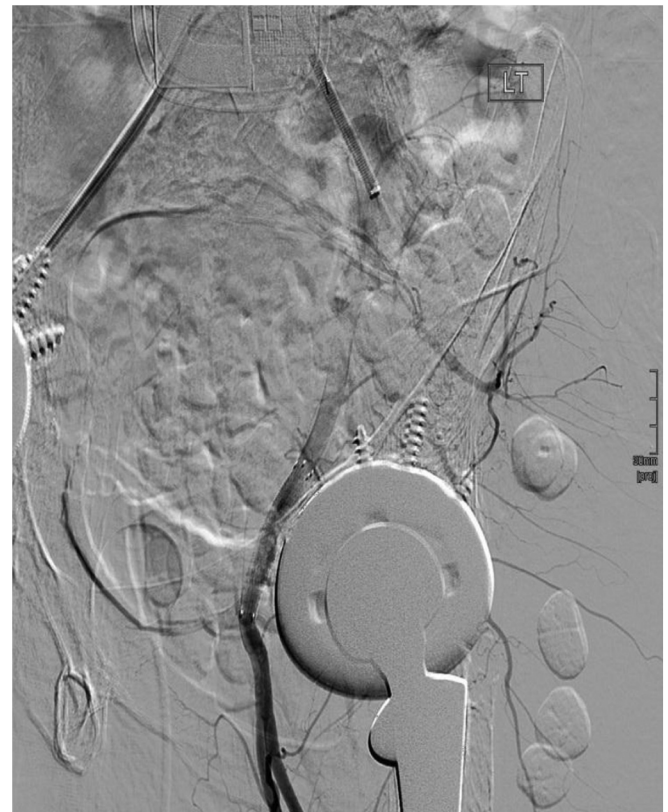presented to an outside hospital after a “pop” and worsened left hip pain. She was discharged without an orthopaedic consult and re-presented 6 weeks later to our emergency department with continued, worsening left hip pain. On examination, her left hip was fluctuant and tender beneath a sealed, nonerythematous wound. Lab work showed a normal ESR, but her CRP had elevated from 23 mg/L to 140 mg/L at the outside emergency department 6 weeks prior. Most notably, her hemoglobin had dropped from 10 to 5 g/dL. Her international normalized ratio was 1.4 while on

clopidogrel. The patient also had a urinary tract infection with a positive culture for *Proteus mirabilis*.

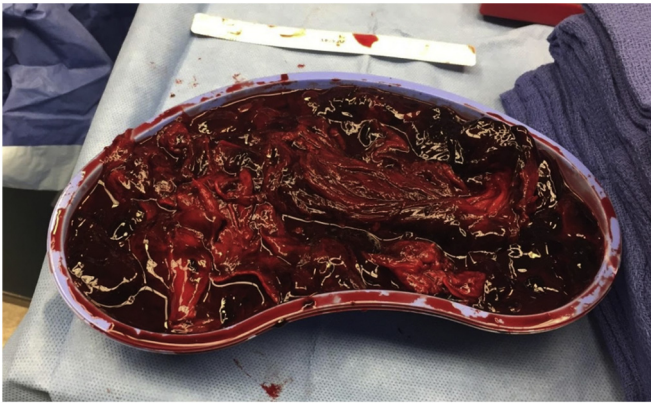
There was concern for an expanding hematoma in the setting of periprosthetic hip infection, and computed tomography angiography confirmed a large amount of collected blood. The radiologist noted no active arterial extravasation from the external iliac or femoral arteries, but that the study was difficult to interpret secondary to metallic artifact. We remained suspicious and consulted a vascular surgeon, and an ultrasound revealed a pseudoaneurysm (6 × 2 cm) emanating from the left, distal external iliac artery in close relation to her acetabular component (Fig. 3). They administered on-table angiography and stented the bleeding pseudoaneurysm (Figs. 4 and 5). The vascular surgeon agreed this was a septic pseudoaneurysm resulting from contiguous spread of the patient’s periprosthetic infection along her acetabular component and its screw(s). Later that day, she underwent surgical decompression and debridement of her left hip (along with removal of its cement beads while her internal iliac fossa was not reoperated on, and its beads were retained), which revealed copious amounts of foul-smelling hematoma and necrotic muscle (Fig. 6). Importantly, she did retain the majority of the gluteus medius inserting on her greater trochanter (Fig. 7). Cultures from this procedure grew only *Cutibacterium acnes*. Her components remained well-fixed without any obvious polyethylene wear or metallosis. Again, we opted to retain them, given risks including the blood loss it would take to remove her fully porous-coated femoral stem. She would return to the operating room for a repeat debridement 3 days later, which revealed neither necrotic tissue nor further hematoma development. She was primarily closed over resorbable antibiotic beads (Stimulan®, Biocomposites Inc., Wilmington, NC) impregnated with vancomycin and tobramycin powder (dosage not dictated by



**Figure 4.** Angiography showing active extravasation from the left external iliac artery.



**Figure 5.** Angiography showing stent placement and no further extravasation from the left external iliac artery.



**Figure 6.** During her second admission after stent placement, this is the hematoma among necrotic muscle we excised from her hip and thigh.

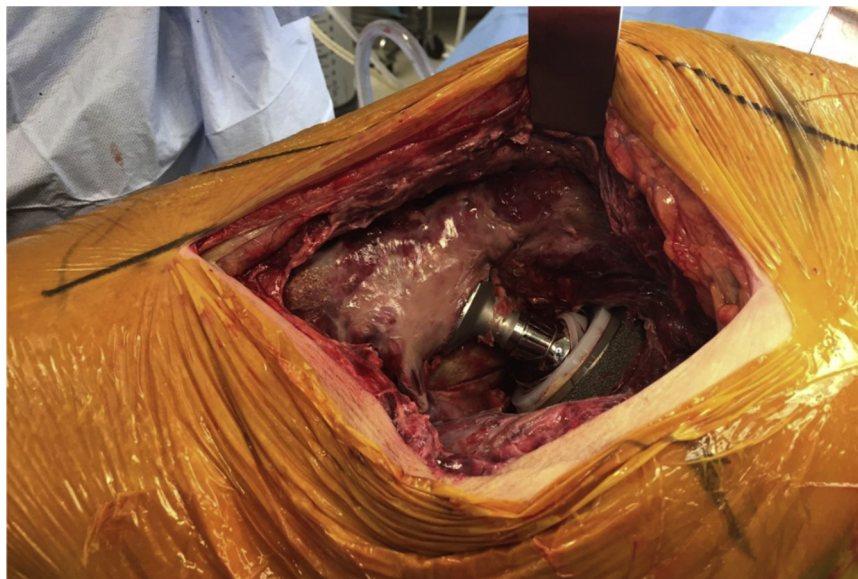
the operative surgeon). While an inpatient, she was treated with IV vancomycin and piperacillin-tazobactam (Zosyn®, Pfizer Inc., New York, NY). She was transitioned back to oral doxycycline indefinitely at discharge. She again did well postoperatively and was discharged to a rehabilitation facility for 1 month before returning home. She followed-up and was ambulating comfortably with a walker and had a well-healing wound. Her CRP had come down to 2.4 mg/L, and her ESR remained normal at 14 mL/hr. She had declined any further vascular surgery on discharge, despite their recommendation of an iliofemoral bypass, and became quite satisfied with her quality of life. She continued to follow-up and did well until she fell and sustained a nondisplaced right superior pubic ramus fracture. She underwent a computed tomography angiography at that time that showed no recurrent pseudoaneurysm formation at the left external iliac artery and patent and stable position of her stent. In addition, she had no obvious abscess or hematoma reformation. At her latest follow-up with us over 2 years out from her first debridement, and while still on doxycycline, we did assess a small, draining area at her left hip felt to represent a draining sinus. We discussed with the patient that this likely represented a chronically infected prosthesis. She refused any further

surgery and was counseled on monitoring for worsening signs or symptoms of systemic illness and abscess formation. Owing to some developing limb ischemia, the patient ultimately underwent iliofemoral bypass with a deep femoral vein graft 2 and a half years after her initial presentation.

## Discussion

We present here the rare complication of a bleeding, mycotic pseudoaneurysm secondary to contiguous spread of periprosthetic hip infection. Review of the literature revealed 27 cases of vascular complications including pseudoaneurysms of the iliac arteries after THA, but these were all aseptic [7–35]. The majority of these were treated with endovascular coiling/stenting similar to that in the patient in our case. As discussed previously, causes of pseudoaneurysm after THA have traditionally included aberrant retractor placement, excess medialization (or perforation) of the acetabular cup, cement fragmentation from the femoral component, and long acetabular screws [22–31].

Another unique component of this case was the bacteria causing the infection. *P. multocida* is a facultative, anaerobic, gram-negative coccobacillus commonly found in the nasopharyngeal tract of cats and dogs [1,4,36]. Cats are more frequently found to be colonized with the bacteria. Soft-tissue infection can be associated with cat bites and scratches as the bacteria can be transferred from their mouth to the paw with licking [4,36,37]. Review of the literature reveals that 50% of infections resulting from cat bites and 15–20% of infections from dog bites are caused by *P. multocida* [1,38]. Risk factors for this unique causative organism include advanced age, diabetes, rheumatoid arthritis, obesity, immunosuppression, previous surgical intervention, renal insufficiency, blood loss during surgery, and postoperative drainage [39]. Our review of the literature identified 34 documented cases of periprosthetic knee and hip infections with *P. multocida* [2,3,5,6,37–67]. In the majority of these cases, the patients presented similarly to ours with a clinical picture including pain, an effusion (if at the knee), drainage, fever, and an elevated peripheral white blood cell count, ESR, and CRP. We also found a case that occurred in an immunocompromised patient who presented with sepsis, meningitis, and septic arthritis [52].



**Figure 7.** At the conclusion of the debridement as shown in Fig. 6, this is her cleansed, prosthetic wound bed with some retained gluteus medius insertion at the top of the wound deep to the retractor.

Periprosthetic infection was routinely confirmed with an aspiration and its cell count and culture [68–73]. In most of the cases reviewed, the patients were treated with IV penicillin or a second- or third-generation cephalosporin. The patient in this case was treated with IV Unasyn® (Pfizer Inc., New York, NY) as is the usual protocol when treating patients admitted with infection secondary to dog or cat bites. The patient was eventually discharged with oral doxycycline, which was the most commonly selected oral antibiotic in the published cases we reviewed. However, many different oral antibiotics have been found to be efficacious including penicillin V, amoxicillin, amoxicillin-clavulanate (Augmentin®, GlaxoSmithKline Inc., Brentford, UK), cefuroxime, and fluoroquinolones [2,3,5,6,37–67].

With respect to the surgical treatment of these infections, the treatment of choice varies widely and is often case dependent. As is well-documented, most septic prosthetic joints, especially when outside the acute phase and with radiographic signs of osteolysis or loosening, should be removed and revised (either in 1 or 2 stages after an antibiotic spacer) [57]. Review of the current literature by Honnorat et al. [40] in 2016 found that 54% of cases of prosthetic infections caused by *P. multocida* underwent prosthesis removal, which was lower than we anticipated. Another literature review of *P. multocida* prosthetic infections by Heydemann et al. [39] in 2010 found that 62% of reviewed cases underwent prosthesis removal with reimplantation at a later date. In our case, the patient's press-fit and ingrown acetabular and femoral components were retained as we thought the risks of prosthetic removal (including extensive surgery and blood loss) outweighed the benefits, and her infection did not seem to be overly chronic. In certain scenarios such as those in this patient, a stable implant can be maintained as long as the patient's lab work (falling inflammatory markers, etc.) and examination (and quality of life) continue to be reassuring. As noted previously, we did assess a draining sinus tract at her latest follow-up consistent with recalcitrant, chronic periprosthetic infection, but she refused consideration of any further orthopaedic surgery.

Perhaps, the most important take-home point from this case report is to beware of the THA that presents with a large hematoma without a causative factor such as trauma or heavy, baseline anticoagulation. Although there are anecdotes within the orthopaedic community of patients undergoing hematoma decompression and then exsanguinating in the operating room, we could not find any published reports of this scenario. In our case, if we had been too aggressive with surgery during her second admission before vascular surgery consultation, she very well may have catastrophically bled (perhaps to death) from release of the tamponade on her actively bleeding external iliac artery.

## Summary

A bleeding pseudoaneurysm of the external iliac artery is a rarely documented complication after THA. And a mycotic one resulting from direct spread of infection in the setting of a hip arthroplasty has never been reported in the literature, to our knowledge. Our case presents several learning points including the management of infections secondary to *P. multocida* in THA, the diagnosis and management of pseudoaneurysms in the setting of a THA, and most importantly recognizing the need for imaging and necessary vascular intervention in the setting of a decreased hemoglobin or a large hematoma without a history of previous trauma or heavy, baseline anticoagulation. Our patient was diagnosed with angiography and treated with an endovascular stent, which allowed her to safely undergo debridement and set the stage for component retention and lifetime antibiotic suppression.

## Conflict of interest

The authors declare there are no conflicts of interest.

## References

- [1] Weber DJ, Wolfson JS, Swartz MN, Hooper DC. *Pasteurella multocida* infections. Report of 34 cases and review of the literature. *Medicine (Baltimore)* 1984;63(3):133.
- [2] Arvan GD, Goldberg V. A case report of total knee arthroplasty infected by *Pasteurella multocida*. *Clin Orthop Relat Res* 1978;132:167.
- [3] Spagnuolo PJ. *Pasteurella multocida* infectious arthritis. *Am J Med Sci* 1978;275:359.
- [4] Weber DJ, Hansen AR. Infections resulting from animal bites. *Infect Dis Clin North Am* 1991;5(3):663.
- [5] Luessenhop CP, Higgins LD, Brause BD, Ranawat CS. Multiple prosthetic infections after total joint arthroplasty. Risk factor analysis. *J Arthroplasty* 1996;11:862.
- [6] Alsaffar L, Gaur S. Acute infection of a total hip arthroplasty by *Pasteurella multocida* successfully treated with antibiotics and joint washout. *J Med Cases* 2014;5:411.
- [7] Chen J-L, Yang T-Y, Chuang P-Y, Huang T-W, Huang K-C. Pseudoaneurysm rupture with hemorrhagic shock in a patient with periprosthetic hip joint infection: a case report. *Medicine* 2018;97(26):e11028.
- [8] Fukuhara S, Kanki S, Daimon M, Shimada R, Ozawa H, Katsumata T. Pseudoaneurysm of the external iliac artery is a rare late complication after total hip arthroplasty. *J Vasc Surg Cases Innov Tech* 2017;3(3):149.
- [9] Gorospe L, Tobio-Calo R, Rodriguez-Diaz R, et al. Cement fragment from hip arthroplasty causing deep femoral artery pseudoaneurysm. *Asian Cardiovasc Thorac Ann* 2017;25(9):633.
- [10] Shah A, Botchu R, Dunlop D, Davies AM, James SL. Metal-on-Metal total hip arthroplasty associated with adverse local tissue reaction and pseudoaneurysm of the superior gluteal artery: a case report and literature review. *Surg J* 2016;2(4):e113.
- [11] Horn C, Wang V, Williams M, Jacobs D. Infected iliac pseudoaneurysm after cardiac catheterization complicated by girdlestone pseudoarthroplasty for recurrent infection of hip prosthesis. *Ann Vasc Surg* 2017;40:294.
- [12] Agarwala S, Mohrir G, Moonot P. Internal iliac artery pseudoaneurysm in primary total hip arthroplasty. *Indian J Orthop* 2016;50(2):218.
- [13] Harper K, Iorio J, Balasubramanian E. Profunda femoris pseudoaneurysm following total hip arthroplasty revision. *Case Rep Orthop* 2015;2015:301949.
- [14] Thomas MS, O'Hara JN, Davies AM, James SL. Profunda femoris pseudoaneurysm following Birmingham hip resurfacing: an important differential diagnosis for a periarticular cystic mass. *Skeletal Radiol* 2012;41(7):853.
- [15] Smith GH, Nutton RW, Fraser SC. Iliac artery pseudoaneurysm rupture following excision of an infected hip prosthesis. *J Arthroplasty* 2011;26(6):977.e13.
- [16] Sawbridge D, O'Connor OJ, MacEneaney P, Maher MM, Fitzgerald E. Successful endovascular treatment of an infected external iliac pseudoaneurysm with hemorrhage at total hip arthroplasty. *J Vasc Interv Radiol* 2010;21(7):1135.
- [17] Molfetta L, Chiapale D, Caldo D, Leonardi F. False aneurysm of the superficial femoral artery after total hip arthroplasty: a case report. *Hip Int* 2007;17(4):234.
- [18] Makar RR, Salem A, McGee H, Campbell D, Bateson P. Endovascular treatment of bleeding external iliac artery pseudo-aneurysm following control of haemorrhage with sengstaken tube during revision total hip arthroplasty. *Ann R Coll Surg Engl* 2007;89(5):W4.
- [19] D'Angelo F, Piffaretti G, Carrafiello G, et al. Endovascular repair of a pseudoaneurysm of the common femoral artery after revision total hip arthroplasty. *Emerg Radiol* 2007;14(4):233.
- [20] Proschek D, Proschek P, Hochmuth K, Balzer JO, Mack MG, Vogl TJ. False aneurysm of the left femoral artery and thrombosis of the left femoral vein after total hip arthroplasty. *Arch Orthop Trauma Surg* 2006 Sep;126(7):493.
- [21] Ulmar B, Aschoff AJ, Orend KH, Puhl W, Huch K. Minimally invasive intervention for acute bleeding from a pseudoaneurysm after revision hip arthroplasty. *Acta Orthop Belg* 2004;70(4):361.
- [22] Bechet FR, Himmer O, Mairy Y, Looetvoet L. Arterial false aneurysm after total hip arthroplasty. A case report. *Rev Chir Orthop Reparatrice Appar Mot* 2004;90(4):365.
- [23] Nozawa M, Irimoto M, Maezawa K, Hirose T, Shitoto K, Kurosawa H. False aneurysm of the profunda femoris artery after total hip arthroplasty. *J Arthroplasty* 2000;15(5):671.
- [24] Bach CM, Steingruber I, Wimmer C, Ogon M, Frischhut B. False aneurysm 14 years after total hip arthroplasty. *J Arthroplasty* 2000;15(4):535.
- [25] Sethuraman V, Hozack WJ, Sharkey PF, Rothman RH. Pseudoaneurysm of femoral artery after revision total hip arthroplasty with a constrained cup. *J Arthroplasty* 2000;15(4):531.
- [26] Mallory TH, Jaffe SL, Eberle RW. False aneurysm of the common femoral artery after total hip arthroplasty. A case report. *Clin Orthop Relat Res* 1997;105.
- [27] Mody BS. Pseudoaneurysm of external iliac artery and compression of external iliac vein after total hip arthroplasty. Case report. *J Arthroplasty* 1994;9(1):95.

- [28] Taks AC, van der Weijer JA, Jannelli FI, Bronswijk HL. A false aneurysm of the external iliac artery following double cup arthroplasty of the hip. *Neth J Surg* 1980;32(1):34.
- [29] Suren EG, Mellmann JR, Letz KH. Vascular complications of alloplastic hip replacement. *Archiv für Orthopädische und Unfall-Chirurgie* 1976;85(2):217.
- [30] Fitzgerald RH. Infected total hip arthroplasty: diagnosis and treatment. *J Am Acad Orthop Surg* 1995;3:249.
- [31] Bergqvist D, Carlsson AS, Ericsson BF. Vascular complications after total hip arthroplasty. *Acta Orthop* 1983;54(2):157.
- [32] Mutlu S, Guler O, Ucar A, Mahirogullari M. An unusual complication following total hip arthroplasty: median circumflex femoral artery pseudoaneurysm. *Acta Orthop Traumatol Turc* 2014;48(1):106.
- [33] Garrido-Gómez J1, Garrido-Gómez MN, Arrabal-Polo MA, Garrido-Pareja F, Linares-Palomino JP. Iatrogenic false aneurysms. A rare complication of hip surgery. *Hip Int* 2012;22(4):397.
- [34] Calligaro KD, Dougherty MJ, Ryan S, Booth RE. Acute arterial complications associated with total hip and knee arthroplasty. *J Vasc Surg* 2003;38(6):1170.
- [35] Adovasio R, Mucelli FP, Lubrano G, et al. Endovascular treatment of external iliac artery injuries after hip arthroplasty. *J Endovasc Ther* 2003;10(3):672.
- [36] Carter GR. Pasteurellosis: *pasteurella multocida* and *pasteurella hemolytica*. *Adv Vet Sci* 1967;11:321.
- [37] Mehta H, Mackie I. Prosthetic joint infection with *Pasteurella multocida* following cat scratch: a report of 2 cases. *J Arthroplasty* 2004;19:525.
- [38] Ferguson KB, Bharadwaj R, MacDonald A, Syme B, Bal AM. *Pasteurella multocida* infected total knee arthroplasty: a case report and review of the literature. *Ann R Coll Surg Engl* 2014;96:e1.
- [39] Heydemann J, Heydemann JS, Antony S. Acute infection of a total knee arthroplasty caused by *Pasteurella multocida*: a case report and a comprehensive review of the literature in the last 10 years. *Int J Infect Dis* 2010;14(Suppl 3):e242.
- [40] Honnorat E, Seng P, Savini H, et al. Prosthetic joint infection caused by *Pasteurella multocida*: a case series and review of literature. *BMC Infect Dis* 2016;16(1):435.
- [41] Hubbert WT, Rosen MN. *Pasteurella multocida* infections. II. *Pasteurella multocida* infection in man unrelated to animal bite. *Am J Public Health Nations Health* 1970;60:1109.
- [42] Elliott DR, Wilson M, Buckley CMF, Spratt DA. Cultivable oral microbiota of domestic dogs. *J Clin Microbiol* 2005;43:5470.
- [43] Griffin AJ, Barber HM. Letter: joint infection by *pasteurella multocida*. *Lancet* 1975;1:1347.
- [44] Maurer KH, Hasselbacher P, Schumacher HR. Letter: joint infection by *pasteurella multocida*. *Lancet* 1975;2:409.
- [45] Sugarman M, Quismorio FP, Patzakis MJ. Letter: joint infection by *pasteurella multocida*. *Lancet* 1975;2:1267.
- [46] Gomez-Reino JJ, Shah M, Gorevic P, Lusskin R. *Pasteurella multocida* arthritis. Case report. *J Bone Joint Surg* 1980;62:1212.
- [47] Mellors JW, Schoen RT. *Pasteurella multocida* prosthetic joint infection. *Ann Emerg Med* 1985;14:617.
- [48] Orton DW, Fulcher WH. *Pasteurella multocida*: bilateral septic knee joint prostheses from a distant cat bite. *Ann Emerg Med* 1984;13:1065.
- [49] Gabuzda GM, Barnett PR. *Pasteurella multocida* infection in a total knee arthroplasty. *Orthop Rev* 1992;21(601):604.
- [50] Guion TL, Sculco TP. *Pasteurella multocida* infection in total knee arthroplasty. Case report and literature review. *J Arthroplasty* 1992;7:157.
- [51] Braithwaite BD, Giddins G. *Pasteurella multocida* infection of a total hip arthroplasty. A case report. *J Arthroplasty* 1992;7:309.
- [52] Antuña SA, Méndez JG, Castellanos JL, Jimenez JP. Late infection after total knee arthroplasty caused by *Pasteurella multocida*. *Acta Orthop Belg* 1997;63:310.
- [53] Takwale VJ, Wright ED, Bates J, Edge AJ. *Pasteurella multocida* infection of a total hip arthroplasty following cat scratch. *J Infect* 1997;34:263.
- [54] Maradona JA, Asensi V, Carton JA, Rodriguez Guardado A, Lizón CJ. Prosthetic joint infection by *Pasteurella multocida*. *Eur J Clin Microbiol Infect Dis* 1997;16:623.
- [55] Chikwe J, Bowditch M, Villar RN, Bedford AF. Sleeping with the enemy: *pasteurella multocida* infection of a hip replacement. *J R Soc Med* 2000;93:478.
- [56] Stiehl JB, Sterkin LA, Brummitt CF. Acute *pasteurella multocida* in total knee arthroplasty. *J Arthroplasty* 2004;19:244.
- [57] Polzhofer GK, Hassenpflug J, Petersen W. Arthroscopic treatment of septic arthritis in a patient with posterior stabilized total knee arthroplasty. *Arthroscopy* 2004;20:311.
- [58] Heym B, Jouve F, Lemoal M, Veil-Picard A, Lortat-Jacob A, Nicolas-Chanoine MH. *Pasteurella multocida* infection of a total knee arthroplasty after a "dog lick". *Knee Surg Sports Traumatol Arthrosc* 2006;14:993.
- [59] Kadakia AP, Langkamer VG. Sepsis of total knee arthroplasty after domestic cat bite: should we warn patients? *Am J Orthop (Belle Mead NJ)* 2008;37:370.
- [60] Romanò CL, De Vecchi E, Vassena C, Manzi G, Drago L. A case of a late and atypical knee prosthetic infection by no-biofilm producer *Pasteurella multocida* strain identified by pyrosequencing. *Pol J Microbiol* 2013;62:435.
- [61] Ciampolini J, Timperley J, Morgan M. Prosthetic joint infection by cat scratch. *J R Soc Med* 2004;97:441.
- [62] Zebeede E, Levinger U, Weinberger A. *Pasteurella multocida* infectious arthritis. *Isr Med Assoc J* 2004;6:778.
- [63] Serrano MT, Menéndez JN, García Bde L, Fernández ML. Infección de prótesis articular de rodilla por *Pasteurella multocida*. *Enferm Infecc Microbiol Clin* 2007;25:492.
- [64] Blanco JF, Pescador D, Martín JM, Cano C, Sanchez MD. Acute infection of total knee arthroplasty due to a cat scratch in a patient with rheumatoid arthritis. *J Clin Rheumatol* 2012;18:314.
- [65] Miranda I, Angulo M, Amaya JV. Acute total knee replacement infection after a cat bite and scratch: a clinical case and review of the literature. *Rev Esp Cir Ortop Traumatol* 2013;57:300.
- [66] Subramanian B, Holloway E, Townsend R, Sutton P. Infected total knee arthroplasty due to postoperative wound contamination with *Pasteurella multocida*. *BMJ Case Rep* 2013;2013.
- [67] Velez FA, Laboy Ortiz IE, Lopez R, Sanchez A, Colon M, Hernan Martinez J. *Pasteurella multocida*: a nightmare for a replaced joint and the challenge to save it. *Bol Asoc Med P R* 2014;106:43.
- [68] Annual joint replacement registry 2016 annual report. [http://www.ajrr.net/images/annual\\_reports/AJRR\\_2016\\_Annual\\_Report\\_final.pdf](http://www.ajrr.net/images/annual_reports/AJRR_2016_Annual_Report_final.pdf). [Accessed 12 January 2019].
- [69] Zawadzki N, Wang Y, Shao H, et al. Readmission due to infection following total hip and total knee procedures: a retrospective study. *Medicine (Baltimore)* 2017;96(38):e7961.
- [70] Springer BD, Cahue S, Etkin CD, Lewallen DG, McGrory BJ. Infection burden in total hip and knee arthroplasties: an international registry-based perspective. *Arthroplasty Today* 2017;3(2):137.
- [71] Phillips JE, Crane TP, Noy M, Elliott TS, Grimer R. The incidence of deep prosthetic infections in a specialist orthopaedic hospital: a 15-year prospective survey. *J Bone Joint Surg Br* 2006;88:943.
- [72] Gundtoft PH, Overgaard S, Schønheyder HC, Møller JK, Kjærsgaard-Andersen P, Pedersen AB. The "true" incidence of surgically treated deep prosthetic joint infection after 32,896 primary total hip arthroplasties: a prospective cohort study. *Acta Orthop* 2015;86(3):326.
- [73] Tande AJ, Patel R. Prosthetic joint infection. *Clin Microbiol Rev* 2014;27(2):302.