

# Cutaneous plasmacytoma-like posttransplant lymphoproliferative disorder after renal transplantation with response to imiquimod 5% cream and reduced immunosuppression



Danya Traboulsi, MD, John Wink, MD, Rachel Wong, MD, Iwona Auer, MD, Pavandeep Gill, MD, Jason Tay, MD, and Jori Hardin, MD  
Calgary, Alberta, Canada

**Key words:** plasmacytoma; posttransplant lymphoproliferative disorder; renal transplantation.

## INTRODUCTION

Posttransplant lymphoproliferative disorder (PTLD) describes a varied group of lymphoid proliferative processes that affect immunosuppressed solid organ and bone marrow transplant recipients. Approximately 70% of PTLD cases are related to Epstein-Barr virus (EBV) infection, and the average onset is 8.2 years after transplant.<sup>1</sup> Plasmacytoma-like PTLD is a particularly rare monomorphic form of PTLD with plasmacytic differentiation. There are very few cases in the literature describing cutaneous manifestations of plasmacytoma-like PTLD.<sup>1-13</sup> We report a unique case of cutaneous EBV-negative plasmacytoma-like PTLD presenting 25 years after renal transplant, responsive to reduced immunosuppression and topical imiquimod 5% cream.

## CASE REPORT

A 27-year-old man with a history of renal transplantation in 1992 for congenital hypoplastic kidney-related renal failure presented to the dermatology transplant clinic for evaluation of a 2-year history of pruritic plaques in the axillae and inguinal folds recalcitrant to treatment with topical corticosteroids, topical tacrolimus 0.1% ointment, and topical antifungals. Past medical history was notable for bilateral optic neuritis, hypertension, and epilepsy. Relevant review of systems was negative. His immunosuppressive regimen of tacrolimus 2 mg orally twice daily, mycophenolate mofetil 750 mg orally twice daily, and prednisone 5 mg orally daily had remained unchanged for many years. On clinical examination,

### Abbreviations used:

EBV: Epstein-Barr virus  
PTLD: posttransplant lymphoproliferative disorder

there were symmetric erythematous fissured and macerated plaques in the axillae, intergluteal, and inguinal folds with no palpable lymphadenopathy (Fig 1).

The differential diagnosis included allergic or irritant contact dermatitis, dermatophytosis, cutaneous candidiasis, recalcitrant frictional intertrigo, inverse psoriasis, granular parakeratosis, Hailey-Hailey disease, and pemphigus vegetans.

A biopsy of the skin on the right side of the inguinal fold showed perivascular infiltrates of mature-appearing plasma cells and small lymphocytes in the papillary and superficial dermis with focal epidermotropism (Fig 2). Immunohistochemistry was notable for kappa light-chain restricted plasma cells lacking CD56/cyclin D1/CD20/PAX5/CD10/bcl-6 expression. Test results for EBV-encoded small RNA were negative, and Ki67 showed a low proliferative index (<10%). The lymphocytic infiltrate featured reactive CD3<sup>+</sup>/CD5<sup>+</sup> T cells and scant CD20<sup>+</sup> B lymphocytes. The diagnosis was consistent with cutaneous plasmacytoma-like EBV-negative PTLD.

Further workup was significant for the following: negative for hematopoietic or lymphoid neoplasia on bone marrow biopsy; elevated gamma globulin level (18.1 g/L) on serum protein electrophoresis and

From the University of Calgary, Calgary, Alberta, Canada.

Funding sources: None.

Conflicts of interest: None disclosed.

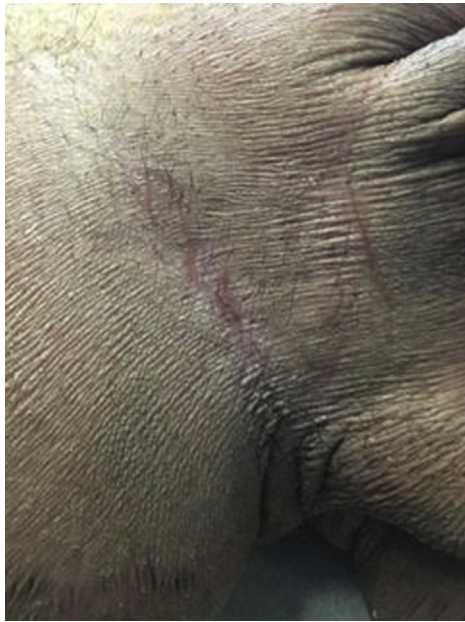Correspondence to: Danya Traboulsi, MD, 347-2233 34 Ave SW, Calgary, Alberta, Canada T2T 6N2. E-mail: [dtraboulsi@qmed.ca](mailto:dtraboulsi@qmed.ca).

JAAD Case Reports 2019;5:1071-4.

2352-5126

© 2019 by the American Academy of Dermatology, Inc. Published by Elsevier, Inc. This is an open access article under the CC BY-NC-ND license (<http://creativecommons.org/licenses/by-nc-nd/4.0/>).

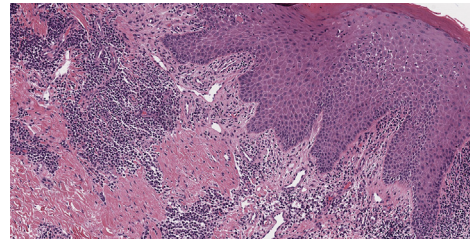
<https://doi.org/10.1016/j.jidcr.2019.10.005>



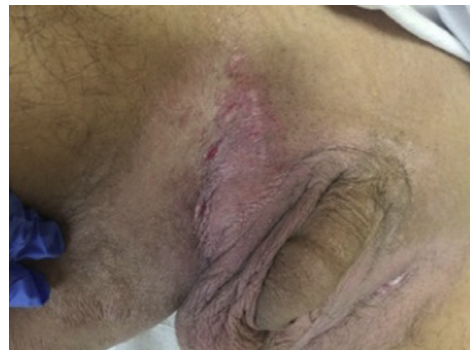**Fig 1.** Atrophic, erythematous, fissured plaques in the inguinal fold on the right side.

immunofixation; elevated free  $\kappa$  (20.9 mg/L), normal free  $\lambda$  (8.27 mg/L), and increased  $\kappa/\lambda$  ratio (2.53) of serum immunoglobulin free light chains; normal lactate dehydrogenase and C-reactive protein levels; and negative blood EBV polymerase chain reaction. Whole-body positron emission tomography/computed tomography showed multiple sites of moderate to intense fluorodeoxyglucose avid disease, including lymph nodes in the neck, bulky bilateral lingual tonsils, and lymph nodes in the pelvis.

The consultant hematologist believed that the presentation was most consistent with limited cutaneous PTLD with reactive adenopathy as opposed to disseminated PTLD. A reduction in immunosuppression was initiated as first-line therapy; mycophenolate mofetil was discontinued, and the dose of tacrolimus reduced. Repeat whole-body positron emission tomography/computed tomography 5 months later showed significant interval decrease or resolution in the metabolic activity within the multiple groin, neck, and tonsillar lymph nodes. Topical imiquimod 5% cream was added as skin-directed therapy applied twice per week for two months and then increased to daily applications (Fig 3). After 10 months of therapy with imiquimod, along with a reduction in immunosuppressive medications, the skin appeared normal (Fig 4). Repeat skin biopsies from inguinal sites showed no evidence of residual disease.



**Fig 2.** Punch biopsy from the inguinal area on the right side showing perivascular infiltrates of mature-appearing plasma cells and small lymphocytes in the papillary and superficial dermis with focal epidermotropism.

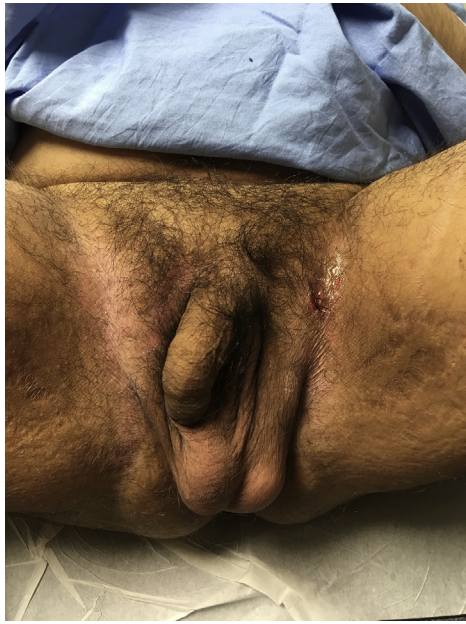

**Fig 3.** Significantly increased erythema and inflammation in the inguinal region on the right side after 3 months of therapy with imiquimod 5% cream.

## DISCUSSION

Pathologically, PTLD is an umbrella term for a spectrum of disorders ranging from infectious mononucleosis to frank lymphoma. PTLD was first described in 1969, and data from large transplantation registries have shown an increased incidence in recent years; this is attributed to the growing number of transplants, use of new immunosuppressive regimens, improved diagnostic tools, and increased awareness of the condition.<sup>14</sup> Small intestine transplant recipients are at highest risk for developing PTLD (up to 32%), whereas recipients of pancreas, heart, lung, and liver transplants are at moderate risk (3%-12%), and renal transplant recipients are at lowest risk (1%-2%).<sup>15</sup> However, renal transplant recipients have a higher cumulative incidence of PTLD 10 years after transplant than liver transplant recipients.<sup>16</sup> The theories behind the development of PTLD include universal programmed death-ligand 1 expression in tumor cells independent of EBV status and morphologic classification, as well as chronic inflammation resulting in lymphomagenesis.<sup>17,18</sup>

Primary cutaneous plasmacytoma-like PTLD is extremely rare, with fewer than 20 published cases in the literature.<sup>1-13</sup> This scarcity of information poses prognostic and therapeutic uncertainty. Limited



**Fig 4.** At 10 months after topical imiquimod therapy and reduction in immunosuppression, there is no clinically evident sign of cutaneous PTLD (inguinal fold on the left side is the site of repeat biopsy).

evidence suggests that plasmacytoma-like PTLD has a favorable outcome compared with other types of PTLD.<sup>19</sup> The 2017 World Health Organization classification separates PTLD into 6 main pathologic types: plasmacytic hyperplasia, infectious mononucleosis, florid follicular hyperplasia, polymorphic PTLD, monomorphic PTLD, (including both B-cell and T-cell neoplasms), and classic Hodgkin lymphoma.<sup>20</sup> Plasmacytoma-like PTLD is a monomorphic B-cell PTLD subtype that is typically CD20<sup>-</sup>.

Most reported cases of plasmacytoma-like PTLD presented as nodules in the skin.<sup>1-13</sup> Very few cases manifested as erythematous plaques or ulcerations, and the majority were EBV<sup>+</sup>.<sup>3,7</sup> To our knowledge, this is the first case of an intertriginous distribution.

Furthermore, this case represents the longest latency period reported between transplantation and the diagnosis of plasmacytoma-like PTLD presenting in the skin. Although the patient had been symptomatic for 2 years before the diagnosis, primary cutaneous PTLD was not confirmed until 25 years and 4 months after transplant. Most other cases are diagnosed within 10 years of transplantation.<sup>1</sup> Of note, EBV<sup>-</sup> monomorphic PTLD often has a later onset after transplant than EBV<sup>+</sup> cases.<sup>21</sup>

Treatment of localized cutaneous disease consists primarily of reduction in immunosuppression, radiation, or surgical excision.<sup>9</sup> Other treatment strategies include antiviral therapy, systemic chemotherapy, and rituximab.<sup>9</sup> Imiquimod is a

synthetic toll-like receptor 7 agonist that stimulates innate and cell-mediated immunity to induce anti-tumor effects and has been used to treat a number of cutaneous malignancies.<sup>22</sup> To our knowledge, this is the first report of topical imiquimod as a therapeutic option for cutaneous PTLD. We believe that topical imiquimod did have an adjunctive role in the treatment of this patient, given the significant improvement in his cutaneous findings with the addition of imiquimod compared with the preceding 5 months when reduced immunosuppression was the only therapy. Additionally, he developed a marked inflammatory reaction to the imiquimod, similar to what is observed in the treatment of other cutaneous malignancies with imiquimod.

In conclusion, we present a case of EBV<sup>-</sup> plasmacytoma-like PTLD presenting in the skin 25 years after renal transplant. Our case highlights the fact that plasmacytoma-like PTLD should be added to the differential diagnosis for erythematous intertriginous plaques in transplant patients unresponsive to traditional topical regimens for treatment of intertrigo. Given that reduction in immunosuppression is often sufficient to treat localized plasmacytoma-like PTLD, it is important to identify this disease early and modify immunosuppressant regimens in transplant patients to avoid worsened morbidity and mortality.

#### REFERENCES

1. Molina-Ruiz AM, Á Pulpillo, Lasanta B, Zulueta T, Andrades R, Requena L. A rare case of primary cutaneous plasmacytoma-like lymphoproliferative disorder following renal transplantation. *J Cutan Pathol.* 2012;39(7):685-689.
2. Pacheco TR, Hinthner L, Fitzpatrick J. Extramedullary plasmacytoma in cardiac transplant recipients. *J Am Acad Dermatol.* 2003;49(5):255-258.
3. Tessari G, Fabbian F, Colato C, et al. Primary cutaneous plasmacytoma after rejection of a transplanted kidney: case report and review of the literature. *Int J Hematol.* 2004;80(4):361-364.
4. Willoughby V, Werlang-Perurena A, Kelly A, Francois J, Donner LR. Primary cutaneous plasmacytoma (posttransplant lymphoproliferative disorder, plasmacytoma-like) in a heart transplant patient. *Am J Dermatopathol.* 2006;28(5):442-445.
5. Richendollar BG, Hsi ED, Cook JR. Extramedullary plasmacytoma-like posttransplantation lymphoproliferative disorders: clinical and pathologic features. *Am J Clin Pathol.* 2009;132(4):581-588.
6. McFarlane R, Hurst S, Sabath D, George E, Argenyi Z. A rare case of plasmacytoma-like post-transplant lymphoproliferative disorder presenting in the skin of a lung transplant patient. *J Cutan Pathol.* 2008;35(6):599-602.
7. Ibe W, Wittlinger T, Sebastian M, Meyer J, Darius H. A nonhealing ulcer diagnosed as extramedullary plasmacytoma of the limb eight years after cardiac transplantation. *Transplantation.* 1999;68(6):901-904.
8. Leigh BR, Larkin EC, Doggett RL. Solitary extramedullary plasmacytoma five years after successful cardiac

- transplantation: case report and review of the literature. *Am J Clin Oncol*. 1997;20(5):467-470.
9. Samolitis NJ, Bharadwaj JS, Weis JR, Harris RM. Post-transplant lymphoproliferative disorder limited to the skin. *J Cutan Pathol*. 2004;31(6):453-457.
  10. Wang E, Stoecker M. Primary cutaneous giant cell plasmacytoma in an organ transplant recipient: a rare presentation of a posttransplant lymphoproliferative disorder. *Am J Dermatopathol*. 2010;32(5):479-485.
  11. Salama S, Todd S, Cina DP, Margetts P. Cutaneous presentation of post-renal transplant lymphoproliferative disorder: a series of four cases. *J Cutan Pathol*. 2010;37(6):641-653.
  12. Karuturi M, Shah N, Frank D, et al. Plasmacytic post-transplant lymphoproliferative disorder: a case series of nine patients. *Transplant Int*. 2013;26(6):616-622.
  13. Ponder TB, Collins BT, Bee CS, Grosso LE, Dunphy CH. Fine needle aspiration biopsy of a posttransplant lymphoproliferative disorder with pronounced plasmacytic differentiation presenting in the face. A case report. *Acta Cytol*. 2002;46(2):389-394.
  14. Dierickx D, Habermann TM. Post-transplantation lymphoproliferative disorders in adults. *N Engl J Med*. 2018;378(6):549-562.
  15. Opelz G, Dohler B. Lymphomas after solid organ transplantation: a collaborative transplant study report. *Am J Transplant*. 2004;4(2):222-230.
  16. Peters AC, Akinwumi MS, Cervera C, et al. The changing epidemiology of posttransplant lymphoproliferative disorder in adult solid organ transplant recipients over 30 years: a single-center experience. *Transplantation*. 2018;102(9):1553-1562.
  17. De Jong D, Roemer M, Chan J, et al. B-cell and classical Hodgkin lymphomas associated with immunodeficiency. 2015 SH/EAHP workshop report—part 2. *Am J Clin Pathol*. 2017;147(2):153-170.
  18. Rickinson A. Co-infections, inflammation and oncogenesis: future directions for EBV research. *Semin Cancer Biol*. 2014;26:99-115.
  19. Trappe R, Zimmermann H, Fink S, et al. Plasmacytoma-like post-transplant lymphoproliferative disorder, a rare subtype of monomorphic B-cell post-transplant lymphoproliferation, is associated with a favorable outcome in localized as well as in advanced disease: a prospective analysis of 8 cases. *Haematologica*. 2011;96(7):1067-1071.
  20. Swerdlow SH, Webber SA, Chadburn A, Ferry JA. Post-transplant lymphoproliferative disorders. In: Swerdlow SH, Campo E, Harris NL, et al., eds. *WHO Classification of Tumours of Haematopoietic and Lymphoid Tissues* 4th ed. Lyon, France: IARC Press; 2017:453-462.
  21. Luskin MR, Heil DS, Tan KS, et al. The impact of EBV status on characteristics and outcomes of posttransplantation lymphoproliferative disorder. *Am J Transplant*. 2015;15(10):2665-2673.
  22. Huen A, Rook A. Toll receptor agonist therapy of skin cancer and cutaneous T-cell lymphoma. *Curr Opin Oncol*. 2014;26(2):237-244.