

Densiron[®] 68 as an intraocular tamponade for complex inferior retinal detachments

Rumana N Hussain
Somnath Banerjee

Leicester Royal Infirmary,
Leicester, UK

Introduction: Densiron[®] 68 is a high-density liquid used to tamponade inferior retinal detachments. We present a case series of 12 patients treated with Densiron as an intraocular tamponade agent.

Methods: A retrospective analysis of 12 eyes in 12 patients was carried out. The primary endpoint was anatomic reattachment of the retina following removal of Densiron oil.

Results: All patients had inferior detachments; 33% had associated proliferative vitreoretinopathy (PVR). Densiron was utilized as a primary agent in five patients (42%); the remaining patients had prior unsuccessful surgery for retinal reattachment, including pars plana vitrectomy, cryotherapy, laser, encirclement, gas (C3F8 or C2F6), or silicone oil. Eleven patients (91%) had successful reattachment of the retina at 3 months following removal of Densiron; one patient had extensive PVR, total retinal detachment, preretinal macula fibrosis, and chronic hypotony, and surgical intervention was unsuccessful. Six patients (50%) had raised intraocular pressure (IOP), resolving in the majority of cases following Densiron removal; two patients had long-term raised IOP requiring topical or surgical therapy. Of the six phakic patients, 50% developed significant cataract in the operated eye. Of those with successful retinal reattachment, visual outcome was variable, with 36% patients gaining two to four lines on Snellen, 27% remaining objectively the same, and 36% losing one to two lines.

Conclusion: The anatomic success rate is high (91%) in patients requiring Densiron tamponade for inferior retinal detachments with or without evidence of PVR either as a primary or secondary intervention. A common complication is raised IOP; however, this most often resolves following removal of the oil.

Keywords: intraocular tamponade, silicone oil, retinal detachment, retinal reattachments

Introduction

The complexities associated with inferior retinal detachments are well recognized. The difficulties with appropriate postoperative posturing and the predilection of the inferior retina for proliferative vitreoretinopathy (PVR) makes successful repair challenging.¹ These cases have often been repaired utilizing an intraocular tamponade of silicone oil; however, as the density of silicone oil is lower than that of water, the inferior retina is therefore only adequately supported if silicone oil fill is no less than 100%.

Perfluorohexyloctane (F6H8) has also been utilized within model systems due to its higher density; however, the tendency is for this compound to disperse into droplets and emulsify.² The formation of Densiron[®] 68 (Fluoron GmbH, Neu-Ulm, Germany) is a combination of the higher-density F6H8 and polydimethylsiloxane and has been developed for the purpose of intraocular tamponade for such cases (density 1.06 g/cm³; viscosity 1400 mPas at 25°C).

Correspondence: Rumana N Hussain
Leicester Royal Infirmary, Infirmary
Square, Leicester LE1 5VW, UK
Tel +44 (0)300 303 1573
Email rumanahussain@hotmail.com

The reports so far have been encouraging, with good anatomic results for both primary and secondary procedures. Successful reattachment of the retina following use of Densiron as a primary procedure for inferior retinal detachment complicated by PVR is reported for between 91% and 95% of patients.^{3,4} For secondary procedures in patients with previous unsuccessful surgical interventions, anatomic success has understandably been more variable, reported as 46%–70%.^{5,6} These studies also demonstrated a significant improvement in visual acuity following surgical intervention.^{3,4,6}

The main consequence reported is that of raised intraocular pressure (IOP); the rate of IOP > 30 mm Hg has been reported as being 10%–20%,^{3,5,7,8} generally resolving following removal of the agent.^{8,9} In comparison with silicone oil, the rate of raised IOP has been shown to be higher with Densiron in the initial few days postoperatively, but this equalizes after subsequent weeks.⁷ Although most cases of raised IOP resolve after removal of Densiron, the cases that are resistant seem to be more difficult to manage with topical agents than those secondary to silicone oil, occasionally requiring more invasive techniques.⁷

The aim of this report was to analyze the efficacy and rates of complications in patients with inferior retinal detachments treated with Densiron as an intraocular tamponade in our unit.

Methods

A retrospective case note analysis was performed for all patients who had undergone retinal detachment repair utilizing Densiron over the period of October 2007 to August 2009, as identified by the theater logbook. Twelve patients were identified. All patients had rhegmatogenous inferior retinal detachments with or without clinical evidence of PVR; there were no patients with detachments secondary to trauma or any concurrent inflammatory ocular pathology. All patients with inferior detachments were included, whether this was a primary or secondary procedure.

There were no postoperative postural instructions. All patients were followed up for a minimum of 3 months following removal of the Densiron tamponade. Each record was assessed in respect of visual outcome, anatomic position of the retina, IOP, and any further intervention required for either redetachment or raised IOP.

Results

Patient age ranged from 54 years to 72 years; the male to female ratio was 7:5. Indications for use of the high-density

oil were inferior retinal detachments (100%) and associated PVR (four patients; 33%). Densiron was utilized as a primary agent in five patients (42%); the remaining patients had prior unsuccessful surgery for retinal reattachment, including pars plana vitrectomy, cryotherapy, laser, encirclement, gas (C3F8 or C2F6), or silicone oil. Time to removal of Densiron was 46–247 days (manufacturer recommends 60 days).

Eleven patients (91%) had successful reattachment of the retina at 3 months following removal of Densiron; one patient had extensive PVR and total retinal detachment, macula preretinal fibrosis, and chronic hypotony, and surgical intervention was unsuccessful (Figure 1).

Six patients (50%) had raised IOP following Densiron administration, which resolved in the majority of cases following removal of the oil, two patients had long-term raised IOP requiring topical therapy, and one is awaiting Bearvelt tube insertion (Figure 2).

Six patients were pseudophakic; of the remaining six patients, three (50%) developed significant cataract in the operated eye (Figure 3). There were no cases of oil emulsification.

Of those with successful retinal reattachment, visual outcome was variable, with four (36%) patients gaining two to four lines on Snellen, three (27%) remaining objectively the same, and four patients (36%) losing one to two lines on Snellen (Figure 4). These were predominantly due to development of cataract or epiretinal membrane.

Table 1 gives a summary of the pre- and postoperative patient characteristics.

Discussion

Inferior retinal detachments are notoriously difficult to treat due to the increased preponderance of PVR. The use of other

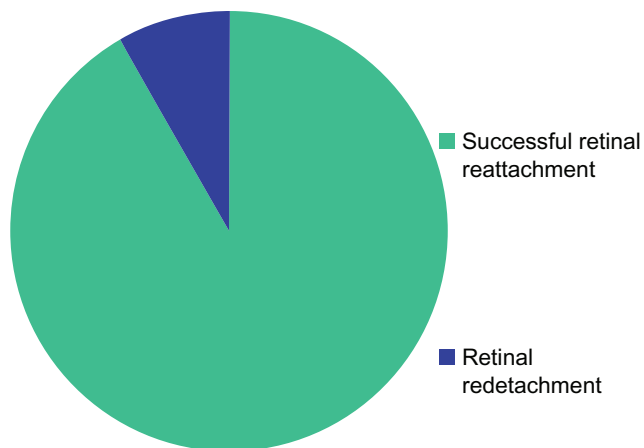


Figure 1 Anatomical reattachment following densiron removal.

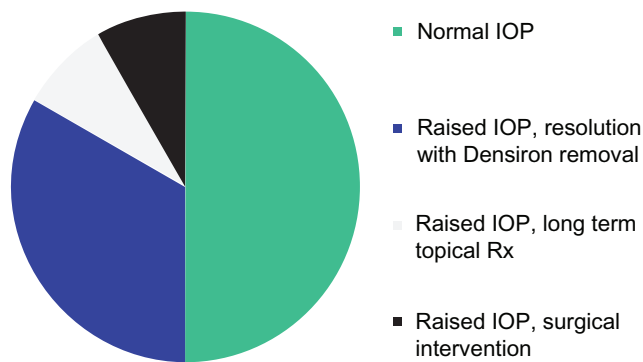


Figure 2 Postoperative raised intraocular pressure rates.

intraocular tamponade agents such as gas or silicone oil is complicated by reduced density in comparison with water. This predisposes to failure of anatomic retinal reattachment, as 100% vitreous fill and tamponade is essentially impossible. In addition, postoperative posturing for patients managed with these agents is consequently quite troublesome. We had no cases of band keratopathy or oil emulsification, which have both been described with silicone oil.¹⁰ Scleral buckles are an alternative therapy modality; however, not only are they more likely to be a cause of postoperative discomfort and inflammation but also they have an increased rate of induced myopia and ocular muscle imbalance. In addition, they are less straightforward in the management of larger and more posterior retinal tears or holes.

Densiron has been shown to have good anatomic results in patients with inferior retinal detachments, with or without the complication of PVR. The reported anatomic success rate for use of silicone oil as an intraocular tamponade varies from 75% to 90%;^{11,12} however, these results are not solely for inferior detachments and will therefore include superior

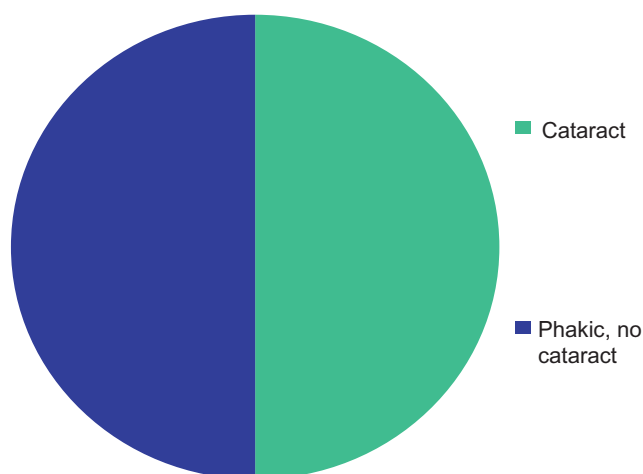


Figure 3 Rates of cataract formation in phakic patients.

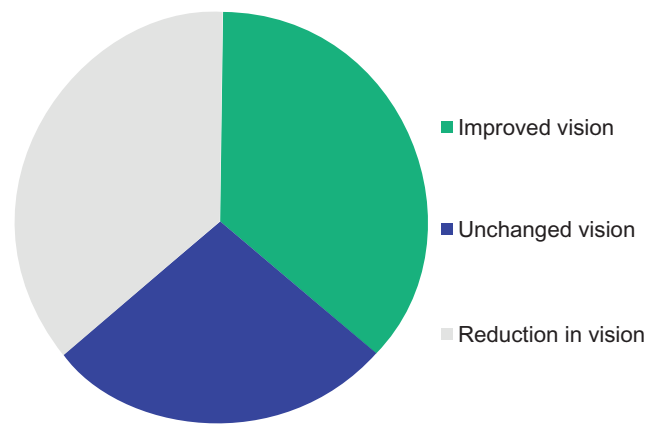


Figure 4 Change in visual acuity (measured by Snellen) post Densiron removal.

pathologies that are adequately tamponaded by a less dense agent. In addition, high-density silicone oil has been trialled for inferior detachments with an anatomic success rate of 79%–88%^{13,14} but with higher rates of emulsification.

The combination of silicone oil with a heavy liquid has enabled the formation of a tamponade agent that is denser than water and is therefore ideal for such inferior pathologies. Posturing is not a problem, as an upright position is much preferred by patients and is utilized for the majority of the day. No postoperative postural instructions were given to the patients in this study. In comparison with silicone oil alone, Densiron is denser and therefore anatomically more effective for inferior pathology, but it also has comparable, if not better, rates of complications.

Our results, although in small numbers, are highly suggestive of a high anatomic success rate whether the use of Densiron as an intraocular tamponade was as a primary agent or as a subsequent procedure following single or multiple failed surgical interventions. There were no cases of oil emulsification; however, the most common complication was raised IOP. The rate of persistent raised IOP following Densiron removal was 16% (two patients). One patient was uncontrolled with topical therapy and required surgical intervention. This rate is consistent with previously reported rates utilizing silicone oil.^{15,16}

Our current study numbers are small, and no direct conclusions can be drawn from a noncomparative study. Further research is required with comparative data with silicone oil in greater numbers. However, these preliminary results suggest effective results with use of Densiron for complex inferior retinal detachments, with safe outcomes comparable with previously reported outcomes with silicone oil. This compound may therefore be considered first line for such procedures.

Table 1 Pre- and postoperative records per patient

Patient	Phakic Initial VA	Prior procedures	Preoperative VA	Indications	Associated procedures	Duration of Densiron	Postoperative VA	Retinal reattachment	Postoperative raised IOP	Resolved IOP following removal	Cataract	Notes
1	Y	6/60	SiO, laser, cryo	CF-6/36	Inf RD PVR	Retinectomy, endolaser	70	CF-6/18 PL	N	N	Y	Sup RD, preretinal macular fibrosis, immobile total RD, iris bombe
2	Pseudo	3/18	3/18	Inf RD PVR	Encirclement Retinotomy, endolaser	247	6/60 3/24	Y	44	Y		
3	Y	CF-6/36	Pneumatic retinopexy C3F8, endolaser	HM	Inf RD	Retinotomy, endolaser	Never removed	HM	Y	N	Y	
4	Pseudo	6/9	Phaco with vitreous loss	6/60-6/36	PVR	Retinectomy, cryo, laser	129	1/24	Y	34	Y	Recurrent iritis ERM
5	Pseudo	6/9	C2F6, cryo Buckle, SiO, laser	HM	PVR, inf RD	ROSO Retinectomy, laser, cryo	46	3/24-6/18	Y	N		
6	Pseudo	6/18-6/9	6/18-6/9	Inf RD	Buckle, laser	77	6/24-6/12	Y	44	Y		ERM
7	Y	6/9	6/9	Inf RD	Retinotomy, laser	58	6/36-6/12	Y	60	N	N	Continued trusopt, alphasgan, xalatan
8	Y	HM	Lensectomy, SiO, laser, cryo	CF	Inf RD	Buckle, retinectomy, ROSO, laser	63	CF	N	38	N	
9	Y	HM	Endolaser Phaco, SiO, laser	6/60	Inf RD, PVR	Retinectomy, endolaser	81	HM	Y	N	N	Amblyopic, preretinal fibrosis, sclerosed vessels preoperatively
10	Pseudo	6/9	6/9	Inf RD	Laser, cryo	142	6/12	Y	N			Early ERM, some RPE changes
11	Y	3/60-6/36	3/60-6/36	Inf RD, multiple holes	Cryo	112	6/12-6/9	Y	45	N	Y	On trusopt, alphasgan. Awaiting MMC bearevelt tube
12	N	3/36	Previous phaco, vitreous loss, SCH	Inf RD, PVR	Retinotomy, buckle, laser	247	6/60	Y	44	Y		

Abbreviations: CF, count fingers; cryo, cryotherapy; ERM, epiretinal membrane; HM, hand movements; inf RD, inferior retinal detachment; IOP, intraocular pressure; MMC, mitomycin C; PL, perception of light; PVR, proliferative vitreoretinopathy; ROSO, removal of silicone oil; RPE, retinal pigment epithelium; SCH, suprachoroidal hemorrhage; SiO, silicone oil; Sup RD, superior retinal detachment; VA, visual acuity.

Disclosure

The authors report no conflicts of interest in this work.

References

1. Singh AK, Glaser BM, Lemor M, Michels RG. Gravity-dependent distribution of retinal pigment epithelial cells dispersed into the vitreous cavity. *Retina*. 1986;6:77–80.
2. Lepori L, Matteoli E, Spanedda A, et al. Combined use of perfluoro-hexyloctane and silicone oil as intraocular tamponade: an in vitro study. *Graefes Arch Clin Exp Ophthalmol*. 2002;244:79–82.
3. Er H. Primary heavy silicone oil usage in inferior rhegmatogenous retinal detachment. *Ophthalmologica*. 2010;224:122–125.
4. Romano M, Stappler T, Marticorena J, et al. Primary vitrectomy with Densiron-68 for rhegmatogenous retinal detachment. *Graefes Arch Clin Exp Ophthalmol*. 2008;246:1541–1546.
5. Sandner D, Engelmann K. First experiences with high-density silicone oil (Densiron) as an intraocular tamponade in complex retinal detachment. *Graefes Arch Clin Exp Ophthalmol*. 2006;244:609–619.
6. Lim B, Vote B. Densiron intraocular tamponade: a case series. *Clin Experiment Ophthalmol*. 2008;36:261–264.
7. Wong D, Kumar I, Quah S, et al. Comparison of postoperative intraocular pressure in patients with Densiron-68 vs conventional silicone oil: a case-control study. *Eye*. 2009;23:190–194.
8. Stappler T, Heimann H, Wong D, et al. Heavy tamponade 2 Densiron 68 in routine clinical practice: anatomical and functional outcomes of a consecutive case series. *Eye*. 2008;22:1360–1365.
9. Li W, Zheng J, Zheng Q, et al. Clinical complications of Densiron 68 intraocular tamponade for complicated retinal detachment. *Eye*. 2010;24:21–28.
10. Federman JL, Schubert HD. Complications associated with the use of silicone oil in 150 eyes after retina-vitreous surgery. *Ophthalmology*. 1988;95:870–876.
11. Van Meurs JC, Mertens DA, Peperkamp E, Post J. Five-year results of vitrectomy and silicone oil in patients with proliferative vitreoretinopathy. *Retina*. 1993;13:285–289.
12. Jonas JB, Knorr HL, Rank RM, Budde WM. Retinal redetachment after removal of intraocular silicone oil tamponade. *Br J Ophthalmol*. 2001;85:1203–1207.
13. Ozdek S, Yuksel N, Gurelik G, Hasanreisoglu B. High-density silicone oil as an intraocular tamponade in complex retinal detachments. *Can J Ophthalmol*. 2011;46:51–55.
14. Regler R, Sachs HG, Hillenkamp J, et al. Long-term evaluation of anatomic and functional results after complicated retinal detachment treated with pars plana vitrectomy and heavy silicone oil tamponade. *Klin Monbl Augenheilkd*. 2009;226:707–701.
15. Honavar SG, Goyal M, Majji AB, et al. Glaucoma after pars plana vitrectomy and silicone oil injection for complicated retinal detachments. *Ophthalmology*. 1999;106:169–176.
16. Al-Jazzaf AM, Netland PA, Charles S. Incidence and management of elevated intraocular pressure after silicone oil injection. *J Glaucoma*. 2005;14:40–46.

Clinical Ophthalmology

Publish your work in this journal

Clinical Ophthalmology is an international, peer-reviewed journal covering all subspecialties within ophthalmology. Key topics include: Optometry; Visual science; Pharmacology and drug therapy in eye diseases; Basic Sciences; Primary and Secondary eye care; Patient Safety and Quality of Care Improvements. This journal is indexed on

Submit your manuscript here: <http://www.dovepress.com/clinical-ophthalmology-journal>

Dovepress

PubMed Central and CAS, and is the official journal of The Society of Clinical Ophthalmology (SCO). The manuscript management system is completely online and includes a very quick and fair peer-review system, which is all easy to use. Visit <http://www.dovepress.com/testimonials.php> to read real quotes from published authors.