

# Distal Avulsion of the Semitendinosus Tendon

## A Case Report

Thomas Kelly,<sup>\*†‡</sup> MPhil (Medicine), MD, Sinem Gultekin,<sup>‡</sup> BBiomed Sci,  
Tom Cross,<sup>§||</sup> MBBS, FACSP, Dip Child Health, ACESP,  
and Julian Feller,<sup>¶</sup> MBBS (Hons), Dip Anat, FRACS, FAOrthA

*Investigation performed at the Sydney Swans Football Club, Sydney, New South Wales, Australia*

**Keywords:** semitendinosus; tendon repair; Australian rules football; distal hamstring

Hamstring injuries (including intramuscular injuries as well as proximal and distal hamstring tendon disruptive injuries) are some of the most common injuries in athletes.<sup>2</sup> In Australian rules football, hamstring muscle injuries are the most common injuries suffered, with professional Australian Football League (AFL) clubs each sustaining an average of 6 injuries per season from their roster of 46 players.<sup>4</sup> Hamstring injuries account for the most time lost from competitive sport (missed games) because of an injury in the AFL.<sup>7</sup> Within hamstring injuries, distal hamstring injuries are far less common than proximal hamstring injuries.<sup>2,7</sup> Treatment protocols for distal musculotendinous hamstring injuries are contentious. Opinion is split between surgical versus nonsurgical (conservative) approaches. Within those who advocate for surgical treatment, opinion is further split between repair versus resection (tenotomy) of the damaged muscle. The vast majority of the available literature that champions operative repair details tenotomy as the approach of choice. The authors were unable to find any literature debating or comparing the differing operative treatment methods for distal hamstring tendon injuries.

We present the case of a 29-year-old male professional athlete who suffered an isolated avulsion of the distal semitendinosus (ST) tendon through a noncontact mechanism during an AFL match. After a review of the available literature and discussion with an expert panel, the athlete elected to undergo direct operative repair 4 days after the injury. This case study describing a successful outcome of early direct operative repair of the ST tendon aims to add to the literature and assist as a reference tool for future athletes and their physicians who are assessing similar injuries.

### CASE PRESENTATION

The patient was a 29-year-old, right foot-dominant male AFL player who suffered an injury to the distal attachment of his right ST tendon during match play. The mechanism of injury was a noncontact eccentric contraction of the right hamstring that occurred while the patient was airborne, after having used his left leg for takeoff (Figure 1). The patient reported that he “felt something tear” and noted acute pain at the site of the combined insertion of the sartorius, gracilis, and ST tendons and bursa, commonly referred to as the pes anserinus<sup>9</sup> on the anteromedial aspect of the right tibia. He likened this to an “electric shock”-type pain associated with paresthesia over his anteromedial shin. The patient attempted to run, but pain and weakness prevented him from doing so. The patient failed sideline functional testing and did not return to the field of play.

On examination, the knee was tender over the region superficial to the insertion point of the pes anserinus tendons. Resisted knee flexion was painful with reduced power. Although the typical contour of the ST tendon in the distal medial thigh and popliteal fossa was clearly visible, as demonstrated by arrow A in Figure 2, on palpation, the tendon did not have comparable tension with resisted knee flexion when compared to the left. A sulcus sign was

\*Address correspondence to Thomas Kelly, MPhil (Medicine), MD, 88 Cascade Street, Paddington, NSW 2021, Australia (email: tkel2180@gmail.com).

<sup>†</sup>Liverpool Hospital, Sydney, New South Wales, Australia.

<sup>‡</sup>University of Sydney, Sydney, New South Wales, Australia.

<sup>§</sup>Stadium Sports Medicine Clinic, Sydney, New South Wales, Australia.

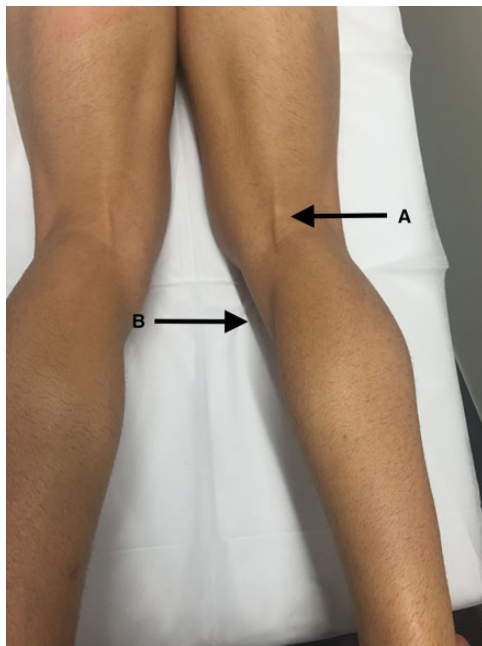
<sup>||</sup>Sydney Swans Football Club, Sydney, New South Wales, Australia.

<sup>¶</sup>OrthoSport Victoria, Melbourne, Victoria, Australia.

The authors have declared that there are no conflicts of interest in the authorship and publication of this contribution. AOSSM checks author disclosures against the Open Payments Database (OPD). AOSSM has not conducted an independent investigation on the OPD and disclaims any liability or responsibility relating thereto.



**Figure 1.** Mechanism of injury: an eccentric contraction of the right hamstring during a center bounce.



**Figure 2.** Arrow A indicates the remaining normal contour of the semitendinosus tendon in the distal thigh. Arrow B indicates a sulcus sign over the site of the semitendinosus insertion, and also represents the area of maximal tenderness.

evident in the pes anserinus anatomic area, where the ST tendon insertion was torn.

The patient had no significant history of hamstring injuries or other injuries to his right knee, nor did he report any feeling of discomfort preceding the injury. The patient had received physical therapy on his right hip for nonspecific muscular tightness before the match, which resolved during the warm-up and did not trouble him during the game. The patient was otherwise fit and well and was on no medication. In particular, there was no history of oral or injectable medications, specifically corticosteroids, which could have weakened the tendon locally or systemically.<sup>12</sup>

Ultrasound was the initial imaging method performed 2 days after the injury. Findings were inconclusive but

indicated a potential distal ST tendon rupture or avulsion. Because of the unusual nature of the injury and the inconclusive ultrasound findings, further imaging was sought. Radiography revealed no fractures or avulsions. Magnetic resonance imaging (MRI) of such soft tissue injuries is considered to have the highest sensitivity.<sup>8</sup> MRI confirmed an ST tendon avulsion from the pes anserinus (Figure 3). An unusually large, intact vinculum was seen to run from the avulsed ST tendon inferiorly, blending fibers onto the medial gastrocnemius and attaching on the shaft of the tibia 18 cm below the knee joint.

An extensive literature search yielded few relevant studies for this specific injury.<sup>1,8-11</sup> After a discussion of the treatment options, the patient elected to undergo surgical repair.

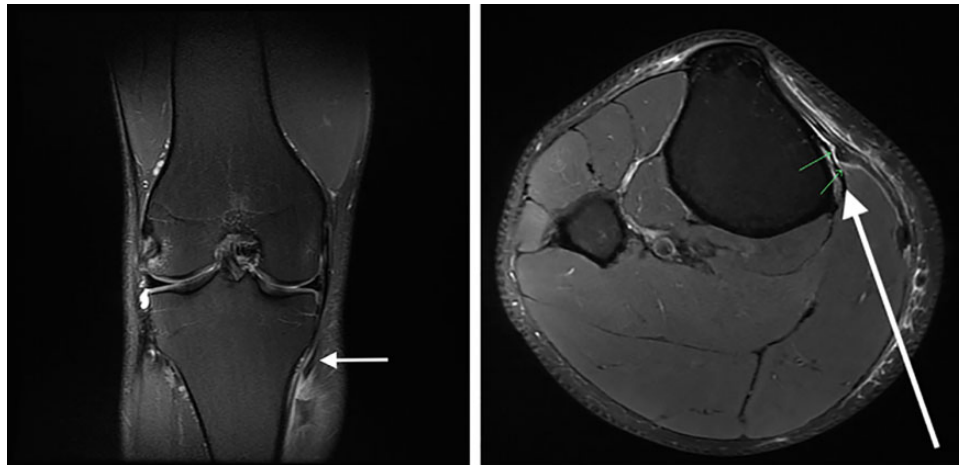During surgery, under tourniquet control, a longitudinal incision was made, centered over the pes anserinus and extending distally. The sartorius fascia was incised obliquely, revealing a complete avulsion of the ST tendon, with no bony fragment avulsion evident, and leaving an adjacent periosteal cuff. A longitudinal incision was made in the fascia distal to this to explore the vinculum of the ST tendon. Hemorrhaging was noted at the distal attachment into the fascia overlying the medial gastrocnemius and adjacent periosteum. No discrete tear was identified, and no intervention was undertaken.

The avulsed ST tendon was tied and repaired back to the periosteal cuff with 2 No. 2 FiberWire sutures (Arthrex) (Figure 4). The wound was irrigated, and layered closure was undertaken.

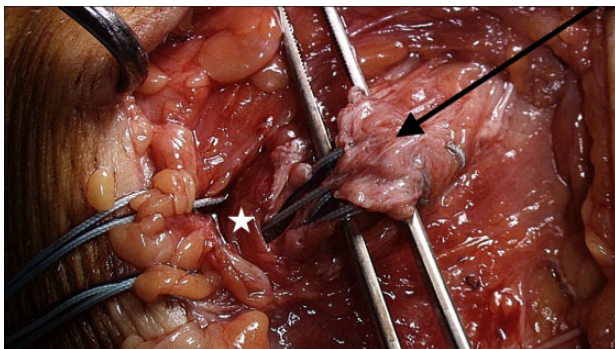
For immediate postoperative management, a hinged/nonhinged knee brace with a cryotherapy option (Cryo/Cuff; OPC Health) was applied to the knee. The patient was allowed to bear weight as tolerated from postoperative day 2. Figure 5 shows the postoperative scar.

## OUTCOME AND FOLLOW-UP

The outpatient review on postoperative day 7 demonstrated good knee flexion against gravity, and improved power was noted when compared to the preoperative state. From postoperative day 10, the patient began stationary cycling, performing strength-based exercises in the gymnasium, and using the rowing ergometer, which he tolerated without pain. The patient iced the surgical site after any exercise and continued to do so for a period of 4 weeks. He noted improved strength and pain tolerance on a daily basis. At 3 weeks postoperatively, he began running on an AlterG Anti-Gravity Treadmill (AlterG) before resuming full contact training with the team at 7 weeks. By 9 weeks, the patient was symptom free with symmetrical thigh muscle bulk and strength. Follow-up ultrasound demonstrated the resolution of preoperative hemorrhaging and perioperative inflammation. At this juncture, he returned to match play. The patient was able to complete the remainder of the season, playing all 6 remaining matches, including the finals series, injury and pain free. At follow-up 2 years postoperatively, the patient retired from professional Australian football. He retired because of chronic ankle



**Figure 3.** The distal semitendinosus tendon (arrows) separated from the insertion site at the anteromedial tibia.

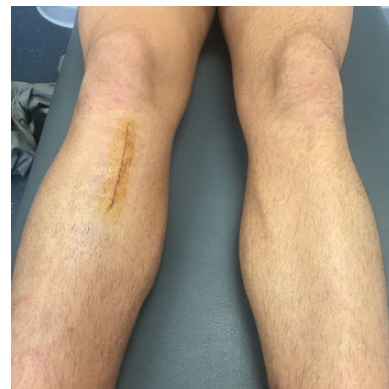


**Figure 4.** The avulsed distal semitendinosus tendon (arrow) being reattached to its periosteal site at the pes anserinus (star).

instability that predated the ST tendon rupture and had no further problems from his distal hamstring injury. He continues to play social basketball and has taken up the sport of ocean swimming. MRI and ultrasound conducted 3 years postoperatively (Figure 6) demonstrated sound attachment of the ST tendon to the anteromedial tibia, with no evidence of inflammation or retraction.

## DISCUSSION

The hamstring muscle complex consists of the biceps femoris, semimembranosus, and ST muscles.<sup>15</sup> The vast majority of hamstring injuries occur in the proximal part of these muscles,<sup>2</sup> and when a distal tendon rupture does occur, it more commonly involves an injury to the biceps femoris.<sup>8</sup> In a longitudinal study of injuries in professional soccer players over 12 seasons, damage to the biceps femoris accounted for 83% of all hamstring injuries, with the semimembranosus and ST accounting for 12% and 5%, respectively.<sup>7</sup> There is limited literature available regarding the management of distal hamstring injuries and less still specifically regarding the distal section of the ST muscle. In

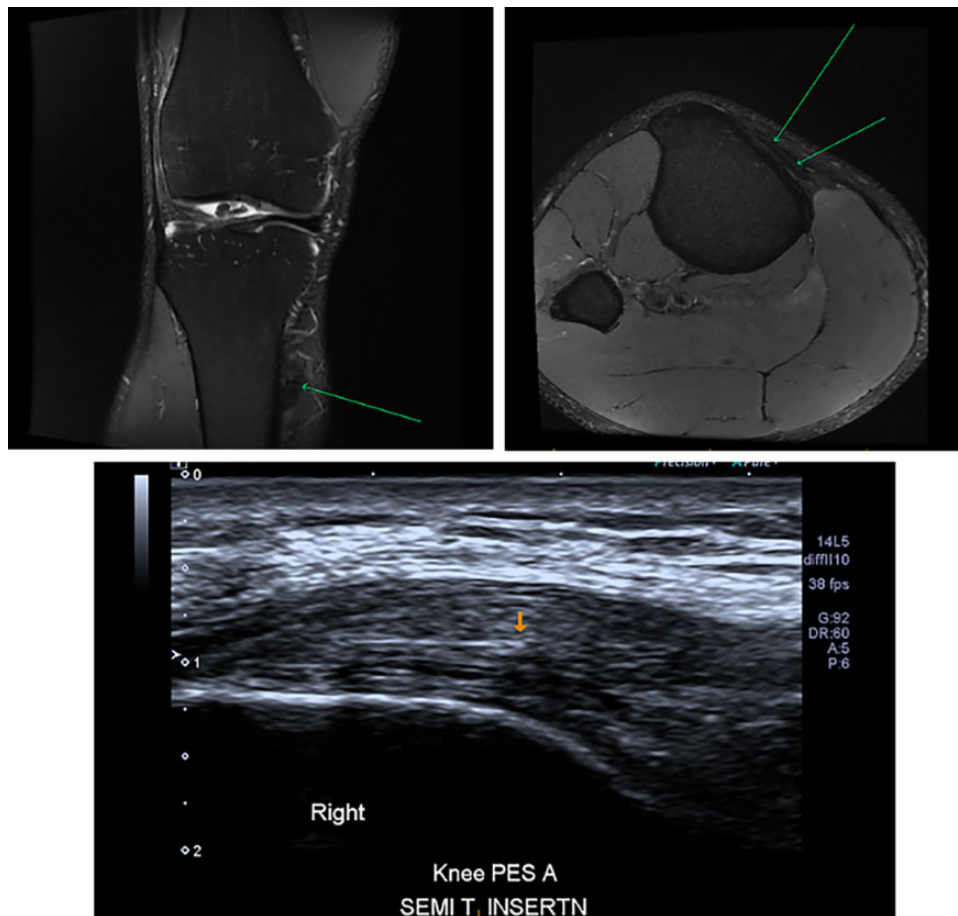


**Figure 5.** Postoperative longitudinal incision centered over the pes anserinus.

the study by Hallén and Ekstrand<sup>7</sup> of elite football (soccer) players in 89 professional teams between 2001 and 2013, hamstring injuries were found to account for 34.3% of all muscle injuries (the most prevalent category). Of that group, in the period from 2007 to 2013, only 2.4% had an injury of the ST muscle, and 0.4% had complete tendon disruption as sustained by the player in this study.<sup>7</sup> The rarity of this injury has led to the paucity of literature published on its management, leading to no clear consensus of opinion.

Within the available literature, there is ongoing debate between conservative (nonoperative) versus operative treatment of distal ST tendon injuries. Cooper and Conway<sup>5</sup> provide the most relevant analysis of this initial management dilemma in their case series of distal ST tendon ruptures in elite-level athletes. Of the 17 athletes who were able to be followed to the completion of rehabilitation and return to play, 5 of the 12 of those who attempted conservative treatment failed and subsequently underwent delayed operative treatment. The remaining 7 players were successfully managed conservatively back to play. All of the athletes who underwent acute surgical management returned to play (n = 5).<sup>5</sup>





**Figure 6.** Postoperative magnetic resonance imaging and ultrasound demonstrating the reattached tendon with some surrounding postoperative change. No other complications were identified.

Within those who advocate for surgical management, there is divided opinion about whether direct repair of the damaged tendon or resection (tenotomy) is the surgical gold standard. Elective tenotomy of the ST tendon is common, as the ST tendon is regularly harvested as the graft of first choice for anterior cruciate ligament (ACL) repair.<sup>8,11</sup> There is literature providing evidence of regeneration of the distal ST tendon after such tenotomy and its use as an ACL graft,<sup>13</sup> with over 85% of those undergoing the procedure demonstrating radiological evidence of regrowth within 33 months postoperatively.<sup>14</sup> However, there are concerns as to ongoing complications that may be sustained as a result of tenotomy of the ST tendon. Konrath et al<sup>8</sup> analyzed 20 patients 2 years after ACL reconstruction employing a distal hamstring graft and noted substantially altered muscle-tendon properties (disturbed anatomy, muscle strength deficits) in the operated limb. Contrary to the above, there are also numerous reports of elite-level athletes returning to professional sport with no or minimal complications.<sup>6</sup> Further investigation needs to be conducted into the different findings published.

All the elite athletes who underwent operative management (acute and delayed) in the case series by Cooper and

Conway<sup>5</sup> case series underwent tenotomy. The authors have only been able to identify 2 case studies of surgical management in distal ST tendon injuries in which tenotomy was not the surgical choice. One study repaired the distal ST tendon using tenodesis to the sartorius.<sup>10</sup> A second study used tenodesis of an avulsed and retracted distal ST tendon to the gracilis.<sup>1</sup> Of note, this second study was published 2 years after the time of our athlete's injury and hence was not considered at the time.

Another consideration that was taken into account for the management of this injury in an elite-level athlete was time until return to play. Distal hamstring injuries have already been shown to have a longer time to return to play than proximal injuries, and those with distal injuries to the musculotendinous junction have the longest delay in the time to return to play compared with other injuries to the hamstring muscles.<sup>13</sup> Cooper and Conway<sup>5</sup> further highlighted that those who undergo conservative management had a delayed return to play compared with those who underwent acute operative management (average time discrepancy, 3.6 weeks). Of note, those who initially underwent conservative management and failed (5/12 of the conservative management group) had a much longer return to competition, with an average time delay of an additional

6.4 weeks.<sup>5</sup> This added “risk” of failed conservative management leading to a longer recovery is a grave concern in a professional athlete.

When direct repair of the avulsed ST tendon to its original attachment site was considered, there were no published cases available for review. A similar study involving an isolated semimembranosus tendon avulsion in a professional 25-year-old football player was analyzed.<sup>3</sup> The player had his tendon directly repaired to the posterior tibial tubercle. He made a good recovery, returning to competition 11 weeks postoperatively. Although not directly relatable, the treating team took particular note of the short recovery time and follow-up muscle strength testing, which revealed only a 2% total work hamstring deficit at 240° per second, indicating the return of functional hamstring output.

The lack of a clear treatment algorithm for this rare injury and the conflicting management approaches make decisions for team physicians very difficult. In this case, the decision to progress with direct operative ST tendon repair was based on 2 key factors: primarily, the most expeditious return to play for the athlete, and secondarily, mitigating the risk of hamstring complications (disturbed anatomy, pain, weakness, and dysfunction) that may have resulted from tenotomy. More rigorous research involving a greater number of patients and longer follow-up time is required to better study the optimal management algorithm for distal ST tendon injuries.

## CONCLUSION

Despite hamstring injuries being very common in professional athletes, a complete distal rupture of the ST tendon is rare. There is therefore limited information to help guide management of this injury. The full recovery and expeditious return to play achieved in this case report suggest that surgical management involving direct repair should be considered in distal ST tendon avulsion injuries.

## ACKNOWLEDGMENT

The authors thank the Sydney Swans Football Club, Mr Kurt Tippett, Mr Matt Cameron, Mr Tim Needham, Mr

Matt McCutcheon, Dr Phil Lucas, and PRP Diagnostic Imaging—Moore Park.

## REFERENCES

1. Ahmed I, Williams M, Murray J. Investigation and management of an isolated complete distal avulsion of semitendinosus. *BMJ Case Rep.* 2018;2018:bcr-2017-222239.
2. Aldebeyan S, Boily M, Martineau PA. Complete tear of the distal hamstring tendons in a professional football player: a case report and review of the literature. *Skeletal Radiol.* 2016;45(3):427-430.
3. Alioto RJ, Browne JE, Barnhouse CD, Scott AR. Complete rupture of the distal semimembranosus complex in a professional athlete. *Clin Orthop Relat Res.* 1997;336:162-165.
4. Cohen SB, Towers JD, Zoga A, et al. Hamstring injuries in professional football players: magnetic resonance imaging correlation with return to play. *Sports Health.* 2011;3(5):423-430.
5. Cooper DE, Conway JE. Distal semitendinosus ruptures in elite-level athletes: low success rates of nonoperative treatment. *Am J Sports Med.* 2010;38(6):1174-1178.
6. Ellman MB, Sherman SL, Forsythe B, LaPrade RF, Cole BJ, Bach BR Jr. Return to play following anterior cruciate ligament reconstruction. *J Am Acad Orthop Surg.* 2015;23(5):283-296.
7. Hallén A, Ekstrand J. Return to play following muscle injuries in professional footballers. *J Sports Sci.* 2014;32(13):1229-1236.
8. Konrath JM, Vertullo CJ, Kennedy BA, Bush HS, Barrett RS, Lloyd DG. Morphologic characteristics and strength of the hamstring muscles remain altered at 2 years after use of a hamstring tendon graft in anterior cruciate ligament reconstruction. *Am J Sports Med.* 2016;44(10):2589-2598.
9. Lempainen L, Banke IJ, Johansson K, et al. Clinical principles in the management of hamstring injuries. *Knee Surg Sports Traumatol Arthrosc.* 2015;23(8):2449-2456.
10. Lempainen L, Sarimo J, Mattila K, Heikkilä J, Orava S. Distal tears of the hamstring muscles: review of the literature and our results of surgical treatment. *Br J Sports Med.* 2007;41(2):80-83.
11. Nakamura N, Horibe S, Sasaki S, et al. Evaluation of active knee flexion and hamstring strength after anterior cruciate ligament reconstruction using hamstring tendons. *Arthroscopy.* 2002;18(6):598-602.
12. Nichols AW. Complications associated with the use of corticosteroids in the treatment of athletic injuries. *Clin J Sport Med.* 2005;15(5):E370.
13. Orchard J, Seward H. Epidemiology of injuries in the Australian Football League, seasons 1997-2000. *Br J Sports Med.* 2002;36(1):39-44.
14. Saw R, Finch CF, Samra D, et al. Injuries in Australian rules football: an overview of injury rates, patterns, and mechanisms across all levels of play. *Sports Health.* 2018;10(3):208-216.
15. Sinnatambay CS. *Last's Anatomy: Regional and Applied.* International ed. London: Elsevier Health Sciences; 2011.