

DATA REPORT

Novel and recurrent *RNF213* variants in Japanese pediatric patients with moyamoya diseaseHiroyuki Akagawa¹, Maki Mukawa², Tadashi Nariai², Shunsuke Nomura^{1,3}, Yasuo Aihara³, Hideaki Onda^{3,4}, Taku Yoneyama⁴, Takumi Kudo², Kazutaka Sumita², Taketoshi Maehara², Takakazu Kawamata³ and Hidetoshi Kasuya⁴

Moyamoya disease is a progressive steno-occlusive condition of the main intracranial arteries that results in the compensatory formation of fragile moyamoya vessels at the base of the brain. *RNF213* is the most significant susceptibility gene and is often found with the p.Arg4810Lys founder variant in East Asian patients. We identified three putatively deleterious variants of this gene from three pediatric patients: two were novel, and one was a recurrent missense variant previously reported in other pediatric patients.

Human Genome Variation (2018) 5, 17060; doi:10.1038/hgv.2017.60; published online 25 January 2018

Moyamoya disease (MMD) is a cerebrovascular disease presenting unique angiographic and clinical features. The nature of this disease is progressive cerebral ischemia due to steno-occlusive lesions around the circle of Willis, which is compensated for by the formation of collateral parenchymal vessels (called 'moyamoya') penetrating toward the base of the brain.¹ Clinical manifestations can vary with the degree of ischemia, ranging from headache to more severe symptoms such as epilepsy, transient ischemic attack, and cerebral infarction. Additionally, a rupture of the fragile moyamoya vessels can also cause intracranial hemorrhage.² Epidemiological and genetic studies have demonstrated that MMD is a multifactorial disease. The recurrence rates in relatives were markedly lower than that expected from simple Mendelian inheritance.³ Likewise, the Japanese p.Arg4810Lys founder variant (c.14429G>A, rs112735431) in *RNF213* showed markedly reduced penetrance despite its extremely high effect size (217.0, additive model).⁴ We previously demonstrated allelic heterogeneity of *RNF213* in the susceptibility to MMD, and the other susceptibility variants found in pedigrees with MMD also showed reduced penetrance. It is thought that the susceptibility variants of *RNF213* require additional environmental or genetic factors for the development of MMD.^{4,5}

In the present study, we analyzed three Japanese pediatric patients showing typical radiological and clinical features of MMD, although they were confirmed to be negative for the p.Arg4810Lys founder variant of *RNF213*.

The first patient was a 12-year-old boy. He presented with transient motor weakness of the right upper extremity while eating hot noodles at 11 years of age. Conventional angiography revealed bilateral steno-occlusive changes at the terminal portions of the internal carotid arteries (ICAs) with moyamoya vascular networks. Bilateral superficial temporal artery to middle cerebral artery anastomoses were performed and resulted in a good postoperative outcome (Figure 1a–c).

The second patient was a 5-year-old boy. He suffered bilateral cerebral infarctions at the age of one (Figure 1d). Magnetic resonance angiography (MRA) demonstrated that

bilateral steno-occlusive changes at the ICA terminals were more prominent on the right side with an early moyamoya vessel formation (Figure 1e). Four years after a right-side encephaloduro-arterio-synangiosis (EDAS), the stage of the ipsilateral lesion progressed with distinct moyamoya vessel formation, although the contralateral lesion at the ICA terminal improved (Figure 1f). Multiple stenoses further developed not only in the proximal intracranial arteries (Figure 1f), but also in the descending aorta involving the left renal artery (Figure 1g). Such extracranial vascular involvement has often been reported in MMD patients.^{6,7}

The third case was a monozygotic twin brother. He was asymptomatic; however, he was diagnosed with MMD after his twin brother died of intraventricular hemorrhage due to MMD at 11 years of age. MRA demonstrated that the right ICA terminal was steno-occlusive with a moyamoya vascular network (Figure 1h). A right side EDAS was performed to prevent stroke. However, he developed an intracerebral hemorrhage at the right frontal lobe years after the surgery (Figure 1i).

These three patients had no familial history of MMD, except for the deceased monozygotic twin brother of the third patient, and none had an underlying disease reported to complicate MMD. Radiological findings met the diagnostic criteria established by the Research Committee on Moyamoya Disease of the Ministry of Health, Labour, and Welfare, Japan,⁸ which were revised to include patients with both bilateral and unilateral lesions in 2015.² They were not included in our previous genetic study of MMD in which resequencing analysis of *RNF213* was performed.⁴ The genetic analysis of MMD patients was approved by the ethics committees of Tokyo Women's Medical University and Tokyo Medical and Dental University. After obtaining written informed consent, genomic DNA was extracted from their peripheral blood samples. Polymerase chain reaction-based direct Sanger sequencing was performed on all coding exons of *RNF213* (NM_001256071.1), as previously described,⁴ and the p.Arg4810Lys variant was confirmed to be negative in the three patients. From this analysis, one of three rare heterozygous, nonsynonymous variants of *RNF213* was detected in each of the three patients: p.(Glu996Lys) (c.2986G>A),

¹Tokyo Women's Medical University Institute for Integrated Medical Sciences (TIIMS), Tokyo, Japan; ²Department of Neurosurgery, Tokyo Medical and Dental University, Tokyo, Japan; ³Department of Neurosurgery, Tokyo Women's Medical University, Tokyo, Japan and ⁴Department of Neurosurgery, Tokyo Women's Medical University Medical Center East, Tokyo, Japan.

Correspondence: Dr H Akagawa (akagawa.hiroyuki@twmu.ac.jp)

Received 16 September 2017; revised 6 November 2017; accepted 23 November 2017

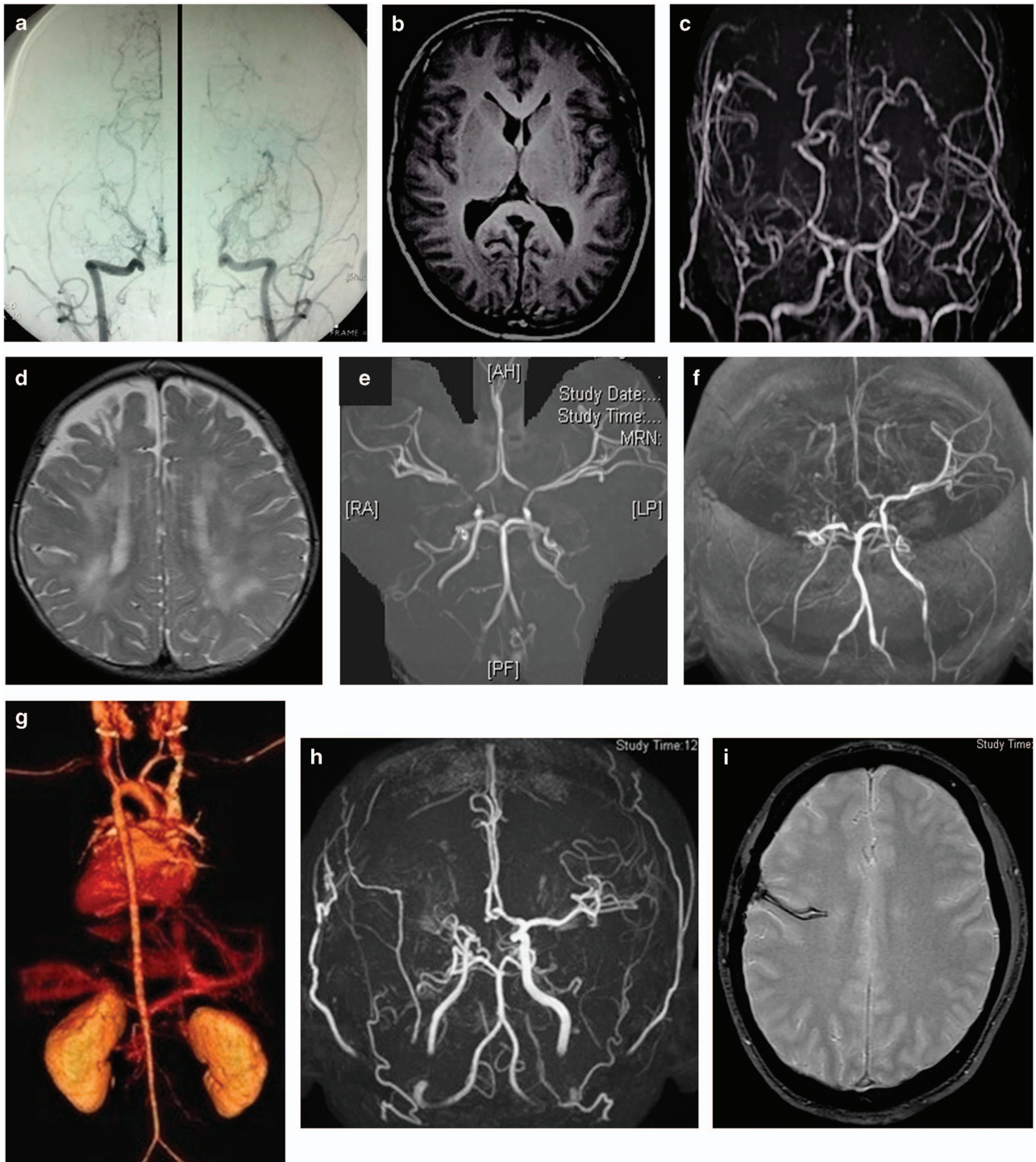


Figure 1. Radiological studies of the patients. Conventional angiography of the first patient shows bilateral stenocclusive changes of the ICAs with moyamoya vascular networks (a), which are also indicated by low-signal-intensity flow voids in the bilateral basal ganglia in T1-weighted magnetic resonance imaging (MRI) (b). Post-operative magnetic resonance angiography (MRA) shows bilateral bypasses between the superficial temporal arteries and the middle cerebral arteries (c). T2-weighted MRI of the second patient shows bilateral cerebral infarctions (d). MRA shows bilateral stenosis of the ICA terminals, which is more severe on the right side (e). MRA 4 years after surgery shows stenoses in the right vertebral artery and the proximal portion of the left ICA, in addition to the disease progression on the right side (f). Three-dimensional-computed tomography angiography (3D-CTA) shows diffuse stenosis along the descending aorta involving the left renal artery (g). MRA shows a stenocclusive change at the right ICA terminal with moyamoya vascular networks (h). T2*-weighted MRI of the third patient shows a low-signal-intensity hemorrhagic scar in the right frontal lobe (i).

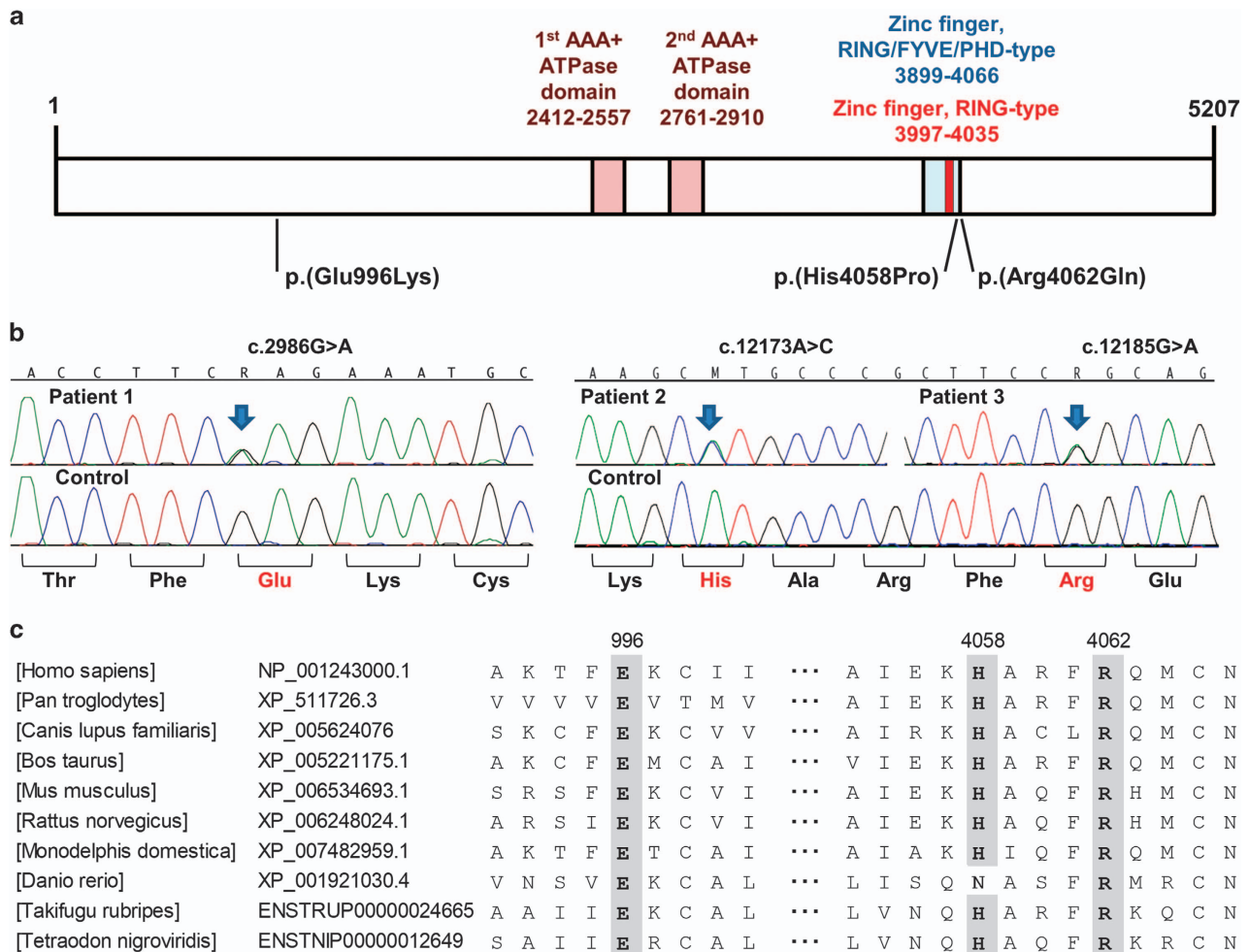


Figure 2. (a) Protein structure of RNF213, based on Q63HN8 (RN213_HUMAN) in the InterPro (<http://www.ebi.ac.uk/interpro/>) database. (b) DNA sequence chromatograms of the three heterozygous missense variants detected in the present study. (c) Multiple alignment of the amino-acid sequences of RNF213 from different species, using ClustalW version 2.1 (<ftp://ftp.ebi.ac.uk/pub/software/clustalw2/2.1/>). RefSeq (<https://www.ncbi.nlm.nih.gov/refseq/>) or Ensembl (<http://www.ensembl.org/index.html>) protein identification was shown for each RNF213 homolog. AAA, ATPases associated with diverse cellular activities; RING, really interesting new gene; FYVE, the acronym for the four cysteine-rich proteins: Fab1, YOTB, Vac1, and EEA1; PHD, plant homeodomain.

p.(His4058Pro) (c.12173A>C) and p.(Arg4062Gln) (c.12185G>A) (Figure 2a, b). They were not listed in the Exome Aggregation Consortium (<http://exac.broadinstitute.org/>) version 0.3.1 data set,⁹ the NCBI dbSNP147 (<http://www.ncbi.nlm.nih.gov/snp>) or the Human Genetic Variation Database (<http://www.hgvd.genome.med.kyoto-u.ac.jp/>).¹⁰ Their HumDiv and HumVar statuses of PolyPhen-2¹¹ were consistently deleterious according to wANNOVAR (<http://wannovar.wglab.org/>),¹² reflecting the substitutions at the evolutionarily conserved amino-acid residues (Figure 2c).¹³ Two of the three variants, p.(His4058Pro) and p.(Arg4062Gln), were regarded as highly deleterious because their C-scores (23.2 and 19.05, respectively) from Combined Annotation Dependent Depletion (<http://cadd.gs.washington.edu/>)¹⁴ version 1.0 were more than 14.67, which was the robust cutoff for MMD susceptibility variants other than p.R4810K, which was defined in our previous study.⁴ The p.(Glu996Lys) variant in the first patient had a higher C-score (8.1) than the p.Arg4810Lys founder variant (6.746). Furthermore, this variant was consistently judged as deleterious even in other commonly used functional predictions such as SIFT¹⁵ and LRT,¹⁶ both of which categorized p.(His4058Pro) as tolerated. To the best of our knowledge, the p.(Glu996Lys) and p.(His4058Pro) variants have not been reported earlier in literature. The p.(Arg4062Gln) variant has been reported in another Japanese MMD pedigree with two

childhood-onset patients sharing this same variant.⁴ This p.(Arg4062Gln) variant has also been reported in a European MMD patient.¹³

RNF213 encodes a 591-kDa protein that acts both as an AAA-type ATPase and an E3 ubiquitin ligase via two AAA+ modules and a RING finger domain, respectively.¹⁷ Several studies demonstrated that *RNF213* was also associated with systolic blood pressure,¹⁸ intracranial aneurysms¹⁹ and coronary artery disease,²⁰ suggesting that this molecule may play an important role in vascular construction. In fact, recent studies revealed its cooperative functions in angiogenic signaling pathways, such as Akt and Wnt signaling pathways, in vascular endothelial cells.^{17,21,22} However, the detailed biochemical functions of this molecule still remain largely unknown. The two highly deleterious variants of the three we studied, the p.(His4058Pro) and p.(Arg4062Gln) variants, were located within the RING/FYVE/PHD-type zinc finger domain according to the InterPro (<http://www.ebi.ac.uk/interpro/>) database (Figure 2a). Therefore, these two variants may affect the nucleotide-binding, protein-binding or E3 ubiquitin ligase activities of this domain, and are high-priority candidates for future functional analysis to elucidate the pathological role of the susceptibility variants of *RNF213*. Furthermore, it is important to accumulate improved knowledge about the variously reported

RNF213 variants in MMD patients because there is little information on genotype–phenotype correlation.

HGV DATABASE

The relevant data from this Data Report are hosted at the Human Genome Variation Database at <http://dx.doi.org/10.6084/m9.figshare.hgv.1747>; <http://dx.doi.org/10.6084/m9.figshare.hgv.1750>; <http://dx.doi.org/10.6084/m9.figshare.hgv.1753>.

ACKNOWLEDGEMENTS

We thank the patients and their families for making this study possible. We also thank the Exome Aggregation Consortium and the groups that provided exome variant data for comparison. A full list of contributing groups can be found at <http://exac.broadinstitute.org/about>. This work was supported by JSPS KAKENHI Grant Numbers 16K10740 (HA), 17K16629 (MM) and the Japan Intractable Diseases Research Foundation (MM).

COMPETING INTERESTS

The authors declare no conflict of interest.

PUBLISHER'S NOTE

Springer Nature remains neutral with regard to jurisdictional claims in published maps and institutional affiliations.

REFERENCES

- 1 Tarasów E, Kulakowska A, Lukasiewicz A, Kapica-Topczewska K, Korneluk-Sadzyńska A, Brzozowska J et al. Moyamoya disease: diagnostic imaging. *Pol J Radiol* 2011; **76**: 73–79.
- 2 Kim JS. Moyamoya disease: epidemiology, clinical features, and diagnosis. *J Stroke* 2016; **18**: 2–11.
- 3 Fukuyama Y, Kanai N, Osawa M. Clinical genetic analysis on the moyamoya disease. In: Yonekawa Y (ed). *The Research Committee on Spontaneous Occlusion of the Circle of Willis (Moyamoya Disease) of the Ministry of Health and Welfare Japan: Annual Report 1992*. Ministry of Health and Welfare Japan: Tokyo, Japan, 1992, pp 141–146.
- 4 Moteki Y, Onda H, Kasuya H, Yoneyama T, Okada Y, Hirota K et al. Systematic validation of *RNF213* coding variants in Japanese patients with moyamoya disease. *J Am Heart Assoc* 2015; **4**: e001862.
- 5 Mukawa M, Nariyai T, Onda H, Yoneyama T, Aihara Y, Hirota K et al. Exome sequencing identified *CCER2* as a novel candidate gene for moyamoya disease. *J Stroke Cerebrovasc Dis* 2017; **26**: 150–161.
- 6 Yamada I, Himeno Y, Matsushima Y, Shibuya H. Renal artery lesions in patients with moyamoya disease: angiographic findings. *Stroke* 2000; **31**: 733–737.
- 7 Cecchi AC, Guo D, Ren Z, Flynn K, Santos-Cortez RL, Leal SM et al. *RNF213* rare variants in an ethnically diverse population with moyamoya disease. *Stroke* 2014; **45**: 3200–3207.
- 8 Research Committee on the Pathology and Treatment of Spontaneous Occlusion of the Circle of Willis Health Labour Sciences Research Grant for Research on

- Measures for Intractable Diseases. Guidelines for diagnosis and treatment of moyamoya disease (spontaneous occlusion of the circle of Willis). *Neurol Med Chir* 2012; **52**: 245–266.
- 9 Lek M, Karczewski KJ, Minikel EV, Samocha KE, Banks E, Fennell T et al. Analysis of protein-coding genetic variation in 60,706 humans. *Nature* 2016; **536**: 285–291.
- 10 Higasa K, Miyake N, Yoshimura J, Okamura K, Niihori T, Saitsu H et al. Human genetic variation database, a reference database of genetic variations in the Japanese population. *J Hum Genet* 2016; **61**: 547–553.
- 11 Adzhubei IA, Schmidt S, Peshkin L, Ramensky VE, Gerasimova A, Bork P et al. A method and server for predicting damaging missense mutations. *Nat Methods* 2010; **7**: 248–249.
- 12 Yang H, Wang K. Genomic variant annotation and prioritization with ANNOVAR and wANNOVAR. *Nat Protoc* 2015; **10**: 1556–1566.
- 13 Liu W, Morito D, Takashima S, Mineharu Y, Kobayashi H, Hitomi T et al. Identification of *RNF213* as a susceptibility gene for moyamoya disease and its possible role in vascular development. *PLoS ONE* 2011; **6**: e22542.
- 14 Kircher M, Witten DM, Jain P, O’Roak BJ, Cooper GM, Shendure J. A general framework for estimating the relative pathogenicity of human genetic variants. *Nat Genet* 2014; **46**: 310–315.
- 15 Kumar P, Henikoff S, Ng PC. Predicting the effects of coding non-synonymous variants on protein function using the SIFT algorithm. *Nat Protoc* 2009; **4**: 1073–1081.
- 16 Chun S, Fay JC. Identification of deleterious mutations within three human genomes. *Genome Res* 2009; **19**: 1553–1561.
- 17 Koizumi A, Kobayashi H, Hitomi T, Harada KH, Habu T, Youssefian S. A new horizon of moyamoya disease and associated health risks explored through *RNF213*. *Environ Health Prev Med* 2016; **21**: 55–70.
- 18 Koizumi A, Kobayashi H, Liu W, Fujii Y, Senevirathna ST, Nanayakkara S et al. P. R4810K, a polymorphism of *RNF213*, the susceptibility gene for moyamoya disease, is associated with blood pressure. *Environ Health Prev Med* 2013; **18**: 121–219.
- 19 Zhou S, Ambalavanan A, Rochefort D, Xie P, Bourassa CV, Hince P et al. *RNF213* is associated with intracranial aneurysms in the French-Canadian population. *Am J Hum Genet* 2016; **99**: 1072–1085.
- 20 Morimoto T, Mineharu Y, Ono K, Nakatochi M, Ichihara S, Kabata R et al. Significant association of *RNF213* p.R4810K, a moyamoya susceptibility variant, with coronary artery disease. *PLoS ONE* 2017; **12**: e0175649.
- 21 Ohkubo K, Sakai Y, Inoue H, Akamine S, Ishizaki Y, Matsushita Y et al. Moyamoya disease susceptibility gene *RNF213* links inflammatory and angiogenic signals in endothelial cells. *Sci Rep* 2015; **5**: 13191.
- 22 Scholz B, Korn C, Wojtarowicz J, Mogler C, Augustin I, Boutros M et al. Endothelial RSPO3 controls vascular stability and pruning through non-canonical WNT/Ca(2+)/NFAT signaling. *Dev Cell* 2016; **36**: 79–93.



This work is licensed under a Creative Commons Attribution-NonCommercial-ShareAlike 4.0 International License. The images or other third party material in this article are included in the article’s Creative Commons license, unless indicated otherwise in the credit line; if the material is not included under the Creative Commons license, users will need to obtain permission from the license holder to reproduce the material. To view a copy of this license, visit <http://creativecommons.org/licenses/by-nc-sa/4.0/>

© The Author(s) 2018