

Contents lists available at [ScienceDirect](https://www.sciencedirect.com)

International Journal of Surgery Case Reports

journal homepage: www.casereports.com

Extended thymectomy via subxiphoid uniportal Video-Assisted Thoracoscopic Surgery: A case report

Ivan Joalsen^{a,*}, David Christian^a, Amy Rosalie^b, Made Angga^b

^a Division of Thoracic, Cardiac and Vascular Surgery, Mulawarman University-Abdul Wahab Sjahranie Hospital Samarinda, East Borneo, Indonesia

^b Intern Doctor of Thoracic, Cardiac and Vascular Surgery, Abdul Wahab Sjahranie Hospital Samarinda, East Borneo, Indonesia

ARTICLE INFO

Article history:

Received 1 February 2021

Received in revised form 16 February 2021

Accepted 17 February 2021

Available online 22 February 2021

Keywords:

Juvenile myasthenia gravis

Thymectomy

Video-Assisted Thoracoscopic Surgery

Case report

ABSTRACT

INTRODUCTION AND IMPORTANCE: Myasthenia gravis (MG) is a well-known disease in adults, but the prevalence in children population is low. One treatment option is thymectomy. Transsternal procedure have been the primary approach, but recent trends lean toward minimally invasive technique with triportal and, recently, uniportal thoracoscopic method. This is related to the suggested less blood loss and hospital length of stay.

CASE PRESENTATION: Hereby we report a case of a 4-year-old boy suffering from Juvenile Myasthenia Gravis (JMG) with thymic hyperplasia who underwent extended thymectomy via subxiphoid uniportal Video-Assisted Thoracoscopic Surgery (VATS) in our hospital. Pathology evaluation reported a case of thymic hyperplasia. The postoperative outcome was uneventful and satisfactory.

CLINICAL DISCUSSION: Subxiphoid uniportal approach for thymectomy is relatively new and has not been widely reported. It is important to highlight its advantages and disadvantages compared to other means for thymectomy.

CONCLUSION: Subxiphoid uniportal VATS is a safe and feasible approach for thymectomy.

© 2021 Published by Elsevier Ltd on behalf of IJS Publishing Group Ltd. This is an open access article under the CC BY-NC-ND license (<http://creativecommons.org/licenses/by-nc-nd/4.0/>).

1. Introduction

Myasthenia gravis (MG) is an autoimmune disorder in which antibodies are directed against acetylcholine receptors (AChR) in the neuromuscular junction. The loss of functional receptors results in fluctuating muscle weakness and paralysis during muscle contraction. Where present before the age of 18 years, this is referred to as juvenile myasthenia gravis (JMG). Available data regarding its prevalence is limited given its rarer incidence compared to the adult population. Madenci et al. [1] approximated 0.9–2.2 cases per million person-years, although this number is further influenced by demographical and racial factors.

Treatment options to date follow those of adult MG, including thymectomy. Thymectomy offers improved chance of remission in the adult literature and suggested to have similar effect in JMG. The surgical approach is either transcervical, transsternal, or video-scopic (Video-Assisted Thoracoscopic Surgery/VATS or robotic). One method for VATS is by subxiphoid approach. Hereby we report a case of extended thymectomy in non-thymomatous JMG via sub-

xiphoid uniportal VATS. This case report has been reported in line with the SCARE 2020 Criteria [2].

2. Presentation of case

A 4-year-old Asian boy was referred from a pediatrician due to ptosis, recurrent fatigue, and dyspnea during activity. Past illness history includes respiratory tract infection at the age of 1-year-old. No other family members have had similar complaints. The acetylcholinesterase test was positive, further evaluation with EMG showed functional decrement in the compound motor action potential. CT scan revealed a 3.1 × 1 cm anterior mediastinal mass (Fig. 1A).

The patient was diagnosed with JMG and admitted for extended thymectomy via subxiphoid uniportal VATS. The patient was positioned supine with a roll placed under the shoulder to maximize chest extension. A single-lumen endotracheal tube was inserted to perform bilateral lung ventilation with reduced tidal volume. The surgery was performed by a board-certified thoracic, cardiac, and vascular senior consultant surgeon in a district general hospital. A longitudinal 3 cm subxiphoid incision was made, the xiphoid process was left in place. The underlying tissue was separated by blunt finger dissection to create retrosternal tunnel and a wound protector was inserted. To further optimize exposure, an assistant elevates the superior side of the subxiphoid process. Obstructing anterior mediastinal adipose tissue was removed with harmonic scalpel. A

* Corresponding author at: Division of Thoracic, Cardiac and Vascular Surgery, Mulawarman University-Abdul Wahab Sjahranie Hospital Samarinda, East Borneo, 75123, Indonesia.

E-mail address: aesculap99@gmail.com (I. Joalsen).

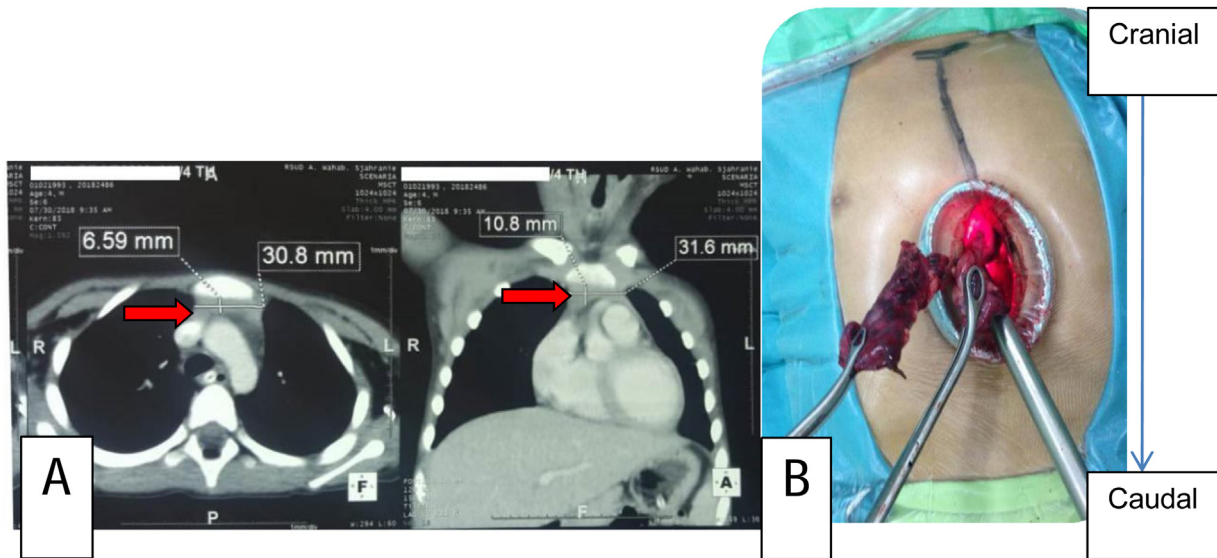


Fig. 1. (A) Chest CT Scan showed a 1 × 3.1 cm mass in the anterior mediastinal segment; (B) Thymus gland removal via subxiphoid uniportal VATS. CT, Computed Tomography; VATS, Video-Assisted Thoracoscopic Surgery.

10 mm 30° angle thoracoscope (Karl Storz, Tuttlingen, Germany) was used. The pericardial and epiphrenic fat pads on both sides were dissected, both pleural cavities were also opened. The right lobe of the thymus along with mediastinal fat tissues were then identified and dissected from the pericardium and ascending aorta. Careful dissection allowed visualization of the innominate vein and superior vena cava. The right superior thymic horn was dissected and pulled left to separate the gland from the underlying innominate vein. The thymic veins draining to the innominate vein were identified and divided with harmonic scalpel. The adipose tissue on the aortopulmonary window was also removed to complete the dissection of the left thymic horn. Finally, the freed thymus gland and its surrounding fat tissue were brought out through the subxiphoid incision (Fig. 1B). A 20 Fr chest drain was inserted into each pleural cavity. Normal ventilation was resumed and the wound closed around the drains. This procedure took 1.5 h and recorded blood loss of 50 mL.

The patient was then transferred to the intensive care unit (ICU) for observation and was successfully extubated within 24 h postoperatively. Mestinon was administered immediately after surgery. The patient stayed in the ICU for 2 days. No instances of phrenic nerve palsy were found. Histopathologic findings of the dissected tissue exhibited thymic hyperplasia (Fig. 2A–B).

3. Discussion

Myasthenia gravis (MG) in children have similar pathogenesis to adult-onset myasthenias. The management principles are to increase the amount of functional acetylcholine, modulate immune response, or lessen the amount of abnormal antibodies. These can be achieved by either acetylcholinesterase inhibitors, immunomodulatory agents, surgical immunomodulatory procedure, or a combination of these approaches [3]. In children, several considerations need to be made due to the potentially debilitating adverse effects of immunosuppressive agents, such as decreased growth velocity and immunocompromised state [4].

In adults, thymectomized MG patients have better chance of remission and reduced need of medications, thus minimizing its complications. Children population has less robust data, but multiple retrospective analyses have shown promising benefit of thymectomy [4]. Wagner et al. [5] stated thymectomy in JMG offers remission rate between 29% and 68% within 3 years. Studies sug-

gest that thymectomy offers higher chance of remission if done within the first year after onset [3,4]. Multiple retrospective studies including Liew and Kang [3] stated that thymectomy in JMG does not appear to impair the development of immunological function. Transsternal approach had been the traditional method for years. Currently, minimally invasive extended thymectomy is the primary surgical technique for MG [6].

Thoracoscopic approach is increasingly preferred due to its superiority in terms of intraoperative blood loss and hospital length of stay compared to open thymectomy [7]. This method also offers the benefit of earlier chest drain removal, reduced analgetics use, and better cosmesis [4,8]. Triportal right-sided approach is the most widely adopted technique [6]. However, this technique is arduous when the lesion is extensive to the left side. Visualization of the left phrenic nerve might also be tougher. In addition, patients still frequently suffer from postoperative intercostal pain. This can be overcome by an even less invasive technique, uniportal VATS. Uniportal incision minimizes physiological insult to the patient, while subxiphoid incision allows preservation of intercostal neurovascular structures, eliminating postoperative intercostal neuralgia and chronic thoracotomy pain [9]. It also allows clear visualization of the anterior mediastinum and both phrenic nerves [6,8], which enables the surgeon to safely perform radical resection, maximizing the oncological outcome. Friedant et al. [7] in their analysis on thymic malignancy patients also confirms the ability for complete resection. A reasonable drawback with this technique, however, is limited instrument manoeuvrability. In the case of malignancy, this might risk disrupting the tumor capsule. Specially modified instruments and angled thoracoscope might aid in this matter [8].

4. Conclusion

Both open and minimally invasive approach are safe for thymectomy. Neither is superior in terms of surgery time and remission rates [4,7]. However, subxiphoid uniportal VATS provides significant benefit in terms of less blood loss, shorter hospital stay, less postoperative pain, and cosmesis. Subxiphoid uniportal approach is safe and feasible for well-selected patients. An analysis attempt to identify factors that would deem a patient eligible for subxiphoid uniportal thymectomy remains inconclusive [7], but those with poor respiratory function and cardiac arrhythmias are generally advised against this method.⁸ This report adds further to

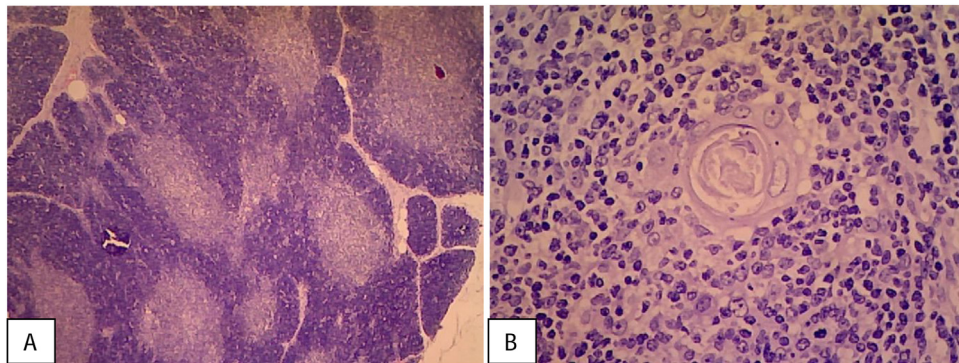


Fig. 2. (A) Lymphoid follicles in the thymus (H&E staining, 10x magnification); (B) High power view showing a Hassall corpuscle (H&E staining, 40x magnification). *H&E, hematoxylin and eosin.*

the evidence that subxiphoid uniportal VATS is a safe and feasible approach to perform extended thymectomy.

Declaration of Competing Interest

The authors report no declarations of interest.

Sources of funding

This research did not receive any specific grant from funding agencies in the public, commercial, or not-for-profit sectors.

Ethical approval

This study has been exempted by our institution.

Consent

Written informed consent was obtained from the patient for publication of this case report and accompanying images. A copy of the written consent is available for review by the Editor-in-Chief of this journal on request.

Author contribution

Ivan Joalsen, MD: conceptualization, data curation, supervision.
David Christian, MD: conceptualization, data curation, supervision.

Amy Rosalie, MD: study design, writing – original draft, review & editing.

Made Angga, MD: study design, writing – original draft, review & editing.

Registration of research studies

Not applicable.

Guarantor

Ivan Joalsen, MD. Division of Thoracic, Cardiac and Vascular Surgery, Mulawarman University – Abdul Wahab Sjahranie Hospital Samarinda, East Borneo, Indonesia.

Provenance and peer review

Not commissioned, externally peer-reviewed.

References

- [1] A.L. Madenci, G.Z. Li, B.R. Weil, D. Zurakowski, P.B. Kang, C.B. Weldon, The role of thymectomy in the treatment of juvenile myasthenia gravis: a systematic review, *Pediatr. Surg. Int.* 33 (2017) 683–694, <http://dx.doi.org/10.1007/s00383-017-4086-3>.
- [2] R.A. Agha, T. Franchi, C. Sohrabi, G. Mathew, for the SCARE Group, The SCARE 2020 guideline: updating consensus Surgical CAse REport (SCARE) guidelines, *Int. J. Surg.* 84 (2020) 226–230.
- [3] W.K.M. Liew, P.B. Kang, Update on juvenile myasthenia gravis, *Curr. Opin. Pediatr.* 25 (2013) 694–700, <http://dx.doi.org/10.1097/MOP.0b013e328365ad16>.
- [4] A.G. Kim, S.A. Upah, J.F. Brandsema, S.W. Yum, T.A. Blinman, Thoracoscopic thymectomy for juvenile myasthenia gravis, *Pediatr. Surg. Int.* 35 (2019) 603–610, <http://dx.doi.org/10.1007/s00383-019-04441-0>.
- [5] A.J. Wagner, R.A. Cortes, J. Strober, E.J. Grethel, M.S. Clifton, M.R. Harrison, D.L. Farmer, K.K. Nobuhara, H. Lee, Long-term follow-up after thymectomy for myasthenia gravis: thoracoscopic vs open, *J. Pediatr. Surg.* 41 (2006) 50–54, <http://dx.doi.org/10.1016/j.jpedsurg.2005.10.006>.
- [6] H.F. Batirel, Minimally invasive techniques in thymic surgery: a worldwide perspective, *J. Vis. Surg.* 4 (2018), <http://dx.doi.org/10.21037/jovs.2017.12.18>, 7–7.
- [7] A.J. Friedant, E.A. Handorf, S. Su, W.J. Scott, Minimally invasive versus open thymectomy for thymic malignancies: systematic review and meta-analysis, *J. Thorac. Oncol.* 11 (2016) 30–38, <http://dx.doi.org/10.1016/j.jtho.2015.08.004>.
- [8] H. Weaver, J.M. Ali, L. Jiang, C. Yang, L. Wu, G. Jiang, G. Aresu, Uniportal subxiphoid video-assisted thoracoscopic approach for thymectomy: a case series, *J. Vis. Surg.* 3 (2017), <http://dx.doi.org/10.21037/jovs.2017.10.16>, 169–169.
- [9] P.S.Y. Yu, C.S.H. Ng, Recent developments in uniportal VATS in Asia and beyond, *J. Vis. Surg.* 4 (2018), <http://dx.doi.org/10.21037/jovs.2018.08.10>, 184–184.

Open Access

This article is published Open Access at [sciencedirect.com](https://www.sciencedirect.com). It is distributed under the [IJSCR Supplemental terms and conditions](#), which permits unrestricted non commercial use, distribution, and reproduction in any medium, provided the original authors and source are credited.