



Wire fracture in postoperative Nuss procedure: a problem that cannot be ignored

Yunxuan Zhang^{1#}, Qiang Chen^{2#}, Yarui Luo², Chenyu Sun³, Meng Chen², Na Wu², Yimin Xie²

¹Department of Burn and Plastic Surgery, Children's Hospital of Chongqing Medical University, Chongqing, China; ²Department of pediatrics, Chongqing University Three Gorges Hospital, Chongqing, China; ³AMITA Health Saini Joseph Hospital Chicago, Chicago, IL, USA

Contributions: (I) Conception and design: Y Xie, Q Chen, Y Zhang; (II) Administrative support: N Wu, Y Xie; (III) Provision of study materials or patients: Y Luo, C Sun; (IV) Collection and assembly of data: Y Zhang, Q Chen, Y Luo; (V) Data analysis and interpretation: Y Zhang, Q Chen; (VI) Manuscript writing: All authors; (VII) Final approval of manuscript: All authors.

[#]These authors contributed equally to this work.

Correspondence to: Yimin Xie. Department of Pediatric Surgery, Chongqing University Three Gorges Hospital, Chongqing 404000, China. Email: cqwzchenqiang@163.com.

Background: Surgical stainless wire has been widely used to stabilize pectus bar and ribs in Nuss procedure for pectus excavatum correction. However, wire fracture and its secondary complications are problems easily to be ignored but very important. The purpose of this article was to describe a series of cases with wire breakage, hoping to arouse the attention of worldwide thoracic surgeons to this potential threat, and to share our modifications on the fixation patterns and materials in Nuss procedure.

Methods: From September 2011 to January 2020, 44 patients underwent Nuss procedure at Chongqing University Three Gorges Hospital. In the initial 25 patients (Group A), each bar was secured by stainless wires, and the latter 19 patients (Group B) received stainless wires and polyblend polyethylene sutures (PDS) in the bar fixation. Patient demographics, Haller index (HI), wire fracture rate, characteristics of the broken wires, and operation time were recorded.

Results: The mean operation age was 8.1 ± 4.3 years in group A and 10.4 ± 2.9 years in group B. There was no statistical difference in HIs between the two groups ($P>0.05$). The wire fracture occurred in 88.0% of the patients in Group A, while the wires in Group B were all intact. There was no bar displacement or other serious complication requiring surgical intervention in the two groups. The mean operation time of bar removal when encountering wire fracture was 104.6 ± 42.8 minutes, which was significantly higher than that in Group B ($P\leq 0.001$).

Conclusions: The wire fracture in the bar fixation could pose potential hazards to patients deserving special attention from thoracic surgeons. Cancel the wire fixation in the non-stabilizer side while simultaneously using wires and PDS in the pectus bar fixation may achieve the pectus bar stability while overcoming the problem of wire fracture.

Keywords: Nuss procedure; wire fracture; complications; polyblend polyethylene sutures (PDS); pectus excavation

Submitted Oct 29, 2020. Accepted for publication Feb 05, 2021.

doi: 10.21037/tp-20-354

View this article at: <http://dx.doi.org/10.21037/tp-20-354>

Introduction

The Nuss procedure (1), first reported in 1998, is currently the standard method for surgical management of pectus excavatum in pediatrics. While, with surgeons constantly involved with such procedures, different types of complications were reported especially pectus bar displacement. Several techniques have been applied in the fixation of pectus bar in Nuss procedure, of which surgical stainless wire fixation was mostly accepted by surgeons due to its strong resistance and endurance. However, there were some complications related to the fracture of the implanted wire, including pneumothorax (2,3), hemopneumothorax, and the increased difficulty in the bar removal procedure (4). Although this has raised concerns (5), details of the wire fracture in the Nuss procedure have not been expounded profoundly, leading to unawareness of the potential complications and harms posed by the broken wire among surgeons.

Here, we reported on a series of patients with wire fracture in postoperative Nuss procedure and details of wire fracture were described in detail. Another group of patients receiving our modified fixation techniques were also included for comparison. Furthermore, a brief literature review of fixation techniques in Nuss procedure was conducted to further explore the necessity of the stainless wire. The purpose of this article was to arouse the worldwide attention of thoracic surgeons to the potential hazard of wire fracture in Nuss procedure, and to share our modifications of its fixation techniques. We present the following article in accordance with the STROBE reporting checklist (available at <http://dx.doi.org/10.21037/tp-20-354>).

Methods

Study design and patients

This study is a retrospective, observational, single-center study. Patients from Chongqing University Three Gorges Hospital between September 2011 to January 2020 were included in this study. The study was conducted in accordance with the Declaration of Helsinki (as revised in 2013) and individual consent for this retrospective analysis was waived. Ethics approval was granted by ethics board of Chongqing University Three Gorges Hospital (NO.: cstc2020jscx-kjfp0005). All methods were performed in accordance with the relevant guidelines and regulations.

Data collection

All data were extracted from electronic medical records, including demographics, illness conditions, surgery performed, follow-up results. Broken wire characteristics, as the main research objective, were also documented and used for this study. Missing data or potentially inaccurate data provided by patients were not included in the calculation.

Diagnostic criteria

(I) Chest imaging reveals a Haller index (HI) greater than 3.25 with symmetric (“Park I”) pectus excavatum (6), and (II) with or without respiratory and circulatory symptoms.

Surgical technique

All patients were under general anesthesia. For the 25 patients in Group A, from 2011–2015, incisions were made between the anterior axillary line and midaxillary line in bilateral sides. A stabilizer was implanted around the incision on one side of the chest wall. An introducer was inserted, through the left to the right incision to create a tunnel between the sternum and the pericardium, without thoracoscopic guidance. Then, the prepared bent bar was tied to the introducer and passed through the right incision and pulled back from the previous tunnel. After adjusting in the position, the bar was rotated 180° to elevate the sunken sternum and chest wall. Then, surgical stainless wires (#5, ETHICON®, XZW945) were used to secure the bar by pericostal techniques: (I) wire-a was used to fasten the stabilizer and the bar using a cross bundling technique; (II) wire-b and wire-c were used to secure the stabilizer to upper and lower ribs respectively; (III) another wire-d was used to secure the other side of the bar to the adjacent rib (*Figure 1*).

For the 19 patients in Group B, from 2016–2020, a single incision was made between anterior axillary line and midaxillary line in the left side. We implanted the stabilizer in advance and passed PDS sutures on the upper and lower ribs. An introducer was then inserted through the incision to create a tunnel without crossing the chest wall on the other side. After constructing the tunnel, the introducer was withdrawn from the original path. The previously prepared pectus bar was then inserted. After adjusting the position, reverse the pectus bar to elevate the sunken sternum just as above mentioned. Stainless wires and PDS (#2,

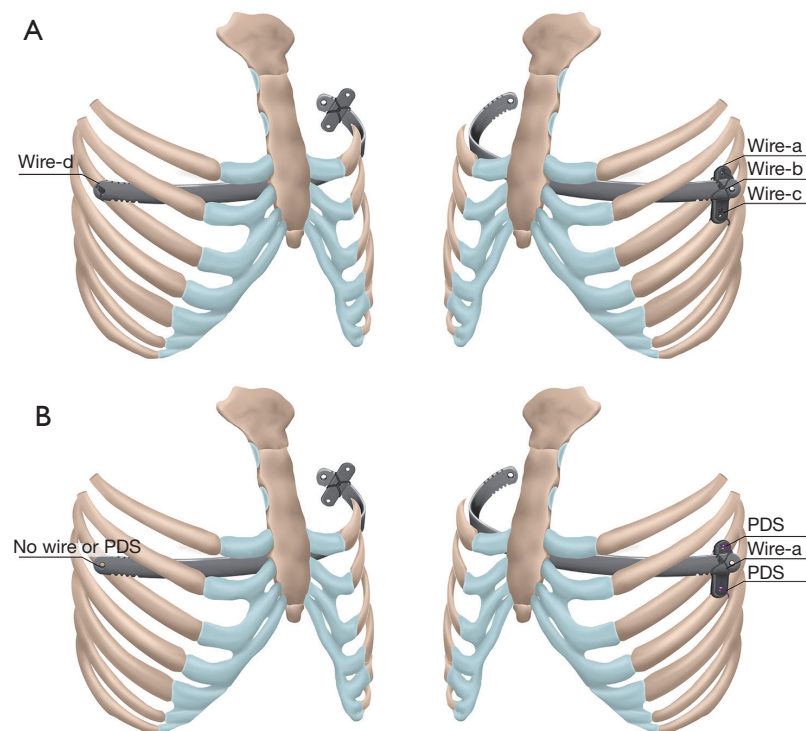


Figure 1 The ideograph of the fixation methods in Group A and Group B. (A) Four fixation points were all secured by wires; (B) the wire-a was retained and the other two points were secured by PDS, while the fixation point on the non-stabilizer side was concealed. PDS, polyblend polyethylene sutures.

ETHICON® XCW9236) were used: (I) wire-a was just as before; (II) PDS were used to secure the stabilizer to upper and lower ribs; (III) the wire-d was canceled (*Figure 1*).

All surgeries were presided over by the same operation surgeon to ensure that the operation habits and various intraoperative treatment methods were basically the same. Patients were followed-up as outpatient, at one, three, six months, and one, two, three years after the surgery. Then the bar removal procedure was performed. Before taking out the pectus bar, callus and sawtooth-like fiberboard around the stabilizer were separated and each wire was extracted (the PDS have been absorbed by tissues). For broken wires, a portable chest X-ray was used to localize.

Statistical methods

Data are expressed as the mean \pm standard deviation (SD), range, or percent with number of patients. Normality was evaluated by using the Shapiro-Wilk test ($P > 0.05$). Comparisons between groups of continuous variables that were normally distributed were carried out using

Student's *t*-test or a corrected *t*-test. Comparisons of categorical variables were performed using the χ^2 test or Fisher's exact test. Statistical analyses were performed by using IBM SPSS v26.0, with a level of significance of 0.05.

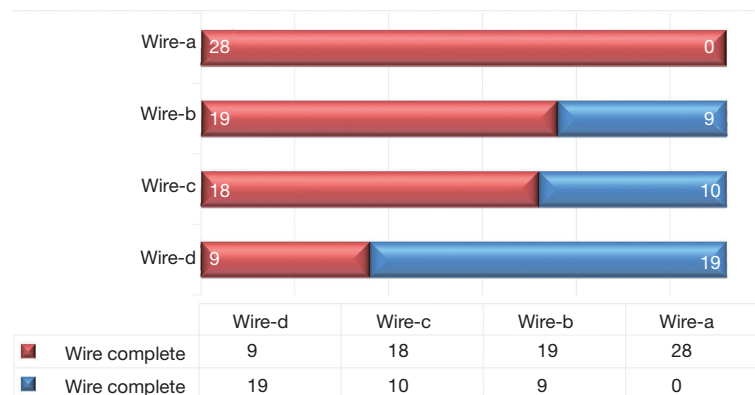
Results

Group A: 21 males and four females, with a mean age of 8.1 ± 4.3 years (ranged from 3.3 to 18.0 years). The mean HI was 4.0 ± 0.3 , ranged from 3.5 to 4.5 (*Table 1*). Twenty-eight groups of wires (wire-a, wire-b, wire-c, and wire-d) were used for bar fixation in 25 patients. Twenty-two of them received a single pectus bar and three patients received double pectus bars. The implanted bar successfully corrected the pectus deformity and achieved satisfactory results, without obvious bar displacement or other complication requiring surgical intervention in all cases during the follow-up period. However, wire fracture occurred in 22 (88.0%) patients, although no related symptom or further complications were found. No patient was found to have broken wire before six months. Fifteen

Table 1 Patients demographics

	Stainless wire group	PDS group
Gender		
Male	21	15
Female	4	4
Age* (years)	8.1 (3.3–18.0)	10.4 (4.0–14.0)
Haller index	4.0 (3.5–4.5)	3.6 (2.5–5.7)
Surgery performed		
Single-bar	22	17
Double-bar	3	2
Wire fracture	22 (88.0%)	0

*, the age when receiving the Nuss procedure.

**Figure 2** The fracture rate in wire-a, wire-b, wire-c, and wire-d.

patients were found with wire fracture during 6–12 months after operation (were first found during the follow-up of 12 months), three patients were found with wire fracture during 1–2 years after operation (were first found during the follow-up of two years), and one patient was found with wire fracture during 2–3 years after operation (were first found during the follow-up of three year). Three patients did not follow up as required, therefore, it was hard to estimate when the wire fractures occurred. Sixty-seven-point-nine percent of wire-d were broken, identified by chest radiography, which was significantly higher than that of wire-b (32.1%, $P < 0.01$) and wire-c (35.7%, $P < 0.05$). Additionally, the wire-a were complete in all cases (Figure 2). The mean operation time in the bar removal procedure was 104.6 ± 42.8 minutes (ranged from 45 to 160 minutes) when encountering wire fractures.

According to the number and location of broken pieces,

we summarized three fracture types (Figure 3): (I) type I, there was only one breakpoint which meant there was no separated wire in this type; (II) type II, there were two or more breakpoints and all of them were scattered anteriorly of the rib; (III) type III, at least two breakpoints were located posteriorly of the rib which meant the broken wires could hide behind the rib.

Most broken wires were adjacent to their original site. Varying degrees of displacement and distant migration also existed, including three grew into the anterior periosteum of the rib, two grew into the posterior periosteum of the rib, one was wrapped by nearby serratus muscles, one migrated to the pleural membrane behind costal cartilage. The wires that grew into the periosteum were usually imperceptible and could not be pinched out directly by clamps because forcible removal of them could cause unnecessary damage to the ribs. Therefore, after roughly identifying the

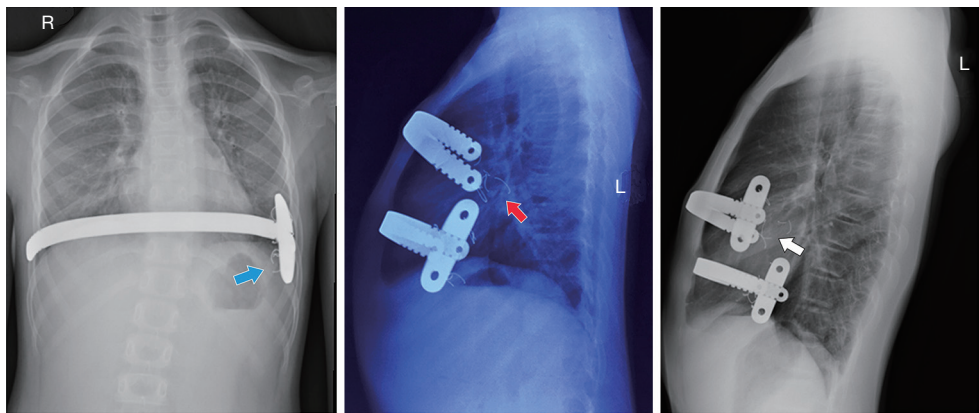


Figure 3 The wire fracture type according to the number and location of wire breaking points. The blue arrow indicated the type I fracture that there was one break point in the wire, so there was no falling fragment. The red arrow indicated the type II fracture that the wire wrapping the anterior half of the rib broke and fell off into two pieces and moved posteriorly. The white arrow indicated the type III fracture that the broken wire was located behind the rib.

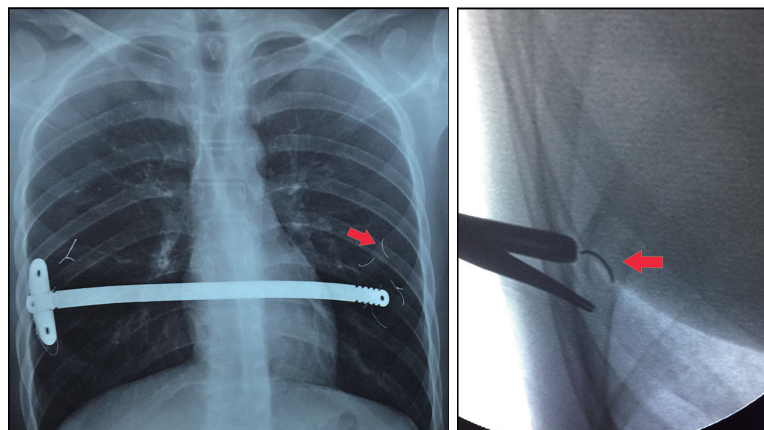


Figure 4 The broken wire pieces migrating to the pleural membrane behind the rib. The red arrows indicated the location of the migrated wire.

localization by portable chest X-rays, we searched for wire fragments by palpating the bony cortex thickened by the foreign body reaction. Then, the electrotonne and pliers were used to open the periosteum and to remove the wire fragments. Removal of the broken wire wrapped by muscles was performed by similar techniques.

In another case, wire fracture without further displacement was initially observed in wire-c and wire-d two years after the operation. Since there was no related symptom (like chest pain or shortness of breath) and the process of correcting the deformation was not completed, we didn't perform surgery to extract the broken wires immediately. One year later, after finishing the correcting

process, the bar removal procedure was performed, and a three-millimeter broken wire hidden on the pleural membrane behind the midclavicular line of the right sixth rib was found. The wire fragment raised and fell with the rhythm of breathing and could pierce the pleural at any time (*Figure 4*). Finally, this unexpected broken wire was extracted and the total operation time was 150 minutes.

Group B: 15 males and 4 females, with a mean age of 10.4 ± 2.9 years (ranged from 4 to 14 years), received the stainless wires and PDS fixation in Nuss procedure (*Table 1*). The mean HI was 3.6 ± 0.9 (ranged from 2.5 to 5.7). There was no statistical difference between Group A and Group B regarding the HIs ($P > 0.05$). Twenty-one wires were

used in the fixation of the pectus bar and stabilizer. No bar displacement or other complication requiring surgical intervention were identified during the current follow-up. In the 11 patients who have received the bar removal procedure, the mean operation time was 51.5 ± 7.4 minutes (ranged from 45 to 67 minutes), which was significantly lower than that in Group A when encountering wire fracture ($P < 0.001$). In addition, the problem of wire fracture did not happen again in this group.

Discussion

It is well accepted that, the Nuss procedure has the advantage of the better cosmetic recovery, shorter operation time, and less blood loss, compared with traditional open techniques (7). However, researchers also indicated that the bar displacement after the Nuss procedure brought more complications and higher reoperation rate (8). Over the past few years, several fixation techniques have been applied to improve the stability and safety of Nuss procedure (4,9-12).

Fixation method

In the original fixation method, described by Nuss, sutures were passed through the holes on both ends of the bar to secure it to lateral chest wall muscles (1). Based on this type of two-point fixation technique, Hebra *et al.* (9) introduced a third fixation point next to the sternum to let the bar and chest wall combined closely. Park *et al.* (13) then invented a five-point pericostal fixation technique: four wires were used to secure the bar (on both ends) to upper and lower ribs, and the fifth wire was in the hinge point. They stated that the major complication rate (1.6%) and reoperation rate (2.0%) were significantly decreased by using this technique. Besides, some researchers proved that securing the bar to adjacent ribs while reducing the intercostal space could improve the overall stabilization (14,15). Recently, Fournier *et al.* (10) introduced a transcostal fixation by using absorbable sutures, that the suture was passed through the cortex of the rib to secure the bar. There was only one (2.8%) cases of bar displacement in their study.

On the other hand, a kind of lateral incorporated stabilizer called stabilizer wing was introduced to stabilize the pectus bar and ribs, which achieved satisfactory results among numerous studies. Therefore, the stabilizer wing was also routinely used in our procedures. Recently, there was a trend towards the use of shorter bars for pectus excavatum correction since very lateral placed stabilizers might

result in higher pectus bar displacement. To date, more convenient and individualized multipoint fixation methods were increasingly utilized and proved to be positive.

Fixation material

Absorbable and non-absorbable sutures were commonly used alone or combined in the early practice of bar fixation (1,9). However, with the gradual reported displacement of the pectus bar, some researchers attribute it to the insufficient toughness of the fixation material. Subsequently, stainless wires were introduced by Uemura *et al.* in 2003 to prevent the bar from full rotation (11). In their study, 91.0% of patients younger than ten years achieved good results by using the wire fixation, while the results in older patients were not as promising as those younger than ten years old. Therefore, they recommended wire fixation in young children. In some large sample studies, stainless wire was also proved to be capable of reducing the bar migration rate and increasing the overall stability of the Nuss system (16,17). However, no technique is free of disadvantages. Uemura *et al.* (11) indicated that wire fracture happened in “many” cases that some broken pieces hid behind the rib, which required fluoroscopy to extract. Additionally, two cases of skin tenderness caused by broken wires required early surgical interventions. In Castellani’s (4) case series, wire fracture occurred in 48 patients (40.7%), which directly contributed to one case of hemothorax and seven cases of failing to extract the broken wire. Recently, Shah *et al.* (3) also reported a high incidence (45.5%) of wire fracture and their secondary complications included pain and pneumothorax. Other researchers also reported pneumothorax or other complications caused by the wire pieces (2,18) (Table 2).

In our practice, wire fracture occurred in 88.0% of the patients, which was considerably higher than that in Castellani’s and Shah’s studies. A comprehensive review of chest radiographs of these 25 patients revealed that: 67.9% of the wire-d were broken, while the wire-a were all intact. The huge difference among wires suggested further exploration of the causes. So far, there was no in-depth analysis of the risk factors of wire fracture in Nuss procedure. Some researchers analyzed the fracture of sternal wire and concluded that the synergic effect of the internal body environment and various applied stress led to the failure of the steel wire (19,20). Although different from the wire fracture in the Nuss procedure, some experience could still be used for reference. We found that in most

Table 2 Literatures referred to wire fracture and their secondary complications

Study	Diameters of wire	Wire fracture	Secondary complication
Uemura 2003	0.8 mm	Many	Pain ×2
Ohno 2003	–	–	Pneumothorax ×1
Castellani 2008	1.0 mm	48 (40.7%)	Hemopneumothorax ×1; Wire residual ×7
Fallon 2013	–	–	– ×1
Shah 2016	–	5 (45.5%)	Pain ×2; Pneumothorax ×1

–, not mentioned.

cases, the wire-d side of the bar relatively shifted to the midline, while the stabilizer side was in place. This may be due to the fact that the pectus bar and stabilizer formed a “T-shape” as a whole, and the three points “b”, “c”, and “d” became the main stress points of the Nuss system. As the physical development and transverse diameter of the thorax widened, the single wire-d gradually failed to provide counterbalanced strength to compete with the assembly of the stabilizer and wires on the other side. Therefore, the relative bar shifting and high fracture rate in wire-d than wire-b and wire-c occurred. In addition, the cross fixation (wire-a) between the bar and the stabilizer was more rigid and firm than the single wire surrounding the rib in other places. The tensile force of wire-a was also relieved by wire-b and wire-c to some extent, which eventually led to a great difference in the fracture rate among wire-a and other wires. It is reasonable to speculate that a variety of factors could collectively lead to wire fractures of which the rapid physical development (after correcting the thoracic deformity and improvement of cardiopulmonary function), the inconsistent force acting to the wire resulting from the different fixation device at both sides, and the reduced resistance of stainless wire itself maybe three important ones. Even though patients and guardians denied any trauma or excessive exercise, we cannot definitively say they are inconsequential. Some cumulative damage that went unnoticed in daily activities and spontaneous thoracic pressure changes caused by cough were inevitable, which could be other potential factors for the occurrence of wire fracture.

It was also worth noticing that the wire fracture occurred in most patients, none of them had distinct bar displacement requiring surgical intervention. Besides, all pectus bars successfully corrected the pectus excavatum deformity to satisfactory results. Obviously, when the integrity of these wires was destroyed, sufficient support could not be

provided to maintain the stability of the Nuss system. So, what prevented the bar from displacement in the early postoperative period other than these intact wires? During the bar removal procedure, we found that the stabilizer and wires were wrapped by solid fibrous tissues as a whole, which took extensive time and extra efforts for surgeons to isolate. It seemed that these fibrous tissues caused by metal foreign bodies and surgical incisions provided long-term protection for the bar. Therefore, we suspected that these solid fibrous tissues had been formed before the wire breakage and gradually replaced wires to provide reliable support until the final bar removal procedure. In this study, 68.2% of the wire breakage occurred in 6–12 months after surgery (were first found during the follow-up of 12 months). However, the bar displacement did not occur, which may indicate that these solid fibrous tissues were greatly formed before this period of time. According to previous literature, these fibrous tissues were believed to form within 4–6 months after surgery (4). Patients should be cautious and pay special attention to symptoms that related to the broken wires during the gap period of fibrous tissue formation.

In order to solve the problem of wire fracture, some previous researchers have used other materials in the bar fixation. Castellani *et al.* (4) replaced the wire with 1.0 mm polyblend polyethylene sutures (PDS) in 49 patients and achieved good results. In recent years, fiberwire was demonstrated to have excellent resistance to fraying and knotted strength (21,22) and was confirmed to be capable of providing the tension required for bar fixation (12). Furthermore, the fiberwire was also successfully applied in adult patients older than 30 years, which made it more reliable in young patients (14).

In our later practice, several improvements were applied to the other 19 patients, including the fixation materials changing and fixation points selecting. Inspired by the

phenomenon of wire fracture without bar displacement and the surrounding solid fibrous tissues, we believed that wire-d had little effect in the bar fixation. Because wire-b and wire-c had certain proportions of fracture, PDS was used as the fixation material between the stabilizer and the rib, instead of wires, to achieve the balance of eliminating the wire fracture while maintaining its overall stability. However, we could not cancel every wire because the stabilizer needed to cooperate with the bar to complete the whole process of deformity correction, and once they were separated, it was likely to cause bar flipping, which could directly lead to unsatisfactory clinical results and additional surgical intervention (4). Therefore, considering the low fracture rate of wire-a, we retained the wire-a to ensure the pectus bar and the stabilizer formed a sturdy integral structure. The reason why we did not increase the diameter or the number of the wires was that we speculated the rigid restriction of these wires may limit the rapid growth of the rib. Besides, we were not clear about how thick the wire that could secure the bar for three years without breaking and the additional wires may complicate the operation. And the advantages of using PDS were that, compared to other common absorbable sutures, it could provide firm fixation in the early postoperative period (more than 60% tension was retained at 1 month postoperatively), and it had a longer absorption time (120 to 180 days) (23). This absorption time almost coincided with the formation time of the fibrous tissues surrounding the bar. Even after its absorption, the fibrous tissues surrounding the bar had become the dominant support in the whole system. The clinical results validated our perspective that, to date, there was no severe complication or bar displacement requiring surgical intervention. In addition, the problem of wire fracture was not encountered again, which greatly protected patients from unnecessary injuries caused by detecting the broken pieces. Because there was no broken wire needing localization and extraction, and the PDS had been absorbed by tissues, the bar removal procedure only included extraction of the stabilizer, pectus bar, the complete wire-a, and some general steps. The mean operation time was, thereby, statistically decreased from 104.6 minutes to 51.5 minutes ($P < 0.001$), which dramatically decreased the difficulty and workload of the operation.

After that, we began to look back at the wire fixation technique and reconsider its necessity in Nuss procedure. In an experienced thoracic surgery team, on the basis of selecting the appropriate pectus bar and fixation point,

are the benefits and disadvantages brought by the wire balanced? Shah *et al.* (3) indicated that complications secondary to wire fixation (8.2%) were more frequent than bar migration needing surgical intervention (1.6%). Our results suggested that both wires and PDS fixation had low bar migration rates, while the broken wire increased the difficulty in the bar removal procedure. Once the wire broke and the extracted pieces could not be spliced into a complete circle, a portable chest X-ray was applied to detect these missing fragments, thus increasing the operation time and whole blood loss. According to our classification of wire fracture, no wire fragments fell off in type I, so the operation was not difficult and just as normal bar removal procedure. In the situation of type II, the falling wire fragments were scattered in front of the rib and were in visual range during operation. Therefore, even if further displacement occurred, the surgical procedure was also not difficult. However, what troubled us most was Type III fracture, because some fragments were located behind the ribs, with concealed location and narrow surgical field. Moreover, some wire fragments behind the ribs were adjacent to the smooth parietal pleura, which could slide further to distant positions through the respiratory movement. According to our experience, most broken wires stayed around the original location. While, some broken pieces may grow into the periosteum of the ribs, and surgeons needed to pay special attention to the back of the ribs where there were limited surgical field. The reason for this may be a minor fracture caused by the rival between rib and wire at the time of wire fixation or during follow-up. In addition, the nearby serratus muscles and distant pleura were also easily neglected wire displacement sites. Therefore, an intraoperative chest radiograph was extremely necessary. Although no secondary complication was found in our patients, we believed that the wire fracture, distant migration of broken pieces, and its secondary complications were dangerous and should not be ignored.

There were several limitations to this study. We were not able to conduct mechanical and material analysis on the broken wires and we assumed that these wires uniformly purchased by the hospital were in conformity with the quality regulations. The retrospective nature of the study and lack of control over variables made it unable to provide direct statistical analysis supporting the PDS fixation. Furthermore, our patients were children with medium to minor symmetric ("Park I") pectus excavatum, so our suggestions may not apply to adult patients and children

with extremely severe pectus deformity.

Conclusions

To date, wire fracture and its secondary complications (pain, pneumothorax, hemopneumothorax, and wire residue) are increasingly regarded in the Nuss procedure. Even though no serious complication occurred in our case series, its high incidence and increased difficulty in surgery perplexed us. We found that the firm fibrous tissue wrapped around the bar became the main force for the fixation of the whole Nuss system. We have made some improvements that cancel the wire fixation on the non-stabilizer side and simultaneously use PDS and wire fixations on the stabilizer side, which avoid the wire fracture while maintaining the pectus bar stability in the treatment of non-severe pectus excavatum. However, for severe pectus excavatum in children and adult pectus excavatum, further studies are needed to determine whether the PDS are applicable.

Acknowledgments

Funding: This work was supported by the funds from the Special Project of Technological Innovation and Application Development of Chongqing (cstc2020jscx-kjfp0005).

Footnote

Reporting Checklist: The authors have completed the STROBE reporting checklist. Available at <http://dx.doi.org/10.21037/tp-20-354>

Data Sharing Statement: Available at <http://dx.doi.org/10.21037/tp-20-354>

Peer Review File: Available at <http://dx.doi.org/10.21037/tp-20-354>

Conflicts of Interest: All authors have completed the ICMJE uniform disclosure form (available at <http://dx.doi.org/10.21037/tp-20-354>). The authors have no conflicts of interest to declare.

Ethical Statement: The authors are accountable for all aspects of the work in ensuring that questions related to the accuracy or integrity of any part of the work are appropriately investigated and resolved. The study was conducted in accordance with the Declaration of Helsinki (as

revised in 2013). The study was approved by ethics board of Chongqing University Three Gorges Hospital (NO.: cstc2020jscx-kjfp0005) and individual consent for this retrospective analysis was waived.

Open Access Statement: This is an Open Access article distributed in accordance with the Creative Commons Attribution-NonCommercial-NoDerivs 4.0 International License (CC BY-NC-ND 4.0), which permits the non-commercial replication and distribution of the article with the strict proviso that no changes or edits are made and the original work is properly cited (including links to both the formal publication through the relevant DOI and the license). See: <https://creativecommons.org/licenses/by-nc-nd/4.0/>.

References

1. Nuss D, Kelly RE, Croitoru DP, et al. A 10-year review of a minimally invasive technique for the correction of pectus excavatum. *J Pediatr Surg* 1998;33:545-52.
2. Ohno K, Morotomi Y, Ueda M, et al. Comparison of the Nuss procedure for pectus excavatum by age and uncommon complications. *Osaka City Med J* 2003;49:71-6.
3. Shah M, Frye R, Marzinsky A, et al. Complications Associated with Bar Fixation after Nuss Repair for Pectus Excavatum. *Am Surg* 2016;82:781-2.
4. Castellani C, Schalamon J, Saxena AK, et al. Early complications of the Nuss procedure for pectus excavatum: a prospective study. *Pediatr Surg Int* 2008;24:659-66.
5. Notrica DM. Modifications to the Nuss procedure for pectus excavatum repair: A 20-year review. *Semin Pediatr Surg* 2018;27:133-50.
6. Park HJ, Lee SY, Lee CS, et al. The Nuss Procedure for Pectus Excavatum: Evolution of Techniques and Early Results on 322 Patients. *Ann Thorac Surg* 2004;77:289-95.
7. Mao YZ, Tang S, Li S. Comparison of the Nuss versus Ravitch procedure for pectus excavatum repair: an updated meta-analysis. *J Pediatr Surg* 2017;52:1545-52.
8. Nasr A, Fecteau A, Wales PW. Comparison of the Nuss and the Ravitch procedure for pectus excavatum repair: a meta-analysis. *J Pediatr Surg* 2010;45:880-6.
9. Hebra A, Gauderer MW, Tagge EP, et al. A simple technique for preventing bar displacement with the Nuss repair of pectus excavatum. *J Pediatr Surg* 2001;36:1266-8.
10. Fournier A, Fron D, Bonneville M, et al. Original bar fixation technique in minimally invasive repair of pectus excavatum in adolescents: A 36-case series. *Orthop*

- Traumatol Surg Res 2020;106:155-7.
11. Uemura S, Nakagawa Y, Yoshida A, et al. Experience in 100 cases with the Nuss procedure using a technique for stabilization of the pectus bar. *Pediatric Surgery International* 2003;19:186-9.
 12. McMahon LE, Johnson KN, Jaroszewski DE, et al. Experience with FiberWire for pectus bar attachment. *J Pediatr Surg* 2014;49:1259-63.
 13. Park HJ, Lee SY, Lee CS. Complications associated with the Nuss procedure: analysis of risk factors and suggested measures for prevention of complications. *J Pediatr Surg* 2004;39:391-5.
 14. Jaroszewski DE, Ewais MM, Chao CJ, et al. Success of Minimally Invasive Pectus Excavatum Procedures (Modified Nuss) in Adult Patients (>=30 Years). *Ann Thorac Surg* 2016;102:993-1003.
 15. Yoon YS, Kim HK, Choi YS, et al. A modified Nuss procedure for late adolescent and adult pectus excavatum. *World J Surg* 2010;34:1475-80.
 16. Park HJ, Chung WJ, Lee IS, et al. Mechanism of bar displacement and corresponding bar fixation techniques in minimally invasive repair of pectus excavatum. *J Pediatr Surg* 2008;43:74-8.
 17. Pilegaard HK. Nuss technique in pectus excavatum: a mono-institutional experience. *J Thorac Dis* 2015;7:S172-6.
 18. Fallon SC, Slater BJ, Nuchtern JG, et al. Complications related to the Nuss procedure: minimizing risk with operative technique. *J Pediatr Surg* 2013;48:1044-8.
 19. Shih CM, Su YY, Lin SJ, et al. Failure analysis of explanted sternal wires. *Biomaterials* 2005;26:2053-9.
 20. Chao J, Voces R, Pena C. Failure analysis of the fractured wires in sternal perichronal loops. *J Mech Behav Biomed Mater* 2011;4:1004-10.
 21. Scherman P, Haddad R, Scougall P, et al. Cross-sectional area and strength differences of fiberwire, prolene, and ticon sutures. *J Hand Surg Am* 2010;35:780-4.
 22. Wüst DM, Meyer DC, Favre P, et al. Mechanical and handling properties of braided polyblend polyethylene sutures in comparison to braided polyester and monofilament polydioxanone sutures. *Arthroscopy* 2006;22:1146-53.
 23. Pillai CK, Sharma CP. Review paper: absorbable polymeric surgical sutures: chemistry, production, properties, biodegradability, and performance. *J Biomater Appl* 2010;25:291-366.

Cite this article as: Zhang Y, Chen Q, Luo Y, Sun C, Chen M, Wu N, Xie Y. Wire fracture in postoperative Nuss procedure: a problem that cannot be ignored. *Transl Pediatr* 2021;10(3):569-578. doi: 10.21037/tp-20-354