

An atypical symptomatic discoid lateral meniscus in a toddler

Michael G. Fazio, DO; Eric J. Royston, DO, MPH; and Veronica J. Rooks, MD

Meniscal tears and meniscal instability are rare complications of a discoid lateral meniscus in a very young child. We report a case of a 32-month-old male who presented with a limp and limited extension of his right knee. Magnetic resonance and sonographic images demonstrated a discoid meniscus with a posterior horn tear and unstable anterior horn, confirmed by arthroscopy. The patient was treated with saucerization of the lateral discoid meniscus, debridement of the posterior horn tear, and repair of the unstable anterior horn. This case shows a rare complication of variant anatomy that is not well documented in the pediatric radiologic literature, but nonetheless should be considered in the pediatric population.

Case report

The parents of a 32-month-old boy noticed that their toddler was limping, but was otherwise well. There was no witnessed trauma. He was taken to an acute-care clinic 5 days later; on examination, he was afebrile and noted to have decreased range of motion with extension of the right knee. There was no swelling, erythema, or warmth of the joint. Knee and hip radiographs demonstrated normal knee anatomy.

On followup with the child's primary-care physician, the child was playful without signs of pain. However, there was still a persistent right-sided limp, and the leg remained flexed at 10-15 degrees at all times. Motrin was prescribed for pain. C-reactive protein and erythrocyte sedimentation rate tests were performed, and both were within normal limits.

The patient was then referred to Orthopedics for further evaluation. The orthopedic surgeon observed an antalgic gait and swelling of the right knee without ballottable effu-

sion. Full extension of the knee joint was achieved only with passive motion, with visible discomfort.

MRI demonstrated a normal, triangular-shaped medial meniscus (Fig. 1A). The lateral meniscus demonstrated an additional lobular 1.1 x 0.5 x 0.8-cm focus of decreased signal posteromedially, representing a torn and displaced discoid meniscus. There was increased T2 signal throughout the remaining portions of the meniscus, compatible with edema. The anterior meniscus was deficient on the T2 sagittal sequence, demonstrating the absence of the "bow tie" (Fig. 1B). There was increased height and globular configuration of the posterior meniscus, consistent with a flipped posterior medial fragment tear. The thickening of the meniscus in the coronal view extending across the entire condyle was consistent with a discoid meniscus.

On arthroscopy, the lateral meniscus was visualized but was incomplete, covering approximately 70% of the surface of the lateral tibial plateau (consistent with a Watanabe type II discoid meniscus). The patient subsequently underwent arthroscopic reduction and fixation of the unstable anterior horn with a single suture using an outside-in technique, as well as debridement of the posterior horn tear and saucerization of the discoid meniscus (Fig. 2). At 3-month followup, the patient was subjectively improved and on physical exam was able to fully extend his knee symmetric to the contralateral side.

Discussion

Symptomatic discoid lateral menisci, meniscal tears, and meniscal instability are extremely rare in toddlers, with

Citation: Fazio MG, Royston EJ, Rooks VJ. An atypical symptomatic discoid lateral meniscus in a toddler. *Radiology Case Reports*. (Online) 2013;8:828.

Copyright: © 2013 The Authors. This is an open-access article distributed under the terms of the Creative Commons Attribution-NonCommercial-NoDerivs 2.5 License, which permits reproduction and distribution, provided the original work is properly cited. Commercial use and derivative works are not permitted.

The authors are all in the Department of Radiology, Tripler Army Medical Center, Honolulu HI. Contact Dr. Fazio at michael.g.fazio@us.army.mil.

Competing Interests: The authors have declared that no competing interests exist.

DOI: 10.2484/rcr.v8i2.828

An atypical symptomatic discoid lateral meniscus in a toddler

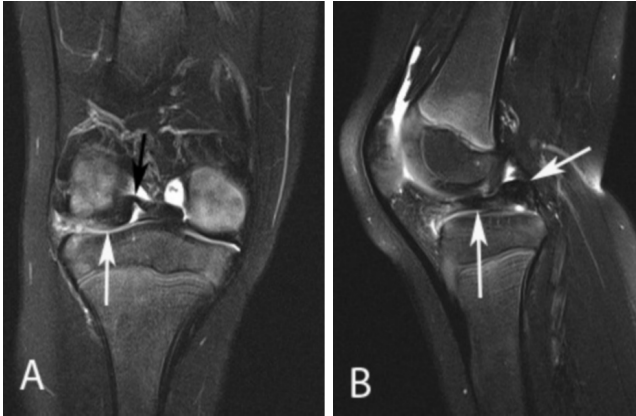


Fig. 1. Discoid lateral meniscus in a toddler. (A) Coronal, T2-weighted, fat-suppressed MR image of the right knee posteriorly demonstrates a homogeneous hypointensity (white arrow) extending across the entire lateral joint space, indicative of a discoid meniscus. There is hyperintensity in the meniscal body with an oblong focus in the intercondylar notch (black arrow) representing a torn meniscus with a flipped anterior horn posteromedially. (B) Sagittal, T2-weighted, fat-suppressed MR image of the middle right knee (at slice thickness of 3 mm with slice spacing of 3.3 mm) demonstrates a homogeneous area of low signal intensity extending anteriorly to posteriorly (vertical arrow) with thickened posterior meniscal tissue (angled arrow) and absence of the anterior portion of the discoid meniscus, resulting in loss of the normal "bow-tie" configuration.

very few cases reported in the literature. Lee et al reported arthroscopic treatment of a symptomatic 26-month-old girl with a torn discoid lateral meniscus (1).

A discoid meniscus is a congenital morphological variant that most often affects the lateral meniscus (2-3). It has a documented prevalence that varies from 0.4 to 17%, occurring more commonly in Asians (16.6%), as compared to 5% in Caucasians (2-4). Discoid menisci may be stable or may lack peripheral attachments, leading to instability and symptoms. The majority of discoid menisci occur laterally and are asymptomatic. Discoid menisci are more susceptible to tearing and degeneration than a normal semilunar meniscus due to several factors, including increased thickness, peripheral motion, and poor vascularization (2).

A normal meniscus should have a "bowtie" appearance on sagittal MR images. If a meniscus is visualized on three or more successive sagittal images with standard adult spacing, it is considered to be discoid. For children, the intervals should be decreased to take into account the smaller size of the patient. Our slice interval was 3 mm, and slice spacing was 3.3mm, nicely depicting the abnormality. Another finding, and in some circumstances the only evidence of a discoid meniscus, may be asymmetric height of the anterior and posterior horns of the meniscus. Children may have an incomplete discoid meniscus, which may be difficult to exclude in the absence of these findings. It is also important

to evaluate for a discoid meniscus in the setting of displaced or unstable meniscal tears. Peripheral rim instability may occur as a result of a discoid meniscus, and it has been reported in up to 28% of cases (5). Most commonly, especially in younger children, the anterior horn is affected. Treatment for a discoid meniscus depends on the presence of symptoms as a result of variant anatomy. Stable discoid menisci are often asymptomatic and are typically observed as opposed to repaired, as a meniscectomy may predispose the patient to early osteoarthritic changes (3-4, 6).

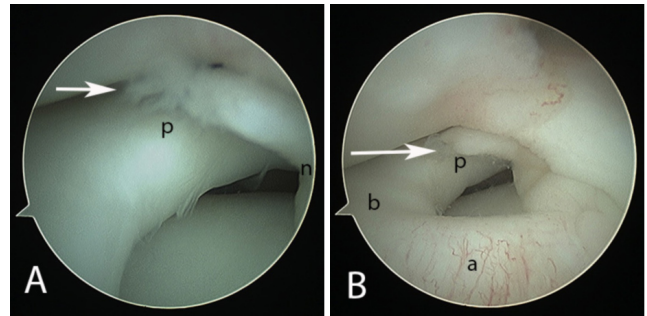


Figure 2. Discoid lateral meniscus in a toddler. Static arthroscopic images of the right knee demonstrate the posterior horn of the lateral discoid meniscus with tear (white arrow) (A), as well as the anterior horn (B) (N- notch; P- posterior horn; B- body; A- anterior horn).

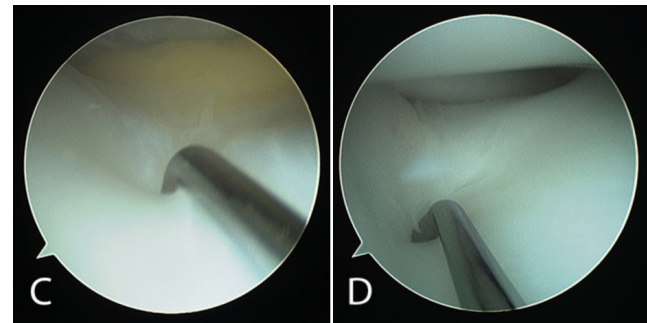


Figure 2, continued. Discoid lateral meniscus in a toddler. The lateral compartment probed demonstrates large posterior (C) and anterior (D) bodies of the meniscus.

Meniscal tears usually occur in the setting of trauma. In preadolescents and adolescents, they commonly occur during sports activities. Tears most commonly involve the medial meniscus, with a prevalence varying between 9% and 34% (2). They are classified based on shape (horizontal, vertical, or complex) and location (peripheral or central) (7). The most common type of tear associated with a discoid meniscus is a degenerative horizontal tear (7). Vertical tears are subdivided based on direction and may be longitudinal or radial or both (which is then called a "parrot beak" tear).

An atypical symptomatic discoid lateral meniscus in a toddler

A bucket-handle tear is a vertical, longitudinal tear with a displaced inner fragment (7). Signs of bucket-handle tears seen on MRI include the “double PCL sign” and absence of the “bow-tie” (7). In our case, due to both of these signs, we initially thought this might be a bucket-handle tear. However, during arthroscopy, we could see that the anterior horn of the meniscus was flipped posteriorly (due to instability in conjunction with a posterior horn tear that was flipped medially), giving a similar appearance.

In the Watanabe arthroscopic classification, a discoid lateral meniscus is divided into three types: type I (complete), which covers the entire tibial plateau; type II (incomplete), which covers less than 80% of the plateau; and type III, which is the Wrisberg variant (2, 8). The presence of a bucket-handle tear with a discoid meniscus is most often seen as a result of the Wrisberg variant, in which there is no support by the posterior attachment of the meniscofemoral ligaments, thereby allowing the posterior segment to flip anteriorly (3). Types I and II discoid menisci generally have normal peripheral attachments and are stable with probing. Our case was consistent with a type II discoid meniscus, and was even more unusual in that the anterior horn of the discoid meniscus was unstable and flipped posteriorly. Signs and symptoms of a meniscal tear include snapping, pain, swelling, locking, and limited motion. Symptoms may occasionally be insidious and without a history of previous trauma, in contrast to the usual presentation of an acute meniscal tear. If a discoid meniscus is symptomatic, the generally accepted treatment is a partial meniscectomy (3-4).

Diagnosis of a discoid meniscus can be difficult, as there are no specific clinical findings. A history of knee-clicking or snapping is common in children with an unstable discoid meniscus (2, 8). Discoid menisci without associated tears may remain asymptomatic, only to be identified incidentally on MRI or arthroscopy. MRI is therefore helpful when the clinical diagnosis is uncertain (4).

Acknowledgements

The views expressed in this manuscript are those of the authors, and do not reflect the official policy or position of the Department of the Army, Department of Defense, or the United States Government. The authors have no financial, personal, or other vested interests in the information contained within this document.

References

1. Lee BI, Choi SH (2003) Arthroscopic treatment of symptomatic discoid lateral meniscus in a 26-month-old girl. *Arthroscopy* 19(10):1133-1136. [PubMed]
2. Choi JW, Chung HW, Ahn JH, Yoon YC (2009) Central hole tear of the discoid meniscus of the knee in magnetic resonance imaging: mimicking the bucket-handle tear. *J Comput Assist Tomogr.* 33(1):155-159. [PubMed]
3. Cosgarea AJ, Ryan A (2000) Repair of a bucket-handle tear of a complete discoid lateral meniscal incarcerated in the posterolateral compartment. *Am J Sports Med.* 28(5):737-740. [PubMed]
4. Mayer-Wagner S, von Liebe A, Horng A, Scharpf A, Vogel T, Mayer W, Jansson V, Glaser C, Muller P (2011) Discoid lateral meniscus in children: magnetic resonance imaging after arthroscopic resection. *Knee Surg Sports Traumatol Arthrosc.* 19:1920-1924. [PubMed]
5. Klingele KE, Mininder SK, Hresko MT, Gerbino P, Micheli LJ (2004) Discoid lateral meniscus: Prevalence of peripheral rim instability. *J Pediatr Ortho* 24: 79-82. [PubMed]
6. Patel D, Dimakopoulous P, Denoncourt P (1986) Bucket handle tear of a discoid medial meniscus arthroscopic diagnosis – partial excision: A case report. *Orthopedics.* 9(4):607-608. [PubMed]
7. Helms CA. The meniscus: Recent advances in MR imaging of the knee. *Am J Roentgenol* 2002; 179:1115-1122. [PubMed]
8. Kocher MS, Klingele K, Rassman SO. Meniscal disorders: Normal, discoid, and cysts. *Orthop Clin North Am* 2003; 34:329-340. [PubMed]