

## Cystic Mass on Right Atrium of Unusual Form of Chiari's Network: A Case Report

Chi-Hoon Bae, M.D., Oh-Choon Kwon, M.D., Sub Lee, M.D., Chul Ho Lee, M.D., Jun Woo Cho, M.D.

Chiari's networks are present in 1.5% to 4% of the population. They are a congenital disease characterized by a remnant of the right valve of sinus venosus and rarely have clinical significance. Chiari's network, as the name implies, has network-like shape, but there are other forms of appearance. We have experienced a case of a 60-year-old woman who had a cystic mass on the right atrium. Surgical treatment was performed for the mass removal and differential diagnosis of the mass. There was no evidence of other tumor, but Chiari's network. As cystic form of Chiari's network have not been reported before, it is the first report of cystic form of Chiari's network.

Key words: 1. Chiari's networks  
2. Surgical procedure  
3. Right atrium

### CASE REPORT

A 60-year-old woman visited Daegu Catholic University Medical Center due to periumbilical pain lasting several days. The patient had no medical history except a benign ovarian tumor which she had under gone surgery 13 years earlier. According to physical examination findings, the sound of a regular heart beat and clear breathing were observed. The blood pressure was 108/69 mmHg, pulse 81 beats per minute, respiratory rate 20 breaths per minute, and body temperature 36.5°C. On laboratory test, only the cholesterol was high at 205 mg/dL. Old pulmonary tuberculosis was observed through a simple chest X-ray. On a computed tomography (CT) scan of the abdomen, a lesion suspected being a mass on the right atrium was found (Fig. 1). On trans-thoracic and trans-esophageal echocardiograms, a 2.65×3.06 cm mobile

cystic mass was visible on the right atrium and some small calcified masses were also seen inside (Fig. 2). Normal cardiac function was observed, and no abnormal observations were found in cardiac motility or the heart valves. Positron emission tomography-CT was performed due to her gynecologic history, but there was no evidence of malignancy and the CA-125 was within normal range.

Surgical treatment was performed for mass removal. After median sternotomy, an arterial cannula was inserted into the ascending aorta and, a venous cannula into the superior and inferior vena cava. We also started extracorporeal circulation, and decreased the central temperature to 28°C. Cardioplegia was induced by infusing retrograde cardioplegic solution into the coronary sinus, an incision was made in the right atrium, and a 3 cm cystic mass was identified on the lower margin of the limbus fossa ovalis, which had been connected by a

Department of Thoracic and Cardiovascular Surgery, Daegu Catholic University Medical Center, Catholic University of Daegu School of Medicine

Received: November 20, 2011, Revised: April 19, 2012, Accepted: April 28, 2012

Corresponding author: Oh-Choon Kwon, Department of Thoracic and Cardiovascular Surgery, Daegu Catholic University Medical Center, Catholic University of Daegu School of Medicine, 33 Duryugongwon-ro 17-gil, Nam-gu, Daegu 705-718, Korea  
(Tel) 82-53-650-4566 (Fax) 82-53-650-6963 (E-mail) ockwon@cu.ac.kr

© The Korean Society for Thoracic and Cardiovascular Surgery. 2012. All rights reserved.

© This is an open access article distributed under the terms of the Creative Commons Attribution Non-Commercial License (<http://creativecommons.org/licenses/by-nc/3.0>) which permits unrestricted non-commercial use, distribution, and reproduction in any medium, provided the original work is properly cited.

stalk. The cystic mass was completely removed, and three 0.5 cm calcified masses and old blood without clotting were found in the cyst (Fig. 3). There were no remaining lesions associated with the mass. The incision was sutured, and weaning from cardiopulmonary bypass was possible without complications. The pathologic finding was Chiari's network.

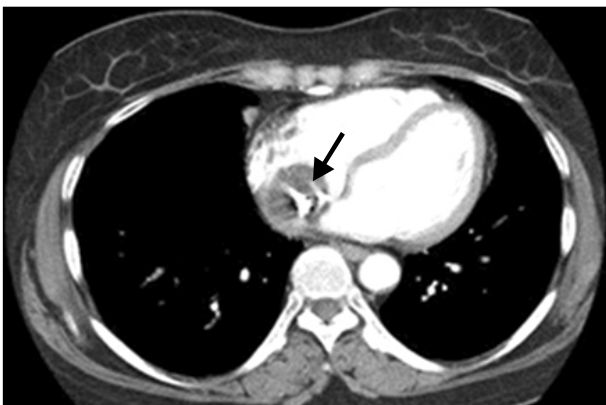## DISCUSSION

Chiari's network is a congenital disease characterized by a remnant of the right valve of the sinus venosus. It was first described in 1897 by Hans Chiari, who described 11 cases in which the valve of the inferior vena cava, the Eustachian valve, represented by networks with attachments to the superior vena cava and to the tubercle of Lower [1,2]. In normal embryology, the right valve of the sinus venosus is regressed, while the Thebesian and Eustachian valves are remain at 15

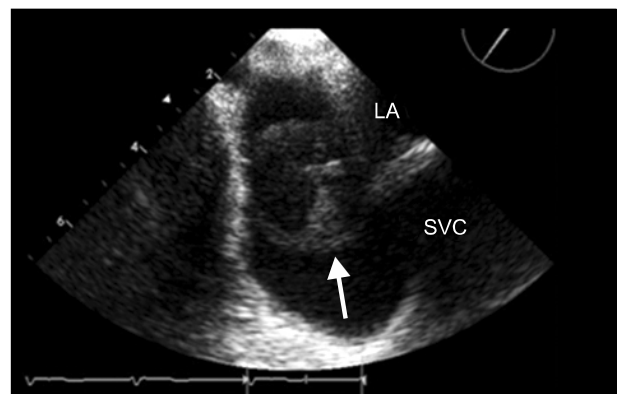
weeks of gestational age [2]. Chiari's networks are present in 1.5% to 4% of the population, and they rarely have clinical significance [2-4].

Chiari's network has a broad variety of possible appearances. Some reports have described the network as highly mobile, with an oscillating or whiplike motion pattern during each cardiac cycle [4].

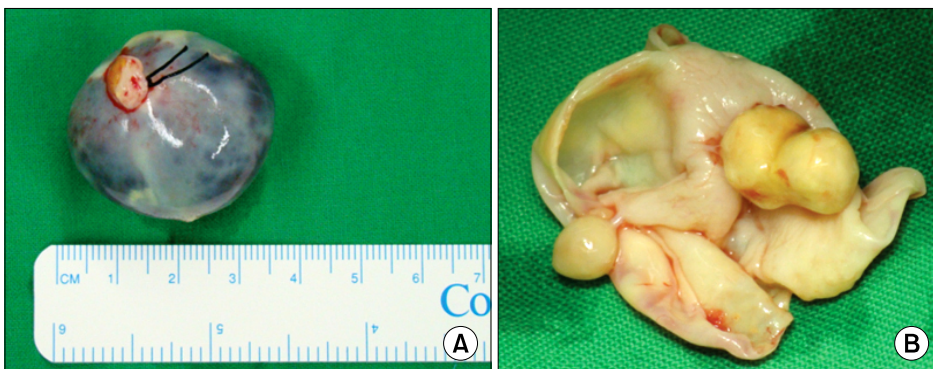
The close relationship between Chiari's networks and patent foramen ovals (PFOs) has been well documented [4]. According to Schneider et al. [4], PFO was detected in 83% of patients with Chiari's networks compared with 28% of controls. However, in patients with Chiari's network, a PFO was significantly more common in arterial embolic events [4]. They also found that right-to-left shunting of a PFO was significantly more common in patients with Chiari's network than in control patients [4]. For this reason, PFOs may be



**Fig. 1.** Computed tomography image of right atrial cystic mass. The arrow shows the calcified mass in the cyst.



**Fig. 2.** Transesophageal echocardiography image of right atrial cystic mass. The arrow shows heterogeneous mass in right atrium. LA, left atrium; SVC, superior vena cava.



**Fig. 3.** (A) Gross photo of cystic mass and (B) incised view of cystic mass.

come a source of cerebral and peripheral arterial emboli, although a right atrial thrombus is usually asymptomatic in Chiari's network [5].

Schneider et al. [4] identified atrial aneurysms in 7 out of 29 patients with Chiari's networks, who were associated with a PFO. In the same context, among the patients with atrial aneurysms, 21% were found to have Chiari's networks [4]. Cardiac arrhythmias have also been reported in patients with Chiari's networks. The arrhythmias terminated with surgical excision of Chiari's network [2,6,7]. There are reports of Chiari's networks acting as a physical barrier of right-sided catheters and pacemakers [4]. There are also rare reports of Chiari's network associated with valvular endocarditis [2].

The diagnosis of Chiari's network is usually made incidentally. The echocardiographic finding of Chiari's network is a mobile curvilinear structure on the right atrium. CT and magnetic resonance imaging also differentiate Chiari's network from other cardiac masses [3].

In our case, the patient was not found to have PFO, atrial thrombus, or atrial aneurysm. We presumed that the right atrial mass was a teratoma as her history of ovarian tumor and echocardiographic findings were cystic and calcified lesions. On pathologic study the mass was confirmed as Chiari's

network. As cystic form of Chiari's network have not been reported before, it is the first report of cystic form of Chiari's network.

## REFERENCES

1. Powell ED, Mullaney JM. *The Chiari network and the valve of the inferior vena cava*. Br Heart J 1960;22:579-84.
2. Payne DM, Baskett RJ, Hirsch GM. *Infectious endocarditis of a Chiari network*. Ann Thorac Surg 2003;76:1303-5.
3. Loukas M, Sullivan A, Tubbs RS, Weinhaus AJ, Derderian T, Hanna M. *Chiari's network: review of the literature*. Surg Radiol Anat 2010;32:895-901.
4. Schneider B, Hofmann T, Justen MH, Meinertz T. *Chiari's network: normal anatomic variant or risk factor for arterial embolic events?* J Am Coll Cardiol 1995;26:203-10.
5. Pansini L, Iorio C, Mattace R. *Occurrence of the Chiari network in a centenarian: echocardiographic study and magnetic resonance imaging*. Arch Gerontol Geriatr 1996;22 Suppl 1:399-402.
6. Clements J, Sobotka-Plojhar M, Exalto N, van Geijn HP. *A connective tissue membrane in the right atrium (Chiari's network) as a cause of fetal cardiac arrhythmia*. Am J Obstet Gynecol 1982;142(6 Pt 1):709-12.
7. Goedde TA, Conetta D, Rumisek JD. *Chiari network entrapment of thromboemboli: congenital inferior vena cava filter*. Ann Thorac Surg 1990;49:317-8.